

Lip tape therapy in patients with a cleft lip – a report on eight cases

SADJ March 2014, Vol 69 no 2 p62 - p69

S M Dawjee¹, JC Julyan², JC Krynauw³

ABSTRACT

Introduction: Lip tape therapy or lip taping is a widely used tissue approximation technique in cleft lip babies. Various tapes have been tested and used worldwide. Allergic reactions and skin irritation are the most common problems encountered. Tension force across the tape cannot be consistently applied. Cost is also an obstacle to adopting lip tape therapy, particularly in developing countries.

Aim: A study was undertaken to evaluate a different tape, "physio tape", which has never been used for lip approximation in cleft lip babies.

Method: Eight babies were available for this study, which was conducted over a six-week period (Ethical Approval number 33/2013). Standardised pre- and post-treatment recordings were made with a digital camera and soft tissue analysis was carried out with Cliniview software.

Results: All participants showed a reduction in cleft size ranging from 9.1mm to 36.7mm at the vermilion end of the cleft. Caregivers had no difficulty with the lip tape procedure and generally no untoward or allergic reactions were reported.

Conclusion: On the basis of the positive results of this investigation, it is recommended that this method of lip tape therapy be used on all babies born with a cleft lip. It is affordable, simple to use and should facilitate the surgical repair.

INTRODUCTION AND REVIEW

1. **S M Dawjee:** *BChD, BChD Hons, MSc(Odont), MDent(Ortho), PGDip IRE, PhD.* Head of the Department of Orthodontics, University of Pretoria, South Africa.
2. **JC Julyan:** *BChD V.* Undergraduate student, University of Pretoria, South Africa.
3. **JC Krynauw:** *BChD V.* Undergraduate student, University of Pretoria.

Corresponding author

S M Dawjee:

Department of Orthodontics, School of Dentistry, University of Pretoria, P.O. Box 1266, Pretoria, 0001, Gauteng, South Africa. Tel: +27 082 778 6450. E-mail: s.dawjee@up.ac.za

Clefting of the upper lip results from the absence of fusion or incomplete fusion of the maxillary and medial nasal processes. In a complete labiomaxillary cleft, the muscles of the nasal floor and the upper lip cannot bridge the gap of the cleft and cannot unite with their muscular counterparts on the opposite side. The muscular integrity of the region is considerably disrupted, which has a profound effect on the underlying skeleton, the child's development and the social well-being of the family.

Anteriorly, the ring of muscles surrounding the oral cavity may be divided into four segments¹:

- A superior nasolabial segment formed on each side by the transverse fibres of the nasalis muscle and the levator muscles of the upper lip;
- Central labial segments formed on each side by the orbicularis oris muscles of both the upper and the lower lips; and
- A lower labiomental segment formed by the depressor anguli oris, depressor labii and mentalis muscles.

In patients with cleft lips, the physiological function of the transverse fibres of nasalis is the most affected element of the nasolabial ring. These fibres pass from the anterior border of the nasal bone to the incisive crest and then to the nasal septal perichondrium. Not only is this muscle responsible for nostril constriction but, together with the external fibres of the orbicularis oris muscle, it provides support for both its corresponding half of the upper lip and indirectly, the labial commissure.

In cases of total unilateral labiomaxillary cleft, the muscles on the cleft side remain lateral to the defect and cannot function normally, even if they are correctly formed. Deprived of the nasal septum and the anterior nasal spine as points of anchorage, the structure on that side collapses, as a tent would if its central pole was lost.¹ Growth of the minor segment of the maxillofacial complex appears reduced, probably as a consequence of the absence of stimulation from the nasolabial muscles.

Parents are usually very distressed at the birth of an infant with a cleft and become desperate for urgent attention and solutions. Several factors, however, influence the optimum timing for closure of a cleft lip. In young infants, it is practically impossible to distinguish the individual muscle bundles which,



because of lack of function, are underdeveloped, friable and unable to adequately support sutures. It is therefore preferable to wait until at least the end of the fourth month *post partum*.² By then the labial musculature will have developed significantly as a result of both growth and functional stimulation created by sucking, crying and other facial activity.

The type of the cleft, whether unilateral or bilateral, must also be considered. In unilateral complete clefts, early reconstruction of the lip further reduces forward growth of the lesser fragment. Such a situation results in retrusion of the entire dentoalveolar segment and underdevelopment of the premaxilla, which is a problem that is difficult to correct later. Some treatment protocols recommend waiting until the end of the sixth month, by which time the upper deciduous incisors are further developed or even erupting.³

Early surgery is also not without risk and possible complications might be:⁴

- Life threatening, e.g. upper airway obstruction;
- Local, associated directly with surgery, e.g. haemorrhage and dehiscence; or
- General and without direct relation to surgery, e.g. cross infections during the hospital stay.

The incidence of local infection and dehiscence of lip closure varies in the literature from 1% to 7.4% and is mostly observed in bilateral clefts.⁵

Generally the 'rule of ten' (10g haemoglobin, 10 weeks of age and 10 pounds of bodyweight), is applied for determining the time of the surgical correction of congenital clefts.⁴ While a waiting period of four to six months may be physiologically and medically appropriate, it may be psychologically distressing for anxious parents.

Lip taping or lip tape therapy is a clinically beneficial and socially comforting interim treatment procedure that can be implemented from birth to the date of the cheiloplasty.⁶ According to Grayson and Shetye, this form of pre-surgical infant orthopaedics has been used in the treatment of cleft lip and palate patients for centuries.⁷ Early alignment across the cleft will assist in projecting the upper lip symmetrically and is necessary to ensure the best possible facial growth during childhood.⁸

Initial techniques were focused on elastic retraction of the protruding premaxilla.⁷ In 1689, Hoffmann demonstrated the use of facial binding to narrow the cleft and prevent

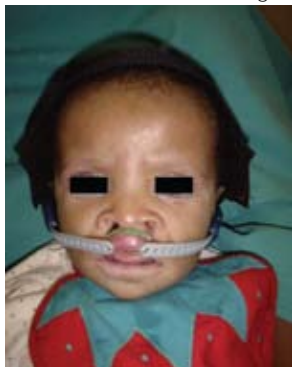

Figure 1: The prolabium retractor

post-surgical dehiscence. A similar technique, shown by Desault in 1790, aimed to retract the maxilla before surgical repair in patients with bilateral cleft. In 1844, Hüllihen stressed the importance of pre-surgical preparation of clefts using an adhesive tape binding.⁹ Complex appliances such as the prolabium retractor (Figure 1) have also been used to align the premaxilla in bilateral clefts.

The most frequent complications and difficulties associated with pre-surgical lip taping are skin irritation and ulceration.⁷ These conditions are aggravated by the type of tape used and the frequency of removal and replacement, together with the degree of tissue tolerance to ulceration. The magnitude of the force needed to approximate the tissues will also be an influence. Any inconsistency in tape application will result in relapse of the tissues and might compromise the final outcome.

The use of skin barrier tapes on the cheeks like DuoDerm® or Tegaderm® has been advocated for reducing irritation.¹⁰ Whilst these are protective, extreme care should be taken when removed. Additionally, it is advocated that the overlying retraction and horizontal tape should be removed once a day, (usually at bath time) and hydration cream such as an aloe vera gel be applied to the cheeks.⁷ Each time the base tape is changed, the position of the horizontal and retraction tape on the patient's face should be varied, to allow ventilation of the underlying epidermal tissue and enable the skin tissue to recuperate, reducing the possibility of irritation.

Base tape remains affixed to the cheeks for four to six days. During this time, the protective tape greatly reduces the amount of cheek tissue irritation normally created by retraction and the horizontal tape.¹¹

It is possible that the difficulties and complications associated with the current material and technique of lip taping may be reduced or even prevented by the use of a different tape. This study reports on a clinical assessment of a product generally referred to as "physio tape" as an alternative material in the lip tape therapy protocol.

Physio tape is marketed as Kinesio®, Leuko®, Spider® or Rock® tape. It is a brightly coloured elastic tape, popularised by physiotherapists in the management of muscle stabilisation related to sports and sporting injuries. It is a cotton-based non-latex tape with adhesive on one side and comes in many different colours, shapes and sizes.¹²

Physio tape is primarily used by sports therapists and its application is based on the following four principles:¹²

- Providing support or restricting movement in an area;
- Improving the functioning of the area being taped;




Figure 2: Digital camera with a frame providing a fixed object lens distance



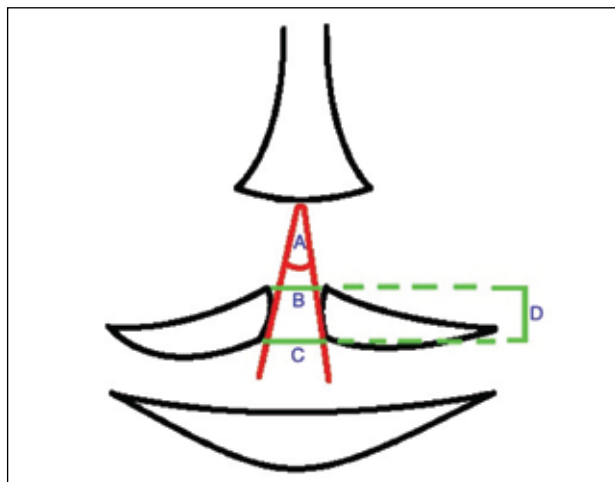


Figure 3: The planes and measurements used

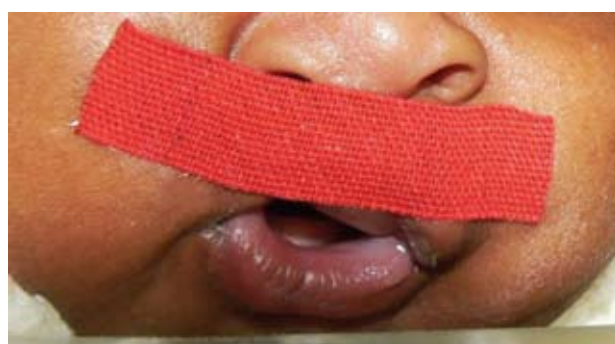

Figure 4: The physio tape in position on the upper lip

- Improving circulation to tissues; and
- Providing some level of feedback to an area.

One advantage that physio tape should have over any other tapes used for cleft lips, is that it has the same elasticity as the skin, which is normally between 130% and 140%.¹²

Physio tape is applied by stretching it over the target area. The tape wraps tightly around the muscles, convoluting the overlying skin. The amount of force is proportional to the stretch while the placement and distribution of the force could vary, depending on the clinical objective.

According to the manufacturers, physio tape constricts the soft tissues and increases blood circulation¹³ bringing more nutrients and energy circulating in the area. In addition, the pressure exerted by the tape numbs the sensory cells of the skin and reduces the perception of any kind of sensation in that area. Physio tape offers a gentle and effective approach to the re-education of the neuromuscular system, to improving the circulation of blood/lymph, to the relief of pain and to providing comfort and stability. The tape also allows athletes to use muscles for a longer duration as it numbs the sensation of muscle pain and fatigue.

Physio tape has been designed to support muscles throughout the day and can be worn for up to three days without being removed. The adhesive is a very strong hypo-allergenic zinc oxide poly-acrylic, having a wave pattern similar to a fingerprint, promoting the natural stretch of

Table 1: Changes in cleft angle(°)

Patient	Before	After	Cleft approximation
1	25.5	16.9	8.6
2	75.9	36.1	39.8
3	51.4	24.2	27.2
4	92.4	74.3	18.1
5	53.7	45.2	8.5
7	43.3	20.3	23
7	69.4	23.5	45.9
8	48.6	9.9	38.7
Average	57.53	31.3	26.23

the skin and contributes to the therapeutic effect of the tape.¹⁴ The material is porous and permits ventilation of the skin while adhesion is maintained. The tape is also water resistant, dries easily and can be used during swimming and showering.¹³

Owing to its hypo allergenicity, the adhesive tape can be used with all skin types. A test patch is recommended for those patients with allergic tendencies. Any excess oils, sweat and dirt should be removed prior to application. As the tape is heat activated, the product should not be stored in direct sunlight or high temperatures.¹²

AIM

The aim of the study was to evaluate the effectiveness of physio tape as a means of approximating soft tissues in cleft lip babies.

MATERIAL AND METHOD

This study was undertaken in the Facial Cleft Deformity Clinic of the Department of Maxillo-Facial and Oral surgery of the University of Pretoria. The investigation was initiated with eight new born babies. Lip taping started within the first week postpartum and lasted for six weeks. Patients were selected on a "first come first served" basis, irrespective of their race, gender and socio-economic category.

Records consisted of frontal photographs taken with a Panasonic Lumix® digital camera (Figure 2), with the use of a 35mm lens, having a frame determining a fixed object-film distance of 150mm. Recordings were taken at the start of treatment and again after six weeks. The photographs were taken at the standardised distance with the frame resting against the patient's forehead and chin. Measurements of any changes in the cleft size were determined with the use of Cliniview® software.

The following parameters were measured (figure 3):

- Cleft angle – the cranially projected angle formed between left and right borders of the cleft.
- Subnasal width of cleft – the superior distance between the right and left cleft borders.
- Vermillion width of cleft – the inferior distance between the right and left cleft borders.

The perpendicular distance (D) between measurement B and C was specific for each patient and was recorded for the pre- and post-treatment measurements of each patient.



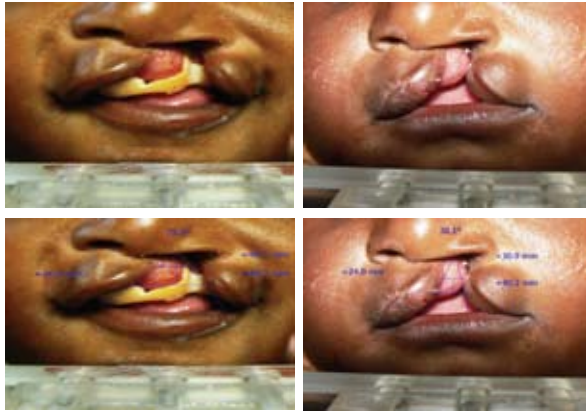

Figure 5: Pre- and post-treatment photographs and measurements of Patient 1

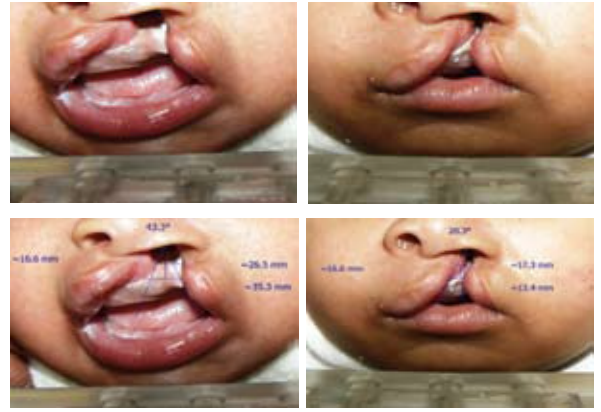

Figure 9: Pre- and post-treatment photographs and measurements of Patient 5

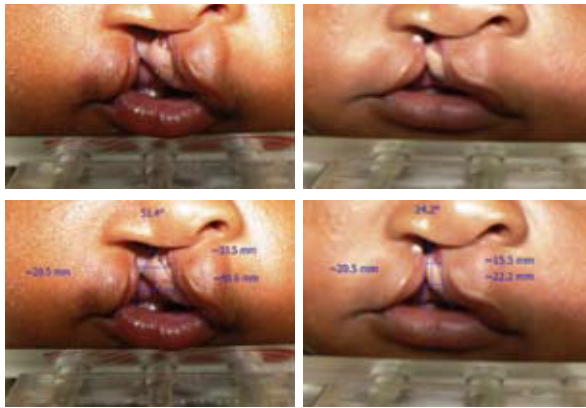


Figure 6: Pre- and post-treatment photographs and measurements of Patient 2

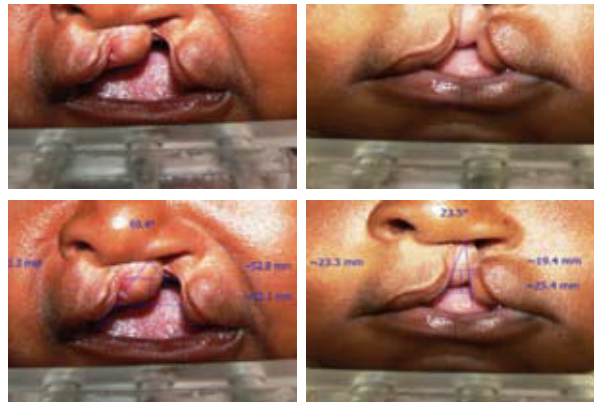


Figure 10: Pre- and post-treatment photographs and measurements of Patient 6

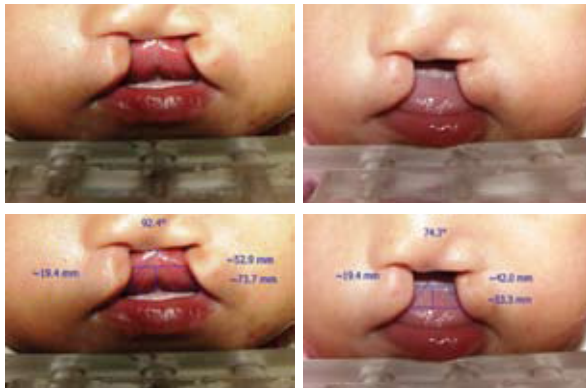


Figure 7: Pre- and post-treatment photographs and measurements of Patient 3

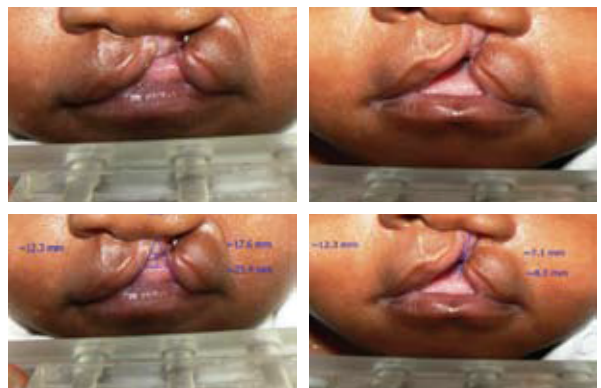

Figure 11: Pre- and post-treatment photographs and measurements of Patient 7

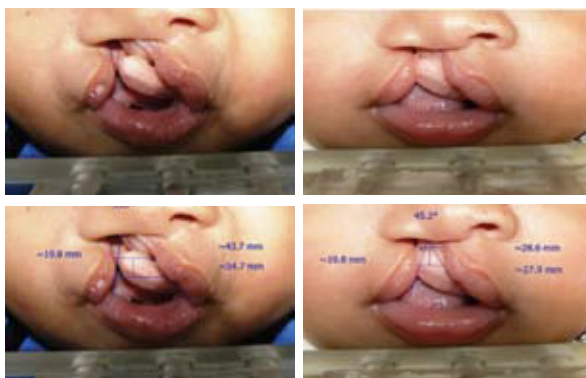


Figure 8: Pre- and post-treatment photographs and measurements of Patient 4

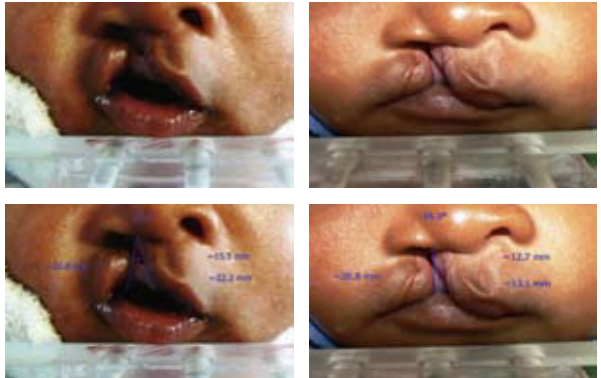


Figure 12: Pre- and post-treatment photographs and measurements of Patient 8



The physio tape was cut into standardised lengths of 5cm and the amount of stretch determined *in vitro* amounted to 25%. In other words, when used clinically, the 5cm tape would measure 6.25cm after placement across the cleft (Figure 4). The lip taping procedure was carefully explained to the caregiver. Nursing and support staff were present to address any concerns of the caregiver. Caregivers were instructed to remove the tape slowly and carefully after one to three days, to clean the area, and immediately apply a fresh strip of tape. Additional strips of physio tape were supplied to the caregiver at the first and subsequent visits. Patients were recalled every three weeks for an examination and evaluation.

The physio tape was sponsored by the Department of Orthodontics and the patients did not incur any additional cost.

This study was approved by the Ethics Committee of the University of Pretoria, (reference no. 33/2013) and was undertaken with informed consent and participation of the parent/guardian.

RESULTS

Results from the initial eight patients who participated in the study, are illustrated and changes in the cleft size are presented in the Tables and bar charts (Figures 5 to 15 and Tables 1 to 3).

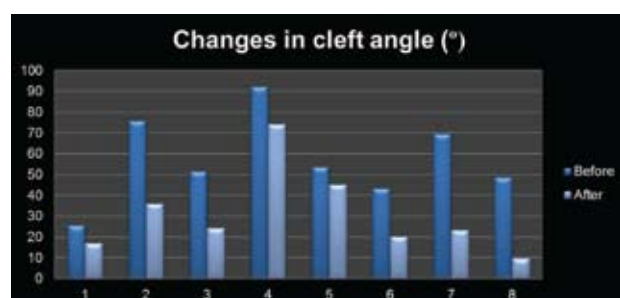


Figure 13: Changes in cleft angle in degrees

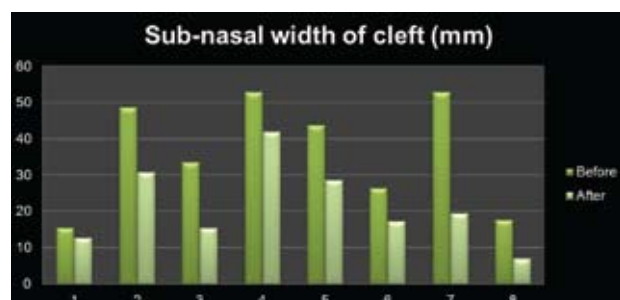


Figure 14: Changes in the sub-nasal width of the cleft expressed in mm

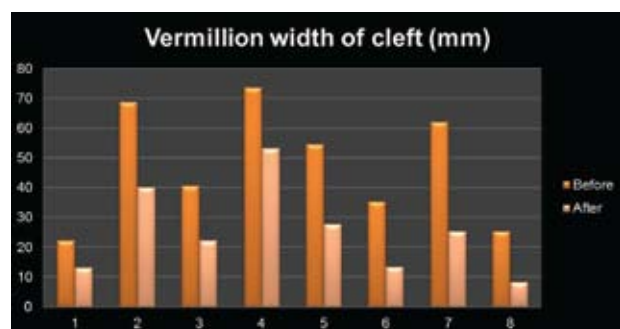


Figure 15: Changes in the vermilion width of the cleft expressed in mm

DISCUSSION

Clefting of the lip and palate is one of the most common congenital malformations encountered worldwide. It affects about 1 to 1.6 per 1000 live births and is more common in males than in females.^{15,16} It occurs more frequently on the left side than on the right side of the face.¹⁷ The condition can come as a severe emotional shock to parents, particularly in third world countries where pre-natal detection is not affordable and parents cannot be sensitised before the birth of their child. Such emotional trauma can lead to a sense of blame, guilt and strained social relations at a time when family support is most needed.

The definitive and in fact, only, remedy, to close the cleft is surgery and depending on the surgical protocol employed by the particular clinic, surgical repair may be undertaken from four to seven months post-partum. Lip taping from birth to the time of surgery can be a supportive and emotionally comforting intermediate measure.⁹ The success of lip taping procedures has, in the past, had some limitations. The most notable drawback of, and limitation to, previously used methods was the complication of skin irritation. This may be evident as a rash or bruising of the cheeks or lips and is usually a result of daily tape replacement. The skin reaction is aggravated by moisture, caused by drooling and seepage of milk during suckling. Allergies to the tape and the adhesive can also compound the problem. Suspension of the taping procedure is often necessary to allow the cheeks and lips time to recover. Because the amount of tissue alignment acquired during the phase of active treatment cannot be retained, some degree of relapse will occur between treatment phases. Hence the net benefit of lip taping is reduced.

As an initiative to overcome the problems described above, physio tape was tested on eight patients with an associated cleft lip. Patients were taped for the full six weeks and the results of this study are positively self-evident. All patients showed a notable reduction in the size of the cleft.

The cranial apex angle formed by the two sides of the cleft was reduced on average by 26.2 degrees, with a range of 8.5 to 45.9 degrees (Table 1, Figure 13). Lip approximation at the sub-nasal end averaged 14.73mm with a range of 2.8mm to 33.5mm (Table 2, Figure 14) while approximation at the vermilion end averaged 22.36mm within a range of 9.1mm to 36.7mm (Table 3, Figure 15).

Parents and caregivers were cooperative and did not report any complications or untoward incidents. Patient number,⁵ however, showed some sign of reaction on the cheek, which – upon inquiry – was found to be due to incorrect application and removal of the tape. The caregiver was re-instructed on how to remove the tape carefully and gently.⁷

Some undesirable tissue stretching, due to crying, is evident in the pre-treatment recordings of patients numbered 1, 5 and 6. This may lead to the assumption that cleft closure in these three cases would be exaggerated, as the pre-treatment recordings of all the other patients were taken in repose. However post-treatment readings of these patients did not show greater closure and the most significant cleft



Table 2: Sub-nasal width of cleft (mm)

Patient	Before	After	Space closure
1	115.5	12.7	2.8
2	48.7	30.9	17.8
3	33.5	15.5	18
4	52.9	42	10.9
5	43.7	28.6	15.1
7	26.5	17.3	9.2
7	52.9	19.4	33.5
8	17.6	7.1	10.5
Average	36.41	21.69	14.73

closure was found in patient number 7, followed by patient number 2, who were completely relaxed at both pre- and post-treatment recordings.

Physio tape can be quite flexible in its application. In all eight patients the tape was centred over the cleft with the ends attached mesial to the cheeks. While the 25% stretch in the tape was uniformly distributed over the length of the tape for this study, it can also be applied differently with the stretch confined to the cleft area and the attachment to the cheeks remaining passive. A uniform stretch was thought to be less cumbersome to caregivers who were also supplied with a measuring instrument to ensure the 25% stretch.

The 5cm length of tape was found to be somewhat small and a longer piece is recommended for future use. The 25% stretch can still be maintained across the cleft area while the distal ends of the tape can be passively attached to the cheeks. The tape may also be sectioned so that a strip attaches to the septum and lateral nasal wall to reproduce the function of the transverse nasal muscle. This modification may elevate and align the collapsed nostril on the cleft side.

Parents and caregivers were pleased with the results and eager to comply with the treatment instructions. It was reassuring to witness, within the confines of the dental cubicle, the speed with which the tape was re-applied after examination of the patients at the three-week follow up visits.

Therefore, the findings from this case study of eight patients show that physio tape can be effectively used in lip tape therapy as an interim measure from birth to the time of cheiloplasty. Its advantage over previously used material and techniques are:

- It imitates muscle elasticity and function, which assists with feeding and facial expression.
- It encourages muscle development and muscle bulk.
- It is hypoallergenic and treatment is therefore not interrupted due to skin reactions.
- It dries easily, does not retain moisture and permits ventilation of the skin.
- It encourages tissue alignment and decreases the defect, facilitating surgery with less scarring and fewer complications.
- It renders emotional relief and support to the parents in that immediate and evident steps are taken to remedy the condition.

Table 3: Vermillion width of cleft (mm)

Patient	Before	After	Space closure
1	22.2	13.1	9.1
2	68.7	40.2	28.5
3	40.6	22.2	18.4
4	73.7	53.3	20.4
5	54.7	27.9	26.8
7	35.3	13.4	21.9
7	62.1	25.4	36.7
8	25.4	8.3	17.1
Average	47.84	25.48	22.36

- It can mask or embellish the defect, as the tape is available in different fashionable colours for selection by the caregivers.

Physio tape is produced by several manufacturers and marketed under different brand names. Their common attribute is that they are all non-toxic, hypo allergenic elastic tapes, readily obtainable at an affordable price.

CONCLUSION

As is evident from the findings of this study, lip tape therapy using physio tape can have a positive effect on the pre-surgical management of babies born with a cleft lip. Although the procedure cannot of course completely resolve the defect, nevertheless, use of the tape over the period from birth to the date for cheiloplasty will minimise the surgical procedure and subsequent scarring. In on-going and future studies it may be instructive to observe and to document any changes in alveolar and maxillary alignment of those patients presenting an associated cleft palate.

Use of the tape is not limited and can include medical conditions where tissue approximation and muscle development is needed. In patients with hemifacial microsomia, for example, physio tape may be applied to stimulate development of the weaker side.

It would appear that this novel method of lip tape therapy is cost effective and efficient and could, with benefit, be followed in all babies born with a cleft lip.

The authors wish to extend their sincere gratitude and appreciation to Prof. K-W Bütow for his support and for granting us unrestricted and continued access to the Facial Cleft Deformity Clinic.

Declaration: No conflict of interest declared.

References

1. Precious DS, Goodday RH, Morrison AD, Davis BR. Cleft lip and palate: a review for dentists. *J.Can.Dent.Assoc.* 2001;67(11):668-73.
2. Shah CP, Wong D. Management of children with cleft lip and palate. *Can.Med.Assoc.J.* 1980 12;122(1):19-24.
3. Butow KW. Treatment of cleft lip and palate. Part III: Surgical techniques and discussion, different phases from birth to adulthood. *J.Dent.Assoc.S.Afr.* 1984;39(6):395-400.
4. Wilhelmsen HR, Musgrave RH. Complications of cleft lip surgery. *Cleft Palate J.* 1966;3:223-31.



5. Lees VC, Pigott RW. Early postoperative complications in primary cleft lip and palate surgery--how soon may we discharge patients from hospital? *Br.J.Plast.Surg.* 1992;45(3):232-4.
6. Tollefson TT, Gere RR. Presurgical cleft lip management: nasal alveolar molding. *Facial Plast.Surg.* 2007;23(2):113-22.
7. Grayson BH, Shetye PR. Presurgical naso-alveolar moulding treatment in cleft lip and palate patients. *Indian J.Plast.Surg.* 2009;42 Suppl:S56-61.
8. Choo H, Maguire M, Low DW. Modified technique of presurgical infant maxillary orthopedics for complete unilateral cleft lip and palate. *Plast.Reconstr.Surg.* 2012;129(1):249-52.
9. Pool R, Farnworth TK. Preoperative lip taping in the cleft lip. *Ann. Plast.Surg.* 1994;32(3):243-9.
10. Levy-Bercowski D, Abreu A, DeLeon E, Looney S, Stockstill J, Weiler M, *et al.* Complications and solutions in presurgical nasoalveolar molding therapy. *Cleft Palate.Craniofac.J.* 2009;46(5):521-8.
11. Presurgical Orthopedic Therapy for Cleft Lip and Palate Available at: <http://emedicine.medscape.com/article/2036547-overview>. Accessed 5/22/2013, 2013.
12. What is Physio Tape? | Vitality Medical Blog Available at: <http://vitalitymedical.wordpress.com/2010/05/28/what-is-physio-tape/>. Accessed 7/22/2013, 2013.
13. Physio Tape Benefits and Usage | Physio Tape Article | Physio and sports tape, St Albans, Harley Street, Moorgate, London - Perfect Balance Clinic - Perfect Balance Clinic Available at: <http://www.perfectbalanceclinic.com/News/Physio-Tape---Kinesio-Tape-only-for-sports-injurie.aspx>. Accessed 7/22/2013, 2013.
14. Leukotape® P Available at: <http://www.bsnmedical.no/en/products/alphabetical-product-search/l/leukotaper-p.html>. Accessed 7/22/2013, 2013.
15. Operation Smile South Africa - About Us - Quick Facts Available at: <http://southafrica.operationssmile.org/aboutus/facts/>. Accessed 7/30/2013, 2013.
16. Thornton JB, Nimer S, Howard PS. The incidence, classification, etiology, and embryology of oral clefts. *Semin.Orthod.* 1996;2(3):162-8.
17. Cleft palate facts, information, pictures | Encyclopedia.com articles about cleft palate Available at: http://www.encyclopedia.com/topic/cleft_palate.aspx. Accessed 5/22/2013, 2013.