

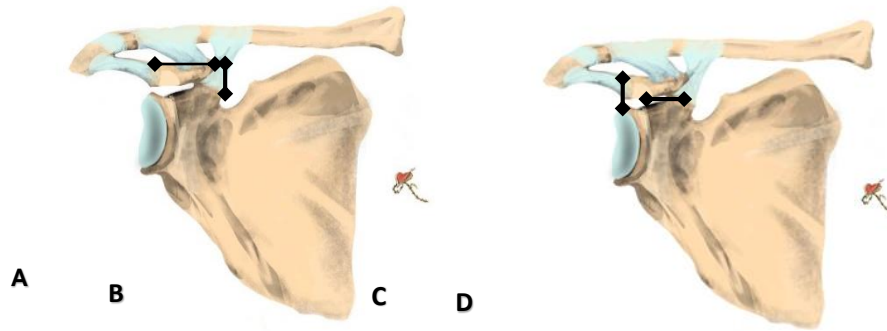**Figure 2.4:** Coracoid process measurements: (A) coracoid length from base to tip, (B) coracoid height at the base, (C) coracoid height superior-inferior, (D) coracoid base thickness medial-lateral.

As reported by Rios *et al.* (2009), the mean coracoid length is around  $45\text{mm} \pm 4.1\text{mm}$ , with a mean width and height of  $24.9\text{mm} \pm 2.5\text{mm}$  and  $11.9\text{mm} \pm 1.8\text{mm}$ , respectively. However, the mean coracoid length and width ranges from 43 to 45mm and 14 and 27.9mm, respectively (Salzmann *et al.*, 2008; Coale *et al.*, 2013; Dolan *et al.*, 2011), with significantly larger measurements in males than females (Salzmann *et al.*, 2008).

The attachments of the CC ligaments on the superior aspect of the coracoid process are broad. The dorsal proximal half and the entire lateral body of the coracoid process are covered by the trapezoid ligament (Harris *et al.*, 2001; Takase, 2010; Saccomonna *et al.*, 2014). The conoid ligament is positioned more along the base of the coracoid process; however, it is limited anteriorly by the trapezoid insertion (Harris *et al.*, 2001; Saccomonna *et al.*, 2014). Other structures attached to the coracoid process include the coracoacromial and coracohumeral ligaments, the short head of the biceps brachii muscle, the coracobrachialis muscle, and the pectoralis minor muscle.

The AC joint muscular fascial tissues contribute to the AC joint anatomy and function. The deltoid, trapezium and pectoralis major muscles attach to the clavicle near the AC joint. The

musculotendinous aponeurosis of the deltotrapezial fascia interdigitates with the superior AC ligaments fibres; activity in these fascial muscles affects the biomechanics of the AC joint (Sellards, 2004). Both the deltoid and trapezius muscles function as dynamic stabilizers of the AC joint (Sellards, 2004). The AC joint innervation is derived from the supraclavicular, suprascapular, lateral pectoral, and axillary nerves, while the blood supply is derived from the suprascapular artery together with the branches of the thoracoacromial artery (Moore *et al.*, 2013).

## 2.2 Biomechanics of the AC joint

The stability of the AC joint depends on the CC ligaments and AC joint capsule. This capsuloligamentous complex is essential for horizontal and vertical translation of the clavicle on the acromion (Chernchujit and Artha, 2020).

The AC joint allows for rotation between the clavicle and acromion during shoulder movements (DePalma, 1963; Sahara *et al.*, 2006; Radhakrishnan and Henderson, 2019). During shoulder abduction, there is a 3.5mm anteroposterior and 1mm superior translation of the clavicle at the AC joint (Sahara *et al.*, 2006) and the clavicle rotates approximately  $40^{\circ}$  to  $50^{\circ}$  during full abduction (Rockwood, 1994; Ludewig *et al.*, 2004, Dyrna *et al.*, 2018). This clavicular motion is combined with scapular rotation, resulting in only  $7-9^{\circ}$  of the rotation occurring at the AC joint (Rockwood, 1994; Kim *et al.*, 2014). The AC joint capsule's integrity and CC ligaments contribute to the clavicle's strut function for guiding the scapula's rotation (Dyrna *et al.*, 2018).

The nature of the attachment of the CC ligaments also provides a mechanism capable of producing outward rotation of the scapula during shoulder movements. According to DePalma, during abduction of the arm, as the scapula rotates, the coracoid process is displaced downwards (DePalma, 1963; Dumonski *et al.*, 2004). The CC ligaments facilitate clavicular

rotation in its longitudinal axis due to their attachment to the posterior curvature of the bone. Without the S-shape of the clavicle, abduction of the arm would be restricted.

The vertical and horizontal stability of the AC joint is maintained by the integrity of the static and dynamic stabilizers (Fukuda *et al.*, 1986; Johansen *et al.*, 2011; Li *et al.*, 2014). Static stabilizers include the AC ligaments (superior, inferior, anterior, and posterior) and the CC ligaments (conoid and trapezoid), with rotational stability of the distal clavicle influenced by the superior AC ligaments specifically (Mazzocca *et al.*, 2007; Johansen *et al.*, 2011).

A biomechanical study by Debski *et al.* (2001) demonstrated the importance of the AC ligaments in stabilizing the AC joint in the horizontal plane. The authors concluded that, following AC capsule transection, there is a significant increase in the forces acting on the CC ligaments during anterior-posterior directed loads (Debski *et al.*, 2001). Furthermore, during CC ligament reconstruction, augmentation of the AC capsule has been shown to improve horizontal stability (Jordan *et al.*, 2019; Schar *et al.*, 2019).

The static stabilizers, i.e., the CC ligaments, function more like the vertical stabiliser to the AC joint by providing resistance against superior and inferior displacement (Fukuda *et al.*, 1986). However, studies have shown that these ligaments also play an important role in limiting displacement in the horizontal plane (Lee *et al.*, 2003; Lee *et al.*, 2021). Due to the distinct orientation of the conoid and trapezoid ligaments, they each function on their own and collectively across the joint, and some researchers have suggested that both sets of ligaments (AC and CC ligaments) should be reconstructed surgically for better biomechanical functional results (Fukuda *et al.*, 1986; Lee *et al.*, 2003).

Studies with intact AC ligaments have shown that the conoid ligament acts as the primary restraint against superior displacement while the trapezoid acts to resist compression across the AC joint (Fukuda *et al.*, 1986; Debski *et al.*, 2001; Mazzocca *et al.*, 2007). The conoid ligament

contributes significantly to the anterior and superior rotation with anterior and superior displacement of the clavicle on the acromion during shoulder movement, whereas the trapezoid ligament contributes more towards the stability in the horizontal and vertical directions when there is axial loading of the clavicle on the acromion (Fukuda *et al.*, 1986; Mazzocca *et al.*, 2007).

Structural properties of the CC ligaments have been evaluated in several studies, and the ultimate strength of native CC ligaments has been found to vary between 500-725 N. (Harris *et al.*, 2000; Motamedi *et al.*, 2000; Costic *et al.*, 2004; Grutter and Petersen, 2005; Lee *et al.*, 2008). Furthermore, biomechanical studies demonstrated that the most common type of failure of the CC ligaments is a mid-substance tear (Harris *et al.*, 2000; Motamedi *et al.*, 2000).

Dynamic stabilizers include the deltoid, serratus anterior and trapezius muscles. The trapezius and serratus anterior muscles collectively function as a force couple to stabilize the AC joint. The AC capsular ligaments blend with the trapezius and deltoid fascia; this provides more stability during the contraction of the muscles (Mazzocca *et al.*, 2007). At 90 and 120 degrees of shoulder abduction, there is an anterior and posterior translation of the lateral clavicle at the AC joint, respectively (Sahara *et al.*, 2006). The difference in the traction force of the deltoid and the superior trapezius muscles is responsible for the disparity in translation at 90 and 120 degrees. Sahara *et al.* (2006) showed that, at lower degrees of shoulder abduction, the anterior part of the deltoid muscle traction force is smaller than the posterior component of the trapezius muscle, resulting in the clavicle translating anteriorly. The translation forces are reversed at maximum shoulder abduction. This highlights the significant roles of the static and dynamic stabilizers in the overall stability of the AC joint.

Mazzocca *et al.* (2006) evaluated load-to-failure of three AC joint reconstruction techniques: the modified Weaver-Dunn, the anatomical coracoclavicular ligament reconstruction (ACCR)

and the arthroscopic assisted reconstruction methods. The authors found no significant difference in the load-to-failure between the native ligaments and the tested reconstructions (Mazzocca *et al.*, 2006). Several researchers have reported the importance of AC joint horizontal stability after reconstruction procedures (Gonzalez-Lomas *et al.*, 2010; Michlitsch *et al.*, 2010; Beitzel *et al.*, 2012; Saier *et al.*, 2015). Saier *et al.* (2015) demonstrated superiority in horizontal plane stability if reconstruction of both the CC ligament and AC capsule is performed, following anatomical reconstruction of the CC ligament and AC joint with suture tape. During AC joint reconstruction, to achieve biomechanical stability, both the horizontal and vertical plane stability must be considered (Saier *et al.*, 2015).

### 2.3 Acromioclavicular joint injuries

Injuries to the AC joint represent 9-12% of all acute shoulder injuries (Fraser-Modie *et al.*, 2008; Kim *et al.*, 2014); with a higher incidence in males than females (5:1) (Modi *et al.*, 2013). Individuals participating in contact sports are also at increased risk (Fraser-Modie *et al.*, 2008; Li *et al.*, 2014; Boffano *et al.*, 2017; Gowd *et al.*, 2018; Nordin *et al.*, 2020). However, the true incidence in the general population is unknown, and it's thought to be underestimated due to few individuals seeking treatment (Li *et al.*, 2014). Most patients have a low-grade injury that can be managed non-operatively (Modi *et al.*, 2013). High-grade injuries of the AC joint lead to disruption of the CC ligaments.

AC joint injuries occur due to direct or indirect mechanisms (Stucken and Cohen, 2015). A direct mechanism is secondary to a force onto the acromion and often occurs when an individual falls directly on the superior-lateral aspect of the shoulder (Figure 2.5).



**Figure 2.5:** Acromioclavicular joint direct mechanism of injury. Fall onto the superior aspect of the acromioclavicular joint.

There is a typical sequence of ligament failure during a fall onto the shoulder when the acromion is driven inferior-medially in relation to the distal clavicle (Nordin *et al.*, 2020). The AC ligaments are disrupted, followed by the CC ligaments and then the deltotrapezial fascia (Tauber *et al.*, 2010; Johansen *et al.*, 2011). Indirect mechanisms occur during a fall with an adducted arm onto the elbow/outstretched hand with a superior directed force, humeral head impacting the acromion leading to AC ligament and CC ligament disruption (Johansen *et al.*, 2011; Lee and Bedi, 2016).

The presenting complaint and mechanism of injury are important aspects and should be extracted from the history of injury (Mazzacco *et al.*, 2007). Individuals with a history of shoulder trauma and complaining of pain in the AC region must be evaluated for an AC joint dislocation. During the examination, the arm should be free and not supported; the deformity will be more pronounced due to the gravity and weight of the arm (Simovitch *et al.*, 2009).

The deformity observed in unreduced dislocations of the AC joint is maintained by the pull of the trapezius muscle on the distal end of the clavicle as well as by gravity and the absence of

any counterforce of the aponeurosis of the anterior portion of the deltoid (Wright *et al.*, 2011). Swelling, abrasions or ecchymosis should be documented if present on the affected joint. During loading of the affected side, the scapula and acromion process is drawn downward and forward, causing the joint gap to be increased both in anteroposterior and superior-inferior directions (Wright *et al.*, 2011).

The cross-body adduction test loads the AC joint, and these can be performed to accentuate pain from the joint. The arm is elevated to 90 degrees and then adducted across the chest with the elbow bent at 90 degrees. This causes a compression force across the AC joint, leading to pain (Mazzacco *et al.*, 2007). The sternoclavicular joint should also be assessed for associated injuries, especially in posterior dislocation of the distal clavicle, as there may be a concomitant anterior dislocation of the sternoclavicular joint (Li *et al.*, 2014).

Currently, radiographs are the imaging modality of choice in investigating AC joint injuries. The Zanca view has been described to evaluate the AC joint accurately. It is an AP view with the X-ray beam tilted 10-15 degrees cephalad with 50% of exposure strength required for standard shoulder X-ray (Zanca, 1971; Stucken and Cohen, 2015). Tilting the beam allows for visualisation of the AC joint as the scapula is moved away from the field (Stucken and Cohen, 2015). Vertical displacement of the lateral clavicle will be seen on anteroposterior views. The average distance between the inferior aspect of the clavicle and the coracoid process ranges between 11-13mm in a relaxed standing position (Simovitch *et al.*, 2009; Radhakrishnan and Henderson, 2019). An increase in 25-50% coracoclavicular distance indicates a complete coracoclavicular ligament disruption (Bearden, 1973). The axillary view is ideal for assessing a posterior dislocation of the clavicle on the acromion (Johansen *et al.*, 2011). There are no universal guidelines regarding the patient's position during axillary view imaging (Tauber *et al.*, 2010). Stress views are not routinely performed, mainly due to the unnecessary pain they

inflict in acute injuries. Still, they may help decide whether surgical treatment is indicated in high-risk patients with Type III injuries (Cook and Krul, 2013).

The original classifications of AC joint injuries were described by Cadenant (1917), Tossy et al. (1963) and Allman (1967). Currently, the most widely used classification is by Rockwood and is based on the original work by Tossy. The Rockwood (1998) classification is based on the extent of disruption of AC and CC ligaments, as evidenced by the degree of displacement on radiographs. The different grades are based on the integrity of the AC ligaments, CC ligaments and deltatrapezial fascia (Table 2.1).

Type I is a sprain on the AC ligaments, while the CC ligaments and deltatrapezial fascia are intact. The radiographs are normal. In type II, the AC ligaments are torn and there is a CC ligament sprain. The deltatrapezial fascia is intact. The radiographs are normal, or there is <25% displacement. In type III, both the CC and AC ligaments are torn. The deltatrapezial fascia is intact and there is a 25-100% increase in the coracoclavicular space on X-ray compared to the contralateral side. In type IV, the CC and AC ligaments are torn, and there is a posterior displacement of the distal end of the clavicle. Axillary views are mandatory to make a diagnosis. It is essential to assess the sternoclavicular joint for anterior dislocation. In type V, the CC and AC ligaments are torn with a severe displacement of the lateral clavicle, indicating loss of soft tissue attachments on the distal 3<sup>rd</sup> of the bone. The deltatrapezial fascia is torn. Radiographs show >300% displacement of the coracoid-clavicular space. In type VI, the lateral clavicle is displaced in the sub-acromial/sub-coracoid region.

**Table 2.1:** The Rockwood Classification of acromioclavicular joint dislocation. AC- acromioclavicular, CC- coracoclavicular.

<b>TYPE</b>	<b>AC LIGAMENTS</b>	<b>CC LIGAMENTS</b>	<b>DELTOPECTORAL FASCIA</b>	<b>X-RAY CC DISTANCE</b>
<b>I</b>	<i>Sprained</i>	<i>Intact</i>	<i>Intact</i>	<i>Normal</i>
<b>II</b>	<i>Torn</i>	<i>Intact</i>	<i>Intact</i>	<i>&lt;25%</i>
<b>III</b>	<i>Torn</i>	<i>Torn</i>	<i>Intact</i>	<i>25-100%</i>
<b>IV</b>	<i>Torn</i>	<i>Torn</i>	<i>Torn</i>	<i>Increased</i>
<b>V</b>	<i>Torn</i>	<i>Torn</i>	<i>Torn</i>	<i>100-300%</i>
<b>VI</b>	<i>Torn</i>	<i>Torn</i>	<i>Torn</i>	<i>Decreased</i>

Non-operative treatment is indicated for individuals with Rockwood Type I, II and in some cases, Type III AC joint injuries. Multiple immobilisation devices are described, including adhesive devices, tape strapping, arm sling, braces, harness, traction, and plaster cast (Beitzel *et al.*, 2013). The generally accepted initial treatment involves using a sling and anti-inflammatories for pain relief. The sling is continued for one and two weeks for type I and II AC joint injuries, respectively (Johansen *et al.*, 2011). When the pain subsides, physical therapy is commenced. However, controversy exists concerning the sequelae of non-operative treatment (Mouhsine *et al.*, 2003; Mikek, 2008; Verstift *et al.*, 2021). The activity demand of an individual plays a significant role in the success of conservative treatment (Ma *et al.*, 2015). Gumani *et al.* (2009) stated that scapulothoracic dyskinesia occurs in 70% of patients with chronic Type III AC dislocation. Post-traumatic arthritis and distal clavicle osteolysis are recognised complications following non-operative treatment (Ma *et al.*, 2015). The key to the success of non-operative treatment is compliance with a rehabilitation programme. Rehabilitation that focuses on strengthening the shoulder girdle muscles is vital to the success of non-surgical treatment (Simovitch *et al.*, 2009).

Dislocated AC joints lead to abnormal joint kinematics and load transmission; this predisposes to pain, instability, and early degenerative joint disease. Surgical treatment aims to reduce the AC joint and allow healing of the CC ligaments and AC ligaments. The current trend to repair the CC ligaments and AC ligaments are based on biomechanical studies that emphasise the importance of anatomical repair to offer stability (Gonzalesz-Lomas *et al.*, 2010; Saier *et al.*, 2015; Struhl *et al.*, 2015; Dyrna *et al.*, 2018; Morikawa *et al.*, 2019).

The literature is abundant on surgical procedures for treating AC joint dislocations (Gowd *et al.*, 2018; Chernchujit *et al.*, 2020). However, there is no consensus on which method is the “gold standard” to attain long-term reduction. The procedures can be grouped into anatomical and non-anatomical, ligament repair or reconstruction, and they can be done by open technique or arthroscopic-assisted surgery. A recent meta-analysis has shown no difference with open or arthroscopic AC joint repair/reconstruction in terms of loss of reduction, overall complication, and revision rates (Gowd *et al.*, 2019). Another meta-analysis also reported no difference between open versus arthroscopic AC joint resection (Hohmann *et al.*, 2019). Reported complications following surgical treatment include infection, coracoid and/or clavicular fracture and implant failure (Bofano *et al.*, 2017; Chernchujit and Artha, 2020).

Kibler *et al.* described that surgical techniques and fixation devices could be categorised into three main groups (Kibler *et al.*, 2017). Firstly, the use of metal or non-biological material to stabilize the joint while allowing the healing of damaged ligaments. The second group uses biological material to reconstruct the CC ligaments and reduce the joint. The third group uses biological material to repair and reconstruct the CC ligaments and the AC ligament, also referred to as anatomical acromioclavicular reconstruction [AACR] (Mazzocca *et al.*, 2007).

*Use of metal/non-biological material:*

Surgical treatment of AC joint dislocations using PDS-braided suture, suture anchor, suture button, polyester prosthetic ligament and hook plates has been described (Windhamre *et al.*, 2010). This treatment method allows for the damaged ligaments to heal with the AC joint in a reduced position. The non-biological materials are commonly used together with the Weaver and Dunn procedure. Long-term follow-up studies have shown that the Weaver and Dunn procedure tends to have a loss of reduction (Kibler *et al.*, 2017)

*Use of biological material to repair and reconstruct both the CC ligaments and the AC ligament:*

The biological material commonly used is the semitendinosus graft (Tauber *et al.*, 2009; Yoo *et al.*, 2010). Other biological grafting options described include the free gracilis and toe extensor tendons (Lee *et al.*, 1997). This surgical treatment method aims to recreate the native anatomy of the AC joint, and studies have shown that it results in the most biomechanically stable construct (Beitzel *et al.*, 2014; Braun *et al.*, 2014; Kibler *et al.*, 2017). The surgical technique described by Carofina and co-workers is known as the Anatomical Coracoclavicular Ligament Reconstruction (ACCR) (Carofina *et al.*, 2010). During ACCR, the clavicular bone tunnels are prepared in the anatomical locations of the CC ligaments' landmarks. An auto/allograft of the semitendinosus tendon is passed through the tunnel and looped underneath the coracoid process. Following the reduction of the AC joint, the graft is secured with an interference screw in the clavicular tunnels (Carofina *et al.*, 2010).

*Arthroscopic assisted technique:*

Arthroscopic assisted AC joint fixation can perform diagnostic arthroscopy and check for associated pathology. The procedure is performed with the patient in a beach chair position. The direct visualisation of the coracoid process reduces the risk of neurovascular structure

damage (Chernchujit and Artha, 2020). Following the diagnostic arthroscopy using a posterior portal, a more anterior-lateral portal visualises the coracoid process base (Flinkkila and Ihanainen, 2013). An incision is done on the superior aspect of the reduced AC joint, which is held temporarily with a K-wire through the acromion to the lateral aspect of the clavicle. A guidewire is passed through the clavicle into the coracoid process. A hole is drilled over the guidewire with a 4,5mm drill bit. A non-absorbable suture with titanium endo-buttons at both ends is passed through the clavicle and coracoid process holes. The endo-button is flipped under the coracoid process and a suture knot is secured over the endo-button on the superior aspect of the clavicle. Although a common and popular technique, the major disadvantage of arthroscopic assisted anatomical reconstruction is its steep learning curve (Stucken and Cohen, 2015).

Multiple rehabilitation protocols following AC joint reconstruction exist (Stucken and Cohen, 2015). These correlate with the high number of described surgical techniques in the literature. With the AC joint as a strut connecting the appendicular skeleton to the axial skeleton, gravity creates continuous stress on the CC and AC ligaments (Stucken and Cohen, 2015). Common in the rehabilitation protocols is a period of immobilization, accompanied by limited shoulder range of movement, then finalising with strengthening exercises. Most authors agree on 4-6 weeks of immobilisation in an arm-sling/brace (Mazzocca *et al.*, 2007; Landermann *et al.*, 2011; Beris *et al.*, 2013; Braun *et al.*, 2014). Alternatively, as Francesco *et al.* (2012) described, early mobilisation during the first week helps preserve the range of motion and muscle tone. Permitted shoulder movements below the shoulder level occur around week two post-operatively (Mazzocca *et al.*, 2007; Simovitch *et al.*, 2009; Johansen *et al.*, 2011). This includes activities of daily living and pendulum exercises (Windhamre *et al.*, 2010; Yoo *et al.*, 2011). Furthermore, return to sporting activities varies from 3-6 months (Landermann *et al.*, 2011; Yoo *et al.*, 2011; Braun *et al.*, 2014).

The AC joint is vital to upper limb function. AC joint injuries leading to instability have a devastating outcome on patients. With a myriad of techniques available, both open and arthroscopically, the need for biomechanical studies to guide treatment choice is of paramount importance. Current studies are limited on the effect of coracoid tunnel position on AC joint horizontal stability following repair/reconstruction.

## **Chapter 3 : MATERIALS AND METHODS**

The biomechanical properties of the coracoclavicular (CC) ligaments and predefined surgical suture techniques for CC ligaments repair were investigated through cadaveric dissection of fresh-frozen specimens and biomechanical testing.


### **3.1 Specimen Acquisition**

A total testing sample comprising 15 fresh shoulder specimens was procured from the National Tissue Bank under the auspices of the University of Pretoria. Ethics approval was obtained from the University of Pretoria Research Ethics Committee, Reference No. 83/2019. Specimens were included if originating from skeletally mature donors. Specimens were excluded if there was a presence of AC joint pathology and/or previous surgery. Before testing, all specimens were stored in the freezer (-5 degrees Celsius) and thawed at room temperature (22-23 degrees Celsius).

### **3.2 Specimen Preparation**

During dissection, the humerus was disarticulated, and all soft tissues were removed. Great care was taken to expose the CC and AC ligaments and to keep them intact. The clavicle length, coracoid process and CC ligaments were measured with a digital caliper calibrated and accurate to 0.01mm. A custom-made mounting jig was used to fixate the specimens onto the testing apparatus. The body of the scapula was potted with gypsum in an open rectangle metal box. The gypsum in the metal box was limited to the inferior part of the glenoid. This allowed the spine of the scapula, glenoid and coracoid process to project freely.

A 40mm polyvinyl chloride pipe (PVC) was filled with gypsum to secure the medial one-third of the clavicle. The long axis of the clavicle was centred within the PVC pipe, and the gypsum was allowed to harden over 24 hours before testing. Once the shoulder specimen had been assembled on the testing machine, all the testing was performed without altering the initial assembled position (Figure 3.1). To prevent desiccation during testing, each specimen was kept moist by regularly spraying with a normal saline solution.

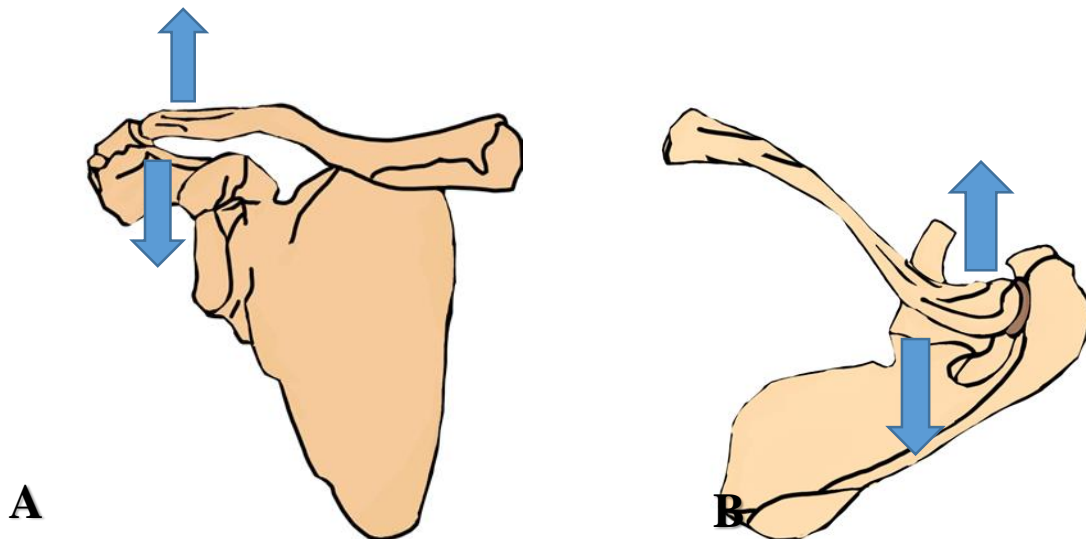


**Figure 3.1:** Specimen mounted on the Hydropuls® testing machine. Load cells (A), custom-made jig (B), gypsum-filled polyvinyl chloride pipe with the clavicle (C), gypsum-filled rectangle metal box with the scapula (D), motion tracking reference marker (E), bottom clamp (F).

### 3.2.1 Biomechanical testing

Biomechanical testing was performed using a 100kN Hydropuls® Universal Testing Machine. Custom-made clamps were used to rigidly mount the specimens on the Hydropuls® machine (Figure 3.1). The clamps allowed various positional settings to secure the specimen on the testing machine. The AC joint orientation was physically checked to be reduced in the vertical

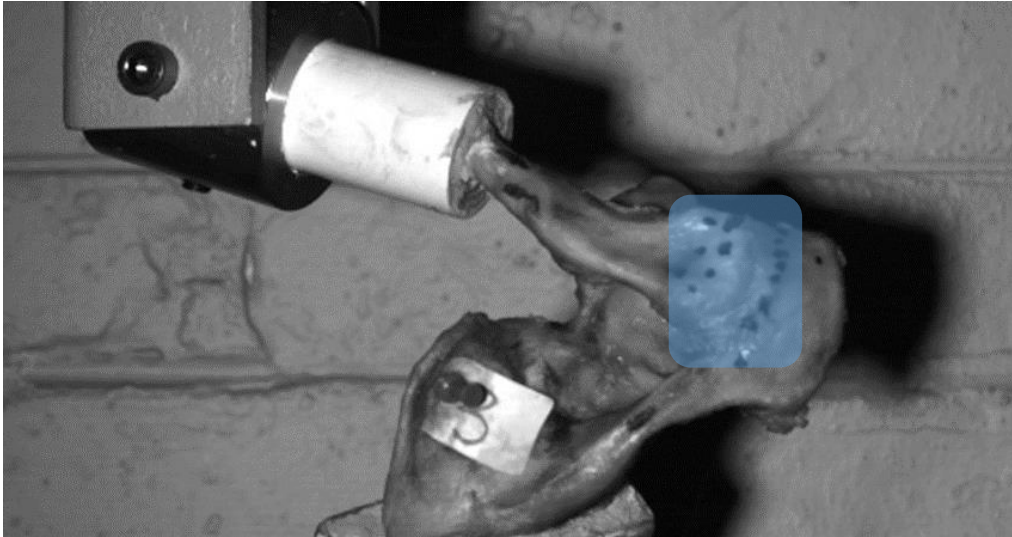
and horizontal planes (Figure 3.2). This position allowed the AC joint horizontal plane to be aligned with the vertical pull of the Hydropuls® testing machine. The custom-made clamps permitted five rotational degrees of freedom (top clamp two and bottom clamp three) and allowed the reduced AC joint specimen's superior surface to be parallel with the Hydropuls® vertical line of pull.



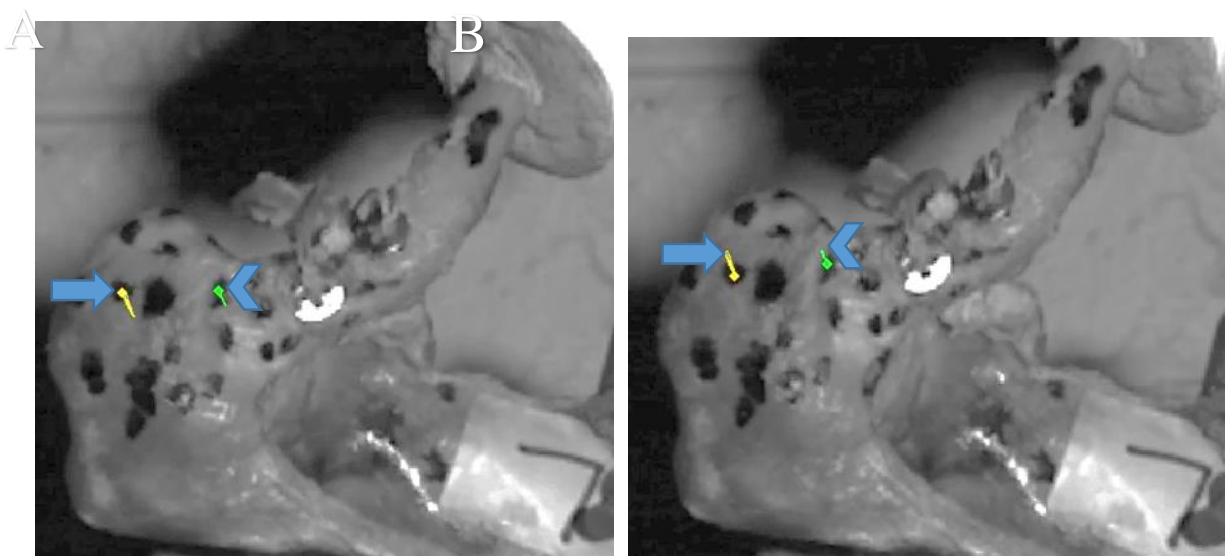
**Figure 3.2:** Illustration of the anterior view of the right shoulder with arrows demonstrating vertical plane directions of the acromioclavicular joint (A). Axial view of the right shoulder with arrows demonstrating horizontal plane directions of the acromioclavicular joint (B).

Following load cell calibration, the specimens were loaded on the Hydropuls® machine. All the specimens were subjected to displacement-controlled loading at a constant rate of 25mm/min with maximum displacement set at 6.25mm. The specimens were loaded at 25mm/min for 15 seconds, and then the clavicle displacement on the acromion was measured. An alcohol-based ink with a rubber dropper was used to create random patterns on either side of the AC joint surface (Figure 3.3). The completed pattern met the requirements described in the literature to serve as tracing markers (Crammond *et al.*, 2013). An IDT NX8-S2 camera was used to capture images of the lateral third of the clavicle on the AC joint during testing.

2D motion analysis was performed on the captured images using the TEMA motion analysis software (Figure 3.4). This method gives the advantage of analysing the AC joint displacement without altering the mechanical properties of the specimens. Calibration of the camera was performed on the day of testing.



**Figure 3.3:** The shaded region around the acromioclavicular joint demonstrates the tracking markers. The tracking markers were created with an alcohol-based ink rubber stopper.



**Figure 3.4:** Image captured on NX8-S2 camera, demonstrating tracking of makers at 0 seconds (A) and tracking at 15 seconds (B). The acromion marker (arrow) and the clavicle marker arrowhead). During testing the scapula is pulled inferiorly relative to the clavicle. The measured line of the acromion marker indicates the displacement of the acromion.

**a. Test-1, testing for a baseline of the AC joint horizontal (anterior) stability with intact CC ligaments:**

Each specimen was mounted on the Hydropuls® testing machine using the jig and clamps. The AC joint was reduced in horizontal and vertical planes before loading the Hydropuls® machine. The specimen was subjected to the load described above.


**b. Test-2, testing for a baseline of the AC joint horizontal (anterior) stability with disrupted CC ligaments:**

A surgical blade was used to sharply transect at the mid-substance of the conoid and trapezoid ligaments, after specimen testing with CC ligaments intact. A displacement-controlled load of 25mm/min for 6.25mm was applied to the loaded specimen with the AC joint in a reduced position.

**c. Test-3, AC joint horizontal stability test following a 4cm single transclavicular and transcoracoid tunnel reconstruction at the coracoid base (ST-0).**

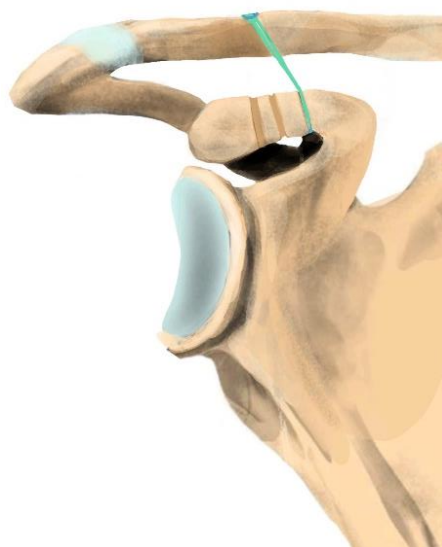
The specimen with the transected conoid and trapezoid ligaments underwent reconstruction of the CC ligaments while mounted on the testing machine. A single transclavicular tunnel centrally placed at 4cm medial to the AC joint was created with a 2mm K-wire. A 4mm cannulated drill bit was used to over drill the K-wire. A cortical fixation button device (TightRope, Arthrex, Naples, FL, USA) containing four strands of No. 5 fibre suture with a titanium button and a washer on each end was used to repair the transected conoid ligament (Figure 3.5). The length of the coracoid process was used to locate the tunnel's position. The initial tunnel in the coracoid process was located on its base (Figure 3.6). A 2mm K-wire was

passed through the base of the coracoid process. The coracoid tunnel hole was created using a 4mm cannulated drill bit to drill over the K-wire.



**Figure 3.5:** Coracoclavicular suspension device containing No. 5 fibre suture with titanium button on the right and washer on the left (A). The titanium button end of the cortical fixation button device passed from the superior aspect of the clavicle through the coracoid process tunnel, with the titanium button flipped and orientated transverse to the long axis of the coracoid process (B).

The AC joint reduction was confirmed before securing the cortical fixation button device with four knots on the superior aspect of the clavicle over the washer.

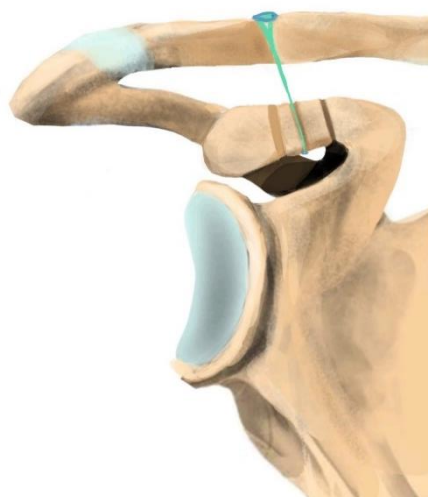


**Figure 3.6:** The titanium button end of the cortical fixation button device was passed from the superior aspect of the clavicle through the coracoid process tunnel towards its position at the base of the coracoid process.

**d. Test-4, testing reconstruction technique for a 4cm single trans-clavicular and transcoracoid tunnel at 1:9 from the coracoid base (ST-9):**

The length of the coracoid process was used to locate the position of the tunnel on the specimen loaded in the Hydropuls® machine. The second bone tunnel in the coracoid process was 1:9th from the base (Figure 3.7). A 2mm K-wire was drilled through and a 4mm cannulated drill bit was used to over drill the K-wire. A single transclavicular hole was reated at 4cm medial to the AC joint on the clavicle with a 2mm K-wire. A 4mm cannulated drill bit was used to over drill the K-wire.

A cortical fixation button device containing four strands of No. 5 fibre wire with a titanium button and a washer on opposite ends was used for the reconstruction. Only the conoid ligament part of the transected CC ligaments was reconstructed. The titanium button end of the cortical fixation button was passed from the superior aspect of the clavicle through the coracoid process tunnel. The titanium button was then flipped and orientated transverse to the long axis of the coracoid process. AC joint reduction was confirmed before securing the cortical fixation button with four knots on the superior aspect of the clavicle over the washer.

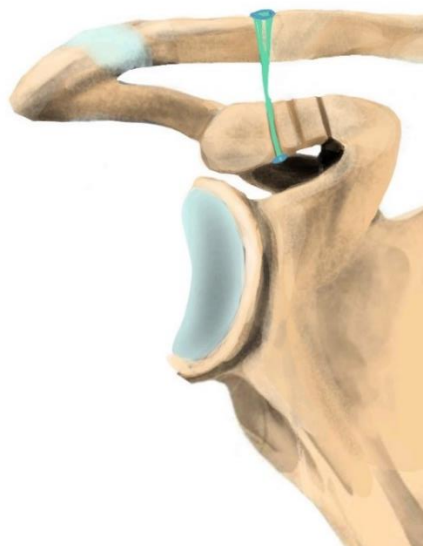


**Figure 3.7:** The titanium button end of the cortical fixation button was passed from the superior aspect of the clavicle through the coracoid process tunnel. The coracoid process tunnel position at 1:9 from the base with the suspension device secured in place.

**e. Test-5, testing reconstruction technique for a 4cm single trans-clavicular and transcoracoid tunnel at 1:5 from the coracoid base (ST-5):**

The length of the coracoid process was used to locate the position of the tunnel. The third bone tunnel in the coracoid process was 1:5 from the base (Figure 3.8). A 2mm K-wire was drilled through and a 4mm cannulated drill bit was used to over drill the K-wire. A single transclavicular hole was created at 4cm medial to the AC joint on the clavicle with a 2mm K-wire. A 4mm cannulated drill bit was used to over drill the K-wire.

A cortical fixation button device containing four strands of No. 5 fibre wire with a titanium button and a washer on opposite ends was used to repair the conoid ligament part of the transacted CC ligaments. The titanium button end of the cortical fixation button was passed from the superior aspect of the clavicle through the coracoid process. The titanium button was then flipped and orientated transverse to the long axis of the coracoid process. Before testing, the AC joint reduction was confirmed before securing the tight rope with four knots on the superior aspect of the clavicle over the washer.

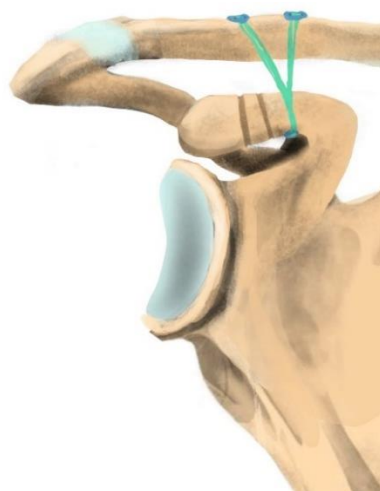


**Figure 3.8:** The titanium button end of the cortical fixation button was passed from the superior aspect of the clavicle through the coracoid process tunnel. The coracoid process tunnel position at 1:5 from the base with the suspension device secured in place.

**f. Test-6, testing reconstruction technique for the 2cm and 4cm double transclavicular and a transcoracoid tunnel at the base (DT-0):**

The length of the coracoid process was used to locate the position of the tunnel. The initial bone tunnel in the coracoid process was on the base (Figure 3.9). A 2mm K-wire was passed through the base of the coracoid process. The coracoid tunnel hole was created using a 4mm cannulated drill bit to drill over the K-wire. Double transclavicular holes were created at 2cm and 4cm medial to the AC joint on the clavicle with 2mm K-wires. A 4mm cannulated drill bit was used to over drill the K-wires.

Two cortical fixation button devices containing four strands of No. 5 fibre wire with a titanium button and a washer on opposite ends were used to independently repair the transacted, conoid and trapezoid ligaments. The titanium button ends of the cortical fixation button were passed individually from the superior aspect of clavicle tunnels through the coracoid process tunnel. The titanium button was then flipped and orientated transverse to the long axis of the coracoid process. AC joint reduction was confirmed before securing the cortical fixation button sequentially with four knots on the superior aspect of the clavicle over the washer.

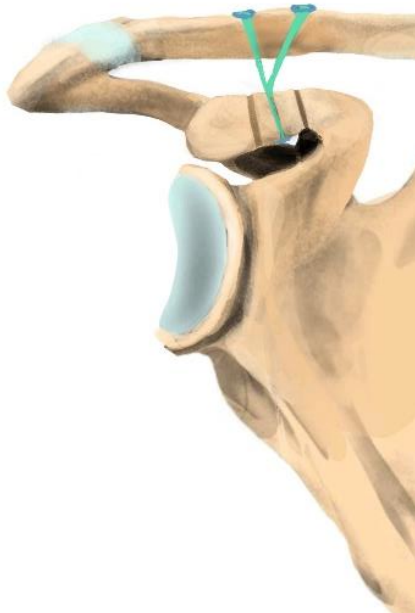


**Figure 3.9:** Two cortical fixation button devices containing four strands of No. 5 suture were inserted on the superior surface of the clavicle. The coracoid process tunnel position is located at the base with the two suspension devices secured in place.

**g. Test 7, testing reconstruction technique for the 2cm and 4cm double transclavicular and a transcoracoid tunnel at 1:9 from the base (DT-9):**

The length of the coracoid process was used to locate the position of the coracoid process tunnel. The second bone tunnel in the coracoid process was 1:9 from the base (Figure 3.10). A 2mm K-wire was passed through the tunnel. The coracoid tunnel hole was created using a 4mm cannulated drill bit to drill over the K-wire. Double transclavicular holes were created at 2cm and 4cm medial to the AC joint on the clavicle with 2mm K-wires. A 4mm cannulated drill bit was used to over drill the K-wires.

Two cortical fixation button devices containing four strands of No. 5 fibre wire with a titanium button and a washer on opposite ends were used to independently repair the transected conoid and trapezoid ligaments. The titanium button ends of the cortical fixation button device were passed individually from the superior aspect of clavicle tunnels through the coracoid process tunnel.



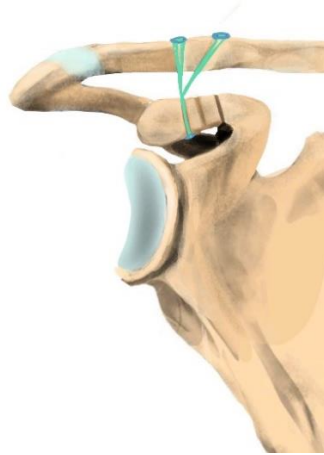
**Figure 3.10:** Two cortical fixation button devices containing four strands of No. 5 suture were inserted on the clavicle superior surface. The coracoid process tunnel position at 1:9 from the base with the two suspension devices secured in place.

The titanium buttons were then flipped and orientated transverse to the long axis of the coracoid process. AC joint reduction was confirmed before securing the cortical fixation buttons sequentially with four knots on the superior aspect of the clavicle over the washer.

**h. Test 8, testing reconstruction technique for the 2cm and 4cm double transclavicular and a transcoracoid tunnel at 1:5 from the base (DT-5):**

The length of the coracoid process was used to locate the position of the tunnel. The third bone tunnel in the coracoid process was 1:5 from the base (Figure 3.11). A 2mm K-wire was passed through 1:9 from the base of the coracoid process. The coracoid tunnel hole was created using a 4mm cannulated drill bit to drill over the K-wire. A double transclavicular holes placed at 2cm and 4cm medial to the AC joint centrally on the clavicle were created with 2mm K-wires. A 4mm cannulated drill bit was used to over drill the K-wires.

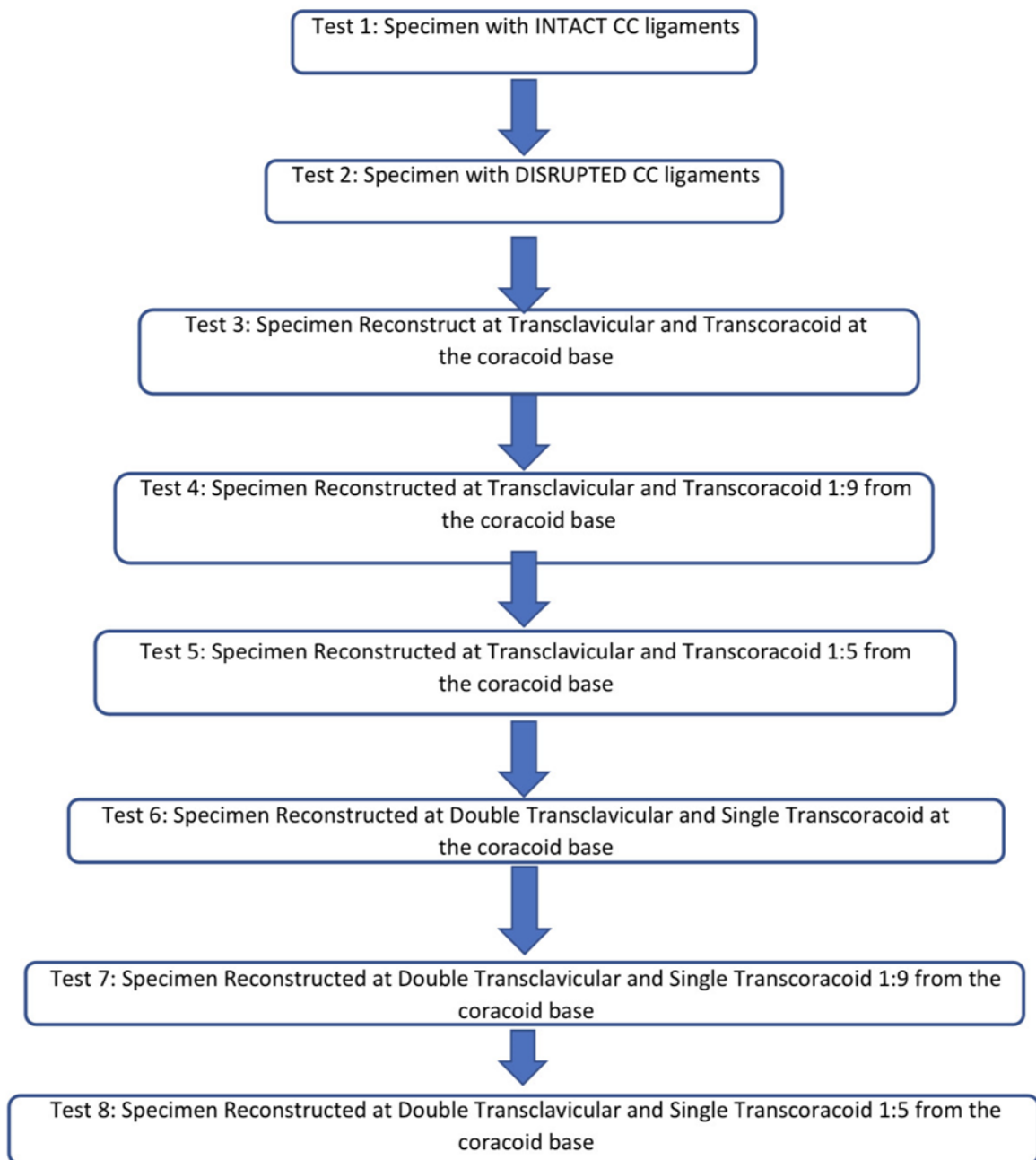
Two cortical fixation button devices containing four strands of No. 5 fibre wire with a titanium button and a washer on opposite ends were used to repair the transacted conoid and trapezoid ligaments independently. The titanium button ends of the cortical fixation buttons were passed individually from the superior aspect of clavicle tunnels through the coracoid process tunnel. The titanium button was then flipped and orientated transverse to the long axis of the coracoid process. AC joint reduction was confirmed before securing the cortical fixation buttons sequentially with four knots on the superior aspect of the clavicle over the washer.



**Figure 3.11:** Illustration of two cortical fixation button devices containing four strands of No. 5 suture were inserted on the clavicle superior surface. The coracoid process tunnel position at 1:5 from the base with the two suspension devices secured in place.

A Flow diagram demonstrating the total number of 15 shoulder specimens, sequentially tested on the Hydropuls® machine is provided (Figure 3.12). Following placing Specimen 1 on the Hydropuls® machine, Test 1 indicating intact CC ligaments was performed. For Test 2, Specimen 1 CC ligaments were transected, and machine loaded to test horizontal stability. While the specimen was on the Hydropuls® machine Tests 3 to 8 were consecutively performed.

Shoulder Specimens (n=15). Each specimen sequentially investigated from Test 1 to 8



**Figure 3.12:** Flow diagram demonstrating the total number (n=15) of shoulder specimens, sequentially tested on the Hydropuls® machine.

### 3.2.2 Statistics

Descriptive statistics were used to describe and summarize the collected data. If the data were normally distributed, means and standard deviations were calculated. If the data was not normally distributed, the median as a measure of central tendency and the range as a measure of variability was calculated. The Grubbs test to check for outliers was also used. 95% confidence intervals were calculated in all variables. Normal data distribution was analysed using the Shapiro-Wilks test. One-way ANOVA was used for multiple group comparisons. In the event of a significant main effect or interaction, post hoc comparisons (Tukeys HSD) were conducted using the least significant differences. A level of significance of  $p < 0.05$  was selected for all analyses. All analyses were conducted using STATA SE (Version 12.0; StataCorp, College Station, Texas, USA) for Windows.

## Chapter 4 : RESULTS

### 4.1 General

A total of fifteen shoulder specimens (n=15) met the inclusion criteria (8 right and 7 left). The sample comprised nine males and six females with an age range of 44-88 years. The sample consisted of white South African individuals. The longest clavicle length was 250 mm with an overall mean length of  $156 \pm 7.4$ mm. The mean length of the coracoid process hook was  $44 \pm 1.6$ mm. The conoid and trapezoid ligaments' footprint on the inferior aspect of the clavicle were  $44 \pm 1.5$ mm and  $27 \pm 1.3$ mm, respectively. The descriptive data of the specimens are detailed in Table 4.1 (Page 39).

**Table 4.1:** Anatomical description of the tested specimens. Measurement results in millimetres. (L- left, R- right, SD – standard deviation, CI – confidence interval)

Shoulder Anatomical side	Clavicle length	Coracoid process length	CC ligaments clavicular insertion points from the lateral aspect of the clavicle	
			Conoid	Trapezoid
L	250	48	40	24
L	140	46	47	22
L	152	47	50	39
L	170	54	42	30
L	136	30	43	24
L	155	38	50	33
L	146	41	35	22
R	149	44	41	32
R	142	41	40	22
R	173	50	52	23
R	148	42	43	30
R	135	39	41	26
R	138	46	43	27
R	169	53	58	28
R	141	38	42	22
<b>MEAN</b>	<b>156</b>	<b>44</b>	<b>44</b>	<b>27</b>
<b>SD</b>	<b>7.4</b>	<b>1.6</b>	<b>1.5</b>	<b>1.3</b>
<b>RANGE</b>	<b>115</b>	<b>24</b>	<b>23</b>	<b>17</b>
<b>95% CI</b>	<b>140-172</b>	<b>40-47</b>	<b>41-48</b>	<b>24-30</b>

## 4.2 Descriptive statistics

Descriptive statistics for Shoulder 1 to 15 during Tests 1 to 8 were calculated for the AC joint horizontal (anterior) displacement data and are presented in Table 4.2 (Page 40). The largest displacement recorded was 5.8mm. This was 0.5mm less than the maximum displacement set on the Hydropuls® machine.

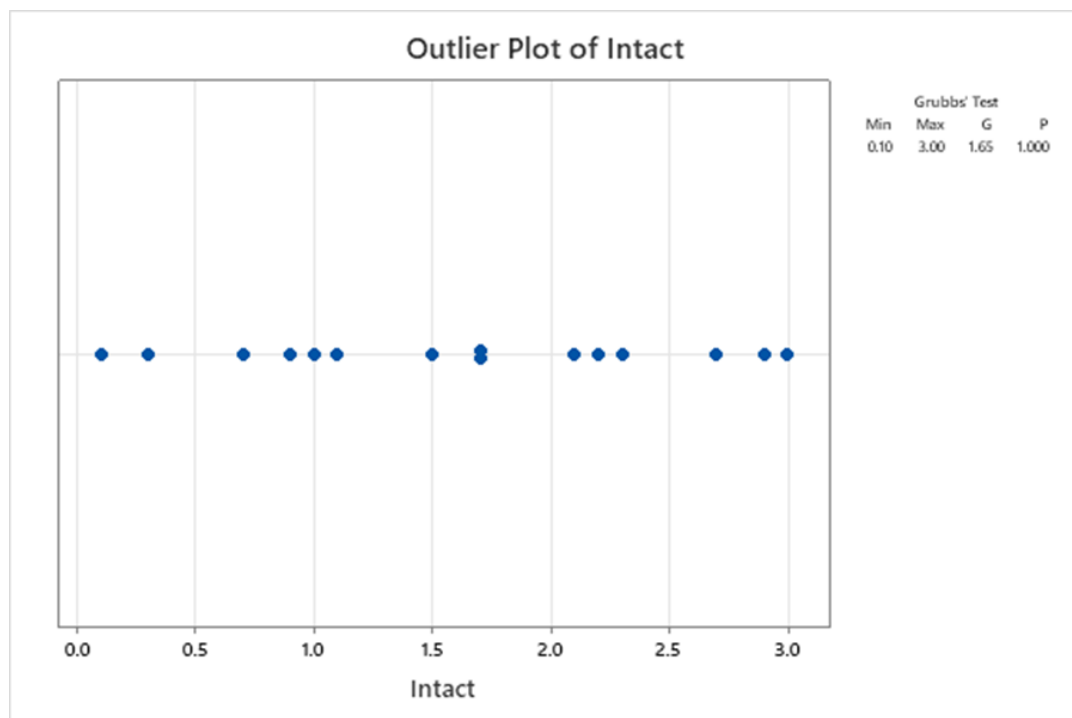
**Table 4.2:** Table showing the maximum horizontal displacement and descriptive statistics for individual Shoulders 1 to 15 during Tests 1 to 8. ST- single transclavicular tunnel. DT- double transclavicular tunnel. ST/DT0- coracoid tunnel at the base, ST/DT9- coracoid tunnel at one-ninth from the coracoid base and ST/DT5- coracoid tunnel at one-fifth from the coracoid base. All measurements in mm (millimetres) were recorded at 15 seconds of loading. (CC Lig- coracoclavicular ligaments).

AC joint Horizontal (anterior) Displacement in mm								
SHOULDER	TEST 1 CC Lig intact	TEST 2 Disrupted CC Lig	TEST 3 ST- 0	TEST 4 ST-9	TEST 5 ST-5	TEST 6 DT-0	TEST 7 DT-9	TEST 8 DT-5
1	2.7	3.5	2.1	2.2	1.9	0.8	1.5	1.1
2	3.0	3.7	3.3	3.8	4.1	1.6	3.2	3.1
3	2.1	2.5	1.3	1.7	0.9	1.0	1.7	1.4
4	1.0	3.0	1.0	0.9	1.4	0.2	0.4	0.1
5	0.1	3.6	0.6	1.9	1.6	0.2	0.8	0.7
6	1.7	3.0	1.5	3.5	3.1	0.6	1.9	1.2
7	1.1	3.8	2.3	1.5	2.1	1.8	1.4	1.9
8	0.3	4.0	2.3	2.6	2.8	1.3	1.1	1.0
9	2.2	5.8	0.7	4.8	4.6	0.4	4.9	4.6
10	2.9	4.5	1.9	2.4	2.5	1.8	1.8	2.0
11	0.9	4.1	2.6	3.3	4.2	2.3	3.0	2.9
12	1.7	5.2	2.1	3.7	3.6	2.0	3.6	3.3
13	0.7	1.4	1.1	0.8	0.9	0.8	0.7	0.7
14	2.3	4.5	2.5	2.8	2.8	2.2	2.5	2.4
15	1.5	2.8	2.7	2.2	2.8	1.8	1.9	1.8
MEAN	1.6	3.6	1.9	2.5	2.5	1.2	2.0	1.9
SD	0.9	1.1	0.8	1.1	1.1	0.7	1.2	1.2
Minimum	0.1	1.4	0.6	0.8	0.8	0.2	0.4	0.1
Maximum	3.0	5.8	3.3	4.8	4.5	2.3	4.9	4.6
RANGE	2.9	4.4	2.6	4.0	3.6	2.1	4.5	4.5
95% CI	1.1 – 2.1	3.0 – 4.3	1.4 – 2.3	1.9 – 3.2	1.9 – 3.1	0.8 – 1.6	1.4 – 2.7	1.2 – 2.5

The Shapiro-Wilks test revealed normal data distributions for all test conditions, and descriptive statistics were calculated using means and standard deviations. In addition to these variables, range and 95% confidence intervals were included for all measures. The Grubbs test did not demonstrate any outliers for all test conditions (Table 4.3, Page 41). No outliers were observed at the 5% significance level (Figure 4.1).

**Table 4.3:** Grubbs test results for outliers. No outliers were demonstrated for all test conditions.

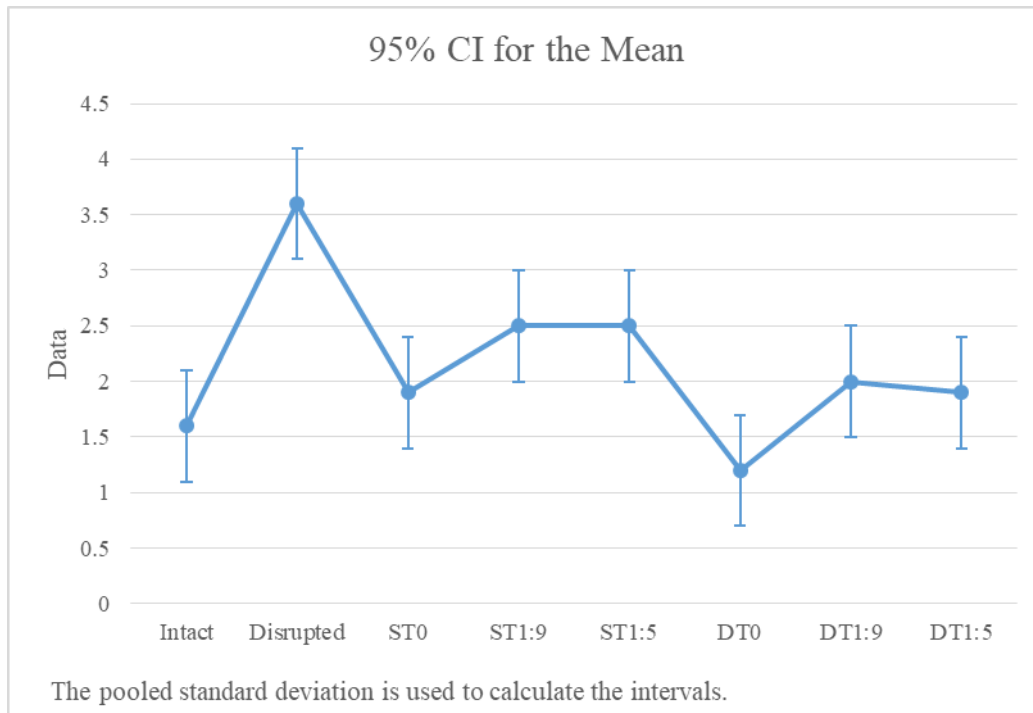
Variable	N	Mean	SD	Min	Max	G	P
Intact	15	1.613	0.920	0.100	3.000	1.65	1.000



**Figure 4.1:** Graph representing the Grubbs' Test, outlier plot at 5% significance level. No outliers were observed.

The means and 95% confidence intervals for the intact, disrupted, and reconstructed groups illustrate graphically that the disrupted group had substantially larger horizontal displacement when compared to the other groups with no overlap of the respective 95% confidence intervals.

The graph in Figure 2 visually demonstrates that all reconstructions restored horizontal instability to its native state.

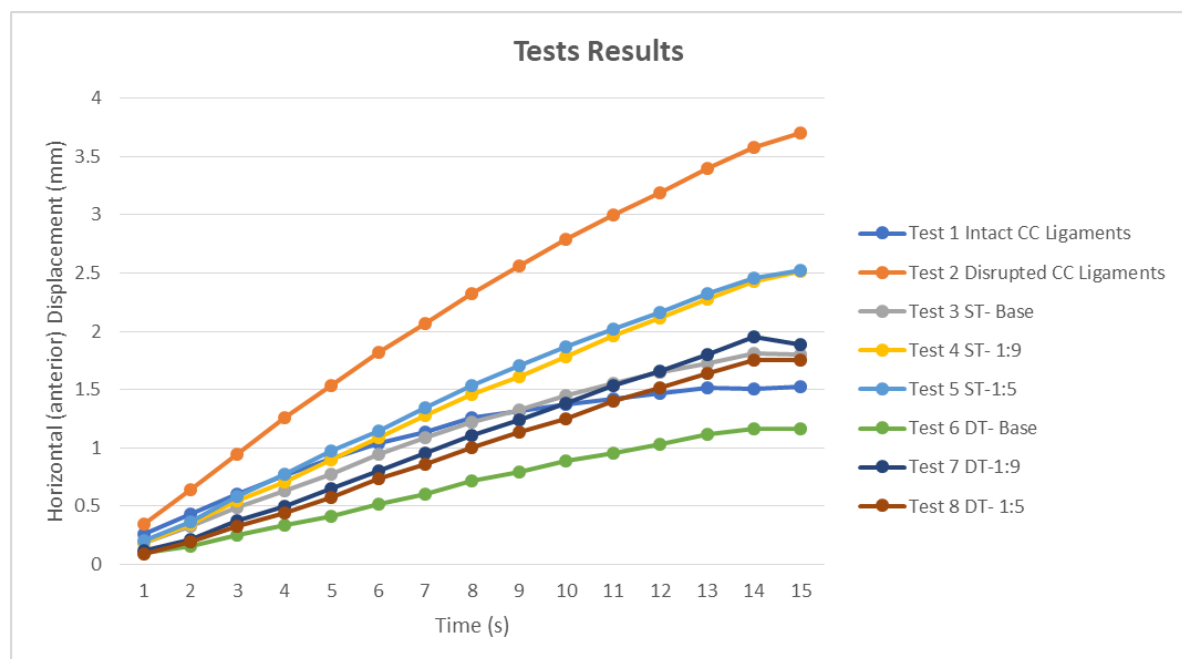


**Figure 4.2:** Interval plot of Tests graph showing the means and 95% confidence intervals for the intact, disrupted, and reconstructed groups.

The overall mean results of the horizontal anterior displacement for all shoulder specimens are shown in Table 4.4 (Page 43) and is illustrated graphically in Figure 4.3. As the constant load (25mm/min) was applied, there was a recorded increase in the horizontal anterior displacement at the AC joint. Test 2 demonstrated a positive slope and had the steepest slope of all the tests (Figure 4.3). This illustrates an almost linear relationship as a continuous load (25mm/min) applied displaces the acromion on the clavicle. Test 6 shows the shallowest slope of all the tests, indicating a minute displacement at the AC joint during loading (Figure 4.3).

**Table 4.4:** Results of AC (acromioclavicular) joint Horizontal (anterior) displacement for combined Shoulders 1 to 15 during loading for 15 seconds in all Test groups. ST- single transclavicular tunnel. DT- double transclavicular tunnel. ST/DT0- coracoid tunnel at the base, ST/DT9- coracoid tunnel at one-ninth from the coracoid base and ST/DT5- coracoid tunnel at one-fifth from the coracoid base. All measurements in mm- millimetres, s-seconds.

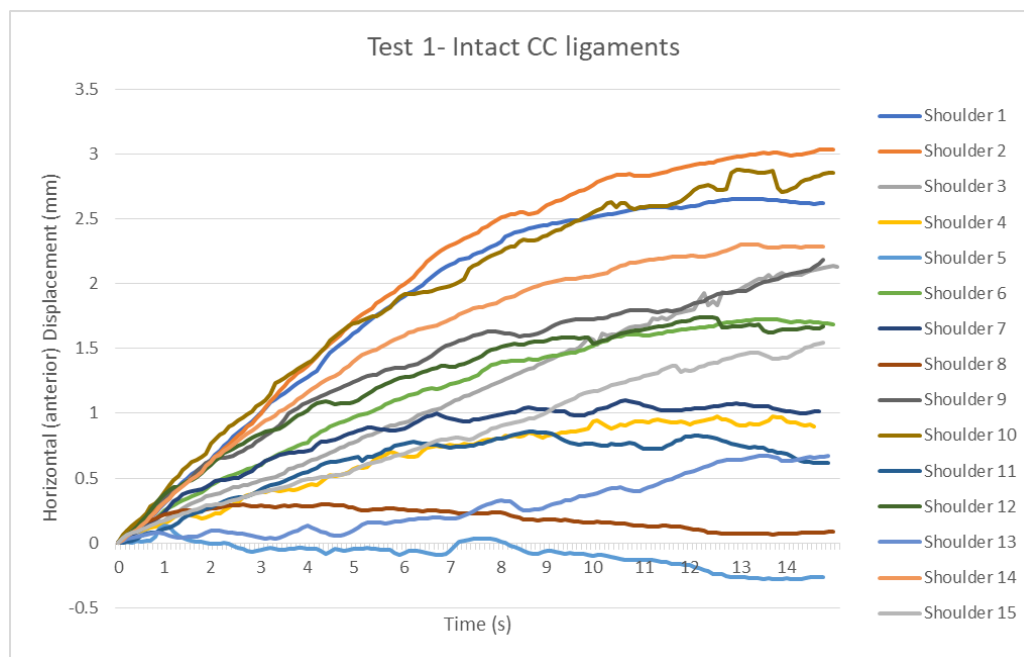
AC joint Horizontal (anterior) Mean Displacement in mm loaded for a period of 15 seconds for all Test conditions.								
Time(s)	Test 1 Intact	Test 2 Disrupted	Test 3 ST-0	Test 4 ST-9	Test 5 ST-5	Test 6 DT-0	Test 7 DT-9	Test 8 DT-5
1	0.3	0.3	0.2	0.2	0.2	0.1	0.1	0.1
2	0.4	0.6	0.3	0.3	0.4	0.2	0.2	0.2
3	0.6	0.9	0.5	0.5	0.6	0.3	0.4	0.3
4	0.8	1.3	0.6	0.7	0.8	0.3	0.5	0.4
5	0.9	1.5	0.8	0.9	1.0	0.4	0.7	0.6
6	1.0	1.8	0.9	1.1	1.1	0.5	0.8	0.7
7	1.1	2.1	1.1	1.3	1.3	0.6	1.0	0.9
8	1.3	2.3	1.2	1.5	1.5	0.7	1.1	1.0
9	1.3	2.6	1.3	1.6	1.7	0.8	1.2	1.1
10	1.4	2.8	1.5	1.8	1.9	0.9	1.4	1.3
11	1.4	3.0	1.6	2.0	2.0	1.0	1.5	1.4
12	1.5	3.2	1.6	2.1	2.2	1.0	1.7	1.5
13	1.5	3.4	1.7	2.3	2.3	1.1	1.8	1.7
14	1.5	3.6	1.8	2.4	2.5	1.2	2.0	1.8
15	1.5	3.7	1.8	2.5	2.5	1.2	2.0	1.8



**Figure 4.3:** Graphs representing Mean Horizontal (Anterior) Displacement (mm) vs Time (s) for all test conditions. ST- single transclavicular tunnel. DT- double transclavicular tunnel. Base- coracoid tunnel at the base, 1:9- coracoid tunnel at one-ninth from the coracoid base and 1:5- coracoid tunnel at one-fifth from the coracoid base. (s- seconds and mm- millimetres).

#### 4.2.1 Baseline results of the AC joint horizontal (anterior) stability with intact CC ligaments (Test 1).

The mean baseline horizontal anterior displacement for intact CC ligaments performed in Test 1 was  $1.6 \pm 0.9$ mm (Table 4.2, Page 40). The confidence interval for this Test ranged from 1.1-2.1mm for all 15 shoulders. The maximum displacement for Test 1 (intact) was 3.0mm, observed in Shoulder 2(Figure 4.4; Table 4.2, Page 40). Of the 15 shoulders tested in the intact state, 40% (n=6/15) displaced more than 2.0mm during the 15s period, while the remaining 9 shoulders (60%) were observed to displace less than 2.0mm during the 15s phase (Table 4.2, Page 40).

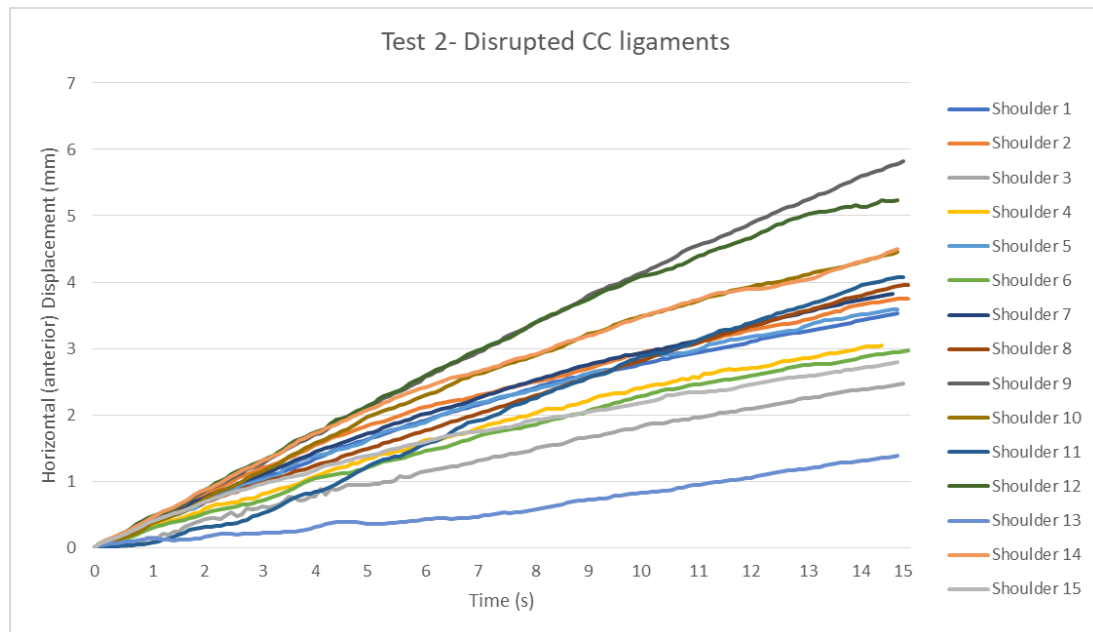


**Figure 4.4:** Graphs representing Horizontal Anterior Displacement (mm) vs Time(s) for Test 1- Intact CC ligaments for all Shoulder specimens (n=15). mm- millimetres, s-seconds.

#### 4.2.2 Results of the AC joint horizontal (anterior) stability with disrupted CC ligaments (Test 2).

Following mid-substance transection of the CC ligaments performed in Test 2, the mean horizontal anterior displacement was  $3.6 \pm 1$ mm. With the CC ligaments disrupted, 93.3%

(n=14/15) of the sample displaced more than 2.0mm while only one shoulder displaced 1.0mm over the 15s period (Table 4.2, Page 40). Of the fourteen shoulders, ten displaced more than 3.0mm. The maximum horizontal anterior displacement reached was 5.8mm on Shoulder 9 (Figure 4.5; Table 4.2, Page 40). Shoulder 13 demonstrated the least displacement during Test 2 (Figure 4.5; Table 4.2, Page 40).

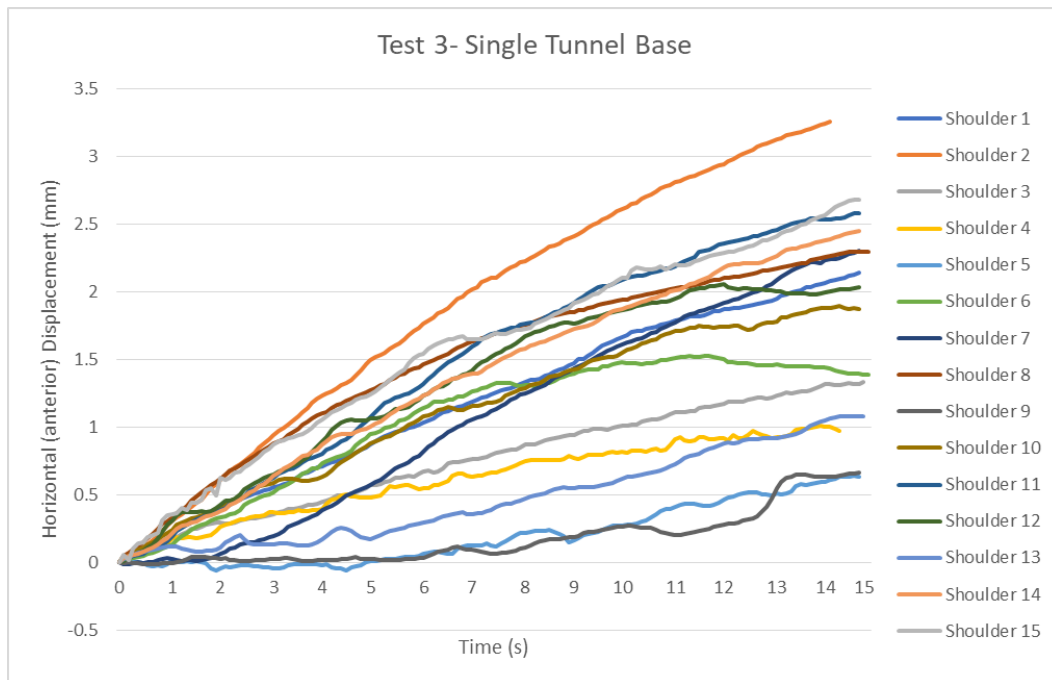


**Figure 4.5:** Graphs representing Horizontal Anterior Displacement (mm) vs Time(s) for Test 2- Disrupted CC ligaments for all Shoulder specimens (n=15). mm- millimetres, s-seconds.

#### 4.2.3 AC joint horizontal stability results following a single transclavicular and transcoracoid tunnel reconstruction at the coracoid base (Test 3).

Reconstructing the AC joint with a single tunnel technique resulted in a mean AC joint horizontal anterior displacement of  $1.9 \pm 0.8$ mm. This represents only 15% more displacement than the intact state in Test 1 (Table 4.2, Page 40). Following the reconstruction technique with a single transclavicular and transcoracoid at the base, 47% (n=7/15) of the specimens displaced

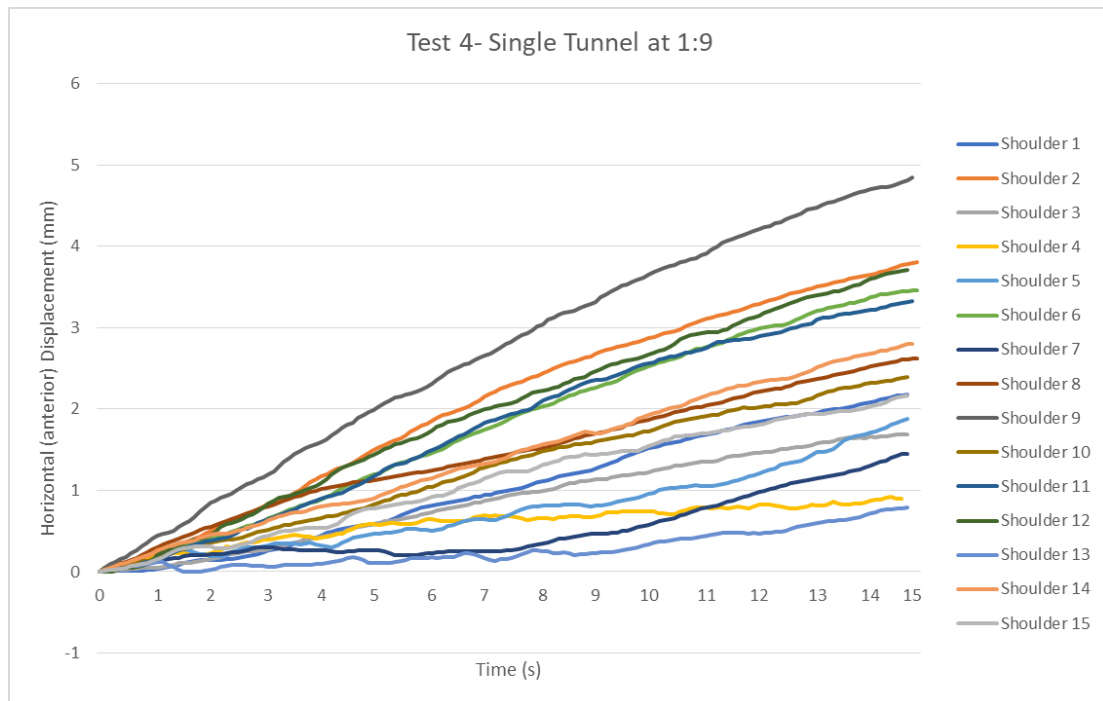
less than 2.0mm. The maximum displacement recorded was 3.3mm, observed in Shoulder 2 (Figure 4.6; Table 4.2, Page 40).



**Figure 4.6:** Graphs representing Horizontal Anterior Displacement (mm) vs Time(s) for Test 3- Single Transclavicular Tunnel Reconstruction at the coracoid base for all Shoulder specimens (n=15). mm- millimetres, s-seconds.

#### 4.2.4 AC joint horizontal stability results following a single transclavicular and transcoracoid tunnel reconstruction at 1:9 from the coracoid base (Test 4).

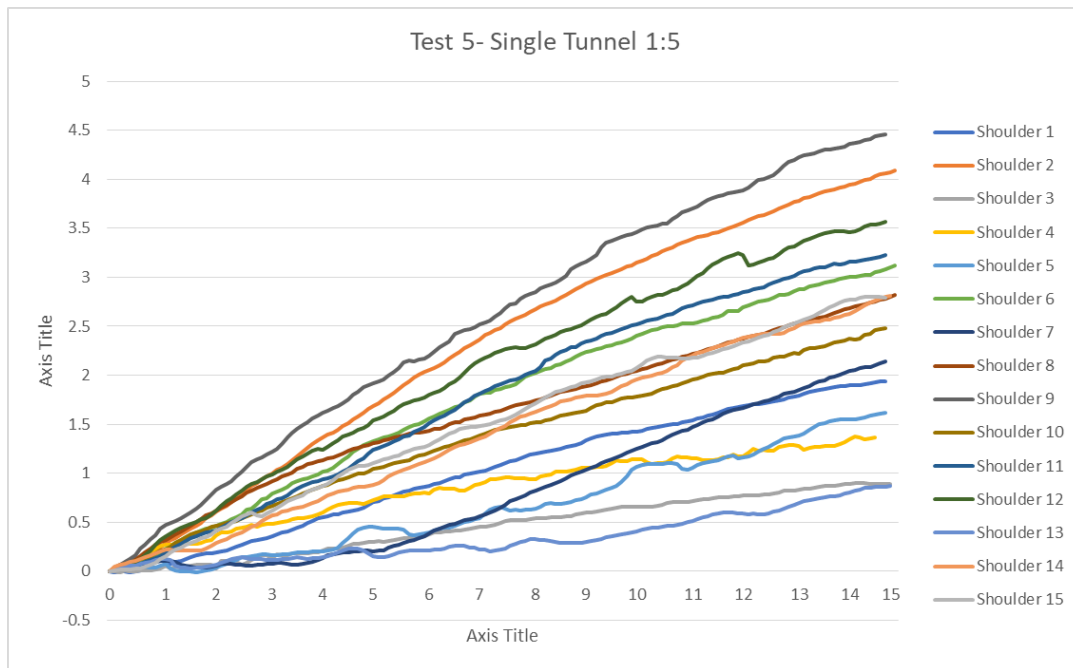
Single transclavicular reconstruction with a tunnel at 1:9 from the coracoid base gave a horizontal anterior displacement of  $2.5 \pm 1.1$ mm. This represents 36% more displacement than the native state. (Table 4.2, Page 40). During Test 4, 33% (n=5/15) of the sample demonstrated a displacement of less than 2.0mm. Of the five shoulders, two recorded displacements of less than 1.0mm (Shoulders 4 & 13). The maximum horizontal (anterior) displacement reached was 4.8mm, observed in Shoulder 9 (Figure 4.7).



**Figure 4.7:** Graphs representing Horizontal Anterior Displacement (mm) vs Time(s) for Test 4- Single Transclavicular Tunnel Reconstruction at 1:9 from the coracoid base for all Shoulder specimens (n=15). mm- millimetres, s-seconds.

#### 4.2.5 AC joint horizontal stability results following a single transclavicular and transcoracoid tunnel reconstruction at 1:5 from the coracoid base (Test 5).

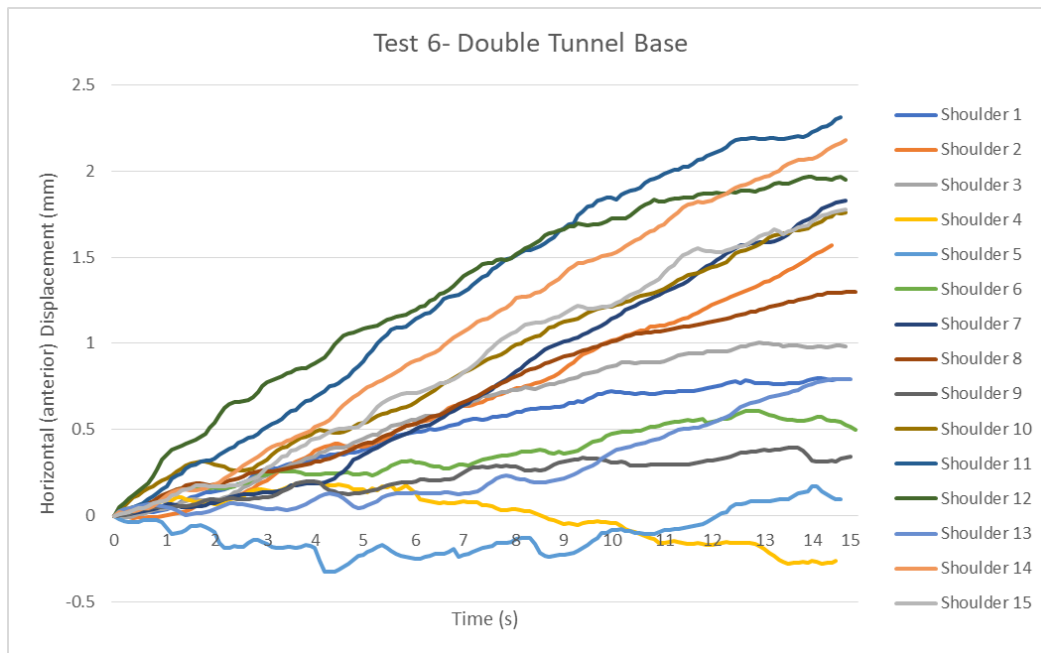
With the coracoid tunnel located 1:5 from the coracoid base, the mean AC joint anterior displacement was  $2.5 \pm 1.1$  mm. The recorded displacement was 36% more than for the intact ligaments (Table 4.2, Page 40). Of the 15 shoulders during Test 5, 33.3% (n=5/15) recorded displacement of less than 2.0mm (Table 4.2, Page 40). The confidence interval for Test 5 was 1.9-3.1mm for all 15 shoulder specimens. The maximum horizontal displacement recorded for Test 5 was 4.6mm seen in Shoulder 9 (Figure 4.8 & Table 4.2, Page 40).



**Figure 4.8:** Graphs representing Horizontal Anterior Displacement (mm) vs Time(s) for Test 5- Single Transclavicular Tunnel Reconstruction at 1:5 from the coracoid base for all Shoulder specimens (n=15). mm- millimetres, s-seconds.

**4.2.6 Results of the reconstruction technique for the 2cm and 4cm double transclavicular and a single transcoracoid tunnel reconstruction at the coracoid base (Test 6).**

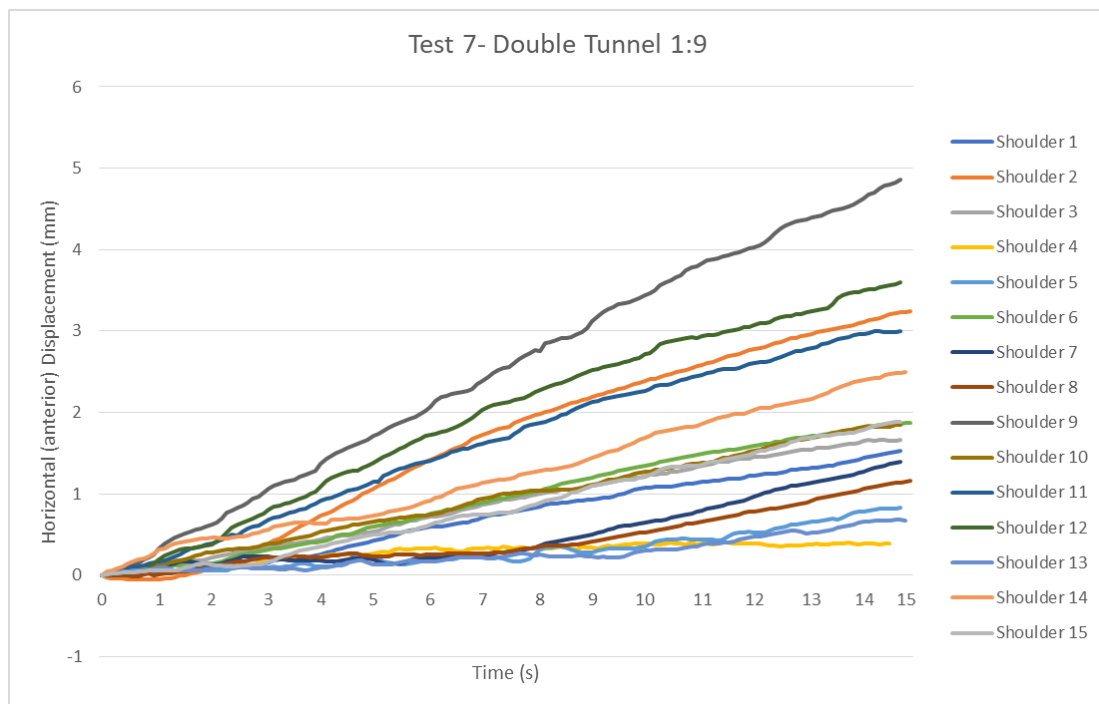
The double transclavicular single transcoracoid tunnel at the coracoid base showed the least AC joint horizontal (anterior) displacement in all the Tests (Table 4.2, Page 40). The recorded displacement was  $1.2 \pm 0.7$ mm with a confidence interval range of 0.8-1.6mm for all 15 shoulders. Test 6 results demonstrate a construct displacing less than 25% of the intact state (Test 1). With the double transclavicular single transcoracoid tunnel reconstruction at the coracoid base, 80% (n=12/15) of the sample displaced less than 2.0mm. The maximum displacement observed was 2.3mm in Shoulder 11 (Figure 4.9; Table 4.2).



**Figure 4.9:** Graphs representing Horizontal Anterior Displacement (mm) vs Time(s) for Test 6- Double Transclavicular Single Transcoracoid Tunnel Reconstruction at the coracoid base for all Shoulder specimens (n=15). mm- millimetres, s- seconds.

#### 4.2.7 Results of reconstruction technique for the 2cm and 4cm double transclavicular and a single transcoracoid tunnel reconstruction at 1:9 from the coracoid base (Test 7).

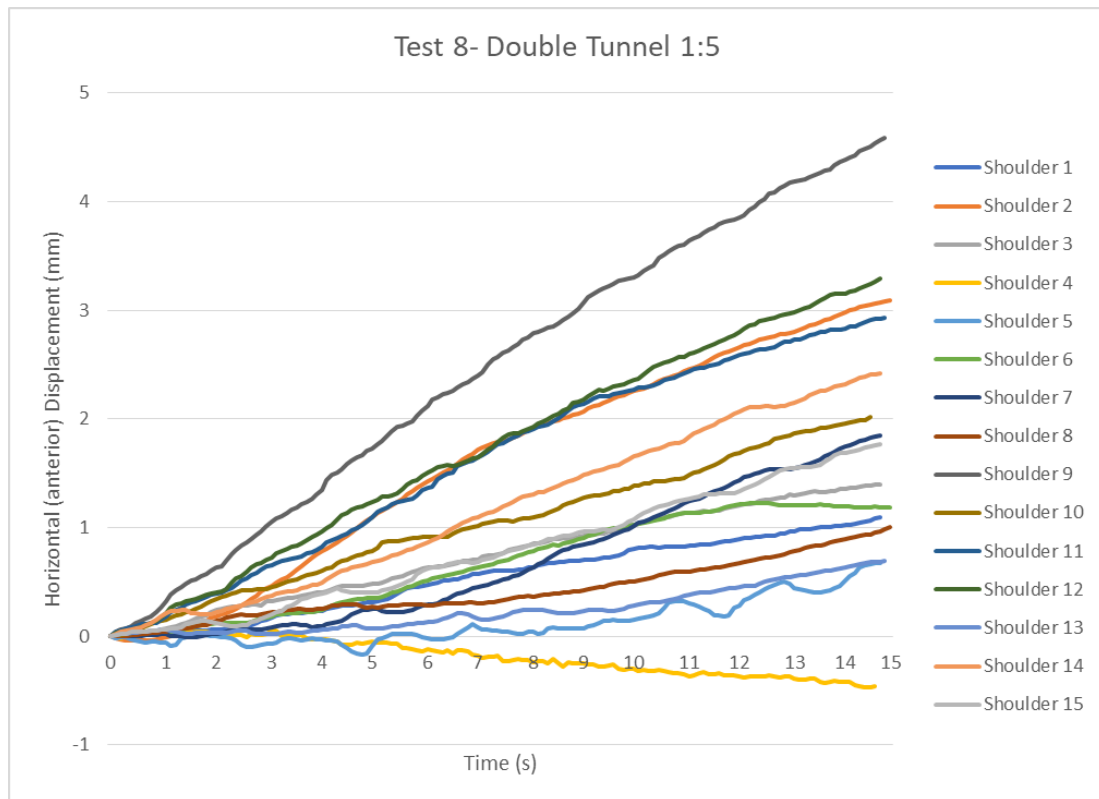
The mean AC joint horizontal (anterior) displacement for Test 7 (DT-9) was  $2.0 \pm 1.2$ mm (Table 4.2, Page 40). The displacement was 20% more than the intact state of CC ligaments in Test 1. The maximum displacement for Test 7 was 4.9mm, observed in Shoulder 9 (Figure 4.10; Table 4.2, Page 40) while Shoulder 5 recorded the least displacement (displacement = 0.2mm) (Figure 4.10; Table 4.2). A displacement of less than 2mm was observed in 66.7% (n=10/15) of the sample (Table 4.2, Page 40).



**Figure 4.10:** Graphs representing Horizontal Anterior Displacement (mm) vs Time(s) for Test 7- Double Transclavicular Single Transcoracoid Tunnel Reconstruction at 1:9 from the coracoid base for all Shoulder specimens (n=15). mm- millimetres, s- seconds.

#### 4.2.8 Results of reconstruction technique for the 2cm and 4cm double transclavicular and a single transcoracoid tunnel reconstruction at 1:5 from the coracoid base (Test 8).

The mean horizontal anterior displacement recorded was  $1.9 \pm 1.2$  mm for Test 8 (Table 4.2, Page 40). Similar to Test 3 (ST-0), Test 8 had a mean AC joint horizontal anterior displacement of 15% more than the native CC ligaments (intact) in Test 1. The confidence interval range for Test 8 was 1.2-2.5 mm for all 15 shoulders. Following reconstruction with double transclavicular single transcoracoid tunnel technique, 60% (n=9/15) of the specimens recorded a displacement of less than 2.0 mm. The maximum displacement was 4.6 mm observed in Shoulder 9 (Figure 4.11; Table 4.2, Page 40).



**Figure 4.11:** Graphs representing Horizontal Anterior Displacement (mm) vs Time(s) for Test 8- Double Transclavicular Single Transcoracoid Tunnel Reconstruction at 1:5 from the coracoid base for all Shoulder specimens (n=15). mm- millimetres, s-seconds.

### 4.3 Comparative results

A one-way ANOVA was performed to compare horizontal displacement between intact and reconstructed specimens. This revealed that there was a statistically significant difference in mean horizontal displacement between the test groups (Table 4.5, Page 51).

**Table 4.5:** Analysis of Variance Analysis (ANOVA) demonstrated statistically significant between-group comparisons.

Source	DF	Adj SS	Adj MS	F-Value	P-Value
Factor	7	60.07	8.581	7.81	0.000
Error	112	123.05	1.099		
Total	119	183.12			

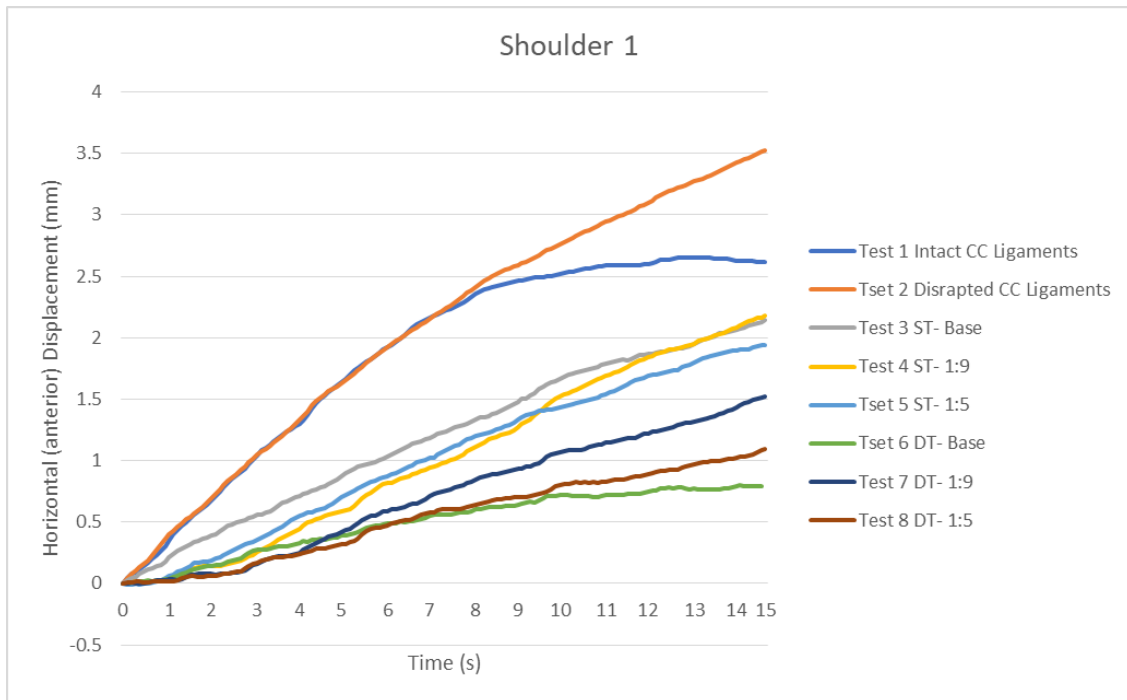
The visual findings are confirmed by Tukeys post hoc test which showed significant differences between disrupted and all the test groups except for ST1:5 and ST1:9 (Table 4.6, Page 52). The DT-0 also demonstrated a significant difference with the ST1:9 and ST1:5 test groups (P-Value = 0.00).

**Table 4.6:** Results of Tukeys Post Hoc Test for Differences of Means.

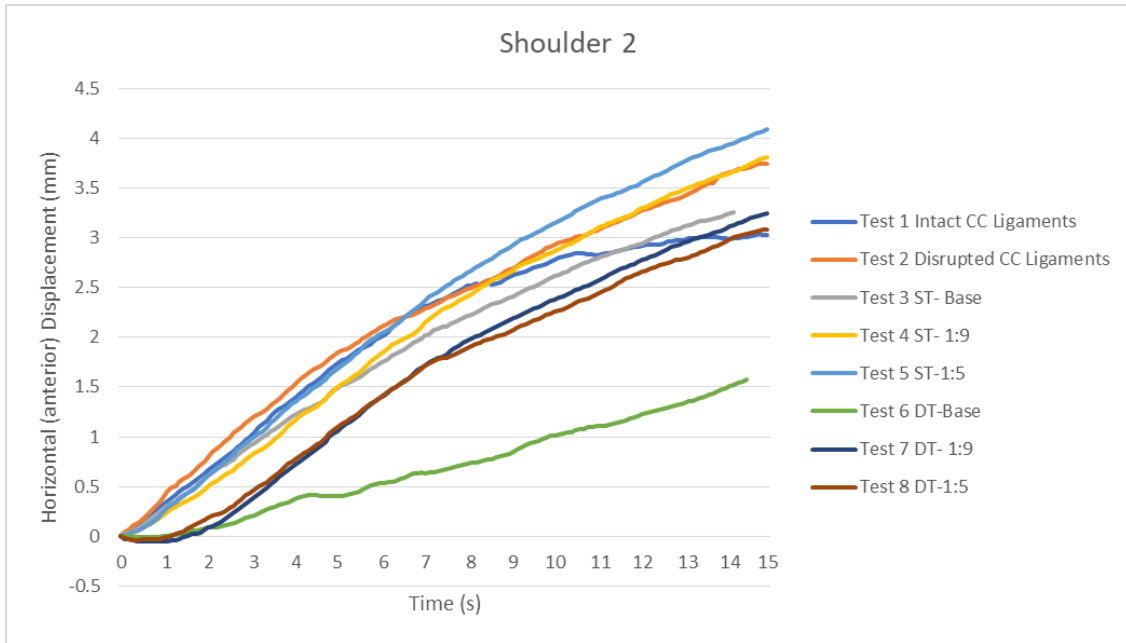
Difference of Levels	Difference of Means	SE of		T-Value	Adjusted P-Value
		Difference	95% CI		
Disrupted - Intact	2.080	0.383	(0.897, 3.263)	5.43	0.000
DT0 - Intact	-0.360	0.383	(-1.543, 0.823)	-0.94	0.981
ST0 - Intact	0.253	0.383	(-0.929, 1.436)	0.66	0.998
ST1:5 - Intact	1.007	0.383	(-0.176, 2.189)	2.63	0.156
DT1:5 - Intact	0.267	0.383	(-0.916, 1.449)	0.70	0.997
ST1:9 - Intact	0.927	0.383	(-0.256, 2.109)	2.42	0.242
DT1:9 - Intact	0.413	0.383	(-0.769, 1.596)	1.08	0.960
DT0 - Disrupted	-2.440	0.383	(-3.623, -1.257)	-6.38	0.000
ST0 - Disrupted	-1.827	0.383	(-3.009, -0.644)	-4.77	0.000
ST1:5 - Disrupted	-1.073	0.383	(-2.256, 0.109)	-2.80	0.104
DT1:5 - Disrupted	-1.813	0.383	(-2.996, -0.631)	-4.74	0.000
ST1:9 - Disrupted	-1.153	0.383	(-2.336, 0.029)	-3.01	0.061
DT1:9 - Disrupted	-1.667	0.383	(-2.849, -0.484)	-4.35	0.001
ST0 - DT0	0.613	0.383	(-0.569, 1.796)	1.60	0.748
ST1:5 - DT0	1.367	0.383	(0.184, 2.549)	3.57	0.012
DT1:5 - DT0	0.627	0.383	(-0.556, 1.809)	1.64	0.727
ST1:9 - DT0	1.287	0.383	(0.104, 2.469)	3.36	0.023
DT1:9 - DT0	0.773	0.383	(-0.409, 1.956)	2.02	0.473
ST1:5 - ST0	0.753	0.383	(-0.429, 1.936)	1.97	0.508
DT1:5 - ST0	0.013	0.383	(-1.169, 1.196)	0.03	1.000
ST1:9 - ST0	0.673	0.383	(-0.509, 1.856)	1.76	0.649
DT1:9 - ST0	0.160	0.383	(-1.023, 1.343)	0.42	1.000
DT1:5 - ST1:5	-0.740	0.383	(-1.923, 0.443)	-1.93	0.531
ST1:9 - ST1:5	-0.080	0.383	(-1.263, 1.103)	-0.21	1.000
DT1:9 - ST1:5	-0.593	0.383	(-1.776, 0.589)	-1.55	0.778
ST1:9 - DT1:5	0.660	0.383	(-0.523, 1.843)	1.72	0.671
DT1:9 - DT1:5	0.147	0.383	(-1.036, 1.329)	0.38	1.000
DT1:9 - ST1:9	-0.513	0.383	(-1.696, 0.669)	-1.34	0.881

The graphical representation of the AC joint horizontal displacement with all tests performed per shoulder is shown on individual graphs below (Figure 4.12- Figure 4.26). In all the tested shoulders there was a consistent pattern of horizontal anterior displacement between the Tests. Test 2 demonstrating disrupted CC Ligaments had the most horizontal displacement in all the tested shoulders. For Shoulder 4, the AC joint displacement showed a negative displacement at 15 seconds of loading in Tests 6 and 8. Also, a negative displacement at 15 seconds was recorded in Tests 1 for Shoulder 5.

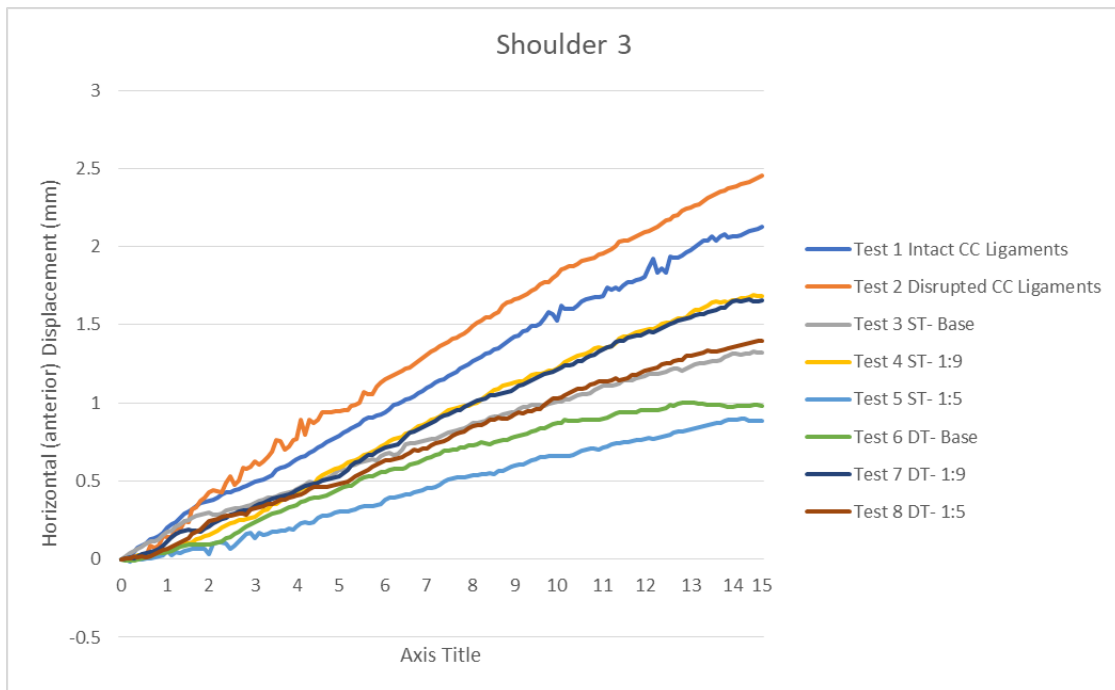The disrupted CC ligaments investigated in Test 2 showed the greatest horizontal displacement in all the tests performed. The DT-0 reconstruction at the base demonstrated the least horizontal displacement on all the reconstructed Shoulders except in Shoulders 3, 4, 8 and 11, whereby the reconstruction at ST-5, DT-5, DT-9 and ST-0, respectively, showed a minor displacement.



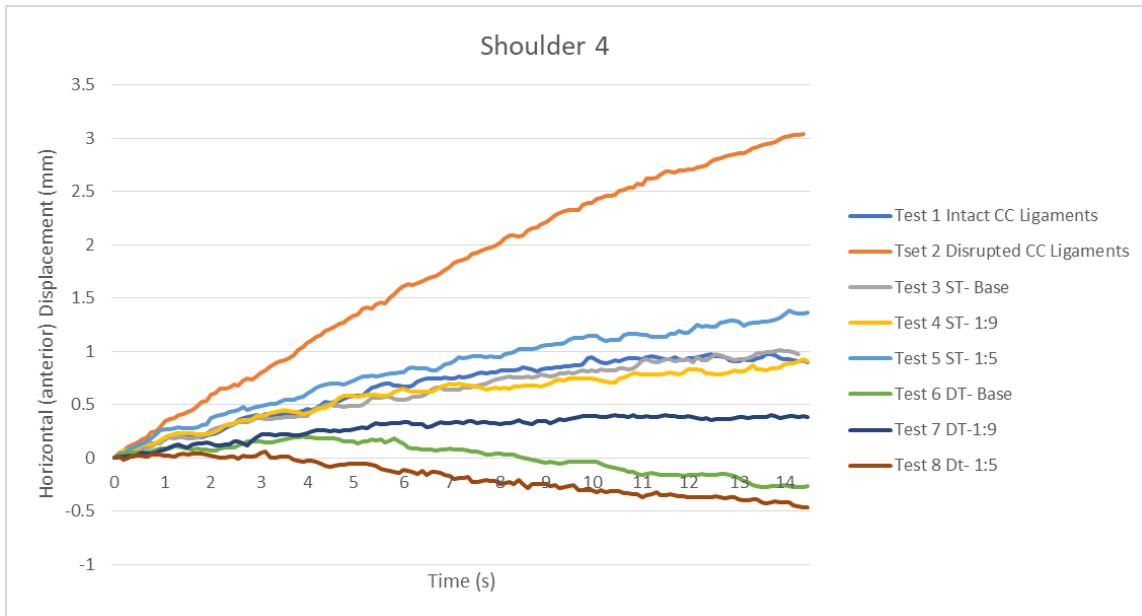
**Figure 4.12:** Graphs representing Horizontal (anterior) Displacement (mm) vs. Time (s) for Shoulder 1 specimen Tests 1 to 8. mm- millimetres, s- seconds.



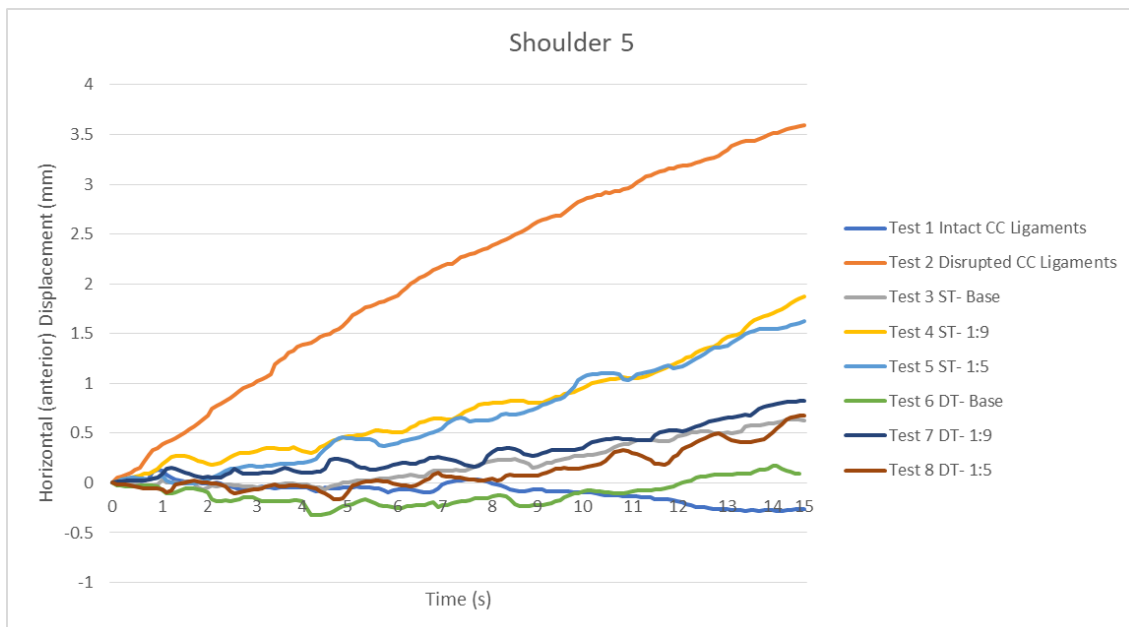
**Figure 4.13:** Graphs representing Horizontal (anterior) Displacement (mm) vs. Time (s) for Shoulder 2 specimen Tests 1 to 8. mm- millimetres, s- seconds.



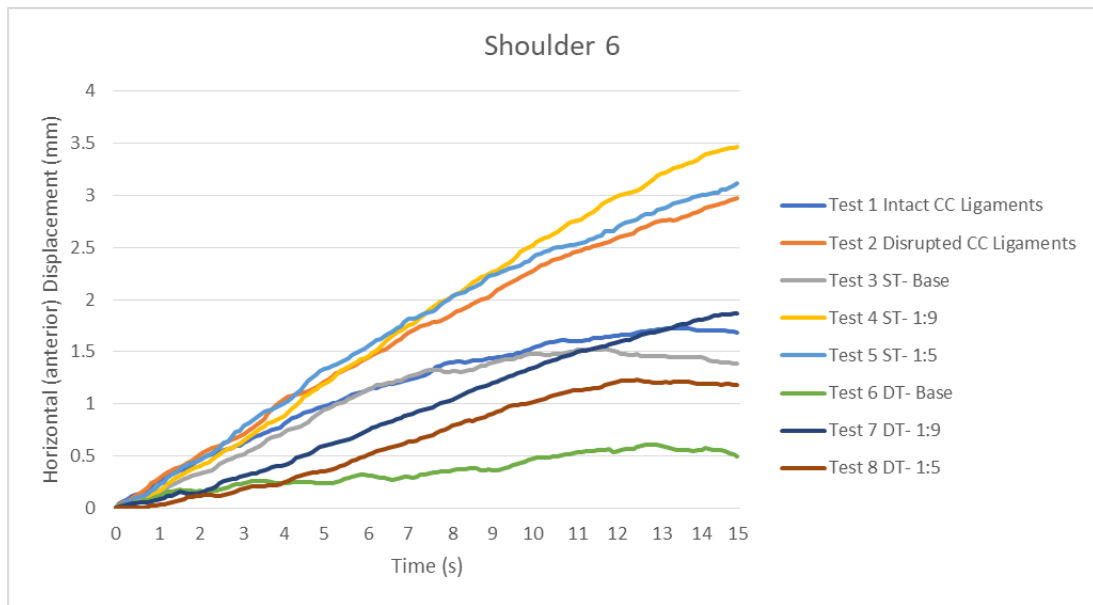
**Figure 4.14:** Graphs representing Horizontal (anterior) Displacement (mm) vs. Time (s) for Shoulder 3 specimen Tests 1 to 8. mm- millimetres, s- seconds.



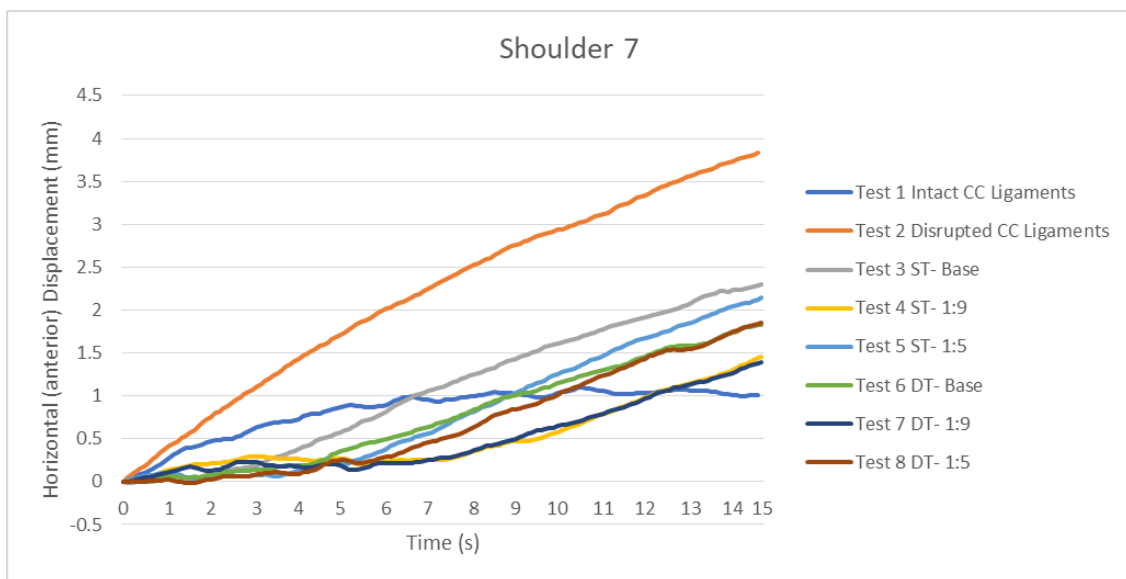
**Figure 4.15:** Graphs representing Horizontal (anterior) Displacement (mm) vs. Time (s) for Shoulder 4 specimen Tests 1 to 8. mm- millimetres, s- seconds.



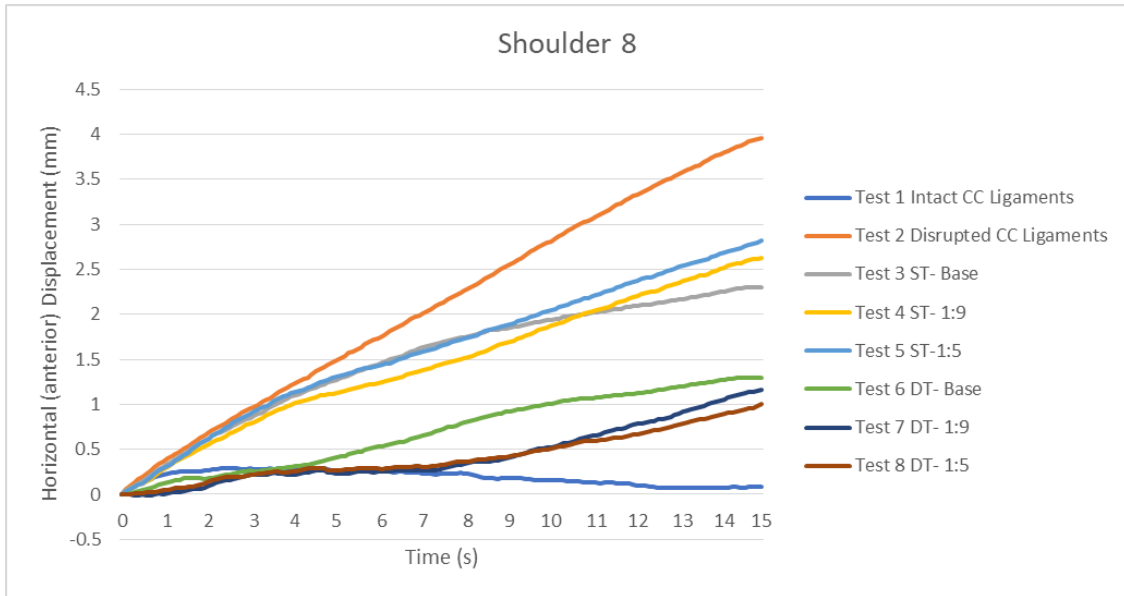
**Figure 4.16:** Graphs representing Horizontal (anterior) Displacement (mm) vs. Time (s) for Shoulder 5 specimen Tests 1 to 8. mm- millimetres, s- seconds.



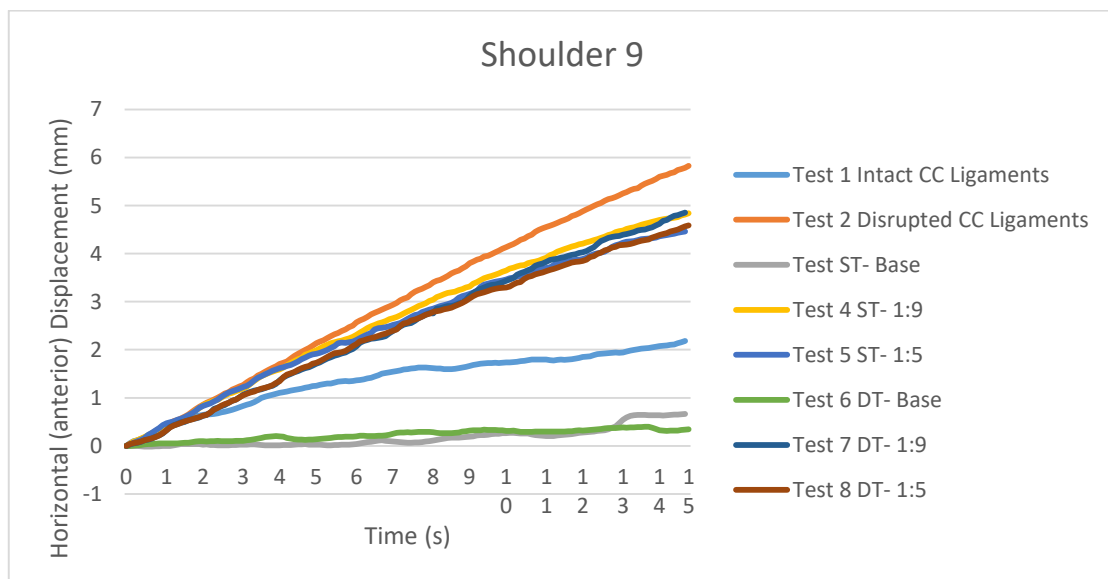
**Figure 4.17:** Graphs representing Horizontal (anterior) Displacement (mm) vs. Time (s) for Shoulder 6 specimen Tests 1 to 8. mm- millimetres, s- seconds.



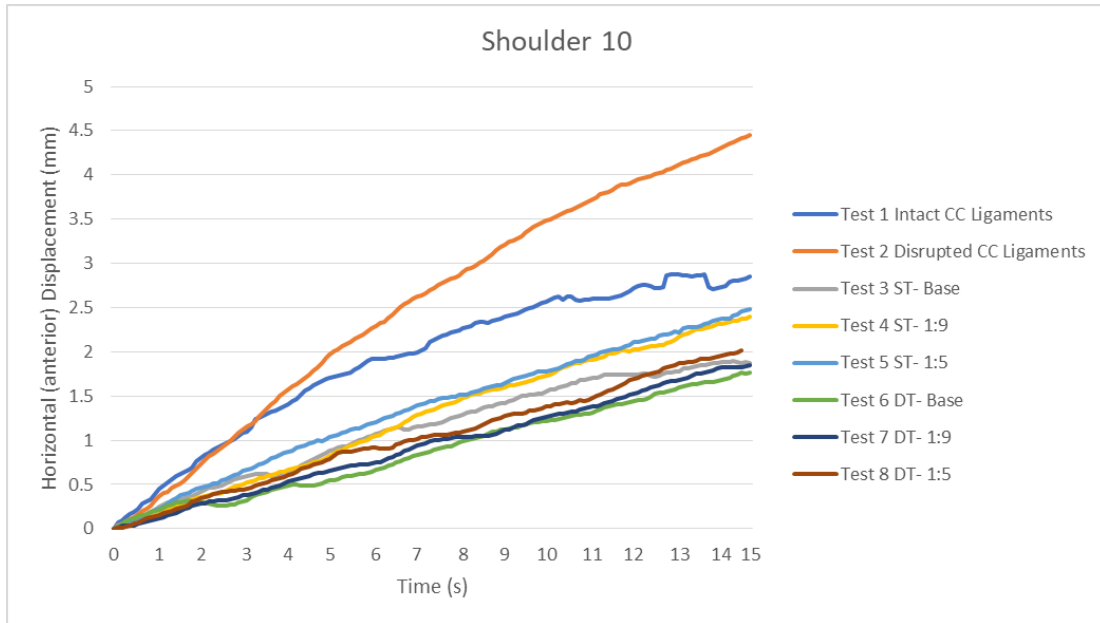**Figure 4.18:** Graphs representing Horizontal (anterior) Displacement (mm) vs. Time (s) for Shoulder 7 specimen Tests 1 to 8. mm- millimetres, s- seconds.



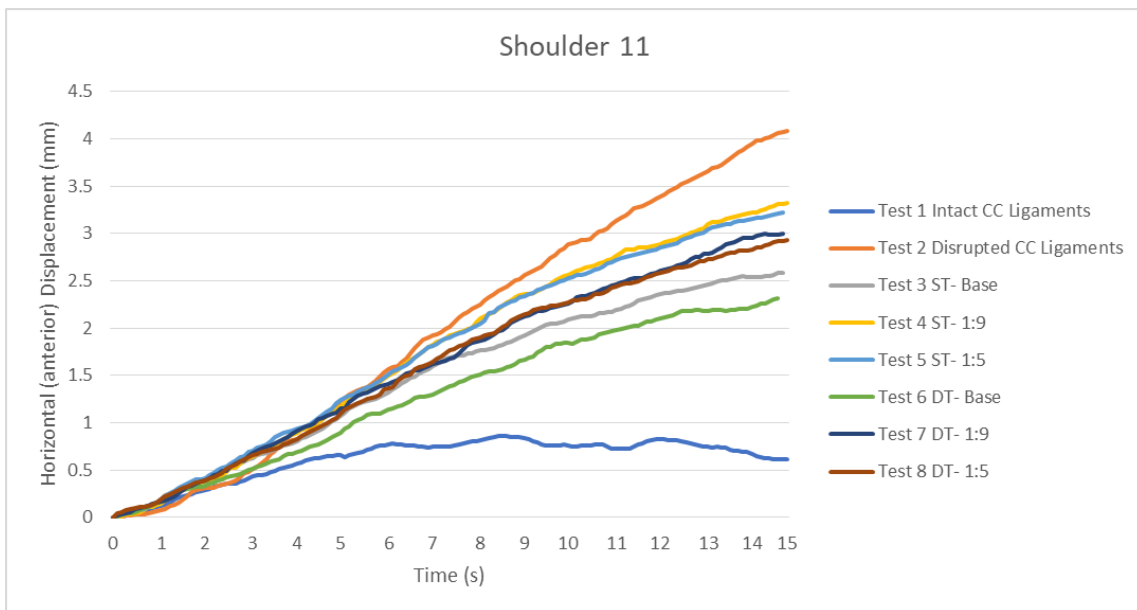
**Figure 4.19:** Graphs representing Horizontal (anterior) Displacement (mm) vs. Time (s) for Shoulder 8 specimen Tests 1 to 8. mm- millimetres, s- seconds.



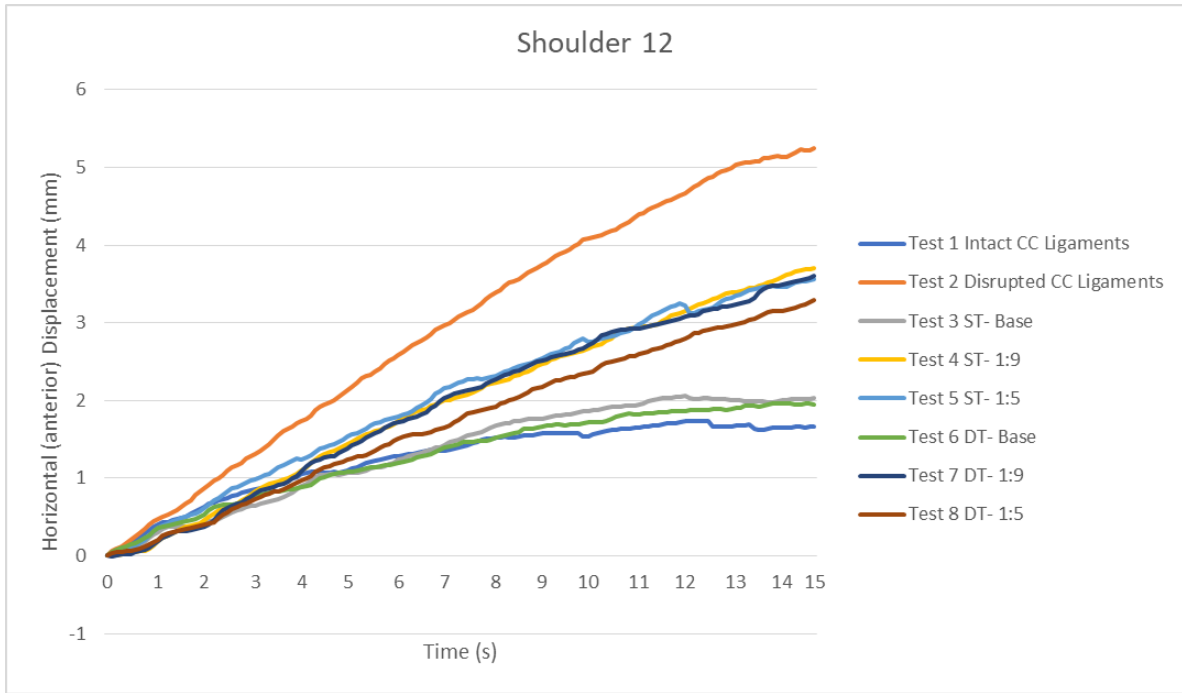**Figure 4.20:** Graphs representing Horizontal (anterior) Displacement (mm) vs. Time (s) for Shoulder 9 specimen Tests 1 to 8. mm- millimetres, s- seconds.



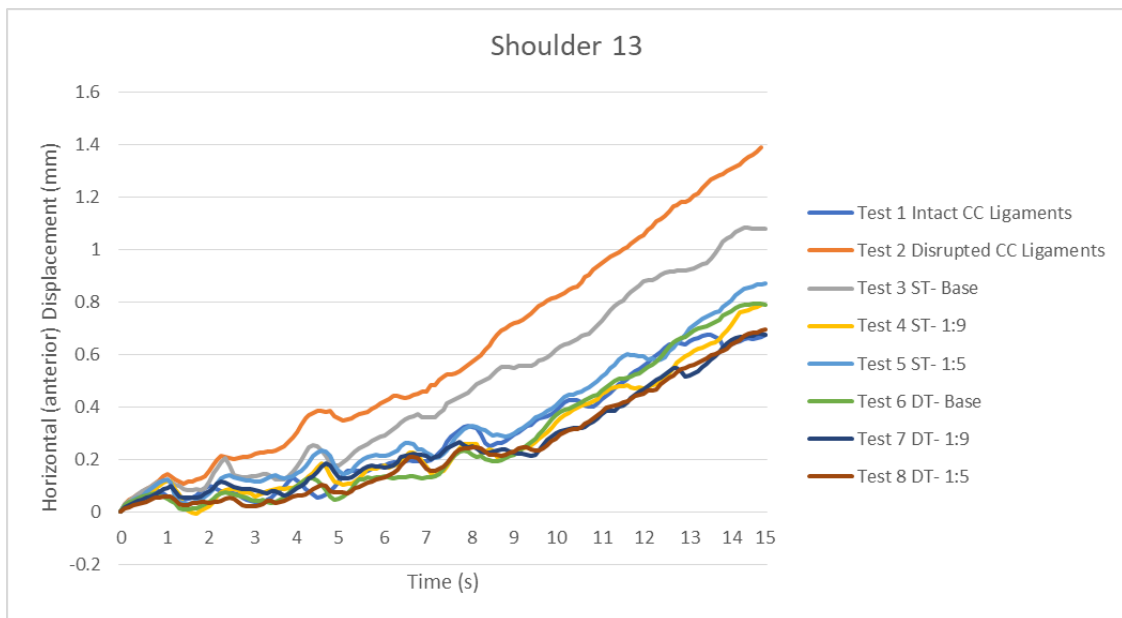
**Figure 4.21:** Graphs representing Horizontal (anterior) Displacement (mm) vs. Time (s) for Shoulder 10 specimen Tests 1 to 8. mm- millimetres, s- seconds.



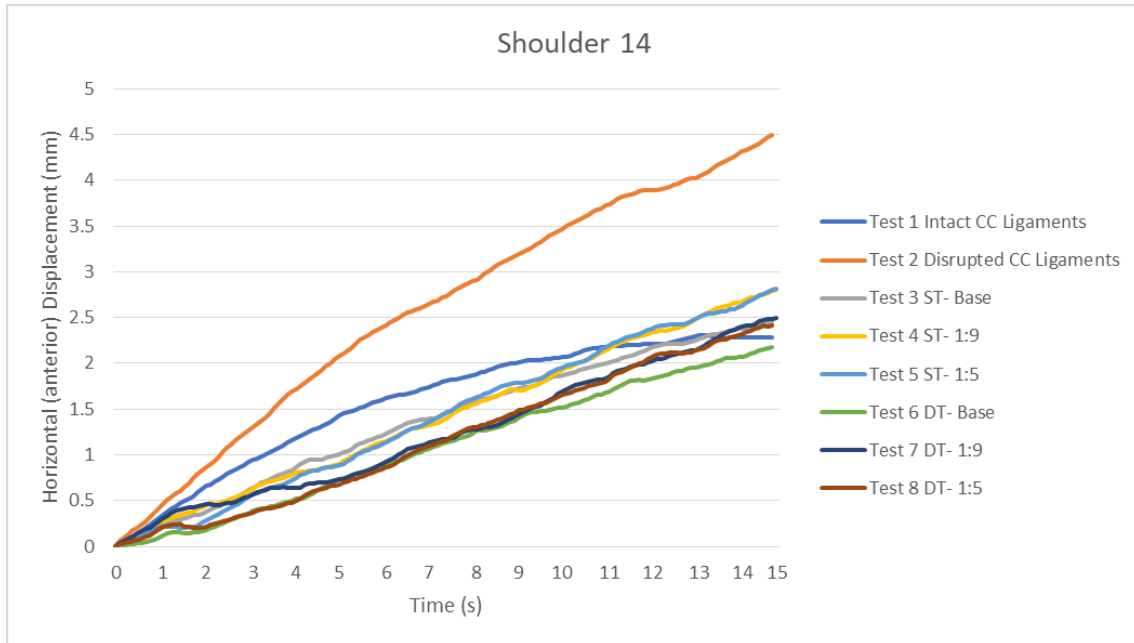
**Figure 4.22:** Graphs representing Horizontal (anterior) Displacement (mm) vs. Time (s) for Shoulder 11 specimen Tests 1 to 8. mm- millimetres, s- seconds.



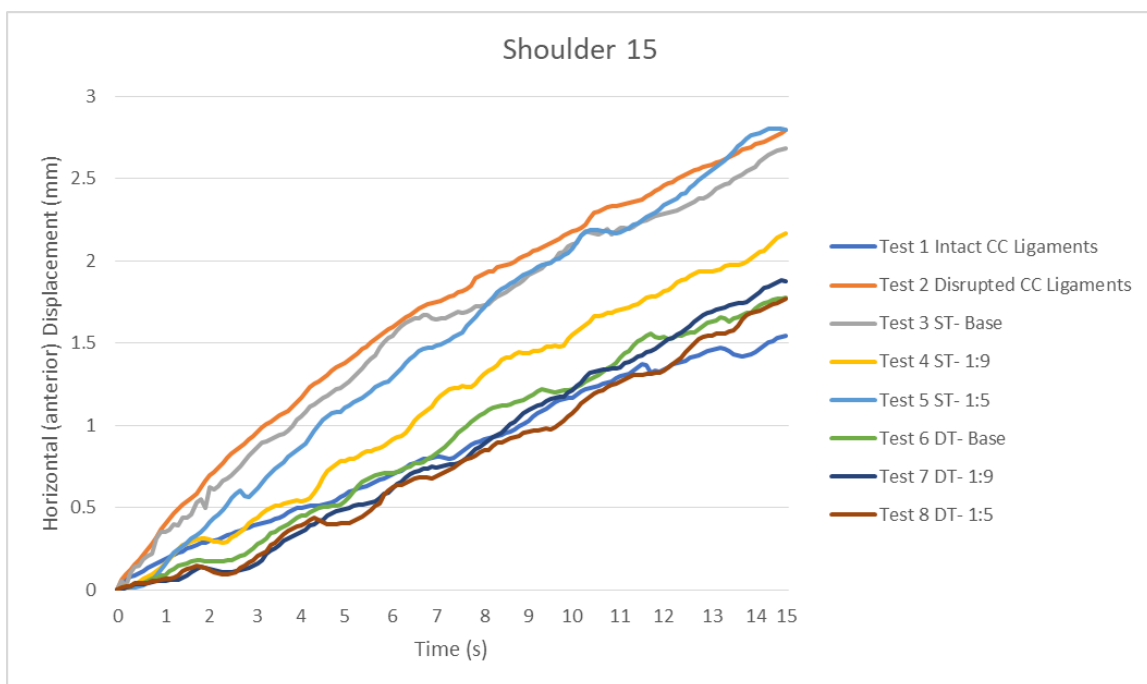
**Figure 4.23:** Graphs representing Horizontal (anterior) Displacement (mm) vs. Time (s) for Shoulder 12 specimen Tests 1 to 8. mm- millimetres, s- seconds.



**Figure 4.24:** Graphs representing Horizontal (anterior) Displacement (mm) vs. Time (s) for Shoulder 13 specimen Tests 1 to 8. mm- millimetres, s- seconds.



**Figure 4.25:** Graphs representing Horizontal (anterior) Displacement (mm) vs. Time (s) for Shoulder 14 specimen Tests. mm- millimetres, s- seconds.



**Figure 4.26:** Graphs representing Horizontal (anterior) Displacement (mm) vs. Time (s) for Shoulder 15 specimen Tests. mm- millimetres, s- seconds.

## Chapter 5 : DISCUSSION

The results of this study demonstrated that disruption of the coracoclavicular (CC) ligaments resulted in a 100% displacement of the clavicle when compared to the intact condition. Following stabilization with Tightrope, the pre-disrupted conditions were restored, and there were no statistically significant differences between the initial intact state and reconstructed conditions after testing in the parameters of this study. In fact, restoration did not appear to be affected by technique (single or double button) or tunnel position, however, there were discrete inter-group differences.

### 5.1 Coracoclavicular ligament repair: Biomechanical studies

Increased anterior-posterior translation of the lateral clavicle against the acromion commonly results in horizontal instability, which has been reported by various researchers (Gonzalez-Lomas *et al.*, 2010; Michlitsch *et al.*, 2010; Beitzel *et al.*, 2012; Saier *et al.*, 2015).

Most surgical techniques used for acromioclavicular (AC) joint reconstruction focus on vertical stability. However, horizontal stability also needs to be addressed to achieve ultimate AC joint integrity. Numerous biomechanical studies have evaluated the horizontal stability of the AC joint using various testing protocols (Lee *et al.*, 1997; Klimkiewicz *et al.*, 1999; Deshmukh *et al.*, 2004; Jari *et al.*, 2004; Beitzel *et al.*, 2014; Saier *et al.*, 2015; Struhl *et al.*, 2016; Hislop *et al.*, 2019; Celik *et al.*, 2020; Goodine *et al.*, 2022; Lee *et al.*, 2021). Most of these studies use a load of 70N applied to the specimen during testing (Lee *et al.*, 1997; Klimkiewicz *et al.*, 1999; Beitzel *et al.*, 2014; Saier *et al.*, 2015; Struhl *et al.*, 2016). The cited load has been highlighted by Lee *et al.* (1997). It is suggested that forces up to 70N result in less bending of the acromion, coracoid process, and clavicle during biomechanical tests (Lee *et al.*, 1997).

Therefore, with a load of 70N as the ideal force applied during testing, a predetermined displacement can be measured in response to that load. This method was used by Hislop et al. (2019) during testing to set the displacement amplitude, and the clavicle was displaced relative to the acromion in the anterior-posterior and superior direction. When a load of 70N was reached, the displacement was recorded, and the amplitude of the displacement cycles was set based on the predetermined displacement measured in response to the 70N load (Hislop *et al.*, 2018)

The present study used the displacement-controlled load testing method with a 100kN Hydropuls® Universal testing machine. A tensile load was applied to the scapula with the AC joint in a reduced position at a 25mm/min rate, and the maximum displacement was set to 6.25mm. The clavicular tunnel location during the reconstruction of the CC ligaments was based on a previously described technique (Walz *et al.*, 2008). During the anatomical reconstruction of the CC ligaments, the clavicular tunnels should be at the anatomical origin of the conoid and trapezoid ligaments. The clavicular tunnels representing the origins of the conoid, and trapezoid ligaments have been reported to be at around 25 and 45-46 mm from the AC joint (Saccamanno *et al.*, 2014), which was like what was found in the current study.

To test the hypothesis of the present study, the coracoid tunnel location had to be modified. During testing, the coracoid tunnel was located at the base of the coracoid, 1:9 and 1:5 from the coracoid base. The origins of the CC ligaments can also be expressed as a ratio (Rios *et al.*, 2007). The trapezoid and conoid clavicular origins are 17 and 31% of the total clavicular length, respectively (Rios *et al.*, 2007). Although in this current study, the trapezoid origin was consistent with their results, the ratio for the conoid was only 28% of the clavicular length. The difference is due to the broad area of conoid insertion on the clavicle. In the Rios et al. (2007) study, the authors measured the conoid insertion from the lateral edge of the clavicle to the centre of the conoid tuberosity. In the current study, the midpoint of the conoid insertion on the

clavicle was used instead, as described by Xue et al. (2013). Additionally, the specimens in the present study were not differentiated between males and females.

Following the repair of the CC ligaments with a single transclavicular tunnel at the coracoid base (ST-0), the results were closely similar to the intact CC ligaments following baseline testing. The single transclavicular tunnel at 1:9 and 1:5 from the coracoid base (ST-5) resulted in 36% more horizontal displacement than intact CC ligaments. The increasing horizontal anterior displacement when the coracoid tunnel moves more anteriorly is likely due to the reduction in tension of the suspension device suture fibres as the acromion on the scapula translates posteriorly. During the acromion and scapula posterior translation, the coracoid process tip moves closer to the clavicle in an anterior-posterior plane. This ultimately reduces the suspension device tension subsequently permitting more anterior displacement of the clavicle on the acromion.

However, for double transclavicular transcoracoid (DT) repair, the tunnel position at the coracoid base during reconstruction, the results did not differ from the native CC ligaments. In fact, the DT repair at the base resulted in stiffness of the AC joint, demonstrating a 25% less horizontal displacement than that of intact CC ligaments. During DT repair, when the suspension device is placed at the coracoid base, the suture fibres are at their elongated position. As the acromion and scapula translate posteriorly during loading, there is an increase in tension of the suspension device suture fibres resulting in less translation of the lateral clavicle on the acromion.

Several studies have evaluated the native AC joint horizontal stability, with varying results (Deshmukh *et al.*, 2004; Jari *et al.*, 2004; Beitzel *et al.*, 2014; Saier *et al.*, 2015; Banffy *et al.*, 2018; Park *et al.*, 2018; Hislop *et al.*, 2018; Kurata *et al.*, 2021; Lee *et al.*, 2021). Banffy *et al.* (2018) demonstrated an anterior and posterior AC joint horizontal displacement baseline of 4.9

and 5.8mm, respectively; these authors used a load-controlled testing method set at 70N. With a similar load-controlled technique, Kurata et al. (2021) and Saier et al. (2015) results showed a mean AC joint horizontal displacement of 3.7 and 12.3mm, respectively, on the native AC joint. Deshmukh et al. (2004) measured the native AC joint horizontal laxity following a load of 100N, and their results showed a mean horizontal displacement of 8.8mm. Conversely, utilizing lower applied loads of 10N and 15N, Park et al. (2018) demonstrated a mean AC joint anterior and posterior displacement of 2.3 and 3.0mm, respectively. Using a 70N load, Beitzel et al. (2014) recorded a mean AC joint anterior translation of 6.6mm. The results of the current study, and under the defined parameters of the study, demonstrated a mean horizontal anterior displacement of around  $1.6 \pm 0.9$ mm for the 15 intact CC ligaments. These results are significantly lower than what has been reported in the literature as seen above. These varying results can possibly be attributed to the different biomechanical testing methods employed throughout all the mentioned studies. Interestingly, one study reported an anterior translation of 0.3mm (range 0-0.8mm) in the native AC joint with/without stress applied (Rochcongar *et al.*, 2012). They utilised ten shoulder specimens that underwent arthroscopic ligaments transection, displacement was measured on X-ray and using an optical tracking system. Following a traction load of 4kg on the acromion and a traction pulley mounted on the wall for anteroposterior traction, they observed an anterior translation of 3.1 mm and 7.1 mm following cutting of the AC and CC ligaments, respectively (Rochcongar *et al.*, 2012).

In this current study, the double-tunnel reconstruction demonstrated less AC joint horizontal (anterior) displacement than the single-tunnel reconstruction; however, the data showed that both reconstruction techniques maintained the AC joint horizontal (anterior) stability comparable to native ligaments. The double tunnel reconstructions at the base demonstrated a horizontal (anterior) displacement of  $1.2 \pm 0.7$ mm (compared to  $1.9 \pm 0.8$ mm horizontal displacement for single tunnel reconstruction at the base). Other researchers tested the efficacy

of single and double trans-clavicular tunnel reconstruction techniques with conflicting results (Beitzel *et al.*, 2012; Banffy *et al.*, 2018; Hislop *et al.*, 2018; Park *et al.*, 2018). Beitzel *et al.* (2012) in their biomechanical study, using a semitendinosus graft prepared and secured to the cortical button and the clavicle washer, concluded that single transclavicular and double transclavicular tunnel reconstructions resulted in similar AC joint horizontal stability to the native ligaments. Another biomechanical study used nine ( $n = 9$ ) matched shoulder specimen pairs divided into a single tunnel and a double tunnel CC ligament reconstruction group; using a semitendinosus graft with a suture tape to secure the graft around the coracoid process supported by a dog-bone button and PEEK tenodesis screw to secure the graft on the clavicle (Banffy *et al.*, 2018). The authors concluded that single tunnel CC ligament reconstruction demonstrated biomechanical properties equivalent to the double tunnel CC ligament reconstruction (Banffy *et al.*, 2018). Similarly, Hislop *et al.* (2018) in a biomechanical study, used 24 specimens randomised into three treatment groups: single clavicular tunnel, double clavicular tunnel, and double clavicular tunnel with the addition of an acromioclavicular suture group; they concluded that there is no difference in stiffness and stability between the single and double clavicular tunnel treatment groups.

However, Park *et al.* (2018) tested eight shoulder specimens ( $n = 8$ ) to biomechanically evaluate four different CC ligament reconstructions: single-bundle, double-bundle with anterolateral limb, and double-bundle with posterolateral limb triple-bundle technique using cortical fixation buttons with a suture tape. These authors reported that a double-bundle with a posterolateral limb, results in better horizontal stability than single-bundle reconstructions (Park *et al.*, 2018). It must be highlighted that the study by Park *et al.* (2018) included an additional implant across the AC joint during double-bundle reconstruction; this evidently increased the stability of the reconstruction.

The present study also looked at the coracoid tunnel position on the AC joint horizontal (anterior) stability following CC ligament reconstruction/repair. The coracoid process projects in an anterolateral direction from the superior part of the scapular neck; according to Rios et al. (2007) the coracoid processes mean length and width range from 43-45mm and 14-27.9mm, respectively. The coracoid process tunnel's orientation and position during AC joint reconstruction are crucial to achieving ideal biomechanical and functional outcomes (Barberis *et al.*, 2022). It has been suggested that the ideal position of the coracoid tunnel be centred at the coracoid base (Ferreira *et al.*, 2012). Two studies evaluated the coracoid process tunnel orientation and position during AC joint reconstruction (Ferreira *et al.*, 2012; Campbell *et al.*, 2015). Ferreira et al. (2012) used 42 specimens grouped into six, including the control group. The groups were based on the coracoid process's drill entry and exit points: centre-centre, centre-medial, centre-lateral, medial-centre, and medial-lateral. Following loading on the Hydropuls® machine, the control group without a coracoid tunnel had the highest ultimate load to failure ( $724.1 \pm 136.4\text{N}$ ). This was followed by the centre-centre and medial-centre groups having a significantly higher peak to load failure ( $538.8 \pm 145.2\text{N}$  and  $537.6 \pm 133.6\text{N}$  respectively) than the other tested groups with a  $p$  value  $< 0.5$ .

Additionally, the modes of failure for centre-centre and medial-centre groups were the least associated with bone failure (Ferreira *et al.*, 2012). Campbell et al. also reported on coracoid tunnel size and location on the load to failure during AC joint reconstruction. They found that a centrally based tunnel provided greater strength than a distally placed coracoid tunnel (Campbell *et al.*, 2015). They also highlighted that a 4.5mm coracoid process tunnel provided greater fixation strength than a 6mm tunnel when using cortical button fixation during AC joint reconstruction (Campbell *et al.*, 2015). However, during their testing, the coracoid tunnel at the base of the coracoid process demonstrated a marked reduction in horizontal (anterior) displacement. Their. were comparable to our study. In the present study, testing both ST (single

transclavicular) and DT (double transclavicular) reconstruction, the coracoid tunnel location was altered from the base to 1:9 and 1:5 from the coracoid base. During ST reconstruction at the coracoid base, 1:9 and 1:5 from the coracoid base, the mean horizontal (anterior) displacement was  $1.9 \pm 0.8\text{mm}$ ,  $2.5 \pm 1.1\text{mm}$  and  $2.5 \pm 1.1\text{mm}$ , respectively. While for DT reconstruction, the mean horizontal (anterior) displacement was  $1.2 \pm 0.7\text{mm}$ ,  $2.0 \pm 1.2\text{mm}$  and  $1.9 \pm 1.2\text{mm}$  at the coracoid base, 1:9 and 1:5 from the coracoid base, respectively. The results showed that the coracoid tunnel position during ST and DT AC joint reconstruction has no marked difference in horizontal (anterior) displacement. However, similar to Campbell et al., the DT reconstruction at the base demonstrated a marked reduction in horizontal (anterior) displacement than the native AC joint (i.e., 25% less horizontal anterior displacement in the present study).

Although the current study did not perform load-to-failure testing on the specimens, two studies reported no difference in the load-to-failure test between single and double transclavicular tunnel AC joint reconstructions (Beitzel *et al.*, 2012; Hislop *et al.*, 2018). Beitzel et al., in their biomechanical study evaluating three techniques for CC ligament reconstruction. They concluded that single transclavicular and double transclavicular methods demonstrated maximal load to failure similar to native ligaments. Hislop et al. found no difference in ultimate strength between single and double transclavicular reconstruction techniques (Hislop *et al.*, 2018).

## 5.2 Coracoclavicular ligament repair: Clinical application

Failure to recognise horizontal instability and address it during surgery, often results in poor clinical outcomes (Scheibel *et al.*, 2011; Tauber *et al.*, 2016; Cisnero and Reiriz, 2017; Minkus

*et al.*, 2017; Aliberti, 2020; Celik *et al.*, 2020). Scheibel *et al.* (2011) performed a prospective study trial and evaluated clinical and radiological outcomes following acute AC joint repairs. The authors demonstrated substantially lower clinical outcome scores associated with poor clinical outcomes if there was evidence of horizontal instability on radiographic Alexander views during follow-up. They also reported persistent posterior instability in 43% of cases, despite using double TightRope repair techniques. Cisneros and Reiriz (2017) also determined the prevalence of horizontal instability and its relation to clinical scores following AC joint injuries that were surgically managed. They surgically treated (open or arthroscopically) 53 patients with high-grade AC joint injuries. Eighteen percent (18%) of the patients demonstrated remaining horizontal instability at the final follow-up. This group also showed a significantly worse clinical outcome score. It must nevertheless be highlighted that quantifying the horizontal instability of the AC joint in clinical practice (Aliberti *et al.*, 2020) and addressing it is not without challenges. Horizontal instability of the AC joint is poorly defined on anteroposterior Zanca or axillary lateral views (Aliberti *et al.*, 2020). The latter reported that using supine dynamic axillary lateral shoulder views and 10 to 15° cephalad Zanca views is better for assessing horizontal instability.

Clinical studies evaluating AC joint horizontal stability following CC ligament reconstruction with augmentation of the AC joint reported improved horizontal stability (Jensen *et al.*, 2013; Tauber *et al.*, 2016; Hann *et al.*, 2018). Jensen *et al.* (2013) evaluated a series of sixteen patients (n = 16) with chronic symptomatic AC joint instability, following arthroscopically assisted stabilization with a GraftRope device. They concluded that an additional AC joint transacromial horizontal tendon augmentation leads to good clinical and sonographic outcomes following CC ligament reconstruction. Tauber *et al.* (2016) reported similar satisfactory clinical scores; in particular, stabilization of the AC joint with a graft restored horizontal stability. The different surgical techniques to solve persistent AC joint horizontal instability have also been

biomechanically tested with conflicting results (Freedman *et al.*, 2010; Saier *et al.*, 2015; Hislop *et al.*, 2018; Theopold *et al.*, 2019). Saier *et al.* (2015) used 12 shoulder specimens to evaluate the value of additional AC joint suture tape on the anatomical CC ligament reconstruction. Horizontal stability was tested with a servo-hydraulic testing machine; they concluded that combining AC and CC ligament reconstruction adequately re-establishes physiological AC joint horizontal stability. Freedman *et al.* (2010) conducted a biomechanical study on six matched pairs of shoulder specimens using an intramedullary free semitendinosus graft to reconstruct the AC ligaments. They concluded that additional intramedullary graft improves horizontal stability (Freedman *et al.*, 2010).

In contrast, Theopold *et al.* (2019) found no difference in the AC joint horizontal stability with additional acromioclavicular cerclage following the double coracoclavicular tunnel technique. Hislop *et al.* (2018) also found that adding a suture across the AC joint has no added improvement in the horizontal stability. Using stiffness as the primary outcome measure to evaluate joint stability, their results demonstrated that adding an implant/structure around the AC joint offered only 39% of the native joint stiffness. It must be highlighted that none of the studies above remarked on the variable AC joint morphology. The AC joint articular surface has a variable inclination with flat, oblique, and curved types (Phadke, 2019). Forces distributed through the joint may not be similar with different inclinations and this may possibly influence the horizontal stability. This study did not assess the effect of AC joint slope on horizontal stability. Therefore, the current clinical and biomechanical data is inconclusive regarding the augmentation of the AC joint to achieve horizontal stability.

Arthroscopically assisted AC joint reconstructions have gained popularity lately (Koh *et al.*, 2018). The advantages of a smaller, minimally invasive surgical wound and reduced soft tissue dissection are mentioned in the literature (Spoliti *et al.*, 2014). The ability to do diagnostic arthroscopy and treatment of concomitant pathologies adds to its advantage. Complications

associated with this surgical technique include clavicle fracture, coracoid process fracture, loss of reduction, migration of the endobutton and osteolysis of the distal clavicle (Clavert *et al.*, 2015; Shin and Kim, 2015; Gowd *et al.*, 2018). The risk of clavicle and coracoid process fracture is influenced by the number and size of tunnels drilled (Martetschlager *et al.*, 2016).

Additionally, performing a single-stage transclavicular-transcoracoid tunnel drilling is associated with a significant risk of a coracoid cortical breach (Coale *et al.*, 2013; Koh *et al.*, 2018). Koh *et al.* used 12 fresh-frozen shoulder cadavers to simulate the transclavicular-transcoracoid tunnel drilling technique. They had a medial cortical breach of the coracoid process in 50% of their specimens and concluded that the technique would not be feasible without a coracoid process fracture (Koh *et al.*, 2018). Considering the risk of neurovascular injury with coracoid process medial cortex breach/fracture, independent clavicle and coracoid process drilling techniques should be considered as an alternative. Furthermore, looking at the results of this current study, the position of the trans-coracoid tunnel concerning the CC ligaments' coracoid footprint did not affect the horizontal (anterior) displacement. Therefore, during arthroscopic assisted CC ligament reconstruction, the placement of a coracoid tunnel on the CC ligaments footprint may not be critical.

## 5.2 Study limitations and future recommendations

The current study has several limitations: the sample size of 15 specimens underpowered the study. Due to the inherent nature of biomechanical studies, the clinical relevance of our study may not be applicable *in vivo* and is limited by the parameters set out in the study. Nonetheless, a clinical study on clavicular and scapular motion during shoulder abduction by Sahara *et al.* demonstrated results close to the current research, with an anterior translation of 1.6mm (Sahara *et al.*, 2006).

The role of other AC joint stabilizers, including the trapezius muscles, deltoid muscle and the deltotrapezial fascia, could not be tested. Furthermore, the fixation of the specimen on the jig may allow minute movements during testing, thereby reducing the overall displacement at the AC joint. However, no load-to-failure tests were performed during the study, reducing the likelihood of specimen jig interface movements. This study's surgical technique may apply only to acute injuries since we did not use allograft for ligament reconstruction. Despite clinical and radiographic findings that AC joint disruption results in horizontal instability and clinical studies confirming that several surgical reconstruction techniques can restore horizontal stability, clinical assessment of horizontal anterior-posterior clavicle displacement is still challenging and unreliable. The cross-body, Speed and O'Brien tests are special tests used to accentuate pain originating from the AC joint. Still, these tests are not specific to horizontal instability (Mowbray *et al.*, 2021). A more specific test for AC joint horizontal instability is described by Irlenbuschet and co-workers. In this test, the lateral end of the clavicle is grasped by the examiner's fingers and moved in an anterior-posterior plane. The other hand is fixing the acromion and an increase in horizontal movement of the lateral clavicle on the acromion is compared to the contralateral side (Irlenbuschet *et al.*, 2012).

One of the strengths of this biomechanical study was the ability to test the intact, transected, and reconstructed CC ligaments without altering the initial mounting position of the specimens. Additionally, to measure the AC joint horizontal displacement TEMA motion analysis software was utilised. This allowed for non-contact measurements and analysis of the AC joint without altering these outcomes through physical contact.

The current study setup and the vertical limb of the Hydropuls® machine mimicked the in vivo force application during AC joint dislocation. During AC joint dislocation the scapula and acromion translate in a horizontal plane around the distal clavicle (Celik *et al.*, 2020).

Based on the current findings on AC joint horizontal (anterior) displacement, the following needs to be further investigated:

- The effect of the AC joint slope on the horizontal stability during CC ligament repair/reconstruction.
- The biomechanical effects of the coracoid tunnel position on the AC joint vertical and rotational stability.
- Coracoid tunnel position effect on the AC joint horizontal posterior stability.

## **Chapter 6 : CONCLUSION**

Disruption of the AC joint capsule and CC ligaments results in 100% horizontal displacement of the clavicle. Both single and double clavicle tunnel and single coracoid tunnel reconstruction restored horizontal instability to its native state. However, single button and single clavicle tunnel placement at the coracoid base resulted in 15% more horizontal displacement when compared to the intact CC ligaments. In contrast, double tunnel and double button reconstruction with coracoid tunnel placement at the coracoid base caused over-constraint with a reduction of 25% clavicular movements. The results of this study suggest that with a single button, single coracoid button surgical reconstruction, the coracoid tunnel should be placed close to the coracoid base. However, when using a double button, double clavicle tunnel surgical reconstruction, the coracoid tunnel should not be placed at the coracoid base as this causes over-constraint. This study suggests that position of the coracoid tunnel during the arthroscopic assisted reconstruction of the CC ligaments be placed 1:9 to 1:5 anterior to the coracoid base.

## REFERENCE LIST

Aliberti, G.M., Kraeutler, M.J., Trojan, J.D., Mulcahey, M.K. 2020. Horizontal instability of the acromioclavicular joint: A systematic review. *Am J Sports Med.* 48(2):504-510.

Allman, F.L. 1967. Fractures and ligamentous injuries of the clavicle and its articulation. *J. Bone Jt. Surg.* 49(4):774-784.

Assaghir, Y.M. 2011. Outcome of exact anatomic repair and coracoclavicular cortical lag screw in acute acromioclavicular dislocations. *J Trauma.* 71(3):E50-4.

Balsler, D. 1976. Eine neue. Moethode zur operative Behandlung der akromioklavikularen Luxation. *Chir Prax.* 24:275-81.

Banffy, M.B., Uquillas, C., Neumann, J.A., ElAttrache, N.S. 2018. Biomechanical evaluation of a single- versus double-tunnel coracoclavicular ligament reconstruction with acromioclavicular stabilization for acromioclavicular joint injuries. *Am J Sports Med.* 46(5):1070-1076.

Barberis, L., Faggiani, M., Calò, M.J., Marenco, S., Vasario, G., Castoldi, F. 2022. Coracoid tunnels in open and arthroscopic treatment of acromioclavicular dislocation: An experimental cadaveric study. *Musculoskelet Surg.* 106(1):15-19.

Bearden, J.M., Hughston, J.C., Whatley, G.S. 1973. Acromioclavicular dislocation: Method of treatment. *Am J Sports Med.* 1(4):5-17.

Beitzel, K., Cote, M.P., Apostolakos, J., Solovyova, O., Judson, C.H., Ziegler, C.G., et al. 2013. Current concepts in the treatment of acromioclavicular joint dislocations. *Arthroscopy*. 29(2):387-397.

Beitzel, K., Obopilwe, E., Apostolakos, J., Cote, M.P., Russell, R.P., Charette, R., et al. 2014. Rotational and translational stability of different methods for direct acromioclavicular ligament repair in anatomic acromioclavicular joint reconstruction. *Am J Sports Med*. 42(9):2141-2148.

Beitzel, K., Mazzocca, A.D., Bak, K., Itoi, E., Kibler, W.B., Mirzayanet, R. 2014. ISAKOS upper extremity committee consensus statement on the need for diversification of the Rockwood classification for acromioclavicular joint injuries. *Arthroscopy*. 30(2):271-278.

Beris, A., Lykissas, M., Kostas-Agnantis, I., Vekris, M., Mitsionis, G., Korompilias, A. 2013. Management of acute acromioclavicular joint dislocation with a double-button fixation system. *Injury*. 44(3):288–292.

Boehm, T.D., Kirschner, S., Fischer, A., Gohlke, F. 2003. The relation of the coracoclavicular ligament insertion to the acromioclavicular joint: A cadaver study of relevance to lateral clavicle resection. *Acta Orthop Scand*. 74(6):718–721.

Boffano, M., Mortera, S., Wafa, H., Piana, R. 2017. The surgical treatment of acromioclavicular joint injuries. *EFORT Open Rev*. 2(10):432–437.

Boström Windhamre, H.A., von Heideken, J.P., Une-Larsson, V.E., Ekelund, A.L. 2010. Surgical treatment of chronic acromioclavicular dislocations: A comparative study of Weaver-Dunn augmented with PDS-braid or hook plate. *J Shoulder Elbow Surg*. 19(7):1040-1048.

Bosworth, B. 1941. Acromioclavicular separation: a new method of repair. *Surg Gynecol Obstet*. 73:866–871.

Braun, S., Imhoff, A.B., Martetschlaeger, F. 2014. Primary fixation of acromioclavicular joint disruption. *Oper Tech Sports Med.* 22(3):221-226.

Bulkmans, K., Peeters, I., De Wilde, L., Van Tongel, A. 2020. The relationship of the acromion to the distal clavicle in normal and symptomatic degenerated acromioclavicular joints. *Arch Orthop Trauma Surg.* 140(4):465–472.

Cadenat, F. 1917. The treatment of dislocations and fractures of the outer end of the clavicle. *Int Clin.* 1:145-169.

Campbell, S.T., Heckmann, N.D., Shin, S.J., Wang, L.C., Tamboli, M., Murachovsky, J., et al. 2015. Biomechanical evaluation of coracoid tunnel size and location for coracoclavicular ligament reconstruction. *Arthroscopy.* 31(5):825- 830.

Carofino, B.C., Mazzocca, A.D. 2010. The anatomic coracoclavicular ligament reconstruction: surgical technique and indications. *J Shoulder Elbow Surg.* 19(2):37–46.

Celik, H., Chauhan, A., Flores-Hernandez, C., Dorthe, E., Goodine, T., D'Lima, D., et al. 2020. Vertical and rotational stiffness of coracoclavicular ligament reconstruction: A biomechanical study of 3 different techniques. *Arthroscopy.* 36(5):1264-1270.

Chernchujit, B., Artha, A. 2020. High grade acromioclavicular injury: Comparison of arthroscopic assisted acromioclavicular joint fixation and anatomic acromioclavicular joint reconstruction. *J. Orthop.* 22:151–157.

Cisneros, L.N., Reiriz, J.S. 2017. Prevalence of remaining horizontal instability in high-grade acromioclavicular joint injuries surgically managed. *Eur J Orthop Surg Traumatol.* 27(3):323–333.

Cisneros, L.N., Reiriz, J.S., Besalduch, M., Petrica, A., Escola, A., Rodriguez, J., et al. 2015. Horizontal and vertical stabilization of acute unstable acromioclavicular joint injuries arthroscopy-assisted. *Arthrosc Tech.* 4(6):e721-e729.

Claverta, P., Meyerb, A., Boyerc, P., Gastaud, O., Barthe, J., Duparc, F. 2015. Complication rates and types of failure after arthroscopic acute acromioclavicular dislocation fixation. Prospective multicenter study of 116 cases. *Orthop. Traumatol.: Surg. Res.* 101(8):S313–S316.

Coale, R., Hollister, S.J., Dines, J.S., Allen, A.A., Bedi, A. 2013. Anatomic considerations of transclavicular-transcoracoid drilling for coracoclavicular ligament reconstruction. *J Shoulder Elbow Surg.* 22(1):137-144.

Colegate-Stone, T., Allom, R., Singh, R., Elias, D.A., Standring, S., Sinha, J. 2010. Classification of the morphology of the acromioclavicular joint using cadaveric and radiological analysis. *J Bone Joint Surg Br.* 92(5):743-746.

Collins, D.N. Disorders of the acromioclavicular joint. In: Rockwood CA, Wirth MA, Lippitt SA, editors. *The shoulder.* 4th edition. Philadelphia: Saunders; 2009. p. 453–526.

Cook, J.B. and Krul, K.P. 2018. Challenges in treating acromioclavicular separations: Current concepts. *J Am Acad Orthop Surg.* 26(19):669-677.

Costic, R.S., Labriola, J.E., Rodosky, M.W., Debski, R.E. 2004. Biomechanical rationale for development of anatomical reconstructions of coracoclavicular ligaments after complete acromioclavicular joint dislocations. *Am J Sports Med.* 32(8):1929-36.

Crammond, G., Boyd, S.W., Dulieu-Barton, J.M. 2013. Speckle pattern quality assessment for digital image correlation. *Opt Lasers Eng.* 51(12):1368–1378.

Debski, R.E., Parsons 4th IM, Woo SL, Fu FH. 2001. Effect of capsular injury on acromioclavicular joint mechanics. *J Bone Joint Surg Am.* 83(9):1344–1351.

DePalma, A.F. 1963. Surgical anatomy of the acromioclavicular and sternoclavicular joints. *Surg Clin North Am.* 43:1540-1550.

Deshmukh, A.V., Wilson, D.R., Zilberfarb, J.L., Perlmutter, G.S. 2004. Stability of acromioclavicular joint reconstruction biomechanical testing of various surgical techniques in a cadaveric model. *Am J Sports Med.* 32(6):1492-1498.

Dolan, C.M., Hariri, S., Hart, N.D., McAdams, T.R. 2011. An anatomic study of the coracoid process as it relates to bone transfer procedures. *J Shoulder Elbow Surg.* 20(3):497-501.

Dumonski, M., Mazzocca, A.D., Rios, C., Romeo, A.R., Arciero, R.A. 2004. Evaluation and management of acromioclavicular joint injuries. *Am J Orthop (Belle Mead NJ).* 33(10):526-32.

Dyrna, F.G.E., Imhoff, F.B., Voss, A., Braun, S., Obopilwe, E., Apostolakos, J.M., et al. 2018. The integrity of the acromioclavicular capsule ensures physiological centering of the acromioclavicular joint under rotational loading. *Am J Sports Med.* 46(6):1432-1440.

Ferreira, J.V., Chowaniec, D., Obopilwe, E., Nowak, M.D., Arciero, R.A., Mazzocca, A.D. 2012. Biomechanical Evaluation of Effect of Coracoid Tunnel Placement on Load to Failure of Fixation During Repair of Acromioclavicular Joint Dislocations. *Arthroscopy.* 28(9):1230-1236.

Flinkkila, T.E., Ihanainen E. 2013. Results of arthroscopy-assisted tightrope repair of acromioclavicular dislocations. *Shoulder Elbow.* 6(1): 18–22.

Francesco, A. Zoccali, C., Colafarina, O., Pizzoferrato, R., Flamini, S. 2012. The use of hook plate in type III and V acromioclavicular Rockwood dislocations: Clinical and radiological midterm results and MRI evaluation in 42 patients. *Injury.* 43(2):147-152.

Fraser-Moodie, J.A., Shortt, N.L., Robinson, C.M. 2008. Injuries to the acromioclavicular joint. *J Bone Joint Surg [Br]*. 90(6):697-707.

Freedman, J.A., Adamson, G.J., Bui, C., Lee, T.Q. 2010. Biomechanical evaluation of the acromioclavicular capsular ligaments and reconstruction with an intramedullary free tissue graft. *Am J Sports Med*. 38(5):958-964.

Fukuda, K., Craig, E.V., An, K.N., Cofield, R.H., Chao, E.Y.S. 1986. Biomechanical study of the ligamentous system of the acromioclavicular joint. *J Bone Joint Surg Am*. 68(3):434-439.

Grutte, P.W., Petersen, S.A. 2005. Anatomical acromioclavicular ligament reconstruction a biomechanical comparison of reconstructive techniques of the acromioclavicular joint. *Am J Sports Med*. 33(11):1723-1728.

Gumina, S., Carbone, S., Postacchini, F. 2009. Scapular dyskinesis and SICK scapula syndrome in patients with chronic type III acromioclavicular dislocation. *Arthroscopy*. 25(1):40-5.

Gonzalez-Lomas, G., Javidan, P., Lin, T., Adamson, G.J., Limpisvasti, O., Lee, T.Q. 2010. Intramedullary acromioclavicular ligament reconstruction strengthens isolated coracoclavicular ligament reconstruction in acromioclavicular dislocations. *Am J Sports Med*. 38(10):2113-2122.

Goodine, T., Celik, H., Flores-Hernandez, C., D'Lima, D., Hoenecke, H. 2022. Combination of surgical techniques restores multidirectional biomechanical stability of acromioclavicular joint. *Arthroscopy*. 38(6):1774-1783.

Gowd, A.K., Liu, J.N., Cabarcas, B.C., Cvetanovich, G.L., Garcia, G.H., Manderle, B.J., et al. 2019. Current concepts in the operative management of acromioclavicular dislocations. *Am J Sports Med*. 47(11):2745–2758.

- Gstettner, C., Tauber, M., Hitzl, W., Resch, H. 2008. Rockwood type III AC dislocation: Surgical versus conservative treatment. *J Shoulder Elbow Surg.* 17(2):220-225.
- Hann, C., Kraus, N., Minkus, M., Maziak, N., Scheibel, M. 2018. Combined arthroscopically assisted coracoacromioclavicular stabilization of acute high-grade acromioclavicular joint separations. *Knee Surg Sports Traumatol Arthrosc.* 26(1):212–220.
- Harris, R.I., Vu, D.H., Sonnabend, D.H., Goldberg, J.A., Walsh, W.R. 2001. Anatomic variance of the coracoclavicular ligaments. *J Shoulder Elbow Surg.* 10(6):585-8.
- Harris, R.I., Wallace, A.L., Harper, G.D., Goldberg, J.A., Sonnabend, D.H., Walsh, W.R. 2000. Structural properties of the intact and the reconstructed coracoclavicular ligament complex. *Am J Sports Med.* 28(1):103-108.
- Hohmann, E., Tetsworth, K., Glatt, V. 2019. Open versus arthroscopic acromioclavicular joint resection: A systematic review and meta-analysis. *Arch Orthop Trauma Surg.* 139(5):685-694.
- Hislop, P., Sakata, K., Ackland, D.C., Gotmaker, R., Evans, M.C. 2018. Acromioclavicular joint stabilization a biomechanical study of bidirectional stability and strength. *Orthop. J. Sports Med.* 7(4):1-7.
- Irlenbusch, U. 2012. Acromioclavicular joint examination. *Obere Extremitat.* 7. 60-62.
- Jari, R., Costic, R.S., Rodosky, M.W., Debski, R.E. 2004. Biomechanical function of surgical procedures for acromioclavicular joint dislocations. *Arthroscopy.* 20(3):237-245.
- Jensen, G., Katthagen, J.C., Alvarado, L., Lill, H., Voigt, C. 2013. Arthroscopically assisted stabilization of chronic AC-joint instabilities in GraftRope™ technique with an additive horizontal tendon augmentation. *Arch Orthop Trauma Surg.* 133(6):841-51.

Johansen, J.A., Grutter, P.W., McFarland, E.G., Petersen, S.A. 2011. Acromioclavicular joint injuries: Indications for treatment and treatment options. *J Shoulder Elbow Surg.* 20(2):S70-S82

Jordan, R.W., Malik, S., Bentick, K., Saithna, A. 2019. Acromioclavicular joint augmentation at the time of coracoclavicular ligament reconstruction fails to improve functional outcomes despite significantly improved horizontal stability. *Knee Surg. Sports Traumatol. Arthrosc.* 27(12):3747–3763.

Keener, J. 2014. Acromioclavicular joint anatomy and biomechanics. *Oper Tech Sports Med* 22(3):210-213.

Kibler, W.B., Sciascia, A.D., Morris, B.J., Dome, D.C. 2017. Treatment of symptomatic acromioclavicular joint instability by a docking technique: Clinical indications surgical technique and outcomes. *Arthroscopy.* 33(4):696-708.

Kienast, B., Thietje, R., Queitsch, C., Gille, J., Schulz, A., Meiners, J. 2011. Midterm results after operative treatment of Rockwood grade III-V acromioclavicular joint dislocations with an AC-hook-plate. *Eur J Med Res.*16(2):52-56.

Kim, S., Blank, A., Strauss, E. 2014. Management of type 3 acromioclavicular joint dislocations: Current controversies. *Bull Hosp Jt Dis.* 72(1):53-60.

Klimkiewics, J.J., Williams, G.R., Sher, J.S., Karduna, A., Des Jardins, J., Iannotti, J.P. 1999. The acromioclavicular capsule as a restraint to posterior translation of the clavicle: A biomechanical analysis. *J Shoulder Elbow Surg.* 8(2):119–24.

Koh, K.H., Shon, M.S., Choi, N.H., Lim, T.K. 2018. Anatomic tunnel placement is not feasible by transclavicular-transcoracoid drilling technique for coracoclavicular reconstruction: A cadaveric study. *Arthroscopy.* 34(7):2012-2017.

Kurata, S., Inoue, K., Hasegawa, H., Shimizu, T., Iida, A., Kawamura, K. 2021. The role of the acromioclavicular ligament in acromioclavicular joint stability. A cadaveric biomechanical study. *Orthop. J. Sports Med.* 9(2):1-6.

Landermann, A., Grosclaude, M., Lunbbekem, A., Christofilopoulos, P., Stern, R., Rod, T. 2011. Acromioclavicular and coracoclavicular cerclage reconstruction for acute acromioclavicular joint dislocations. *J Shoulder Elbow Surg.* 20(3):401-408.

Landermann, A., Gueorguiev, B., Stimec, B., Fasel, J., Rothstock, S., et al. 2013. Acromioclavicular joint reconstruction: a comparative biomechanical study of three techniques. *J Shoulder Elbow Surg.* 22(2):171-178.

Lee, S., Bedi, A. 2016. Shoulder acromioclavicular joint reconstruction options and outcomes. *Curr Rev Musculoskelet Med.* 9(4):368-377.

Lee, J., El-Daou, H., Alkoheji, M., Carlos, A., Di Mascio, L., Amis, A. 2021. Ligamentous and capsular restraints to anteriorposterior and superior-inferior laxity of the acromioclavicular joint: A biomechanical study. *J Shoulder Elbow Surg.* 30(6), 1251-1256.

Lee, S.J., Nicholas, S.J., Akizuki, K.H., McHugh, M.P., Kremenec, I.J., Ben-Avi, S. 2003. Reconstruction of the coracoclavicular ligaments with tendon grafts: A comparative biomechanical study. *Am J Sports Med.* 31(5):648-655.

Li, X., Ma, R., Bedi, A., Dines, D., Altchek, D., Dines, J. 2014. Management of acromioclavicular joint injuries. *J Bone Joint Surg Am.* 96(1):73-84.

Liu, H.H., Chou, Y.J., Chen, C.H., Chia, W.T., Wong, C.Y. 2010. Surgical treatment of acute acromioclavicular joint injuries using a modified Weaver-Dunn procedure and clavicular hook plate. *Orthopedics.* 33(8).

Ludewig, P.M., Phadke, V., Braman, J.P., Hassett, D.R., Cieminski, C.J., LaPrade, F.R. 2009. Motion of the shoulder complex during multiplanar humeral head elevation. *JBJS Am.* 91(2):378-389.

Ludewig, P.M., Behrens, S.A., Meyer, S.M., Spoden, S.M., Wilson, L.A. 2004. Three-dimensional clavicular motion during arm elevation: Reliability and descriptive data. *J Orthop Sports Phys Ther.* 34(3):140-149.

Ma, R., Smith, P.A., Smith, M.J., Sherman, S.L., Flood, D., Li, X. 2015. *Curr Rev Musculoskelet Med.* 8(1): 75-82.

Martetschlager, F., Horan, M.P., Warth, R.J., Millett, P.J. 2013. Complications after anatomic fixation and reconstruction of the coracoclavicular ligaments. *Am J Sports Med.* 41(12):2896-2902.

Mazzocca, A.D., Santangelo, S.A., Johnson, S.T., Rios, C.G., Dumonski, M.L., Arciero, R.A. 2006. A biomechanical evaluation of an anatomical coracoclavicular ligament reconstruction. *Am J Sports Med.* 34(2):236-246.

Michlitsch, M.G., Adamson, G.J., Pink, M., Estess, A., Shankwiler, J.A., Lee, T.Q. 2010. Biomechanical comparison of a modified Weaver-Dunn and a free-tissue graft reconstruction of the acromioclavicular joint complex. *Am J Sports Med.* 38(6):1196-1203.

Mikek, M. 2008. Long-term shoulder function after type I and II acromioclavicular joint disruption. *Am J Sports Med.* 36(11):2147-50.

Millet. P.J., Horan, M.P., Warth, R.J. 2015. Two-year outcomes after primary anatomic coracoclavicular ligament reconstruction. *Arthroscopy.* 31(10):1962-1973.

Minkus, M., Hann, C., Scheibel, M., Kraus, N. 2017. Quantification of dynamic posterior translation in modified bilateral Alexander views and correlation with clinical and radiological

parameters in patients with acute acromioclavicular joint instability. *Arch Orthop Trauma Surg.* 137(6):845–852.

Modi ,C.S., Beazley, J., Zywiell, M.G., Lawrence, T.M., Veillette, C.J.H. 2013. Controversies relating to the management of acromioclavicular joint dislocations. *Bone Joint J.* 95-B(12):1595–1602.

Moore, K.L., Dalley A.F. & Agur, A. 2013. *Clinically Oriented Anatomy.* 7th ed. Philadelphia, PA: Lippincott Williams and Wilkins.

Motamedi, A.R., Blevins, F.T., Willis, M.C., McNally, T.P., Shahinpoor, M. 2000. Biomechanics of the coracoclavicular ligament complex and augmentations used in its repair and reconstruction. *Am J Sports Med.* 28(3):380-384.

Morikawa, D., Dyrna, F., Cote, M.P., Johnson, J.D., Obopilwe, E., Imhoff, F.B., et al. 2019. Repair of the entire superior acromioclavicular ligament complex best restores posterior translation and rotational stability. *Knee Surg Sports Traumatol Arthrosc.* 27(12):3764-3770.

Mouhsine, E., Garofalo, R., Crevoisier, X., Farron, A. 2003. Grade I and II acromio clavicular dislocations: Results of conservative treatment. *J Shoulder Elbow Surg.* 12(6):599-602.

Mowbray, J.L., Moreno, G., Albers, C.G.M., Poon, P. 2021. The reverse coracoacromial ligament transfer for “horizontal” acromioclavicular joint instability. *JSES Reviews, Reports, and Techniques* 1:381-388.

Nordin, J.S., Olsson, O., Luns, K. 2020. Acromioclavicular joint dislocations: incidence, injury profile, and patient characteristics from a prospective case series. *JSES Int.* 4(2):246-250.

Park, I., Itami, Y., Hedayati, B., Bitner, B., McGarry, M.H., Lee, T.Q., et al. 2018. Biomechanical analysis of single-, double-, and triple-bundle configurations for

coracoclavicular ligament reconstruction using cortical fixation buttons with suture tapes: A cadaveric study. *Arthroscopy*. 34(11):2983-2991.

Pastor, M.F., Averbeck, A.K., Welke, B., Smith, T., Claassen, L., Wellmann, M. 2016. The biomechanical influence of the deltotrapezoid fascia on horizontal and vertical acromioclavicular joint stability. *Arch Orthop Trauma Surg*. 136(4):513–519.

Phadke, A., Bakti, N., Bawale, R., Singh, B. 2019. Current concepts in management of acromioclavicular joint injuries. *J Clin Orthop Trauma*. 10(3):480-485.

Radhakrishnan, G., Henderson, D. 2020. Injuries of the acromioclavicular joint. *Orthop Trauma*. 33(5):276-282.

Renfree, K.J., Riley, M.K., Wheeler, D., Hentz, J.G., Wright, T.W. 2003. Ligamentous anatomy of the distal clavicle. *J Shoulder Elbow Surg*. 12(4):355-9.

Rios, C.G., Arciero, R.A., Mazzocca, A.D. 2007. Anatomy of the clavicle and coracoid process for reconstruction of the coracoclavicular ligaments. *Am J Sports Med*. 35(5):811-817.

Rochcongar, G., Emily, S., Lebel, B., Pineau, V., Burdin, G., Hulet, C. 2012. Measure of horizontal and vertical displacement of the acromioclavicular joint after cutting ligament using X-ray and opto-electronic system. *Surg Radiol Anat*. 34(7):639–643.

Rockwood, C.J. W.G., Young, D. 1998. Disorders of the acromioclavicular joint. In: Rockwood CJ (ed). *The Shoulder* (2nd ed). Philadelphia, PA: WB Saunders.

Sacomanno, M.F., Fodale, M., Capasso, L., Cazzato, G., Milano, G. 2014. Reconstruction of the coracoclavicular and acromioclavicular ligaments with semitendinosus tendon graft: A pilot study. *Joints*. 2(1):6-14.

- Sahara, W., Sugamoto, K., Murai, M., Tanaka, H., Yoshikawa, H. 2006. 3D Kinematic analysis of the acromioclavicular joint during arm abduction using vertically open MRI. *J Orthop Res.* 24(9):1823–1831.
- Schär, M.O., Jenni, S., Fessel, G., Snedeker, G.J., Scheibel, M., Zumstein, M.A. 2019. Biomechanical comparison of two biplanar and one monoplane reconstruction techniques of the acromioclavicular joint. *Arch Orthop Trauma Surg.* 139(6):779–786.
- Saier, T., Venjakob, A.J., Minzlaff, P., Föhr, P., Lindell, F., Imhoff, A.B., et al. 2015. Value of additional acromioclavicular cerclage for horizontal stability in complete acromioclavicular separation: A biomechanical study. *Knee Surg Sports Traumatol Arthrosc.* 23(5):1498-1505.
- Salter, E., Nasca, R., Shelley, B. 1987. Anatomic observations on the acromioclavicular joint and supporting ligaments. *Am J Sports Med.* 15(3):199-206.
- Salzmann, G.M., Paul, J., Sandmann, G.H., Imhoff, A.B., Schöttle, P.B. 2008. The coracoid insertion of the coracoclavicular ligaments an anatomic study. *Am J Sports Med.* 36(12):2392-2397.
- Salzmann, G.M., Walz, L., Buchmann, S., Glabgyl, P., Venjakob, A., Imhoff, A.B. 2010. Arthroscopically assisted 2-bundle anatomical reduction of acute acromioclavicular joint separations. *Am J Sports Med.* 38(6):1179-1187.
- Scheiderer, B., Obmann, S., Feucht, M.J., Siebenlist, S., Degenhardt, H., Imhoff, A.B., et al. 2022. The morphology of the acromioclavicular joint does not influence the postoperative outcome following acute stabilization: A case series of 81 patients. *ASMAR.* 4(3):835-842.
- Sellards, R. 2004. Anatomy and biomechanics of the acromioclavicular joint. *Oper. Tech. Sports Med.* 12(1):2-5.

Shin, S., Kim, N. 2015. Complications after arthroscopic coracoclavicular reconstruction using a single adjustable-loop-length suspensory fixation device in acute acromioclavicular joint dislocation. *Arthroscopy*. 31(5):816-824.

Simovitch, R., Sanders, B., Ozbaydar, M., Lavery, K., Warner, J.J. 2009. Acromioclavicular joint injuries: diagnosis and management. *J Am Acad Orthop Surg*. 17(4):207-219.

Spoliti, M., De Cupis, M., Via, A.G., Oliva, F. 2014. All arthroscopic stabilization of acute acromioclavicular joint dislocation with fiberwire and endobutton system. *Muscles, Ligaments and Tendons J*. 4(4):398-403.

Stine, I.A., Vangness Jr, C.T. 2009. Analysis of the capsule and ligament insertions about the acromioclavicular joint: A cadaveric study. *Arthroscopy*. 25(9):968-974.

Struhl, S., Wolfson, T.S., Kummer, F. 2016. Axial-plane biomechanical evaluation of 2 suspensory cortical button fixation constructs for acromioclavicular joint reconstruction. *Orthop. J. Sports Med*. 4(12):1-6.

Stucken, C., Cohen, S.B. 2015. Management of acromioclavicular joint injuries. *Orthop Clin North Am*. 46(1):57-66.

Tauber, M., Koller, H., Hitzl, W., Resch, H. 2010. Dynamic radiologic evaluation of horizontal instability in acute acromioclavicular joint dislocations. *Am J Sports Med*. 38(6):1188-1195.

Takase, K. 2010. The coracoclavicular ligaments: An anatomic study. *Surg Radiol Anat* 32(7):683–688.

Theopold, J., Schöbel, T., Fischer, J., Löffler, S., Osterhoff, G., Schleifenbaum, S., et al. 2019. Acromioclavicular joint reconstruction: An additional acromioclavicular cerclage does not improve horizontal stability in double coraco-clavicular tunnel technique. *Knee Surg Sports Traumatol Arthrosc*. 27(12):3827-3834.

Thomas, K., Litsky, A., Jones, G., Bishop, J.Y. 2011. Biomechanical comparison of coracoclavicular reconstructive techniques. *Am J Sports Med.* 39(4):804-810.

Tienen, T.G., Oyen, J.F., Eggen, P. 2003. A modified technique of reconstruction for complete acromioclavicular dislocation: a prospective study. *Am J Sports Med.* 31:655-659.

Tischer, T., Salzman, G.M., El-Azab, H., Vogt, S., Imhoff, A.B. 2009. Incidence of associated injuries with acute acromioclavicular joint dislocations types III through V. *Am J Sports Med.* 37(1):136-9.

Tossy, J.D., Mead, M.C., Sigmond, H.M. 1963. Acromioclavicular separations: Useful and practical classification for treatment. *Clin Orthop Relat Res.* 28:111- 119.

Urist, M.R. 1946. Complete dislocation of the acromioclavicular joint: The nature of the traumatic lesion and effective method of treatment with an analysis of forty-one cases. *J Bone Joint Surg.* 28:813-837.

Van Bergen, C.J., van Bommel, A.F., Alta, T.D.W., van Noort, A. 2017. New insights in the treatment of acromioclavicular separation. *WJO.* 8(12):861-873.

Verstift, D.E., Kilsdonk, I.D., van Wier, M.F., Haverlag, R., van den Bekerom, M.P.J. 2021. Long-term outcome after nonoperative treatment for Rockwood I and II acromioclavicular joint injuries. *Am J Sports Med.* 49(3):757-763.

Walz, L., Salzman, G.M., Fabbro, T., Eichhorn, S., Imhoff, A.B. 2008. The anatomic reconstruction of acromioclavicular joint dislocations using two TightRope devices: A Biomechanical study. *Am J Sports Med.* 36(12):2398-2406.

Weaver, J.K., Dunn, H.K. 1972. Treatment of acromioclavicular injuries, especially complete acromioclavicular separation. *J Bone Joint Surg Am.* 54(6):1187-1194.

Weinstein, D.M., McCann, P.D., McIlveen, S.J., Flatow, E.L., Bigliani, L.U. 1995. Surgical treatment of complete acromioclavicular dislocations. *Am J Sports Med.* 23(3):324-31.

Williams Jr, G.R., Nguyen, V.D., Rockwood Jr, C.A. 1989. Classification and radiographic analysis of acromioclavicular dislocations. *Appl Radiol.* 18(2):29-34.

Wright A.P., MacLeod, I.A.R., Talwalker, S. C. 2010. Disorders of the acromioclavicular joint and distal clavicle. *J. Orthop. Trauma.* 25(1):30-36.

Wylie, J.D., Johnson, J.D., DiVenere, J., Mazzocca, A.D. 2018. Shoulder Acromioclavicular and Coracoclavicular Ligament Injuries Common Problems and Solutions. *Clin Sports Med.* 37(2):197–207.

Xue, C., Zhang, M., Zheng, T., Zhang, G., Fu, P., Fang, J. et.al. 2013. Clavicle and coracoid process drilling technique for truly anatomic coracoclavicular ligament reconstruction. *Injury.* 44(10):1314-1320.

Yoo, J., Ahn, J., Yoon, J., Yang, J. 2010. Clinical results of single-tunnel coracoclavicular ligament reconstruction using autogenous semitendinosus tendon. *Am J Sports Med.* 38(5):950-957.

Zhu, N., Rui, B., Zhang, Y., Chen, Y. 2016. Anatomic study of coracoclavicular ligaments for reconstruction of acromioclavicular joint dislocations. *J Orthop Sci.* 21(6):749-752.

Zanca, P. 1971. Shoulder pain: involvement of the acromioclavicular joint. (Analysis of 1,000 cases). *Am J Roentgenol Radium Ther Nucl Med.* 112(3):493-506.