

**A study of sarcoid tumours in Cape
Mountain Zebra (*Equus zebra zebra*)**

by

Johan Marais

Submitted in partial fulfilment of the requirements
for the degree of

Master of Science

Companion Animal Clinical Studies
Faculty of Veterinary Science
University of Pretoria

Supervisor

Prof HJ Bertschinger

Co-supervisor

Prof JP Schoeman

November 2006

DECLARATION

I, Johan Marais, do hereby declare that the research presented in this dissertation, was conceived and executed by myself, and apart from the normal guidance from my supervisor, I have received no assistance.

Neither the substance, nor any part of this dissertation has been submitted in the past, or is to be submitted for a degree at this University or any other University.

This dissertation is presented in partial fulfilment of the requirements for the degree MSc in Companion Animal Clinical Studies.

I hereby grant the University of Pretoria free license to reproduce this dissertation in part or as whole, for the purpose of research or continuing education.

Signed

Johan Marais

Date

ACKNOWLEDGEMENTS

I would like to express my sincere gratitude to the following people:

Prof Henk Bertschinger, my supervisor, for his invaluable advice and encouragement during the project and in reading proof after proof of the journal article.

Prof Johan Schoeman, co-supervisor, for all his assistance and valuable editorial comment.

Professor Lucia Lange, for her assistance and interest in the fieldwork and for doing the histopathology on the samples.

Dr SP Sasidharan, for his support during sample collections.

SANPARKS and its conservation officials, especially Dr David Zimmerman, are thanked for their assistance in the procurement of the samples from Bontebok National Park.

Dr Pierre Nel from Gariiep Dam Nature Reserve for his valuable advice on this project.

The Faculty of Veterinary Science, University of Pretoria for providing funding for this project. The Equine Research Centre for providing a vehicle and the SAVF for funding laboratory costs for this project.

TABLE OF CONTENTS

	Page
Title page	01
Declaration	02
Acknowledgements	03
Table of Contents	04
List of Tables	06
List of Figures	06
List of Abbreviations	07
Summary	08
CHAPTER 1: INTRODUCTION	11
CHAPTER 2: LITERATURE REVIEW	13
2.1 Sarcoids in Domestic Horses	13
2.1.1. Prevalence	13
2.1.2 Aetiology	14
2.1.3 Distribution on the body	16
2.1.4 Clinical appearance	17
2.1.5 Histopathology	18
2.1.6 Differential diagnosis	20
2.1.7 Treatment	22
2.2 Sarcoids in Cape Mountain Zebra	26
2.2.1 Distribution of CMZ	26
2.2.2 Occurrence of sarcoids	27
CHAPTER 3: MATERIALS AND METHODS	28
3.1 Animals	28
3.1.1 Cape Mountain Zebra	28
3.1.2 Burchell's zebra	29
3.2 Observations	29
3.2.1 Cape Mountain Zebra	29
3.2.1.1 Immobilisation and identification	29
3.2.1.2 Prevalence of sarcoid	29
3.2.2 Burchell's zebra	30
3.2.2.1 Prevalence of sarcoid	30



3.3 Collection, processing and histological examination of suspected CMZ sarcoids	30
3.3.1 Specimen collection	30
3.3.2 Processing for histology	30
3.3.3 Histological evaluation of sarcoids	31
3.4 Treatment of sarcoids	31
3.4.1 Treatments	31
3.4.2 Assessment of treatment success	33
3.5 Data Analysis	33
CHAPTER 4: RESULTS	34
4.1 Cape Mountain Zebra	34
4.1.1 Prevalence	34
4.1.2 Distribution on the body	35
4.1.3 Clinical appearance	36
4.1.4 Treatment of sarcoids	37
4.1.5 Results of treatments after 18 months	40
4.2 Burchell’s zebra	41
4.2.1 Prevalence	41
4.2.2 Distribution on the body	42
4.3 Histopathology of suspected sarcoids in CMZ	42
CHAPTER 5: DISCUSSION	47
CHAPTER 6: CONCLUSIONS	56
REFERENCES	58
ADDENDUM I: SARCOID DATA COLLECTION SHEET	69

List of Tables

Table 1: CMZ with sarcoids in BNP, with reference to area affected.	34
Table 2: Age distribution of CMZ with sarcoid in BNP	35

List of Figures

Figure 1: Distribution of sarcoids on the body of CMZ in BNP	35
Figure 2: Clinical appearance of sarcoids in CMZ in BNP	36
Figure 3: A typical verrucous sarcoid (CMZ # Q 21)	36
Figure 4: A typical fibroblastic sarcoid. This CMZ stallion (# Q 6) had to euthanased	37
Figure 5: A typical nodular sarcoid (CMZ # Q 6)	37
Figure 6: Ulcerated, verrucous growth on the ventral abdomen of CMZ # Q 15	38
Figure 7: Appearance after resection of the sarcoid in CMZ # Q 15	38
Figure 8: Verrucous lesion on the medial aspect of the left axilla in CMZ # Q 18 that was treated with 5-Fluorouracil	39
Figure 9: Verrucous lesion present on the ventral abdomen of CMZ # Q 21 treated with autogenous vaccine	40
Figure 10: An example of the sarcoid-like growths that was observed in Burchell's zebra in Kruger National Park	42
Figure 11: Normal skin showing epidermis (E) and keratin layer (K) overlying the dermis (D) with all adnexal structures (hair follicles (F) with hair shafts (Sh), sebaceous glands (Se) and sweat glands (Sw)	43
Figure 12: Histopathology typical of sarcoid found in CMZ in BNP, showing epidermal hyperkeratosis, hyperplasia and rete peg formation. Note the spindle-shaped fibroblasts with interlacing and whorling collagen, replacing dermal adnexal structures (hair follicles, sweat and sebaceous glands)	44
Figure 13: Epidermal ulceration and necrosis with exudate, haemorrhage, bacterial infection and crust formation with a zone of granulation tissue interfacing the sarcoid below	45
Figure 14: Hyperplastic epidermis (HE) with hyperkeratosis (HK) and rete pegs (RP) extending into sarcoid (S) below with loss of adnexal structures	46
Figure 15: Fibroblastic sarcoid on sheath of a Burchell's zebra stallion	53

List of Abbreviations

BCG	Bacillus Calmette-Guerin
BZ	Burchell's Zebra
BNP	Bontebok National Park
BPV	Bovine papilloma virus
CITES	Convention on International Trade in Endangered Species of Wild Fauna and Flora
CMZ	Cape Mountain Zebra
CO₂	Carbon dioxide
DNA	Deoxyribonucleic acid
5 – FU	5-Fluorouracil
GDNR	Gariiep Dam Nature Reserve
IUCN	World Conservation Union
KNP	Kruger National Park
MHC	Major Histocompatibility complex
Nd:YAG lasers	Neodymium-doped yttrium aluminium garnet laser
PCR	Polymerase chain reaction
RNA	Ribonucleic acid
RT-PCR	Reverse Transcriptase polymerase chain reaction
SANParks	South African National Parks

SUMMARY

The Cape Mountain Zebra (CMZ) has been described as one of the most vulnerable mammals in the Republic of South Africa with current populations existing in isolated units. In recent years, South African conservation officials have noted the appearance of tumour like growths, similar to equine sarcoids, in some of these populations. The possibility that the existing populations, numbering around 1 500 animals in total, arose from a very small gene pool is very real, considering that in the early 1970's there were only 35 breeding animals in the Mountain Zebra National Park. A genetic component to the susceptibility to sarcoid tumour development has been identified in horses. Researchers have found an association between susceptibility to sarcoid and certain heritable cell-surface proteins called major histocompatibility antigens. Studies have reported the possibility of high levels of inbreeding in CMZ in the Bontebok National Park (BNP). The non-territorial social organisation of mountain zebras allows the population to increase to a high density within a relatively short period of time. These observations, coupled with the fact that there are no confirmed reports of sarcoids in the relatively outbred Burchell's zebra population in the Kruger National Park and the Hartmann's mountain zebra populations in Namibia, strongly support the hypothesis that a correlation exists between inbreeding in zebra populations and expression of sarcoids.

The small number of CMZ in BNP with an apparent high prevalence of suspected sarcoid tumours made this an ideal population to capture, identify and to study the skin tumour. The entire population of CMZ in the BNP was observed and sampled. A total of 15 CMZ was present in the Park at the time of the study. The individual animals were darted from a helicopter using M99®, Azaperone and Hyalase® after which a ground team moved in and covered their eyes and ears. Each animal was thoroughly examined for the presence of any

tumours; the distribution was recorded on a body chart and sizes and appearance were recorded. Anatomical location on the body was divided into head and neck, ventral abdomen and limbs. Biopsies were taken from all of the zebras with sarcoid-like growths. The sarcoids were either surgically excised or a representative biopsy was taken by means of 6mm biopsy punches. The samples were collected in 10% buffered formalin for histological examination.

The prevalence of sarcoid in CMZ in BNP was 53%. Of the affected animals, 50% had multiple tumours. The main predilection sites were on the trunk, followed by the limbs and then the head and neck. The severity of the lesions in one stallion was so extreme that it warranted euthanasia. The verrucous type, followed by much lower percentages of the fibroblastic and nodular types, dominated the clinical appearance. Lastly, the sarcoids examined showed either all or some of the typical epidermal and dermal histological features of equine sarcoid.

A total of 7 of the affected CMZ were treated using four different methods. The sarcoids were surgically excised (n = 2), treated with intra-lesional 5-fluorouracil (n = 2), autogenous vaccine (n = 2) or autogenous vaccine combined with 5-fluorouracil (n =1). The zebras were immobilised for examination 18 months later. One animal that had been treated with intralesional 5-fluorouracil only had large numbers of verrucous and fibroblastic sarcoids. Her condition was so severe that she had to be euthanased. No signs of sarcoids could be found anywhere on the remaining 6 treated CMZ.

This study confirmed that the growths in the CMZ in BNP population are indeed sarcoids and that many of them exhibit an aggressive nature. Sarcoid tumours is a disease that is considered multifactorial in aetiology and therefore other parameters such as immune status of

tumour-affected populations and associated environmental variables warrant further investigation.



CHAPTER 1

INTRODUCTION

Equine sarcoids are the most common skin tumour found in horses^{22,44,77}. The term sarcoid (meaning flesh-like) was first used by Jackson in 1936 to emphasize the clinical and pathological differences between papilloma, fibroma, and fibrosarcoma, and to suggest the malignant sarcomatous appearance of the lesions. He defined the sarcoid as “a unique locally invasive, benign neoplastic-like tumour of the skin with a variable epidermal component which has a high propensity for recurrence”. Sarcoids have been reported in horses, donkeys and mules^{27,61,66,81}. The pathological features of equine sarcoid are well recognized and have been well documented in the literature^{28,40,78}. Sarcoids are recognized as having six different clinical manifestations and can occur at any cutaneous site, although some predilection sites have been identified^{28,43,45,76}. A strong genetic predisposition has also been identified, with over 80 % of affected horses having MHC class-II alleles^{36, 47}.

There are no reports in the literature describing any tumours, and specifically sarcoids, in zebras. Recent unpublished reports from the Gariep Dam Nature Reserve (GDNR) and the Bontebok National Park (BNP) have identified numerous sarcoid-like growths in the Cape Mountain Zebra populations in these parks (D Zimmerman, personal communication; P Nel, personal communication). CMZ occur in isolated populations, numbering over 1 000 animals, spread among various national parks, reserves, private parks and zoos. Free State and Eastern Cape Nature Conservation have reported an increase in the incidence of “sarcoids” in their zebra populations in the GDNR, BNP and Commando Drift Nature Reserve. In the Free State (GDNR) extreme manifestations of the tumour have occurred. At the same time it has been reported that the morbidity in these populations is quite high and that a few mortalities, due to

severe lameness, have been attributed to these growths. A genetic component to the susceptibility to sarcoid tumour development has been identified in horses. Researchers found an association between susceptibility to sarcoid and certain heritable cell-surface proteins called major histocompatibility antigens⁴⁴. Genetic studies on two populations of CMZ in the GDNR and BNP revealed high levels of inbreeding (SP Sasidharan, Comparative genetics of selected Southern African Mountain Zebra populations, MSc, Faculty of Veterinary Science, 2005: pp 106).

To date, it has been assumed that the growths in these populations of CMZ are sarcoids, and no work has been done to refute or confirm this assumption. Due to the endangered status of the Cape Mountain Zebra, it is of utmost importance to identify and type this growth in order to be able to manage it accordingly, either now or in the future.

The aims of this descriptive study were to:

- Study the prevalence of sarcoids in a population of CMZ in the BNP and in a sample of outbred Burchell's zebra in the Kruger National Park.
- Describe the macroscopic appearance of the sarcoids in CMZ using the grading system of Knottenbelt⁶².
- Describe the distribution of the sarcoids on the body of CMZ.
- Describe the histological appearance of sarcoids in CMZ.

CHAPTER 2

LITERATURE REVIEW

2.1 Sarcoids in Domestic Horses

Sarcoid is worldwide in distribution and comprises the most common tumour in the horse^{44,67}. These tumours are fibroblastic in origin, do not metastasise and show variable clinical manifestations, ranging from an aggressive infiltrative growth to the less common “spontaneous” regression, which may be indicative of an ongoing immune response against the tumours⁶⁷. Sarcoids have a reputation of being notoriously difficult to treat due to locally infiltrative growth, multiple lesions, and localisation to sites compromising excision, with high rates of recurrence after treatment or excision.

2.1.1 Prevalence (proportion of individuals in a population having a disease)

Studies on the epidemiology of the equine sarcoid have been hampered by a lack of population data and the low prevalence of disease in individual or small groups of animals. Ragland *et al.* postulating on the viral aetiology of the disease, described an outbreak of sarcoids in a small group of horses⁶⁸. Reid *et al.* estimated an incidence of 0,6 cases per 100 animal-years in a population of donkeys⁷⁰. Medical records from for 22 Veterinary Teaching Hospitals in North America over 9 years revealed a range of 0 to 14 horses with sarcoids per 1000 animals⁵⁰. At autopsy about 20 % of all equine tumours proved to be sarcoids⁷². At the veterinary faculties of the Universities of Berne and Zurich, sarcoid tumours accounted for 2,0 % and 1,5 % of equine clinical cases respectively⁴⁴. In another study, sarcoid tumours accounted for 0,7 % of the equine clinical cases presented at the Cornell University Veterinary Hospital between 1975 and 1987³. In a population survey of Swiss Warmblood and the Freiburger horse breeds, sarcoid tumours occurred in 0,7 % and 0,4 % of these breeds respectively²¹.

Most reports suggest that there is no apparent gender, coat-colour, seasonal, geographic or breed predilection for the occurrence of sarcoid in horses^{20,71}. A higher incidence of sarcoid has been suggested in Quarter horses, Arabians and Appaloosas^{48,50} and a lower incidence in Standardbreds⁴⁴. Horses of all ages may be affected. Many researchers reported a higher incidence in horses under the age of seven years^{71,76,78}. In contrast, Mohammed *et al.* (1992) found an increased tendency for this tumour to occur in horses older than fifteen years⁵⁰.

2.1.2 Aetiology

The aetiology of equine sarcoid is controversial. Some evidence suggests the involvement of an infectious agent. Based on appearance and pattern of spread the first report describing the equine sarcoid suggested a virus origin for the tumours²⁷. There is strong evidence now that bovine papilloma virus (BPV) plays an important role in the aetiology of equine sarcoids, but a direct causal relationship has not been established^{12,14,15,41}. Transmission studies where either sarcoid tissue or cell-free supernatant from minced tumours was inoculated onto the scarified skin of sarcoid-free horses, resulted in the appearance of tumours at the inoculation site⁸⁹. In another study, the inoculation of non-affected horses with BPV also resulted in the growth of sarcoid-like tumours⁶⁹. However, the artificially induced sarcoids showed spontaneous regression, which is rarely encountered in naturally occurring sarcoids.

Although BPV has been suspected as the causative agent, no papillomavirus has been isolated from any clinical cases. Expression of viral genes including oncogenes has been documented in 95 % of examined sarcoid samples⁵³. This provided the first evidence for direct involvement of BPV in the pathogenesis of equine sarcoids. However, recently DNA highly homologous to the naturally occurring genomes of BPV₁ and BPV₂ has been demonstrated in most sarcoids using PCR-based techniques⁴². The reported detection rate between study groups varies from 73 %⁷ to 96 – 100 %^{13,57}. BPV DNA has not been detected in samples

obtained from horses without sarcoids or in non-sarcoid equine tumours or equine papillomas^{52,57}. The virus has however been found in some cases of dermatitis, although the significance of this is a yet unknown¹⁴. BPV gene expression has been examined in equine sarcoids using RT-PCR and Western blotting. Nasir and Reid examined 20 sarcoids containing BPV Type 1 DNA and demonstrated the presence of BPV-specific RNA in all samples⁵³. Carr *et al.* analysed 23 sarcoids by using Western blot and demonstrated the presence of the BPV-E5 protein in all tumours. The E5-protein was absent in all of the non-sarcoid samples examined^{12,13}.

In addition to BPV infection, there is evidence that sarcoids may be associated with a genetic predisposition in horses. An increased occurrence of sarcoid tumours has been recognised in certain families of horses. Research over the last decade has showed an association between susceptibility to sarcoid and certain heritable cell-surface proteins called major histocompatibility antigens. The major histocompatibility complex (MHC) is a group of genes that code for protein involved in the immune response as well as protein components of the compliment system. The MHC is comprised of three different classes of genes with different locations and different functions. The Class 2 genes have been implicated in susceptibility to sarcoid tumours. This class of genes codes for proteins found on the surface of lymphocytes and macrophages which act as receptors for foreign antigens. These receptors are responsible for the presentation of bound antigen to cells of the immune system⁸². The frequency of equine MHC class II haplotypes was examined in Thoroughbred and Standardbred horses in the USA, and researchers found a highly significant association between the MHC class II haplotypes W3 and B1 in the Thoroughbred population⁴⁷. Brostrom *et al.* found that the W13 haplotype is strongly associated with sarcoids in Swedish halfbreds¹⁰. The same author showed an association between the W13 haplotype and increased recurrence of sarcoids

following surgery. He also found that the A5 haplotype was linked to early onset of sarcoids⁹. The underlying mechanisms associated with this genetic predisposition are currently unclear.

2.1.3 Distribution on the body

Jackson reported the predilection sites for equine sarcoids as the lower portions of the limbs, especially the metacarpal area, the head, particularly the eyelids and lips, and the prepuce²⁷. Bastianello (1983) differed slightly from Jackson and reported the head, particularly the ear, followed by the trunk and limbs to be the commonest site for sarcoids. Sites of predilection summarised from five studies conducted in the USA and Australia, representing 662 sarcoids were: legs, 45,8 %; head and neck, 31,6 %; chest and trunk, 8,8 %; abdomen and flank, 6 %; prepuce, 3,6 %; castration wounds, 0,6 %; and other sites, 3,6 %^{23,24,48,66,77}. Another three studies found the most frequent sites to be the legs, ventral trunk and head (around eyes, pinnae, and commissures of lips)^{11,49,76}. Teifke examined 421 sarcoids and found the most common locations to be the ventral body regions, head, neck and sites of thin skin⁷⁹. Another author examined 126 sarcoids found in 58 horses and found the highest occurrence on the ventral abdomen, limbs and head⁸. Vanselow reported about 36 % of all sarcoids occur on the legs, especially on the lower parts⁸⁷. Another Swiss author, Gerber, examined 117 horses and found the highest percentage on the ventral abdomen, followed by the limbs and then the head⁴⁴.

Lesions often occur at wound sites or in sites that are predisposed to trauma^{27,76}. At the same time areas that come in contact with existing sarcoids frequently develop new sarcoids⁷⁷. In warm climates (Australia and the southern United States), the limbs are apparently more frequently affected than in European countries^{44,46,62}. Ragland and co-workers reported an increased incidence of tumour development three to eight months after wound healing⁶⁶.

Tumours may appear in freshly healing wounds of previously normal horses, or re-occur at the same site following apparent complete surgical removal as long as 10 or more years later ⁶².

2.1.4 Clinical appearance

Sarcoids present a variable clinical appearance. Confusion exists in the literature on the classification of gross lesions. Ragland *et al* classified the gross appearance into four broad categories: verrucous, fibroblastic, mixed verrucous and fibroblastic and flat ⁶⁶. A second classification reported by McConaghy *et al* included verrucous, fibroblastic and mixed ⁴⁶. A third classification uses occult, verrucous, nodular and fibroblastic ¹⁸. Recently, Pascoe and Knottenbelt described a fourth classification that included occult, verrucous, nodular, fibroblastic, mixed (verrucous, nodular and fibroblastic) and malevolent ⁶². The description of each category is as follows:

Occult sarcoids manifest as slightly thickened areas of skin, hairless and often circular or roughly circular. These lesions are generally slow growing. Occult sarcoids may progress to the verrucous form or, if traumatised, may develop into fibroblastic lesions ⁴⁶. They are commonest in the face, axilla, medial thigh and groin areas.

Verrucous sarcoids are grey, scabby or warty in appearance. They are generally slow growing and may become aggressive but only when injured. They are commonest in the face, groin, sheath and axilla areas.

Nodular sarcoids are generally solid, subcutaneous, nodules. They may have no skin involvement (Type A), or be firmly attached to the overlying skin (Type B) ⁶². These nodules are most common under the skin in the eyelid, axilla, inside thigh and groin areas.

Fibroblastic sarcoids appear as masses with ulcerated surfaces that haemorrhage easily, either with a thin pedicle, or with a wide flat base. This type of sarcoid will often resemble exuberant granulation tissue. They are common almost all over the body and are also the most aggressive type and may develop quickly from a milder form following damage.

Mixed sarcoids are mixtures of two or more of the other types. They can develop at any site but are commonest on the head, axilla and groin.

The *Malevolent* sarcoid is the most invasive type that spreads extensively through the skin resulting in tumour masses along vessels and at remote sites such as local lymph nodes^{30,62}. This form usually develops after interference with the fibroblastic form. It is a rare and is most commonly seen on the elbow, face and eyelid areas.

2.1.5 Histopathology

Jackson²⁷ originally described the equine sarcoid as a biphasic tumour composed of epidermal and dermal components in 1936. However, several authors have remarked that the epidermal changes are variable and may range from typical hyperplasia with rete peg formation (the finger - like projections of the epidermis that extend into the dermis) to a normal or even atrophic epidermis with marked hyperkeratosis^{44,66}. In a study of the histopathology of 100 equine sarcoids, epidermal hyperplasia, rete peg and “picket fence” formation (fibroblasts lining up perpendicular to the basement membrane of the epidermis) were found to be absent in 33, 12 and 9 % of cases respectively. All tumours however, showed some pattern of fibroblast proliferation⁷⁸. In another study of the 5 clinical types of equine sarcoids, epidermal hyperplasia, rete peg and “picket fence” formation were absent in 46, 54 and 52 %,

respectively, and more so in the occult and nodular sarcoids compared to the other clinical types⁴⁰. This explains why occult sarcoids are often overlooked histologically or why nodular sarcoids are identified as fibromas, neurofibromas or fibrosarcomas⁴⁰. The same study suggests that BPV-DNA detection can be used to obtain a correct diagnosis when the microscopic diagnosis is doubtful.

Examination of the entire excised tumour sectioned centrally in a plane perpendicular to its epidermal surface is far superior to punch biopsies. It allows the pathologist to observe the range of morphological characteristics in a given mass and thus arrive at the correct diagnosis^{2,44,78}. There is concern, however, that surgical excision for purposes of diagnosis may lead to a high rate of recurrence (50 – 64%)^{16,17}. Many surgically excised tumours recur within 6 months, prompting the recommendation that owners be given a fairly guarded prognosis on surgical excision alone.

Histologically, a diagnosis is made on the presence of a capillary poor fibroblast proliferation of moderate to high cell density. Individual cells are fusiform or spindle-shaped, forming whorls, interlacing bundles and haphazard arrays with one another. They vary from slender with elongated, pointed nuclei, to plump cells with large, irregular and more pleomorphic nuclei. Cytoplasmic boundaries are ill defined. The mitotic rate is invariably low and the amount of collagen varies considerably. The occurrence of fibroblastic orientation at a perpendicular angle to the epidermal basement membrane also varies, but is present in a high percentage of tumours. The epidermis, if present, is in most cases hyperplastic with characteristically elongated rete ridges. Especially in flat sarcoids, the epidermis can be normal or even atrophic with marked hyperkeratosis⁴⁴. Infiltration of inflammatory cells is not a prominent feature of sarcoids⁷⁸. A few eosinophils may accumulate in the adjacent

dermis, but neutrophils are usually evident only in the ulcerated areas⁷⁸. Distinct borders are rare and sinuous cords of sarcoid cells may extend into the adjacent dermis.

2.1.6 Differential diagnoses

A definitive diagnosis of sarcoid can only be obtained from the distinctive histopathologic features obtained from biopsy specimens. The following lesions, listed in order of prevalence, should be considered as differential diagnoses of sarcoids^{30,46,62,78}:

- Exuberant granulation tissue
- Papilloma
- Squamous cell carcinoma
- Neurofibroma
- Fibroma
- Fibrosarcoma
- Cutaneous habronemiasis
- Squamous papilloma
- Keloid

Exuberant granulation tissue with epidermal hyperplasia is grossly indistinguishable from fibroblastic sarcoid and may even present a diagnostic problem histologically speaking. A layer of granulation tissue may cover chronically ulcerated sarcoids, but the fibroblastic tissue in granulation is more orderly than that in sarcoids and contains prominent parallel blood vessels perpendicular to the fibroblast bundles. In addition, the “picket fence” pattern that is characteristic of sarcoids is absent in granulation tissue.

Equine papillomas usually develop as multiple, cauliflower-like nodules on the nose and lips of young horses ⁷⁶. A sessile, verrucous sarcoid in this region may be mistaken for a papilloma. Histologically, papillomas can be distinguished from sarcoids by the absence of a dermal component ^{66,78}.

Squamous cell carcinoma occurs most commonly at mucocutaneous junctions, particularly of the ocular tissue and external genitalia. Squamous cell carcinomas, however, can easily be differentiated on the basis of histopathologic features, including the presence of keratin pearls in well-differentiated tumours and individual cell keratinisation in poorly differentiated tumours ^{11,78}.

Neurofibromas restricted to the upper and lower eyelids were found in 17 horses in one survey ⁶³ and may resemble periocular sarcoids. Neurofibromas can be differentiated from sarcoids by identifying association with nerve fibres. Tumour cells may be seen originating adjacent to nerve sheaths ^{76,78}.

Differentiation between *fibromas* and sarcoids may be difficult, especially if the surface is ulcerated. Fibromas are well-circumscribed dermal or extradermal tumours ⁷³, that can be distinguished from sarcoids by their different growth pattern; they expand by compressing the surrounding tissue rather than by infiltration. The “picket fence” pattern of sarcoids is also absent and fibromas are less vascular and lack mitotic figures ^{76,78}.

Fibrosarcomas are more similar to sarcoids than fibromas due to the fact that they are more locally invasive, vary in size and are usually irregular and poorly demarcated. Fibrosarcomas

can be differentiated histologically by the high degree of cellularity, lack of collagen formation and distinct signs of anaplasia ^{66,78}.

Cutaneous habronemiasis have a seasonal occurrence coinciding with peak fly activity. Lesions occur where flies congregate, particularly around the eyes, prepuce, penis and wounds. Histologically, *Habronema* spp. larvae are usually seen in necrotic foci surrounded by a marked infiltration of eosinophils.

Squamous papilloma is a sporadically occurring tumour of adult horses. The mature dermal component of the tumour distinguishes it from equine sarcoid ⁶⁶.

Keloid arises from scar tissue and may resemble fibroblastic sarcoids. Histologically keloid consists of relatively acellular, dense, collagenous connective tissue beneath an acanthotic epidermis ^{66,76}.

2.1.7 Treatment

Currently, no effective therapy for the treatment of sarcoids has been described. Efficacy of different treatments is difficult to assess because most studies have not been controlled and are based on referral populations of horses treated at major clinics or veterinary hospitals. Such referral populations may not represent the overall tumour population in the field but a subset of fast growing, recurrent or multiple tumours that veterinary practitioners in the field have been unable to treat successfully. Conversely, many private practitioners treat sarcoids successfully by a policy of non-intervention, which again may represent a specific population of sarcoids that remain quiescent or the rare spontaneous regressors and there is some anecdotal evidence for this ²².

The methods that are currently available for treatment are as follows:

Surgical removal: Sharp excision of the tumour has been performed for many years. A major problem associated with surgical excision is the propensity for regrowth at the same site. Ragland *et al.* reported that approximately 50 % of surgically excised tumours recurred within 3 years, with most regrowths occurring within 6 months of the surgery⁶⁶. Another group reported a 64 % recurrence rate in 14 horses treated by conventional surgery⁸⁸. Small, well-defined tumours carry the best prognosis for surgical removal while extensive areas of poorly defined verrucous and mixed sarcoid may result in rapid regrowth of a more aggressive sarcoid type²⁹. The same author also reported that sarcoid regrowth can occur at the site of surgery up to 10 to 15 years later and that in over 90 % of cases, the regrowth was more aggressive in character.

Cryosurgery: Cryosurgery alone or in combination with debulking of larger sarcoids has been employed with some success³⁴. Approximately 70 % of treated horses appeared to be free of recurrences in most studies, although rates as high as 100 % and as low as 60 % have been reported^{22,33}. Swelling, hyperaemia, haemorrhage and local oedema occur after treatment and treated tissue undergoes necrosis. The average time for healing in one study was 2,4 months⁷⁵. Several complications have been associated with cryosurgery and include facial paralysis, loss of the upper eyelid, decreased strength of cortical bone and regrowth of white hair at the site of surgery^{19,20,33}.

Laser surgery: The most commonly used lasers for tumour excision are carbon dioxide and Nd:YAG lasers. The CO₂ laser is the preferred instrument for excision of sarcoids due to its

minimal degree of collateral thermal injury and is used to cut and evaporate tumour tissue^{59,60,88}. Vingerhoets *et al.* reported that 81 % of 59 horses treated by CO₂ laser were free from recurrence after 12 months⁸⁸. After CO₂ laser resection, the surgical site is dry and clean, minimal swelling occurs and the site is not painful to palpation. If enough skin is available, primary closure may be performed.

Hyperthermia: Due to limited reports in the literature, the true efficacy of hyperthermia is unclear. It has been reported to induce regression with no recurrence at 7 to 12 months after the last treatment in three cases of equine sarcoid²⁵. Hyperthermia may also be used synergistically with radiotherapy in killing tumour cells⁸⁵.

Immunotherapy: BCG, an attenuated strain of *Mycobacterium bovis*, is the immunomodulator most commonly employed for immunotherapy of equine sarcoids. BCG activates the mononuclear cells, stimulating them to release interleukin-1. Interleukin-1 non-specifically amplifies the immune response to antigens and malignant cells and has an immunoregulatory function^{35,86}. The response to BCG is affected by the immunogenicity of the tumour, tumour size, rate of growth and the ability of the animal to develop an immune response. As a consequence, immunotherapy is most effective against small, well-localized primary tumours in animals with an intact immune system^{74,92}. Immunotherapy is also more successful in periocular sarcoids^{44,58,91}. Potential complications using this method of treatment include severe anaphylactic reactions and death after inoculation of live BCG organisms⁵⁸ and inflammatory reactions with oedema, necrosis and discharge from the site⁸⁶.

Radiotherapy: Small radioactive sources placed in the tissue deliver a continuous, high, local dose of ionizing radiation^{85,93}. In two studies where sarcoids were treated with cobalt isotopes

and radon ²²², the success rate was 50% and 60%, respectively ^{38,90}. Radiotherapy is a useful alternative for sarcoids in areas in which radical excision or cryotherapy is too dangerous. Iridium¹⁹² is a popular therapeutic agent, particularly for tumours around the eyes, because there are few side effects ^{26,85,90}.

Chemotherapy: Daily topical applications of caustic or antimetabolite drugs such as podophyllum and 5-fluorouracil have been advocated for the treatment of small sarcoids ⁸⁴. Some clinicians have reported pragmatic success with topical unlicensed applications ³¹. This topical ointment (AW – 4 Ludes, DC Knottenbelt) has shown some success in treating sarcoids. It contains a variety of heavy metals and the antimitotic compounds 5-fluorouracil and thiouracil ⁵⁵. The ointment is administered on successive or alternate days for three to five treatments. Intralesional implants have been developed and consist of a high-molecular weight collagen matrix that contains a chemotherapeutic agent (5-fluorouracil or cisplatin). These compounds result in maintenance of high local drug concentrations for extended periods. One report demonstrated at least 50 % reduction in tumour volume in 81 of 101 cases after cytoreductive surgery ⁵. Cisplatin in sesame oil has been successful in treating 30 skin tumours in horses, including 19 sarcoids ⁸⁰.

The factors that should be considered in the treatment of equine sarcoids include availability of treatment, location of tumour, cosmetic considerations, cost of treatment, potential complications and the risks to both the patient and the owner.

2.2 Sarcoids in Cape Mountain Zebra

2.2.1 Distribution of CMZ

The CMZ (*Equus zebra zebra*) is a highly vulnerable subspecies of mountain zebra, with around 1600 animals remaining in isolated populations⁶⁵. The World Conservation Union (IUCN) red list (*Version 3.1*) lists *Equus zebra zebra* as vulnerable (criteria D1)¹. The Convention on International Trade in Endangered Species of Wild Fauna and Flora (CITES) lists the CMZ on its Appendix I. Appendix I offer the highest level of protection to “species threatened with extinction which are or may be affected by trade.” International trade for commercial purposes with these species are prohibited (e.g. pet trade, food industry, jewellery or ornament making). The appendix does however allow some trade for non-commercial purposes (e.g. to go to educational facilities, or for scientific purposes).

All South African CMZ are descendants from 30 individual animals originating from three populations: from the Mountain Zebra National Park (MZNP), the Kamanassie Nature Reserve and the Gamka Mountain Nature Reserve⁶. MZNP was established in 1937 near Cradock, with a founder population of five stallions and one mare. In 1950, five stallions and six mares were donated to MZNP. In 1964, another 30 animals were donated to the Park⁶. Since the original population perished without breeding, the latter group of animals formed the breeding nucleus from which the current extant CMZ population is derived. The population at MZNP is currently maintained at around 300 to 400 animals and as many as 40 zebras are removed annually to re-establish breeding herds elsewhere within their original range⁶⁴.

Other seeded populations of CMZ occur in BNP, Karoo Nature Reserve, and GNDR, estimated to be currently at 16, 83 and 70 animals respectively. Other small original

populations of CMZ occur in the Gamka Mountain and Kamanassie Nature Reserves (B Penzhorn, personal communication).

2.2.2 Occurrence of sarcoids

Free State and Eastern Cape Nature Conservation has reported an increase in the incidence of sarcoids in its zebra population, with Free State Nature Conservation reporting an extreme manifestation of the tumour in the population (P Nel, personal communication). A high incidence of sarcoids has been reported from CMZ sub-populations in BNP (D Zimmerman, personal communication) and also from GDNR population (P Nel, personal communication). In addition, isolated cases have been reported in Commando Drift Nature Reserve near Cradock (E Bird, personal communication), Gamka Mountain ⁵¹ and De Hoop Nature Reserves ⁵⁶.

Of particular importance was the report of increasing incidence of sarcoid tumours in some of these sub-populations, especially in the BNP (D Zimmerman, personal communication). This population is thought to be highly inbred (SP Sasidharan, Comparative genetics of selected Southern African Mountain Zebra populations, MSc, Faculty of Veterinary Science, 2005: pp 106) and therefore strongly supports the hypothesis that there is a relation between homozygosity in mountain zebra populations and expression of sarcoid.

CHAPTER 3

MATERIALS AND METHODS

3.1 Animals

3.1.1 Cape Mountain Zebra

The entire population of CMZ used for the study were in the BNP and were examined over a two-day period towards the end of 2002. This is a highly inbred population (SP Sasidharan, Comparative genetics of selected Southern African Mountain Zebra populations, MSc, Faculty of Veterinary Science, 2005: pp 106) and the prevalence of sarcoid has been high in the past. The population of CMZ in BNP numbered 15 animals, consisting of nine females (six subadults and three adults) and six males (three subadults and three adults). All CMZ in BNP originated from the MZNP.

The Bontebok National Park is situated in the foothills of the Langeberg Mountains, located in the region of Swellendam. The park was proclaimed in 1931 to prevent the last few remaining Bontebok from following the footsteps of the Blue Antelope into extinction. The region has a temperate climate with an average rainfall of about 500 mm per annum, occurring mainly during early summer and winter and is also one of the largest remaining 'renosterveld islands' containing several plant species found nowhere else in the world. The 2 786 hectare Park is bordered to the south by the mighty Breede River and provides a refuge for not only Bontebok, but also for other species such as CMZ, Red Hartebeest, Grey Rhebok, Stanley's Bustard, Blue Crane and Secretary Bird. The northern side of the reserve borders commercial farmland with sheep, goats and cattle.

3.1.2 Burchell's zebra

As a comparison to the CMZ, a sample of 524 BZ in the Kruger National Park was selected. BZ between Lower Sabie in the south to Mooiplaas in the northern section was sampled. The reason to cover such a large area was to prevent the observers from sampling the same animals on consecutive days. BZ in the KNP is regarded as an outbred population based on the population size (Census Report KNP 2005 – 32 000 BZ in KNP) and from a genetic diversity point of view, serve as a good comparison to the largely inbred CMZ population in BNP.

3.2 Observations

3.2.1 Cape Mountain Zebra

3.2.1.1 Immobilisation and identification

All animals were immobilised from a helicopter using a combination of 4 – 7 mg etorphine hydrochloride (M99® Novartis, P.O. Box 92, Isando, 1600, RSA), 40 – 80 mg azaperone (Azaperone® BayerAnimal Health, P.O. Box 143, Isando, 1600, RSA) and 1500 iu Hyalase® (Kyron Laboratories, P.O. Box 27329, Benrose, 2011, RSA). Reversal was done with 8 – 14 mg diprenorphine HCL (M50-50® Novartis, P.O. Box 92, Isando, 1600, RSA). Once the animals were down a ground team moved in and covered their eyes and blocked the ears. All animals were identified by microchip and the coat patterns were recorded by means of digital photography.

3.2.1.2 Prevalence of sarcoid

After a thorough examination, the presence and distribution of tumours was recorded on a body chart (Addendum A). Sizes and macroscopic appearance were recorded by means of digital photography. Distribution was divided into three anatomical locations: head and neck, ventral abdomen and limbs.

3.2.2 Burchell's zebra

3.2.2.1 Prevalence of sarcoid

The group of Burchell's zebra was examined in early 2003 in the southern, central and northern sections of Kruger National Park. The animals were examined with the aid of binoculars in order to determine the prevalence of sarcoid-like growths according to sex and approximate age (male, female, foals, subadults, adults). Observations were opportunistic and the side exposed was documented. The distribution and number of growths were recorded for each animal.

3.3 Collection, processing and histological examination of suspected CMZ sarcoids

3.3.1 Specimen collection

Biopsies were taken from all of the zebras with sarcoid-like growths. The sarcoids were either surgically excised or a representative biopsy was taken using a 6 mm biopsy punch. Where two or more tumours were present on a zebra, a maximum of two samples each was taken from the different tumours. After the tissues were fixed in 10% buffered formalin, they were trimmed into blocks and routinely processed.

3.3.2 Processing for histology

The formalin fixed sarcoids were trimmed and dehydrated in alcohol. Following this they were embedded in paraffin wax, before 6 μ m sections were cut. Then they were stained with haematoxylin and eosin, mounted and examined with a light microscope.

3.3.3 Histological evaluation of sarcoids

Each suspected sarcoid sample was examined for some or all of the typical epidermal and dermal histological features of equine sarcoid and categorised accordingly^{40,78}.

3.4 Treatment of sarcoids

Initially we had not intended to carry out any treatments on CMZ with sarcoids. However, during the course of the fieldwork, we were requested by the SANParks veterinarian to treat a number of zebras with sarcoids.

3.4.1 Treatments

The four treatment methods applied are as follows:

Surgical excision

The sarcoids were excised in totality using a 10 mm margin around the tumour. After the CMZ had been immobilised, a tarpaulin was placed underneath the animal to attain optimal cleanliness under the circumstances. The area around the tumour was washed with water and dried with a clean towel. The area was not shaved as time was of the essence. An elliptical incision was made through the skin and subcutis with a number 20 scalpel blade around the tumour. Using Metzebaum scissors, the tumour and adjacent skin were removed by blunt dissection. Any minor bleeding was controlled by application of mosquito forceps, while major blood vessels were tied off with number 1/0 chromic catgut. Closure was routine using 2/0 nylon in a simple continuous pattern. This suture pattern was chosen for speed, over the normal simple interrupted pattern. A wound spray (Necrospray® - Bayer Animal Health, P.O. Box 143, Isando, 1600, RSA) was applied over the surgical site to deter flies.

Intralesional 5-Fluorouracil treatment

5-Fluorouracil (ABIC FLUOROURACIL® 50mg/ml - Teva Pharmaceuticals) is a fluorinated pyrimidine antimetabolite that interferes with DNA biosynthesis and was chosen as the chemotherapeutic agent of choice. No dosage regimen (mg/cm³) exists for 5-Fluorouracil (5 – FU) as it does for cisplatin. Latex gloves were worn while the entire base of the tumour was infiltrated, using a criss-cross pattern. A 16-gauge needle connected to a 20 ml syringe was used and the agent was injected as follows:

The needle was first advanced its full length and while it was being withdrawn, the 5 - FU was slowly injected. This procedure was repeated several times depending on the size of the tumour to ensure its entire base was infiltrated. Some “spillage” always takes place as some 5 – FU leaks out of the injection channels. Pressure was applied to any of these channels that leaked with a gloved hand for 2 to 3 minutes to minimise “spillage”. After all data was collected on the CMZ, the animal was given the antidote and woken up. No antibiotics or anti-inflammatory drugs were given.

Autogenous vaccine

A crude autogenous vaccine was manufactured by using sarcoids from affected animals. The sarcoids were minced and then filtered to provide antigenic mass to stimulate the immune system. The following summarises the manufacturing of the vaccine:

- 15 g minced and filtered sarcoid from CMZ
- 84 ml glycerol-saline (50 % glycerol and 50 % 0.9 % NaCl)
- 1 ml 10 % formalin
- 150 000 IU sodium penicillin
- 100 mg dihydrostreptomycin

Each zebra was treated once only with 1 ml of the autogenous vaccine subcutaneously. All zebras were injected on the left neck area, roughly halfway between the shoulder and head, for future reference and follow-up.

Combined intra-lesional 5-Fluorouracil treatment with autogenous vaccine

In this case the animal was given both the 5-Fluorouracil and the vaccination treatment. The protocol was followed as described above for both procedures.

3.4.2 Assessment of treatment success

The zebras were immobilised 18 months later to assess the effects of treatments performed. During this follow-up examination all animals were darted and examined (as described previously) for the presence of sarcoids.

3.5 Data analysis

This was a descriptive study where the entire BNP CMZ population was examined in 2002 thus providing the prevalence of the disease. The prevalence was compared to the population of CMZ in the GDNR. The anatomical distribution of sarcoids between the two populations was also compared. Statistical analysis was done using Fisher's Exact Test and the Aspin-Welch unequal-variance test.

CHAPTER 4

RESULTS

4.1 Cape Mountain Zebra

4.1.1 Prevalence

The entire population of CMZ in the BNP was examined over two days in November 2002. Eight out of 15 animals (53 %) had tumours in the BNP. Of the affected animals, 4 out of 8 (50 %) had multiple tumours (Table 1). Of the 8 cases, 3 were males and 5 were females. All the animals affected were adult, except one male that was a sub-adult (Table 2).

Table 1: CMZ with sarcoids in BNP, with reference to area affected

ZEBRA	AREA AFFECTED	SEX	AGE
Q06	Shoulder, dewlap, ventral abdomen X 2, penis and ear	Male	Adult
Q09	Udder, thigh	Female	Adult
Q14	Elbow	Male	Adult
Q15	Ventral abdomen	Female	Adult
Q16	Ventral abdomen	Female	Adult
Q17	Ventral abdomen, elbow	Female	Adult
Q18	Axilla, elbow	Male	Subadult
Q21	Ventral abdomen	Female	Adult
TOTAL	16 Lesions	8 Animals	

Table 2: Age distribution of CMZ with sarcoid in BNP

Sex	Age group	Total sarcoids in group	Sarcoid affected animals
Male	Adult	8	2
Male	Subadult	1	1
Male	Foal	0	0
Female	Adult	7	5
Female	Subadult	0	0
Female	Foal	0	0
Total population		16	8

4.1.2 Distribution on the body

Figure 1 shows the anatomical distribution of sarcoids grouped as head and neck, trunk and limbs. Of the 8 cases, 1 (12,5 %) had lesions on the head and neck, 6 (75 %) had lesions on the ventral trunk and 4 (50 %) had lesions on the limbs.

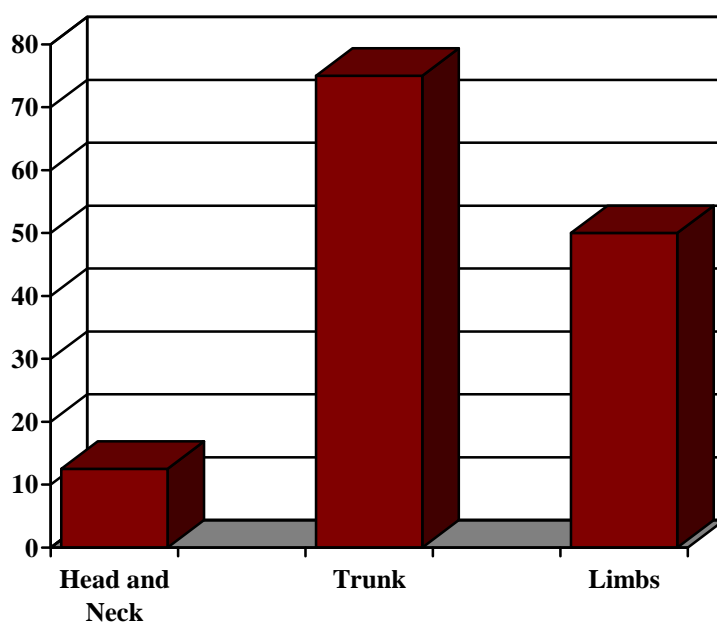


Figure 1: Distribution of sarcoids on the body of CMZ in BNP

4.1.3 Clinical appearance

Figure 2 summarises the clinical appearance of the 16 lesions observed in the 8 affected zebras. Of the 16 lesions 13 (81,25 %) were of the verrucous type, 2 (12,5 %) was fibroblastic and 1 (6,25 %) was nodular. Examples of these are shown in Figures 3 (verrucous), 4 (fibroblastic) and 5 (nodular) respectively.

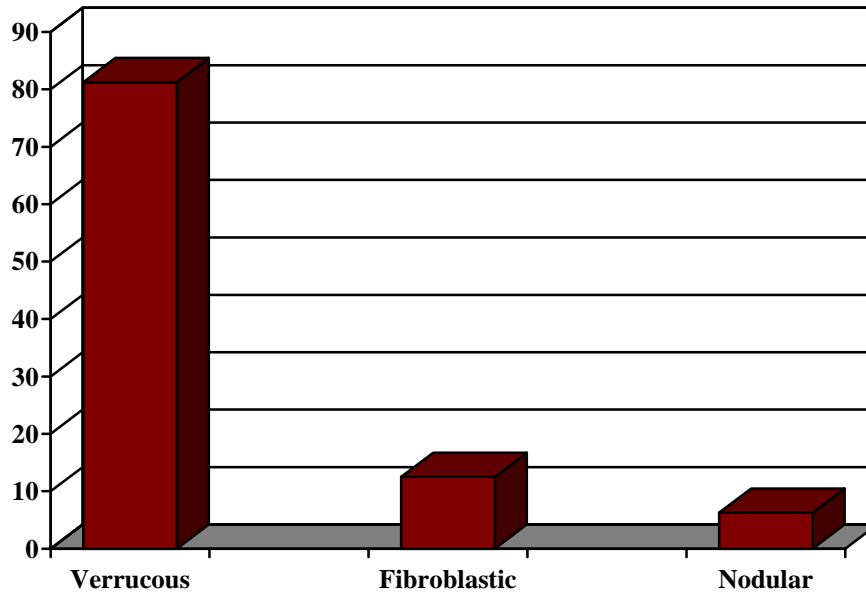


Figure 2: Clinical appearance of sarcoids in CMZ in BNP

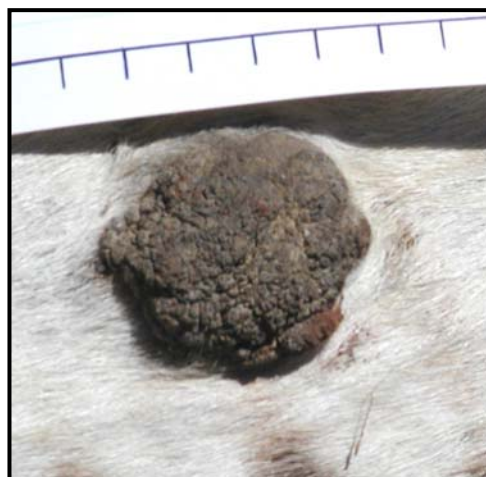

Figure 3: A typical verrucous sarcoid (CMZ # Q 21)

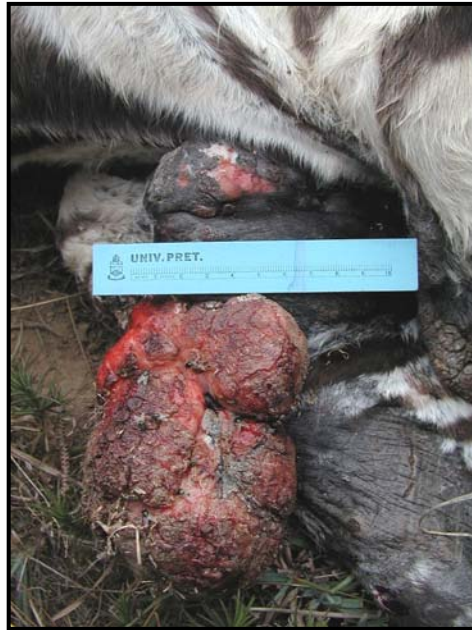

Figure 4: A typical fibroblastic sarcoid. This CMZ stallion (# Q 6) had to euthanased

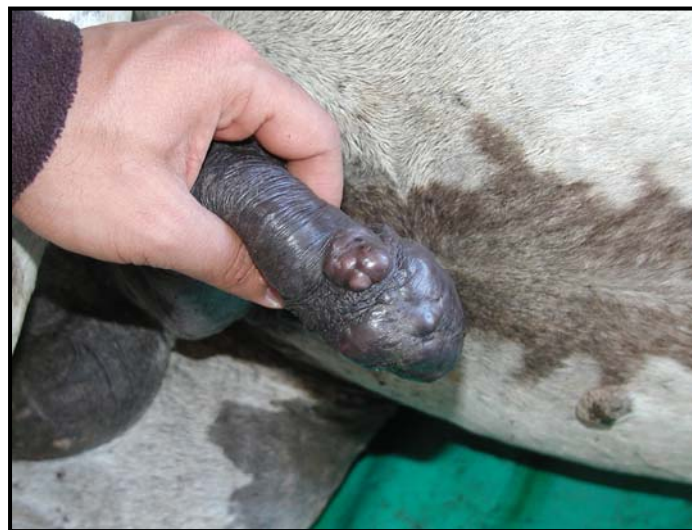

Figure 5: A typical nodular sarcoid (CMZ # Q 6)

4.1.4 Treatment of sarcoids

On first examination in 2002 it was decided to euthanase one stallion (Q6). The decision was based on the extensive nature of sarcoids on the sheath, dewlap, ear, ventral abdomen and in the groin.

Surgical excision

Surgical excision of suspected sarcoids was performed on two animals (Q15 and Q16) that had growths on the ventral abdomen. Both tumours were similar in size and appearance, measuring 90 x 60 x 15 mm, ulcerated and verrucous.



Figure 6: Ulcerated, verrucous growth on the ventral abdomen of CMZ # Q 15

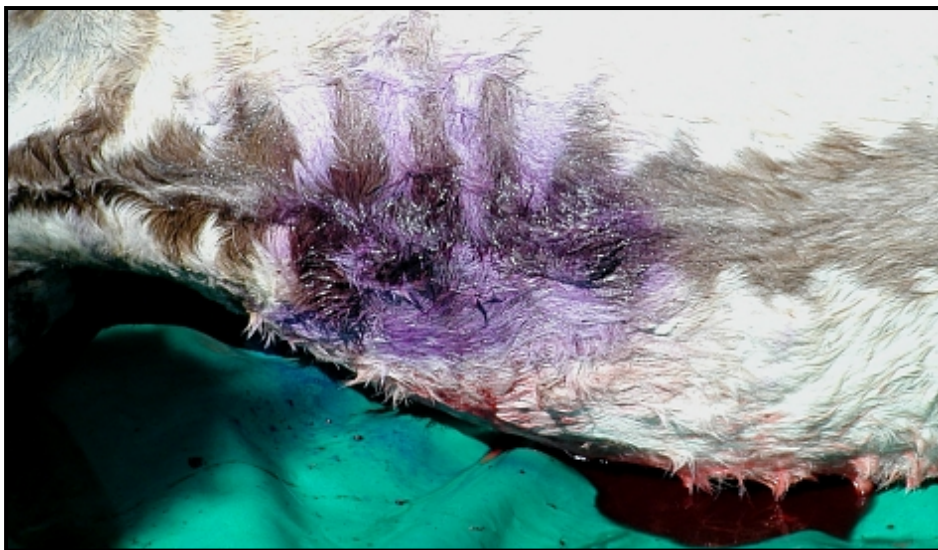

Figure 7: Appearance after resection of the sarcoid in CMZ # Q 15

Intralesional 5-Fluorouracil treatment

Two animals (**Q9** and **Q18**) had lesions on the udder, abdomen and legs. **Q9** had a small raised verrucous lesion on the udder measuring 20 mm in diameter. Another 20 mm plaque-like lesion with verrucous surface was present on the left medial inner thigh. Both lesions were injected with intralesional 5-Fluorouracil. **Q 18** had a 20 mm diameter verrucous lesion on the medial aspect of the left axilla and a 15 mm verrucous growth on the medial aspect of the right elbow. The axillary lesion was treated with 5-Fluorouracil whereas the elbow lesion left untreated.



Figure 8: Verrucous

Autogenous vaccine

Two animals (**Q17** and **Q21**) had lesions on the ventral abdomen and legs. **Q17** had an ulcerated growth on the right ventral midline area posterior to the umbilicus; the lesion was flat, plaque-like and measured 20 mm in diameter. A nodular verrucous growth 20 mm in diameter was also present on the medial aspect of the left elbow. **Q21** had a 15 mm flat

plaque-like lesion on the right ventral abdomen. Both animals were injected with 1 ml autogenous vaccine subcutaneously.

Combined Intralesional 5-Fluorouracil treatment with autogenous vaccine

Q14, a 2-year old stallion, had a verrucous, raised nodular lesion on the inner aspect of the right elbow, 30 mm in diameter. He received intralesional 5-Fluorouracil and was also vaccinated.



Figure 9: Verrucous lesion present on the ventral abdomen of CMZ # Q 21 treated with autogenous vaccine

4.1.5 Results of treatments 18 months later

During the follow-up examination (June 2004), all animals were darted and examined for the presence of sarcoids. Of the previous animals mentioned above (Q15, 16, 9, 18, 14, 17 and 21), only Q18 had any evidence of sarcoids, albeit in such a way that she had to be euthanased. No sarcoids of any size could be found on any of the previous treated animals. Q18 suffered

from several sarcoids consisting of verrucous and fibroblastic forms on the ventral abdomen, the left stifle, the right hock and stifle and extensive tumour formation in the left axilla with severe subcutaneous oedema with enlargement of the axillary lymph nodes. The lymphoid hyperplasia in the lymph nodes was due to extensive tissue necrosis and associated inflammatory response. The severe lesions on the inner aspects of the front limbs contributed to the relative poor condition of this animal (interference with grazing especially in the harsh environment).

4.2 Burchell's zebra

4.2.1 Prevalence

A total of 524 zebras were examined at close range. Of these, 102 animals were males, 365 animals were females and 57 animals were too young to sex. In the 102 male animals, it was possible to examine 32 left, 41 right and 29 both sides of the zebra. In the female animals, it was possible to examine 109 left, 190 right and 67 both sides of the zebra. In the subadults and foals, it was possible to examine 21 left, 28 right and 8 both sides of the animals. A total of 627 sides and 524 zebras were therefore examined. Of these, 104 zebras could be observed on both the left and right sides, while 162 and 259 could be observed on the left and right sides respectively.

Eight out of the 524 zebras examined (1,5 %) had lesions on them that looked similar to sarcoids in the CMZ. Two out of the 8 zebras (25 %) showed evidence of multiple growths.



Figure 10: An example of the sarcoid-like growths that was observed in Burchell's zebra in Kruger National Park

4.2.2 Distribution on the body

In the Burchell's zebra population, 40% of the sarcoid-like lesions were on the head and neck, 30% on the ventral trunk and 30% on the limbs (see Figure 10).

4.3 Histopathology of suspected sarcoids in CMZ

All sarcoids were examined for the presence of the typical histological features such as epidermal hyperplasia, epidermal hyperkeratosis, rete peg formation and proliferation of "fibroblast-like" cells^{40,78}. The microscopic features of the "growths" in this study showed either all or most of the typical epidermal and dermal histological features of equine sarcoid. The epidermal changes included hyperplasia, atrophy, hyperkeratosis and partial surface

ulceration, whereas the dermal changes consisted of increased density of fibroblasts, replacing the dermal collagen and a whorling fibroblast pattern. The formation of long rete pegs was frequent and often associated with epidermal hyperplasia (see Figure 12). The cells had spindle-shaped nuclei with occasional double nuclei and elongated eosinophilic cytoplasm. Differentiation of the tumour cells varied from anaplastic to well differentiated, with the latter present in tumours of a more chronic nature.

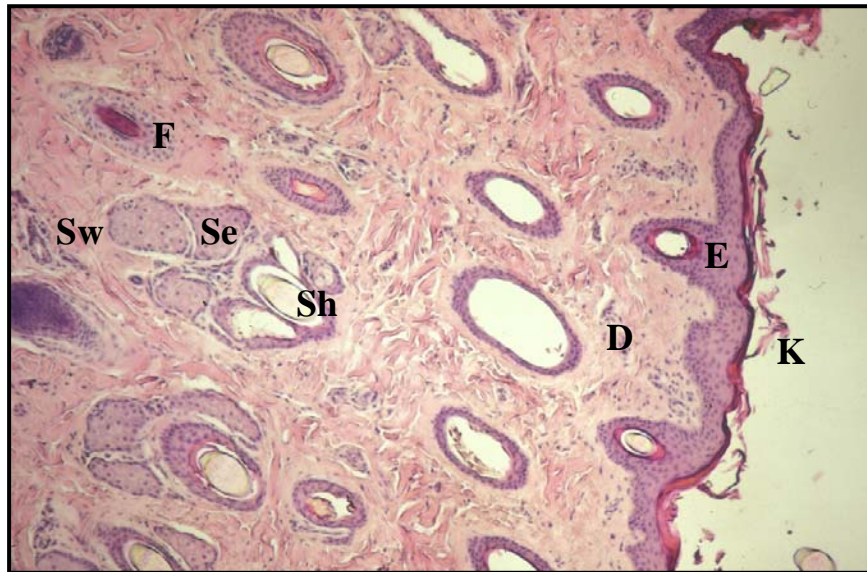


Figure 11: Normal skin showing epidermis (E) and keratin layer (K) overlying the dermis (D) with all adnexal structures (hair follicles (F) with hair shafts (Sh), sebaceous glands (Se) and sweat glands (Sw) [X40 H&E stain].

All fibroblastic tumours had partial epidermal ulceration, with infiltration of polymorphonuclear inflammatory cells (see Figure 13). The verrucous tumours especially showed prominent proliferation of the surface epidermis associated with hyperkeratosis and crust formation (Figure 14). Several of these tumours were also fairly aggressive histologically. This refers to tumour cell infiltration that was extensive with multifocal groups of cells infiltrating into the deeper stroma.

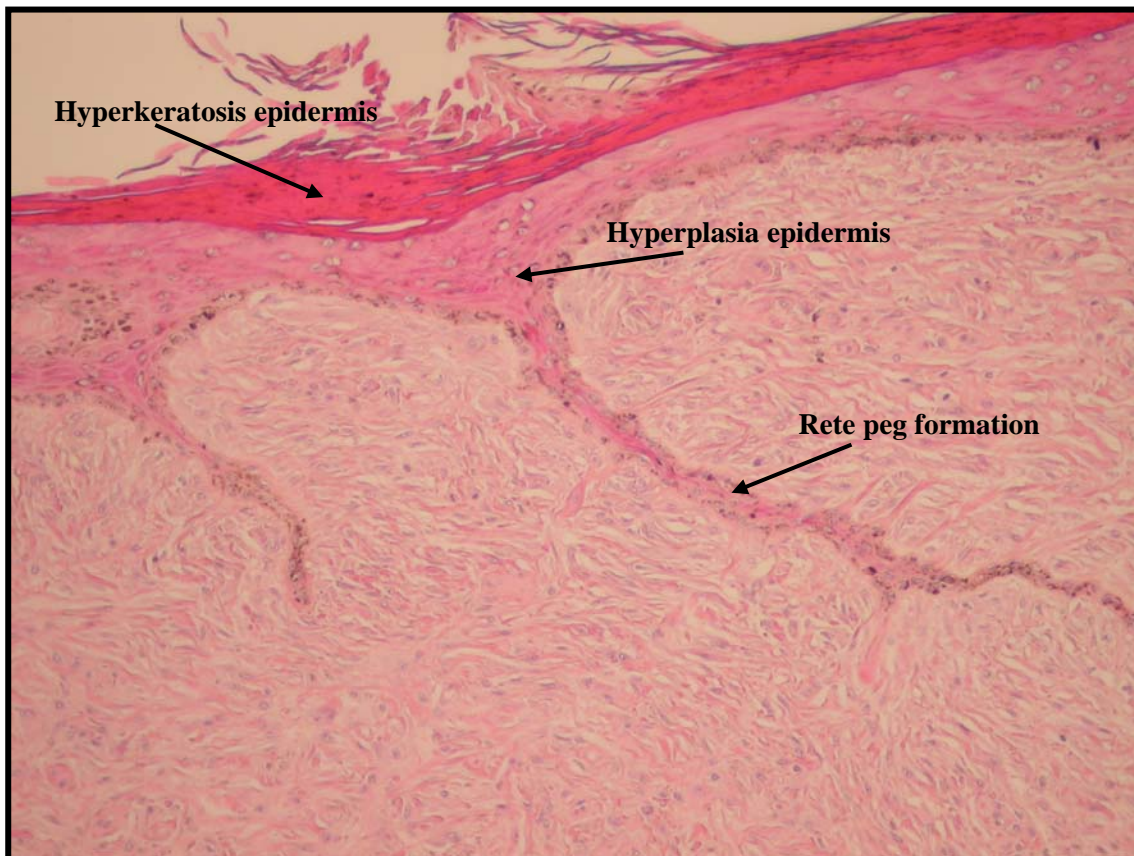


Figure 12: Histopathology typical of sarcoid found in CMZ in BNP, showing epidermal hyperkeratosis, hyperplasia and rete peg formation. Note the spindle-shaped fibroblasts with interlacing and whorling collagen, replacing dermal adnexal structures (hair follicles, sweat and sebaceous glands) [X40 H&E stain].

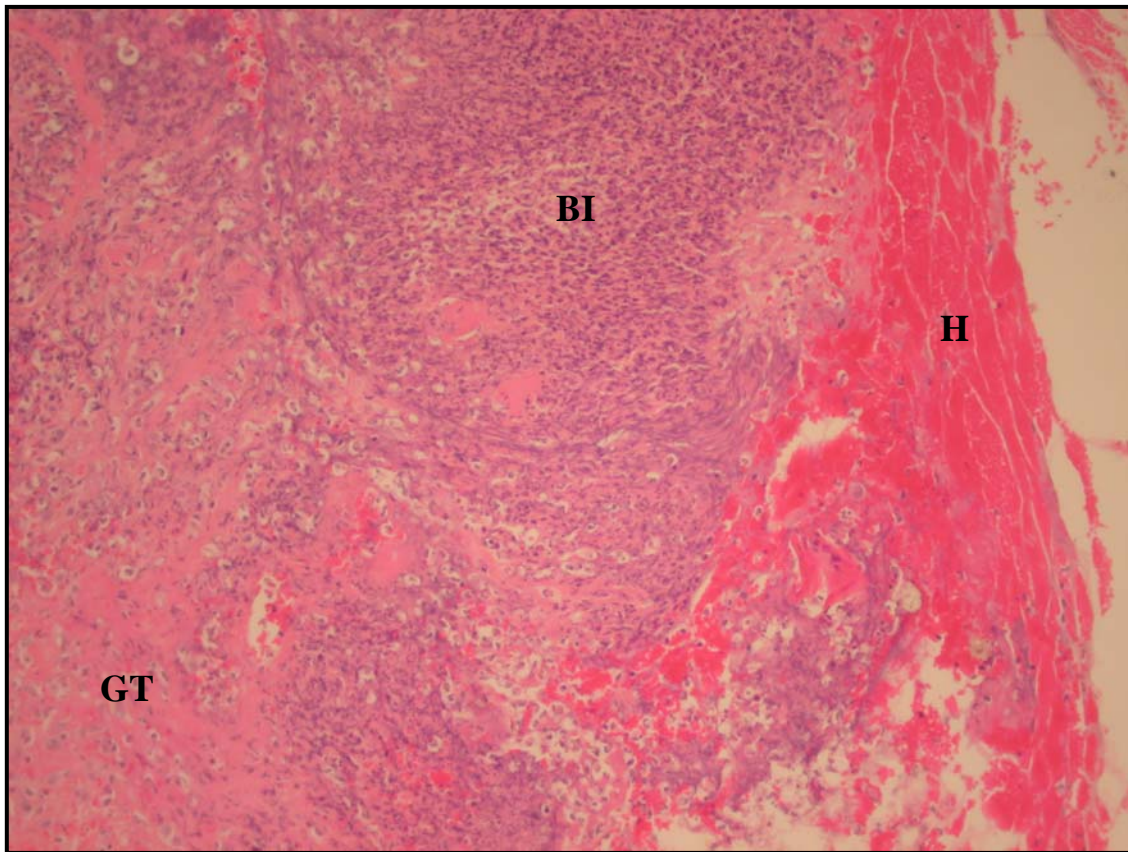


Figure 13: Epidermal ulceration and necrosis with exudate, haemorrhage (H), bacterial infection (BI) and crust formation with a zone of granulation tissue (GT) interfacing the sarcoid below [X20 H&E stain].

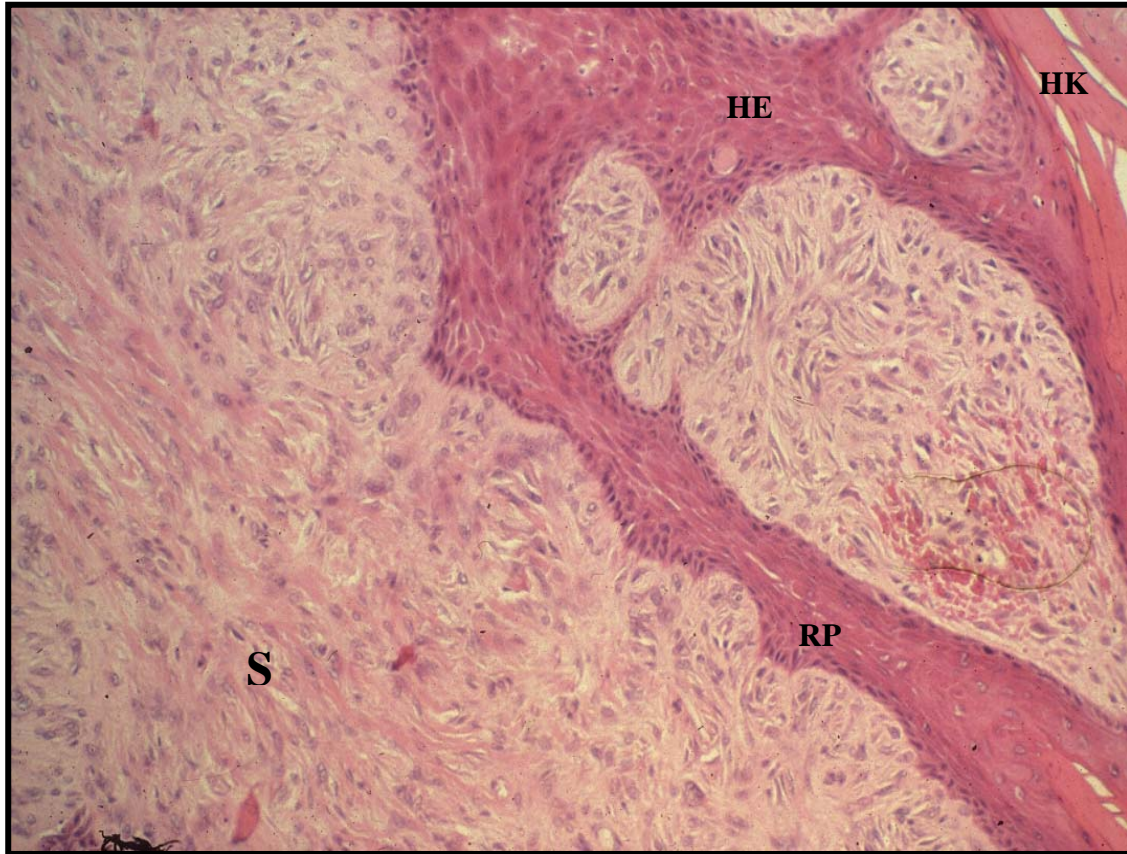

Figure 14: Hyperplastic epidermis (HE) with hyperkeratosis (HK) and rete pegs (RP) extending into sarcoid (S) below with loss of adnexal structures. [x 100 H&E stain]

CHAPTER 5

DISCUSSION

The first report of “wart-like” growths in a stallion in BNP was in 1995. Park staff examined this stallion after he died and several growths were seen on his ears and abdomen. Subsequently, several other animals were seen with the same “wart-like” growths on their bodies and soon the local veterinarian of SANParks as well as Park management expressed some concern on the prevalence of the growths.

This study, undertaken during November 2002, identified the growths as sarcoids histologically, and confirmed the high prevalence in this population of CMZ in BNP.

The available literature mentions the prevalence of sarcoid in horses to range from 0,5 % to 2,0 %^{3,22,44}. Four studies measuring incidence, and not prevalence, reported the incidence to range from 12,9 % to 67 % in all tumours of horses, mules and donkeys^{3,27,48,77}. Data examined from medical records of 22 Veterinary Teaching Hospitals in North America for 9 years, revealed the number of sarcoid cases to range from 0 to 14 per 1000 animals⁵⁰. The average proportional morbidity rate in this study was 6 cases in 1000 animals per year. However, such clinical data are biased in that they depend not only upon the prevalence of the disease in the population but also on the value of the affected animal, the ability of private veterinarians to treat the animals successfully, and the expectation that the veterinary hospital will be able to treat it successfully. Taking this all into account, it is clear that the prevalence of sarcoids in horses worldwide range between 0,5 % to about 3 %. In this study, the prevalence of sarcoids in a population of CMZ in the BNP was 53 %. Although this population is quite small (15 animals), other reports have also been received of much higher than reported prevalence of sarcoids in CMZ in the GDNR, which harbours approximately 70 animals (P

Nel – personal communication). The prevalence in GDNR in 2002 was 27,4 %⁵⁴. The particular study done in GDNR ran between 1996 and 2003. The prevalence of sarcoids was significantly greater in the BNP population (Fisher’s exact test $p = 0.03$). However, from the onset and during this study, affected CMZ were removed from the population which clearly would have had an impact on the prevalence of 27,4 % in 2002. After visibly-affected CMZ were removed from the GDNR population in 1996, the prevalence was 4.6% in 1997 and this increased to almost 25 % in 2002 despite animals being removed from this population⁵⁴. The prevalence of 24,7 % in 2002 in CMZ in GDNR is much higher than the reported 0,5 % to 3 % in the literature. This percentage would probably have been significantly higher if animals had not been removed from the population over a period of seven years. There was no difference for the total population of the two parks for overall prevalence, and body location prevalence between sexes.

Another cause of concern is that recently “wart-like” growths very similar in appearance to the sarcoids in BNP have been noticed in several CMZ in Mountain Zebra National Park (D Zimmerman – personal communication). The question is therefore being asked, what is causing the high prevalence of sarcoids in these animals? Evidence exists in the literature between the development of sarcoid and genetic predisposition³. Similarly, there have been descriptions of sarcoids occurring within particular breeds and bloodlines associated with equine leukocyte antigens^{3,9,10}. All South African CMZ are descendants from no more than 30 individual animals originating from three populations namely the Mountain Zebra National Park (MZNP), and Kammanassie and Gamka Mountain Nature Reserves near Cradock⁶. All three of these populations were within fenced areas for many generations and it is therefore likely that they were considerably inbred. A study recently undertook to document the degree of inbreeding in CMZ in BNP and GDNR specifically, used domestic horse microsatellites to

obtain allelic information (SP Sasidharan, Comparative genetics of selected Southern African Mountain Zebra populations, MSc, Faculty of Veterinary Science, 2005: pp 106). These two populations were compared to populations of CMZ without any history of sarcoids. The sarcoid affected populations had the lowest level of heterozygosity and polymorphism, thereby confirming their limited genetic variation. The CMZ in BNP originated from the Mountain Zebra National Park, whereas the animals in GDNR all came from a breeding nucleus numbering six animals from the Cradock area (N Grootendorst – personal communication). A possible reduction in major histocompatibility complex diversity due to genetic bottlenecks and subsequent inbreeding probably contributed to uniform population sensitivity and the subsequent development of sarcoid in these two CMZ populations. The recent study by Sasidharan *et al* showed specific heterozygote deficiency within the two populations of CMZ in BNP and GDNR. This is clear evidence that the genetic diversity is diminished in these small and fenced-in populations and probably accounts for the high prevalence of sarcoid tumours in CMZ in these two reserves.

The specific aetiology of equine sarcoid remains controversial. The reason for this is that no virus has been isolated from clinical cases. However, there is a large body of evidence that supports the hypothesis that bovine papillomavirus (BPV) is the causative agent of equine sarcoid^{32,39,83}. Although thought initially to be species-specific, it is now known that some papillomaviruses can infect species other than that with which they are commonly associated and this can result in a different pathological outcome to that in the normal host. Using sequence analysis of BPV DNA isolates extracted from sarcoids, the presence of distinct equine sarcoid-specific variants of BPV has been detected⁵⁷. BNP is surrounded by communal land on which cattle are kept. The growths in CMZ in BNP have been histologically confirmed as equine sarcoid and it is therefore safe to speculate that these

sarcoids and equine sarcoid have a similar aetiology. Although evidence suggests that BPV types 1 and 2 are the principal causative agents of sarcoid, there is currently no clear evidence on the mode of transmission. Close contact between cattle and CMZ in BNP is possible as we found at least two breaks in the fence where cattle regularly wander through and could easily come in contact with CMZ. In addition, several authors have proposed that flies may act as a vector with sarcoids developing at wound sites²⁷. This may be clearly the case in BNP with the close proximity of cattle as well as the nature of the vegetation which is found here, namely Fynbos, which may inflict trauma to especially the legs of CMZ, thereby attracting flies and simultaneously providing an area of infection.

The head, limbs and abdomen were the commonest sites where sarcoids were found in this study. This is in agreement with most of the literature cited^{71,78}. Jackson was the first to report the predilection sites for equine sarcoids as the lower portions of the limbs, especially the metacarpus area, the head, particularly the eyelids and lips, and the prepuce²⁷. Another three studies are in agreement and found the most common sites for sarcoid to be the legs, ventral trunk and head (around eyes, pinnae, and commissures of lips)^{11,49,76}. Five studies representing 662 sarcoids reported the same and found the most frequent sites to be the legs, 45,8%; then head and neck, 31,6%; chest and trunk, 8,8%; abdomen and flank, 6% and finally prepuce, 3,6%^{23,24,48,66,77}. CMZ in the BNP had the highest frequency on the ventral abdomen and legs. Compared to this, CMZ in the GDNR over a period of 7 years, also showed a high incidence on the ventral abdomen, but this was followed by the head and then the legs. Statistically, there was a tendency for a greater prevalence of tumours in BNP on the limbs ($p = 0.080267$; Aspin-Welch unequal-variance test) and a significant greater prevalence of tumours in BNP than GDNR on limbs plus the body ($p = 0.014093$; equal variance t-test). Maybe the difference in anatomical distribution can in part be ascribed to the different

vegetation biomes types in the two reserves. The biome in BNP consist mainly of two key vegetation groups namely Fynbos and coastal Renosterveld, although the latter is only found in limited areas in the reserve. A specific feature of the Fynbos in the reserve is the large amount of prickly bush (*Cliffortia ruscifolia*) that occurs here. This sturdy shrub has needle-like, spiny leaves that easily inflicts trauma to the skin. It has been reported that sarcoid lesions often occur at sites of a wound or in sites that are predisposed to trauma, or may even appear in freshly healing wounds in previously normal horses, or re-occur at the same site following apparent complete surgical removal up to 10 or more years later ^{27,62,76}. Another author also reported an increased incidence of tumour development three to eight months after the healing of a wound ⁶⁶. The legs of CMZ in BNP are constantly exposed to trauma from this bush and this may explain the high frequency of lesions on the legs of CMZ in BNP. The biome in GDNR is mainly Nama karoo, with the dominant vegetation consisting of grassy, dwarf shrubland interspersed with grass like Tassel Bristlegrass (*Aristida congesta*) and Lehmann's Lovegrass (*Eragrostis lehmanniana*). On the stony plains, Kapokbush (*Eriocephalus ericoides*), Silverkaroo (*Plinthus karooicus*) and Perdekaroo (*Rosenia humilis*), amongst many other shrubs, are common and do not cause trauma to the skin as in the case of prickly bush. Some authors have also pointed out that in warmer climates (e.g. Australia and the southern United States), the limbs apparently are more frequently affected than in European countries and this can clearly be seen in this study with the high frequency of sarcoid lesions on the limbs in BNP ^{44,46,62}. Bastianello differed slightly from Jackson and reported the head, particularly the ear, followed by the trunk and limbs to be the commonest site for sarcoids ⁴. In another study of 1044 sarcoids, 39 % of lesions were on the head and neck, 26 % on the body and 35 % were on the legs ⁴⁸. Although CMZ in GDNR are reported to have a higher frequency of sarcoid on the head and neck, compared to BNP, most authors

agree that sarcoids can appear on any part of the body. Sarcoid lesions are however, more commonly found on the head and neck, ventral abdomen and limbs^{48,66,76}.

Most of the animals that suffered from sarcoids in BNP were adults. This is in agreement with other studies that reported sarcoids usually affecting horses from 1 to 6 years of age^{18,50}. During both times while the population were examined in BNP, no foals with any sarcoids lesions were detected. This may be due to the fact that a time factor is necessary for animals to come in contact with cattle and flies. At the same time it will take time to develop wounds so that transmission may occur via flies or by some other means.

Sarcoids, arising from multiple sites, have been reported to be relatively common⁶⁶. The reported incidence of multiple tumours in horses varies from 14 % to 84 %^{16,33,66}. This is in agreement with this study where 50 % of CMZ had multiple sarcoids in BNP. Sites that come in contact with existing sarcoids have shown a higher tendency for occurrence⁷⁷. This was clearly the case in one animal in this study (Q18) where we found additional sarcoid growths near or around the previous growth sites after 18 months. The stunting of this animal was a combination of the severe tumour formation as well as inability to graze normally.

CMZ in this study had a high incidence of the verrucous type (81,25 %) in relation to other types (18,75 %). There has been no or very little surgical interference with these lesions and this may account for the small percentage of fibroblastic lesions in this population. Following trauma or incomplete surgical removal, the verrucous type may often progress into the more aggressive fibroblastic type, which must be differentiated from excessive granulation tissue. The verrucous type is generally slow growing and becomes aggressive normally only when injured^{18,29,46}. This was clearly seen in the BNP where a stallion was recently humanely

destroyed as a result of a huge fibroblastic sarcoid. This sarcoid started off as verrucous, and due to the pendulous action underneath the body, which caused trauma, developed into the fibroblastic type. A similar case was observed in a captive Burchell's zebra stallion belonging to the National Zoological Gardens. It developed a verrucous sarcoid on the sheath. It was only partially resected and as a result developed into the fibroblastic sarcoid shown in Figure 15. This necessitated euthanasia of the animal. For the survival of CMZ it is therefore imperative to identify and treat these sarcoids at an early stage.

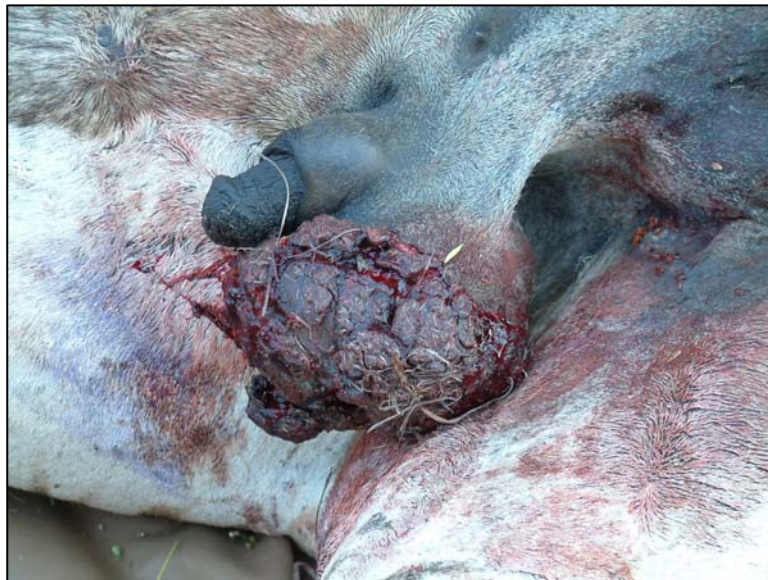

Figure 15: Fibroblastic sarcoid on sheath of a Burchell's zebra stallion

Other differential diagnoses for equine sarcoid include fibroma, fibrosarcoma, papilloma and neurofibroma. Although the clinical presentation may differ between the different types and some tumours may resemble sarcoid clinically, the histopathological appearance of equine sarcoid is quite characteristic. Observation of the entire excised tumour sectioned centrally is far superior to punch biopsies or sectional biopsies. All sarcoids were examined for the presence of the typical histological features that are present in equine sarcoid^{40,78}. These changes include epidermal hyperplasia, hyperkeratosis and thinning and partial surface

ulceration. An increased density of fibroblasts, replacing the dermal collagen and a whorling fibroblast pattern, characterizes the dermal changes. All sarcoids examined histologically in this study showed most or all of the abovementioned changes. Although it has been reported that the epidermal changes may be variable in equine sarcoid^{37,44}, all tumours show some pattern of fibroblast proliferation⁷⁸. In this study, several tumours had epidermal ulceration and hyperkeratosis and some tumours even had these changes within the same tumour. All tumours however were characterised by irregular bundles of capillary poor fibroblast proliferation of which the individual cells varied from plump to stellate in appearance. The cells had spindle shaped nuclei with occasional double nuclei and elongated eosinophilic cytoplasm. On the whole, very low mitotic indexes were visible. The infiltration of inflammatory cells was not seen, except in areas where ulceration was a prominent feature.

Although sarcoids have been diagnosed in BZ in isolated cases, there have been no confirmed reports of sarcoid in the relatively outbred BZ population in KNP. In our observation of a random group of BZ, we found the prevalence of sarcoid-like growths to be 1,5 %. This is in agreement with the prevalence of sarcoid in horses worldwide, which one can assume is a relative outbred population as well. The prevalence in our observed population of BZ may even be lower due to the fact that the animals were only observed from a distance and that none of these sarcoid-like growths were ever sampled and confirmed to be sarcoid. Some of these growths that were recorded may be normal warts on the skin or abnormal connective tissue after injury.

Treatment of equine sarcoid is notoriously difficult. No single approach to therapy has proved universally successful. Choice of and response to therapy may vary with the number of sarcoids present, the anatomic location of the sarcoid and the histological type of sarcoid. Of

the seven animals that were treated in BNP, six showed no evidence of sarcoids after 18 months, while one animal had to be destroyed due to extensive sarcoid growth on the body. These results were highly surprising to us. The two zebras that undergone surgery in the field showed no evidence of any regrowth after 18 months and the ventral abdomen appeared completely normal. In horses, surgical excision in horses has a high recurrence rate (>80 %), while chemotherapy usually relies on a set program over a couple of weeks to be followed if any rate of success is to be expected. Although the follow-up period was after 18 months only, any similar treatment given to horses would definitely not have had the same success rate. The reasons for the good results achieved in CMZ are uncertain and remains speculative. Inbreeding should potentially compromise the immune system, causing the sarcoids to become more aggressive. However, total resolution of the different sarcoid types suggests that there may be an exploitable immunological response in these animals. There are clearly some very interesting, poorly understood aspects of the sarcoids in CMZ relating to environmental factors, histocompatibility antigens and genetic diversity.

BNP management should look to attain more breeding stock from other parts of the country on a regular basis to try and improve the genetic diversity of CMZ in the park, as well as hopefully decrease the prevalence of equine sarcoid in CMZ in the park. If one could identify female individuals that are genetically susceptible to the equine sarcoid and remove them to an isolated area where they are crossbred with non-susceptible males, the population could over time be bred to be sarcoid resistant with improved genetic variability. However, not being able to identify genetically resistant and –susceptible CMZ currently is the most important shortcoming in managing this disease in the endangered Cape mountain zebra. In selected cases where single, small sarcoids appear on animals, any of the above-mentioned therapeutic modalities may be used with expected good results in the short term.

CHAPTER 6

CONCLUSIONS

It is apparent from this study that the growths in the CMZ in BNP were all sarcoids and have a similar aetiology as equine sarcoids. The relative small population had a very high prevalence of 53 % and this is most probably due to inbreeding as the Park's population went through a genetic bottleneck in previous years.

Most sarcoids were distributed on the trunk, followed by the limbs and then the head, while the verrucous type dominated the clinical appearance. Some fibroblastic and nodular forms were also diagnosed. The histopathology of the CMZ sarcoids was typical of sarcoids found in domestic horses.

A total of 7 of the affected CMZ were treated using four different methods. The sarcoids were surgically excised (n = 2), treated with intra-lesional 5-fluorouracil (n = 2), autogenous vaccine (n = 2) or autogenous vaccine combined with 5-fluorouracil (n = 1). The zebras were immobilised for examination 18 months later. One animal that had been treated with intra-lesional 5-fluorouracil had large numbers of verrucous and fibroblastic sarcoids. Her condition was so severe that she had to be euthanased. No signs of sarcoids could be found anywhere on the remaining 6 treated CMZ, possibly indicating that all four treatments implemented could be useful to treat this tumour in CMZ in BNP.

In a free ranging wildlife population, where minimal human interference is the ideal and treatment is difficult, the high prevalence of equine sarcoid poses a real problem. Park management together with scientists should consider researching the disease more intensively in the cytogenetic field because genetic susceptibility is a strong possibility in the endangered

CMZ. The research will not only benefit BNP, but also other parks where equine sarcoid is a problem, like GDNR, or is becoming a problem like MZNP.

REFERENCES

1. Abrahams F, Friedman Y and Daly B (eds) 2004 *Red Data Book of the Mammals of South Africa: A Conservation Assessment: CBSG Southern Africa*. Conservation Breeding Specialist Group (SSC/IUCN), Endangered Wildlife Trust, South Africa
2. Adams R, Calderwood M M, Peyton L C 1988 Excision of cutaneous tumours in the horse using histologic guidance. *Veterinary Surgery* 17: 241-245
3. Angelos J, Oppenheim Y, Rebhun W, Mohammed H, Antczak D F 1988 Evaluation of breed as a risk factor for sarcoid and uveitis in horses. *Animal Genetics* 19: 417-425
4. Bastianello S S 1983 A survey on neoplasia in domestic species over a 40-year period from 1935 to 1974 in the Republic of South Africa. IV. Tumours occurring in Equidae. *Onderstepoort Journal of Veterinary Research* 50: 91-96
5. Bertone A L, McClure J J 1990 Therapy for sarcoids. *Compendium Continuing Education Practising Veterinarian* 12: 262-265
6. Bigalke, R. Early history of the Cape Mountain Zebra. *African Wildlife* 6, 143-153. 1952
7. Bloch N, Breen M, Spradbrow P B 1994 Genomic sequences of bovine papillomaviruses in formalin-fixed sarcoids from Australian horses revealed by polymerase chain reaction. *Veterinary Microbiology* 41: 163-172
8. Brandt K, Ohnesorge B, Dopfer D, Deegen E 1996 Equine sarcoids - occurrence and treatment. *Pferdeheilkunde* 12: 739-748
9. Brostrom H 1995 Equine sarcoids. A clinical and epidemiological study in relation to equine leucocyte antigens (ELA). *Acta Veterinaria Scandinavica* 36: 223-236

10. Brostrom H, Fahlbrink E, Dubath M L, Lazary S 1988 Association between equine leucocyte antigens (ELA) and equine sarcoid tumours in the population of Swedish halfbreeds and some of their families. *Veterinary Immunology and Immunopathology* 19: 215-223.
11. Campbell R F, Pascoe R R 1984 Equine fibrosarcoma (sarcoid). *Refresher course for veterinarians* Sydney, 21-25 May 1984, 129-135; 30 ref. Sydney, Australia; Post-Graduate Committee in Veterinary Science: 21-25.
12. Carr E A, Theon A P, Madewell B R, Griffey S M, Hitchcock M E 2001 Bovine papillomavirus DNA in neoplastic and nonneoplastic tissues obtained from horses with and without sarcoids in the western United States. *American Journal of Veterinary Research* 62: 741-744
13. Carr E A, Theon A P, Madewell B R, Hitchcock M E, Schlegel R, Schiller J T 2001 Expression of a transforming gene (E5) of bovine papillomavirus in sarcoids obtained from horses. *American Journal of Veterinary Research* 62: 1212-1217
14. Chambers G, Ellsmore V A, O'Brien P M, Reid S W, Love S, Campo M S, Nasir L 2003 Association of bovine papillomavirus with the equine sarcoid. *Journal of General Virology* 84: 1055-1062
15. Cheevers W P, Roberson S M, Brassfield A L, Davis W C, Crawford T B 1982 Isolation of a retrovirus from cultured equine sarcoid tumor cells. *American Journal of Veterinary Research* 43: 804-806
16. Cotchin E 1977 A general survey of tumours in the horse. *Equine Veterinary Journal* 9: 16-21

17. Fadok V A 1995 Overview of equine papular and nodular dermatoses. *Veterinary Clinics of North America, Equine Practice* 11: 61-74
18. Foy J.M., Rashmir-Raven A.M., Brashier M.K. 2002 Common Equine Skin Tumours. *Compendium Continuing Education Practising Veterinarian* 24: 242-253
19. Fretz P B, Barber S M 1980 Prospective analysis of cryosurgery as the sole treatment for equine sarcoids. *Veterinary Clinics of North America, Small Animal Practice* 10: 847-859
20. Genetzky R M, Biwer R D, Myers R K 1983 Equine sarcoids: causes, diagnosis, and treatment. *Compendium Continuing Education Practising Veterinarian* 5: S416-S420, S422
21. Gerber H, Dubath M L, Lazary S, Powell D G 1988 Association between predisposition to equine sarcoid and MHC in multiple-case families. *Equine Infectious Diseases V: proceedings of the fifth International Conference* 272-277; 11 ref
22. Goodrich L, Gerber H, Marti E, Antczak D F 1998 Equine sarcoids. *Veterinary Clinics of North America, Equine Practice* 14: 607-623
23. Head K W 1965 Some Data Concerning the Distribution of Skin Tumours in Domestic Animals. In Rook A.J, Walton G S (eds.) *Comparative Physiology and Pathology of the Skin*. FA Davis & Co, Philadelphia: 615-636
24. HMB, Strafuss A C, Smith J E, Dennis J E, Anthony H D 1973 Sarcoid in horses. *Veterinary Medicine and Small Animal Clinician* 68: 1246-1247
25. Hoffman K D, Kainer R A, Shideler R K 1983 Radio-frequency current-induced hyperthermia for the treatment of equine sarcoid. *Equine Practice* 5: 24

26. Houlton J F 1983 Treatment of periocular equine sarcoids. *Equine Veterinary Journal* Suppl. 2, 117-122; 30 ref., 8 fig.
27. Jackson C 1936 The incidence and pathology of Tumours of Domestic Animals in South Africa. A study of the Onderstepoort collection of Neoplasms with special reference to their Histopathology. *Onderstepoort Journal of Veterinary Research* 6: 249 – 378
28. Knottenbelt D C, Matthews J B 2001 A positive step forwards in the diagnosis of equine sarcoid. *Veterinary Journal* 161: 224-226
29. Knottenbelt D, Edwards S, Daniel E 1995 Diagnosis and treatment of the equine sarcoid. *In Practice* 17 (3): 123-129
30. Knottenbelt D C 2001 Facts you need to know about sarcoids. *Proceedings of the 33rd Annual Congress of the Equine Practitioners Group of the SAVA*, 33 – 42
31. Knottenbelt D C, Walker J A 1994 Topical treatment of the equine sarcoid. *Equine Veterinary Education* 6: 72-75
32. Lancaster W D, Theilen G H, Olson C 1979 Hybridization of bovine papilloma virus type 1 and type 2 DNA to DNA from virus-induced hamster tumours and naturally occurring equine tumours. *Intervirology* 11: 227-233
33. Lane J G 1977 The treatment of equine sarcoids by cryosurgery. *Equine Veterinary Journal* 9: 127-133
34. Laursen B A 1987 Treatment of equine sarcoids by cryosurgery. *Dansk Veterinaertidsskrift* 70: 97-104

35. Lavach J D, Sullins K E, Roberts S M, Severin G A, Wheeler C, Lueker D C 1985 BCG treatment of periocular sarcoid. *Equine Veterinary Journal* 17: 445-448
36. Lazary S, Gerber H, Glatt P A, Straub R 1985 Equine leucocyte antigens in sarcoid-affected horses. *Equine Veterinary Journal* 17: 283-286
37. Lepage M F, Carstanjen B, Tschärner C v, Von T C 1998 Equine sarcoid (part I): causes, diagnosis, differential diagnosis. *Praktische Tierarzt* 79: 627-636
38. Lewis R.E. 1964 Radon implant therapy of squamous cell carcinoma and equine sarcoid. *Proceedings American Association of Equine Practitioners* 10, 217-220
39. Lory S, Tschärner C, Marti E, Bestetti G, Grimm S, Waldvogel A, Von T C 1993 In situ hybridisation of equine sarcoids with bovine papilloma virus. *Veterinary Record* 132: 132-133
40. Martens A, De Moor A, Demeulemeester J, Ducatelle R 2000 Histopathological characteristics of five clinical types of equine sarcoid. *Research in Veterinary Science* 69: 295-300
41. Martens A, De Moor A, Ducatelle R. 2001 PCR detection of bovine papillomavirus DNA in superficial swabs and scrapings from equine sarcoids. *The Veterinary Journal* 161: 280 – 286
42. Martens A, De Moor A, Demeulemeester J, Peelman L 2001 Polymerase chain reaction analysis of the surgical margins of equine sarcoids for bovine papilloma virus DNA. *Veterinary Surgery* 30: 460-467
43. Martens A, De Moor A, 1996 Equine Sarcoid – Clinical Types, Prevalence, Epidemiology, Etiology and Pathogenesis. *Vlaams Diergeneesk Tijdschr* 65(1), 10-17

44. Marti E, Lazary S, Antczak D F, Gerber H 1993 Report of the first international workshop on equine sarcoid. *Equine Veterinary Journal* 25: 397-407
45. McConaghy F F., Davis R. E., Hodgson, D R 1994 Equine Sarcoid - A Persistent Therapeutic Challenge. *Compendium Continuing Education Practising Veterinarian* 16(8), 1022-1031.
46. McConaghy F F., Davis R E, Hodgson D R 1996 Equine sarcoid: a persistent therapeutic challenge. *Ippologia* 7: 41-44, 47
47. Meredith D, Elser A H, Wolf B, Soma L R, Donawick W J, Lazary S 1986 Equine leukocyte antigens: relationships with sarcoid tumours and laminitis in two pure breeds. *Immunogenetics* 23: 221-225
48. Miller R I, Campbell R F 1982 A survey of granulomatous and neoplastic diseases of equine skin in north Queensland. *Australian Veterinary Journal* 59: 33-37
49. Miller R I, Norton J H, Summers P M 1980 Black-grained mycetoma in two horses. *Australian Veterinary Journal* 56: 347-348
50. Mohammed H O, Rebhun W C, Antczak D F 1992 Factors associated with the risk of developing sarcoid tumours in horses. *Equine Veterinary Journal* 24: 165-168
51. Moodley Y. 2002 Population structuring in southern African zebras. *PhD Thesis*, University of Cape Town.
52. Nasir L, McFarlane S T, Torrontegui B O, Reid S J 1997 Screening for bovine papillomavirus in peripheral blood cells of donkeys with and without sarcoids. *Research in Veterinary Science* 63: 289-290

53. Nasir L, Reid S W 1999 Bovine papillomaviral gene expression in equine sarcoid tumours. *Virus Res* 61: 171-175
54. Nel P.J, Bertschinger H 2006 Descriptive study of an outbreak of equine sarcoid in a population of Cape mountain zebra (*Equus zebra zebra*) in the Gariep Nature Reserve. *Journal of the South African Veterinary Association* (77) 4: 184 – 190
55. Newton, S. A 2000 Periocular sarcoids in the horse: Three cases of successful treatment. *Equine Veterinary Education* 12(3), 137-143.
56. Novellie P, Lindeque, M., Lindeque P, Lloyd P, and Koen J 2002 *Status and Action Plan for the Mountain Zebra (Equus zebra)*. IUCN/SSC Equid Specialist Group 28: 8-42
57. Otten N, Tschärner C v, Lazary S, Antczak D F, Gerber H, Von T C 1993 DNA of bovine papillomavirus type 1 and 2 in equine sarcoids: PCR detection and direct sequencing. *Archives of Virology* 132: 121-131
58. Owen R R, Jagger D W 1987 Clinical observations on the use of BCG cell wall fraction for treatment of periocular and other equine sarcoids. *Veterinary Record* 120: 548-552
59. Palmer S E 1989 Carbon dioxide laser removal of a verrucous sarcoid from the ear of a horse. *Journal of the American Veterinary Medical Association* 195: 1125-1127
60. Palmer S E 1990 Clinical use of a carbon dioxide laser in an equine general surgery practice. *Proceedings of the Annual Convention of the American Association of Equine Practitioners* 35: 319 – 329
61. Pascoe R R 1981 Skin tumours in the horse – types and treatment. *Refresher course for veterinarians Sydney, 9 – 13 February 1981*, 67 – 92; 36 ref. Sydney, Australia; Post-Graduate Committee in Veterinary Science

62. Pascoe R R, Knottenbelt D C 1999 *Manual of Equine Dermatology*. WB Saunders, London, 244 – 252
63. Pascoe R R, Summers P M 1981 Clinical survey of tumours and tumour-like lesions in south east Queensland. *Equine Vet J* 13: 235-239
64. Penzhorn, B. L. and Novelli, P. A. 1991 Management implications of Cape Mountain Zebra. *Proceedings of an International Symposium on Capture, Care and Management of Threatened Mammals, Wildlife Group of the SAVA* 12-16
65. Penzhorn, B. L. and Novelli, P. A 1991 Some behavioural traits of Cape Mountain zebras (*Equus zebra zebra*) and their implications for the management of a small conservation area. *Applied Animal Behaviour Science* 29: 293-299
66. Ragland W L, Keown G.H., Spencer G R 1970 Equine Sarcoid. *Equine Vet J* 2: 2-11
67. Ragland W. L., McLaughlin C. A, and Spencer, G. R 1970 Attempts to relate bovine papilloma virus to the cause of equine sarcoid: Horses, donkeys and calves inoculated with equine sarcoid extracts. *Equine Vet J* 2, 168-172
68. Ragland, W L., Spencer G. R 1968 Attempts to relate bovine papilloma virus to the cause of equine sarcoid: Immunity to bovine papilloma virus. *Am.J.Vet.Res* 29, 1363-1366
69. Ragland W L., Spencer G. R 1969 Attempts to relate bovine papilloma virus to the cause of equine sarcoid: Equidae inoculated intradermally with bovine papilloma virus. *Am.J.Vet.Res* 30, 743-752
70. Reid S J, Smith K T, Jarrett W H 1994 Detection, cloning and characterisation of papillomaviral DNA present in sarcoid tumours of *Equus asinus*. *Veterinary Record* 135: 430-432



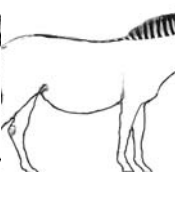
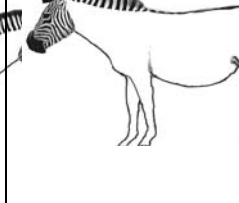


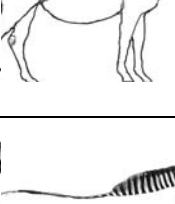
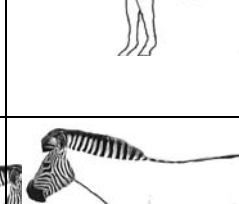


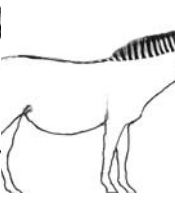
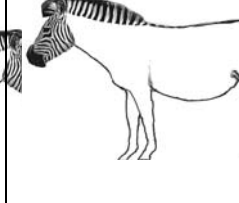


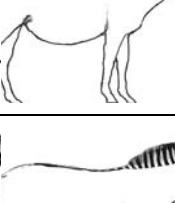
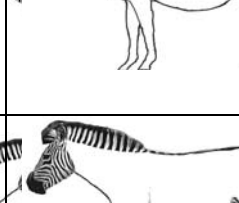


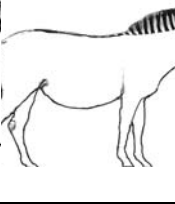
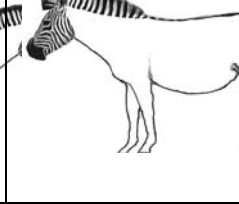


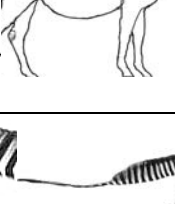
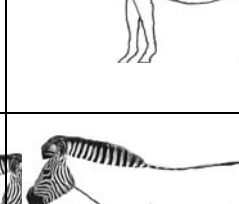


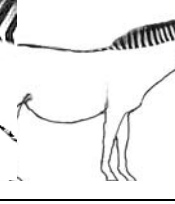
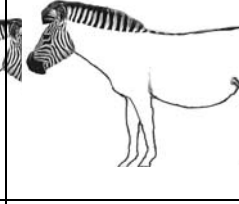


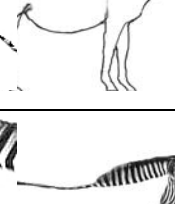
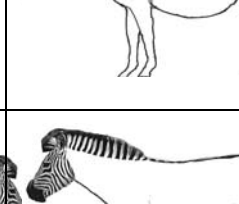



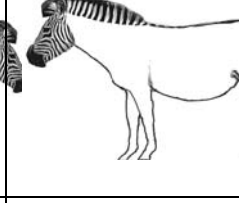


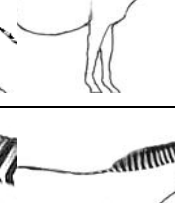
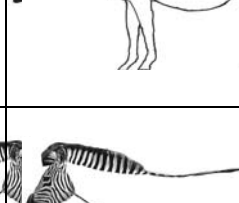


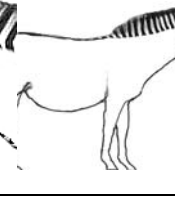
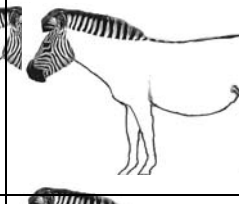


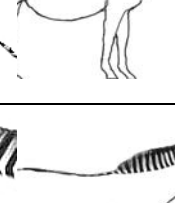
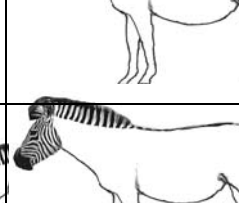


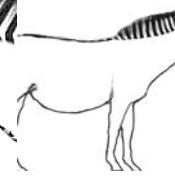




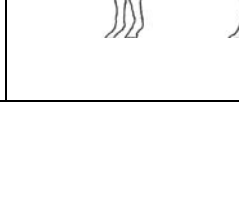
71. Scott DW., Miller W H 2003 *Equine Dermatology*. WB Saunders, 719 – 727
72. Smith H.A. and Jones T.C. 1966 *Veterinary Pathology*. (3rd Edition), Philadelphia, Lea and Febiger, p 269
73. Stannard A A, FJ M 1977 Equine dermatology. *Proceedings, 22nd Annual Convention, American Association of Equine Practitioners*, 273-292
74. Stannard A A, Loomis E C, Halliwell R C, Theilen G H 1983 Skin diseases. *Current Therapy in Equine Medicine* 527-558 WB Saunders, London 527 – 558
75. Steiner A 1989 Testing the immunotherapeutic drug Nomagen for treatment of equine sarcoids in comparison with cryosurgical treatment. *Schweizer Archiv fur Tierheilkunde* 131: 52-53
76. Sullins K E, Lavach J D, Roberts S M, Severin G A, Lueker D 1986 Equine sarcoid. *Equine Practice* 8: 21-27
77. Sundberg J P, Burnstein T, Page E H, Kirkham W W, Robinson F R 1977 Neoplasms of Equidae. *Journal of the American Veterinary Medical Association* 170: 150-152
78. Tarwid J N, Fretz P B, Clark E G 1985 Equine sarcoids: a study with emphasis on pathologic diagnosis. *Compendium on Continuing Education for the Practicing Veterinarian* 7: S293-S300
79. Teifke J P 1994 Morphological and molecular biological studies on the aetiology of equine sarcoids. *Tierarztliche Praxis* 22: 368-376

80. Theon A P, Pascoe J R, Carlson G P, Krag D N 1993 Intratumoral chemotherapy with cisplatin in oily emulsion in horses. *Journal of the American Veterinary Medical Association* 202: 261-267
81. Thomsett L R 1979 Skin diseases of the horse. *In Practice* 1: 15-26
82. Tizard I 1987 Veterinary Immunology. An introduction. 3rd Edition, WB Saunders, 15 - 17
83. Trenfield K, Spradbrow P B, Vanselow B 1985 Sequences of papillomavirus DNA in equine sarcoids. *Equine Veterinary Journal* 17: 449-452
84. Turrel, J. M. 1985 Preliminary results of therapeutic drug matrix implants for equine sarcoid and canine mast cell tumour. *Proc.vet.Cancer Soc.Meet. (May)* 205 – 222
85. Turrel J M, Stover S M, Gyorgyfalvy J 1985 Iridium-192 interstitial brachytherapy of equine sarcoid. *Veterinary Radiology* 26: 20-24
86. Vanselow B A, Abetz I, Jackson A B 1988 BCG emulsion immunotherapy of equine sarcoid. *Equine Veterinary Journal* 20: 444-447
87. Vanselow B A, Spradbrow P B, MJ S 1996 Equine and bovine papillomavirus infections. *Virus infections of equines*, 83-94; *Virus infections of vertebrates*, Volume 6
88. Vingerhoets M, Diehl M, Gerber H, Stornetta D, Rausis C 1988 Treatment of equine sarcoid by CO² laser. *Schweizer Archiv fur Tierheilkunde* 130: 113-126
89. Voss J L 1969 Transmission of equine sarcoid. *Am.J.Vet.Res* 30: 183-191
90. Walker M, Adams W, Hoskinson J, Held J P, Blackford J, Geiser D, Goble D, Henton J 1991 Iridium-192 brachytherapy for equine sarcoid, one and two year remission rates. *Veterinary Radiology* 32: 206-208

91. Webster C J, Webster J M 1985 Treatment of equine sarcoids with BCG. *Veterinary Record* 116: 131-132
92. Wyman M, Rings M D, Tarr M J, Alden C L 1977 Immunotherapy in equine sarcoid: a report of two cases. *Journal of the American Veterinary Medical Association* 171: 449-451
93. Wyn-Jones G 1983 Treatment of equine cutaneous neoplasia by radiotherapy using iridium 192 linear sources. *Equine Veterinary Journal* 15: 361-365

ADDENDUM I

SARCOID DATA COLLECTION SHEET

ZEBRA		SIDE			BIOPSY		
Sex	Age		R	L			
M	F					Yes/No	01
F	SA					no. _____	
	A						
M	F					Yes/No	02
F	SA					no. _____	
	A						
M	F					Yes/No	03
F	SA					no. _____	
	A						
M	F					Yes/No	04
F	SA					no. _____	
	A						
M	F					Yes/No	05
F	SA					no. _____	
	A						
M	F					Yes/No	06
F	SA					no. _____	
	A						
M	F					Yes/No	07
F	SA					no. _____	
	A						