



## CLINICAL RESEARCH

# Assessment of the Prevalence of Radix Entomolaris and Distolingual Canal in Mandibular First Molars in 15 Countries: A Multinational Cross-sectional Study with Meta-analysis

Fatma Pertek Hatipoğlu, MSc,<sup>\*</sup>  
 Güldane Mağat, PhD,<sup>†</sup>  
 Ömer Hatipoğlu, MSc,<sup>‡</sup> Hanan  
 Al-khatib, MClinDent,<sup>§</sup>  
 Anas S. Elatrash, MSc,<sup>||</sup>  
 Imran Zainal Abidin, BDS,<sup>¶</sup>  
 Tomasz Kulczyk, PhD,<sup>#</sup> Moataz-  
 Bellah Ahmed Mohamed Alkhawas,  
 BDS, MSc, PhD,<sup>\*\*</sup>  
 Glynn Dale Buchanan, BChD, MSc,  
 PhD,<sup>††</sup> Maira Kopbayeva, DSc,<sup>‡‡</sup>  
 Sugumaran Surendar, BDS, MDS<sup>§§</sup>  
 Muhammad Qasim Javed, BDS,  
 FCPS, MSc,<sup>|||</sup> Ahmed A. Madfa,  
 PhD,<sup>¶¶###</sup> Sebastian Bürklein,<sup>\*\*\*</sup>  
 Sarah Mimica,<sup>†††</sup>  
 Usman Anwer Bhatti, BDS,  
 FCPS,<sup>†††</sup>  
 Tulegenova Indira Maratovna,  
 MSc,<sup>§§§</sup> Paulo J. Palma, DMD, MSc,  
 PhD,<sup>||||¶¶¶¶</sup> and  
 João Filipe Brochado Martins,  
 MSc<sup>###</sup>

## SIGNIFICANCE

It is crucial for dental professionals to exercise caution and meticulousness when it comes to observing the existence of DLC in M1M in order to prevent any possibility of misdiagnosis that could result in post-treatment complications. The worldwide prevalence of RE and DLC stands at approximately 3% and 22% correspondingly, making it all the more imperative for dentists to remain vigilant in their examination.

From the <sup>\*</sup>Department of Endodontics, Nigde Omer Halisdemir University, Niğde, Turkey; <sup>†</sup>Faculty of Dentistry, Department of Oral Radiology, Necmettin Erbakan University, Konya, Turkey; <sup>‡</sup>Department of Restorative Dentistry, Nigde Omer Halisdemir University, Niğde, Turkey; <sup>§</sup>Private Practice, Aljarah Dental Care, Irbid, Jordan; <sup>||</sup>Faculty of Dentistry, Department of Conservative Dentistry and Endodontics, Libyan International Medical

## ABSTRACT

**Aim:** The aim of this study was two-folded: i) to assess the prevalence of Distolingual Canal (DLC) and Radix Entomolaris (RE) in Mandibular First Molars (M1Ms), using Cone Beam Computed Tomography (CBCT) images and ii) to assess the impact of sociodemographic factors on the prevalence of these conditions worldwide. **Methods:** CBCT images were scanned retrospectively and the ones including bilateral M1Ms were included in the study. The evaluation was performed by 1 researcher in each country, trained with CBCT technology. A written and video instruction program explaining the protocol to be followed step-by-step was provided to all observers to calibrate them. The CBCT imaging screening procedure consisted of evaluating axial sections from coronal to apical. The presence of DLC and RE in M1Ms (yes/no) was identified and recorded. **Results:** Six thousand three hundred four CBCTs, representing 12,608 M1Ms, were evaluated. A significant difference was found between countries regarding the prevalence of both RE and DLC ( $P < .05$ ). The prevalence of DLC ranged from 3% to 50%, and the overall prevalence was 22% (95% CI: 15%–29%). RE prevalence ranged from 0% to 12%, and the overall prevalence was 3% (95% CI: 2%–5%). There were no significant differences between left and right M1Ms or between genders for either DLC or RE ( $P > .05$ ). **Conclusion:** The overall prevalence of RE and DLC in M1Ms was 3% and 22%. Additionally, both RE and DLC showed substantial bilaterally. These variations should be considered by endodontic clinicians during endodontic procedures in order to avoid potential complications. (*J Endod* 2023;49:1308–1318.)

## KEY WORDS

CBCT; Distolingual canal; Endodontics; Prevalence; Radix entomolaris; Root canal anatomy

Understanding the anatomical variations of the root canal system is imperative for the successful execution of root canal therapy. Failure to detect and address anatomical and morphological variations can lead to incomplete elimination of micro-organisms and inflamed or infected pulp tissue, which can ultimately result in the onset or persistence of apical periodontitis (AP). Several studies have found a higher prevalence of posttreatment AP in teeth with missed canals<sup>1,2</sup>. Thus, with detailed anatomical

knowledge, predicting complications that may occur during and after root canal treatment can increase treatment success.

Due to their complex morphology, mandibular first permanent molars (M1Ms) present a significant challenge in terms of effective cleaning and shaping. The mesial root of M1Ms frequently has two canals, while the distal root may contain one or two canals<sup>3</sup>. One of the most common variations is the presence of an additional distolingual root and distolingual canal (DLC)<sup>4</sup>. Another morphological variant is the radix entomolaris (RE), a third root located distolingually, which is typically shorter and more curved than the

distobuccal root (DB). If a canal is present in the RE, it can pose difficulties in terms of shaping, cleaning, and filling in comparison to the main DB canal<sup>5</sup>. The DLC is situated more lingual from the main distal canal, and the traditional access cavity must be modified to create a trapezoidal shape to locate the entrance to the DLC<sup>6</sup>.

To investigate root configurations and canal morphology, various imaging techniques have been employed, including 2-dimensional radiographs, scanning electron microscopy<sup>7</sup>, microcomputed tomography (mCT)<sup>3</sup>, and cone beam computed tomography (CBCT)<sup>8</sup>. CBCT provides 3D reconstruction imaging and has been acknowledged as a highly sensitive diagnostic tool for identifying the presence of the RE, distolingual root, and (DLC)<sup>4</sup>.

Numerous studies have demonstrated that genetic, racial, and ethnic factors can affect the shape and morphology of the root and root canals of molars<sup>5,9</sup>. The morphology of the root and root canals has been found to vary significantly within and between populations, as well as within the same individual<sup>10</sup>. Although the prevalence rates of DLC and RE have been previously assessed in various countries, a substantial disparity exists between the lowest and the highest reported values, possibly due to methodological and ethnic heterogeneities<sup>9</sup>. Global-scale studies with large sample sizes and meta-analyses may help to address this issue in the literature. Moreover, the bilaterally of DLC and RE has not yet been evaluated on a global level.

Therefore, the objective of this cross-sectional study is two-fold: (i) to determine the global prevalence of DLC and RE in mandibular first permanent molars *in vivo*, utilizing CBCT images and (ii) to investigate the potential influence of sociodemographic factors, such as age and gender, on the prevalence of DLC and RE. The first null hypothesis posits that there are no significant differences in the prevalence of DLC and RE among different geographical regions worldwide. The second null hypothesis is that none of the examined sociodemographic factors exert an effect on the prevalence of DLC and RE.

## MATERIAL AND METHODS

### Research Protocol

This is a multinational cross-sectional study conducted from January 2022 to August 2022. The study protocol was developed in adherence to the guidelines recommended for conducting cross-sectional epidemiological studies utilizing CBCT technology to assess root canal anatomy. The study protocol was designed in accordance with the Strengthening the Reporting of Observational

Studies in Epidemiology guidelines (Supplemental Material S1). The ethical committee at Necmettin Erbakan University in Turkey granted ethical approval with protocol number 2021/12-93. Each researcher involved in the study was accountable for adhering to the ethical standards set forth by their respective country.

The formula  $n = \frac{Z^2 P(1-P)}{d^2}$  was used to calculate the sample size<sup>11</sup>. With a 95% confidence level ( $Z = 1.96$ ), 5% precision, and 25% expected DLC prevalence based on a prior study<sup>12</sup>, at least 144 CBCT images that will include 288 bilateral M1Ms were planned to be included.

Diagnostic-quality CBCT images taken according to manufacturer-specified references that were obtained for various reasons, including treatment planning in cases of implant surgery, tooth impaction, orthodontic therapy, or trauma, were included in the study, along with demographic information such as gender and age. The images that did not have M1Ms bilaterally were excluded. Besides, the teeth with incomplete apex formation, crown-bridge prostheses, root canal treatment, or root resorption from the evaluation were excluded.

The prevalence of both DLC and RE in M1Ms was analyzed once by 1 expert in endodontics or in oral and maxillofacial radiology from each country included. G.M. prepared a randomized 20 CBCT images and sent them to observers (to 1 observer for each country). Intraobserver reliability test (Cohen's kappa) was performed for each country, reviewing 20 CBCT images twice, one month apart. Besides, Fleiss' kappa test was conducted among all observers to examine the interobserver reliability.

By reviewing existing CBCT images, the data were obtained in accordance with the position statement of the American Association of Endodontists and Oral and Maxillofacial Radiologists<sup>13</sup>. A written and video instruction (prepared by G.M) showing the protocol to be followed step-by-step was provided to all observers in order to calibrate them with respect to the CBCT reviewing methodology and the anatomical landmark definitions. Tomography sections were visualized in axial, coronal and sagittal planes using the software of the CBCT devices. The researchers were freed to adjust the contrast and brightness of the images using the software's image processing tool to ensure optimum visualization. The long axis of each mandibular first molar was determined, and images were examined in cross-sections up to the apical third of the root by moving the toolbar from the pulp chamber to the apex of the tooth. All observers were allowed to

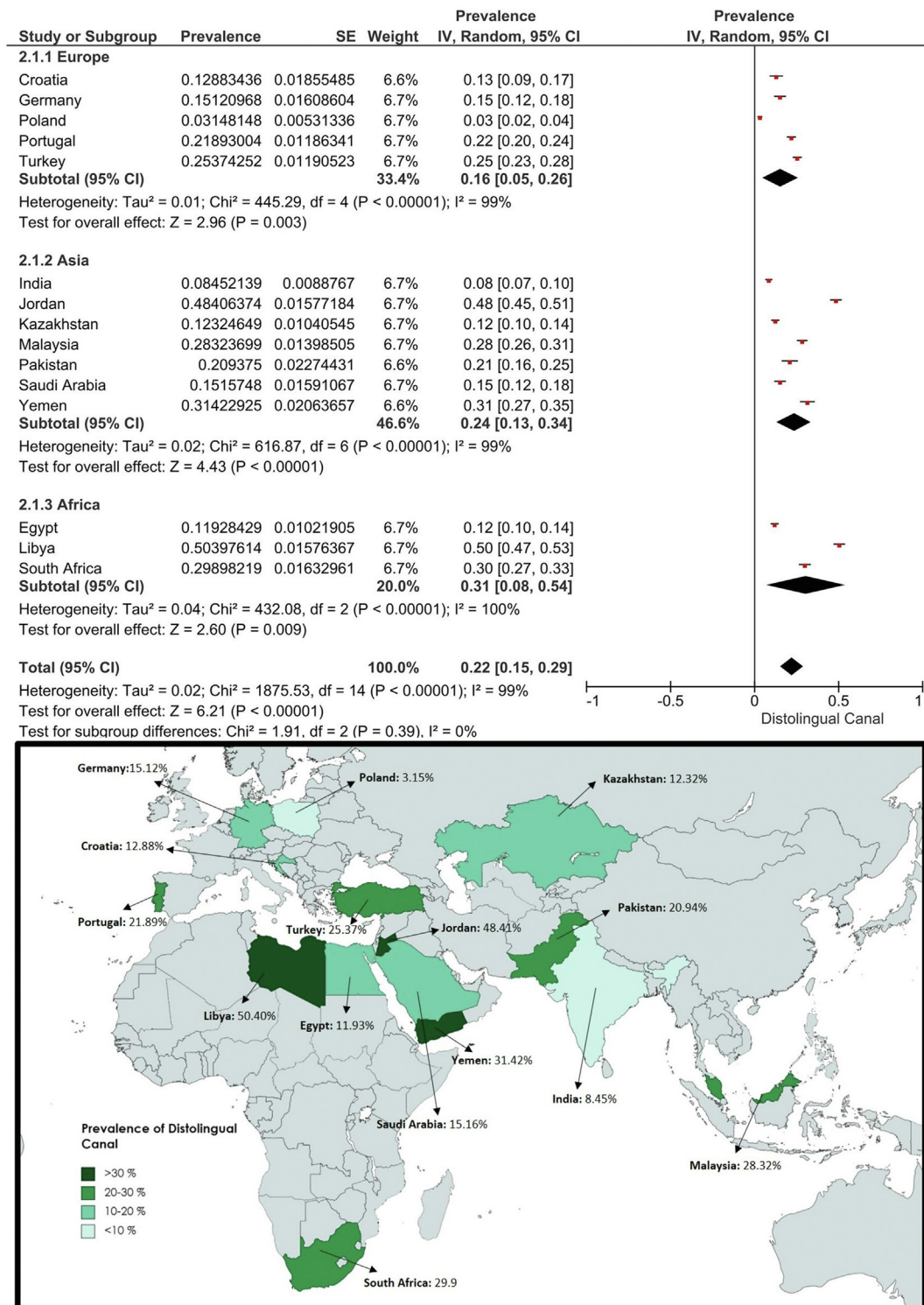
University, Benghazi, Libya; <sup>¶</sup>Department of Restorative Dentistry, International Islamic University Malaysia (IIUM), Kuala Lumpur, Malaysia; <sup>#</sup>Department of Diagnostics, Poznan University of Medical Sciences, Poznan, Poland; <sup>\*\*</sup>Faculty of Dental Medicine, Department of Endodontic, Al-Azhar University, Cairo, Egypt; <sup>††</sup>Department of Odontology, School of Dentistry, Faculty of Health Sciences, University of Pretoria, Pretoria, South Africa; <sup>‡‡</sup>Kazakh National Medical University Asfendiyarov, Kazakhstan; <sup>§§</sup>Department of Conservative Dentistry and Endodontics, Saveetha Dental College, Saveetha Institute of Medical and Technical Sciences, Chennai, Tamil Nadu, India; <sup>|||</sup>Department of Conservative Dental Sciences and Endodontics, College of Dentistry, Qassim University, Buraydah, Qassim, Saudi Arabia; <sup>¶¶</sup>Department of Restorative Dental Science, College of Dentistry, University of Ha'il, Ha'il, Saudi Arabia; <sup>##</sup>Department of Conservative Dentistry, Faculty of Dentistry, Thamar University, Dhamar, Yemen; <sup>\*\*\*</sup>Central Interdisciplinary Ambulance in the School of Dentistry, University of Münster, Münster, Germany; <sup>†††</sup>Department of Endodontics and Restorative Dentistry, School of Dental Medicine, University of Zagreb, Zagreb, Croatia; <sup>††††</sup>Department of Operative Dentistry and Endodontics, Riphah International University, Islamabad, Pakistan; <sup>§§§</sup>Department of Therapeutic Dentistry, Kazakh National Medical University Asfendiyarov, Almaty, Kazakhstan; <sup>||||</sup>Center for Innovation and Research in Oral Sciences (CIROS), Faculty of Medicine, University of Coimbra, Coimbra, Portugal; <sup>¶¶¶</sup>Institute of Endodontics, Faculty of Medicine, University of Coimbra, Coimbra, Portugal; and <sup>###</sup>Private Practice Limited to Endodontics, Amsterdam, The Netherlands.

Address requests for reprints to Dr Paulo J. Palma, Institute of Endodontics and Center for Innovation and Research in Oral Sciences (CIROS), Faculty of Medicine, University of Coimbra, 3000-075 Coimbra, Portugal. E-mail address: [ppalma@uc.pt](mailto:ppalma@uc.pt) 0099-2399

Copyright © 2023 The Authors. Published by Elsevier Inc. on behalf of American Association of Endodontists. This is an open access article under the CC BY-NC-ND license (<http://creativecommons.org/licenses/by-nc-nd/4.0/>). <https://doi.org/10.1016/j.joen.2023.06.011>

**TABLE 1** - Information Regarding the Exposure Parameters and the Origin of the Devices Used in Every Country

Continent	Country	City	Ethnic groups	CBCT database	Observer	CBCT model (CBCT brand)	Voxel size	FOV	Visualization software	Date of CBCT acquisition
Europe	Germany	Muenster	German	Private clinic	S.B.	Planmeca Promax 3D (Planmeca, Helsinki, Finland)	160 $\mu$ m	8 $\times$ 8 cm	Planmeca Romexis Viewer 5.0	2009-2018
Asia	Saudi Arabia	Buraidah Saudi	Arabs	University clinic	M.Q.J.	Sirona galileos comfort (Beinshiem, Germany)	160 $\mu$ m	15 $\times$ 15 cm	GALILEOS Viewer version 1.8	2018-2022
Africa	South Africa	Pretoria	Mixture of black and white	University clinic	G.D.B.	Planmeca Promax 3D (Planmeca, Helsinki, Finland)	200 $\mu$ m	10 $\times$ 9 cm	Romexis (Planmeca)	2011- 2022
Europe	Portugal	Coimbra	Portuguese	University clinic	P.J.P.	i-CAT (i-CAT, Hatfield, England)	200 $\mu$ m	10 $\times$ 8 cm	i-CATvision (i-CAT, Hatfield, England)	2017-2022
Asia	Jordan	Irbid	white	Private practice	H.A.	Care stream CS8100SC 3D	150 $\mu$ m	8 $\times$ 9 cm	CareStream 3D	2021-2022
Asia	Yemen	Yemen	Arab	University clinic	A.M.A.	Pax - I 3D Green 15x15	170 $\mu$ m	12 $\times$ 9 cm	Cs 3D imaging v3.10.12	2019-2022
Asia	Kazakhstan	Almaty	Asian	Private clinic	M.K.	Orthophos XG3D (Sirona)	100 $\mu$ m	8 $\times$ 8 cm	Sidexis4(Sirona)	2022
Africa	Libya	Benghazi	Arab	Private clinic	A.S.E.	Care stream CS 8100	150 $\mu$ m	8 $\times$ 9 cm	CS 3D Imaging Light	2022
Asia	Malaysia	Kuantan	Malay	Private practice	I.Z.A.	Newton Giano HR advanced	150 $\mu$ m	13 $\times$ 8 cm	NewTom's NNT	2022
Africa	Egypt	Cairo	Egyptian	Private clinic	M.A.M.A	Planmeca Promax 3D (Planmeca, Helsinki, Finland)	150 $\mu$ m	8 $\times$ 8 cm	Romexis (Planmeca)	2015-2022
Asia	Pakistan	Islamabad	Pakistani Punjabis	Imaging facility	U.A.B.	Planmeca Promax 3D (Planmeca, Helsinki, Finland)	200 $\mu$ m	13 $\times$ 19 cm	Romexis (Planmeca)	2022
Europe	Poland	Poznań	Slavic	University clinic	T.K.	Cranex 3Dx CRAN (Soredex Oy, Tuusula, Finland)	200 $\mu$ m	6 $\times$ 8 cm	OnDemand	2021-2022
Europe	Croatia	Zagreb	South Slavic ethnic group	Private clinic	S.K.	Cranex 3D CBCT system (Soredex, Tusula, Finland)	200 $\mu$ m	5 $\times$ 10 cm	OnDemand 3D Dental software (Cybermed, Seoul, Korea)	2019-2022
Asia	India	Mumbai	Indo-Aryan	University clinic	S.S.	CS9600	150 $\mu$ m	8 $\times$ 9 cm	Sidexis	2021-2022
Europe	Turkey	Konya	Turkish	University clinic	G.M.	Morita 3D Accuitomo 170	200 $\mu$ m	10 $\times$ 10 cm	i-Dixel	2018-2022




**FIGURE 1** – Forest plot presentation and depiction of DLC prevalence by country.

manipulate the visualization settings and tools (such as noise reduction or specific filters) to improve the quality of the output image. The presence of a DLC and RE (yes/no) was identified and recorded as described by Calberson, De Moor<sup>14</sup>.

A RE was defined as an additional small root present lingual to the main distal root, commonly curved. The RE can be separated from, or partially fused with, the other roots. The RE can be classified according to the course of the root in the bucco-lingual plane:

type I refers to a straight root, type II to an initially curvature that continues as a straight root, and type III to an initial curve in the coronal third of the root canal, followed by a second curve beginning in the middle and continuing to the apical<sup>5</sup>. All types of RE were included in



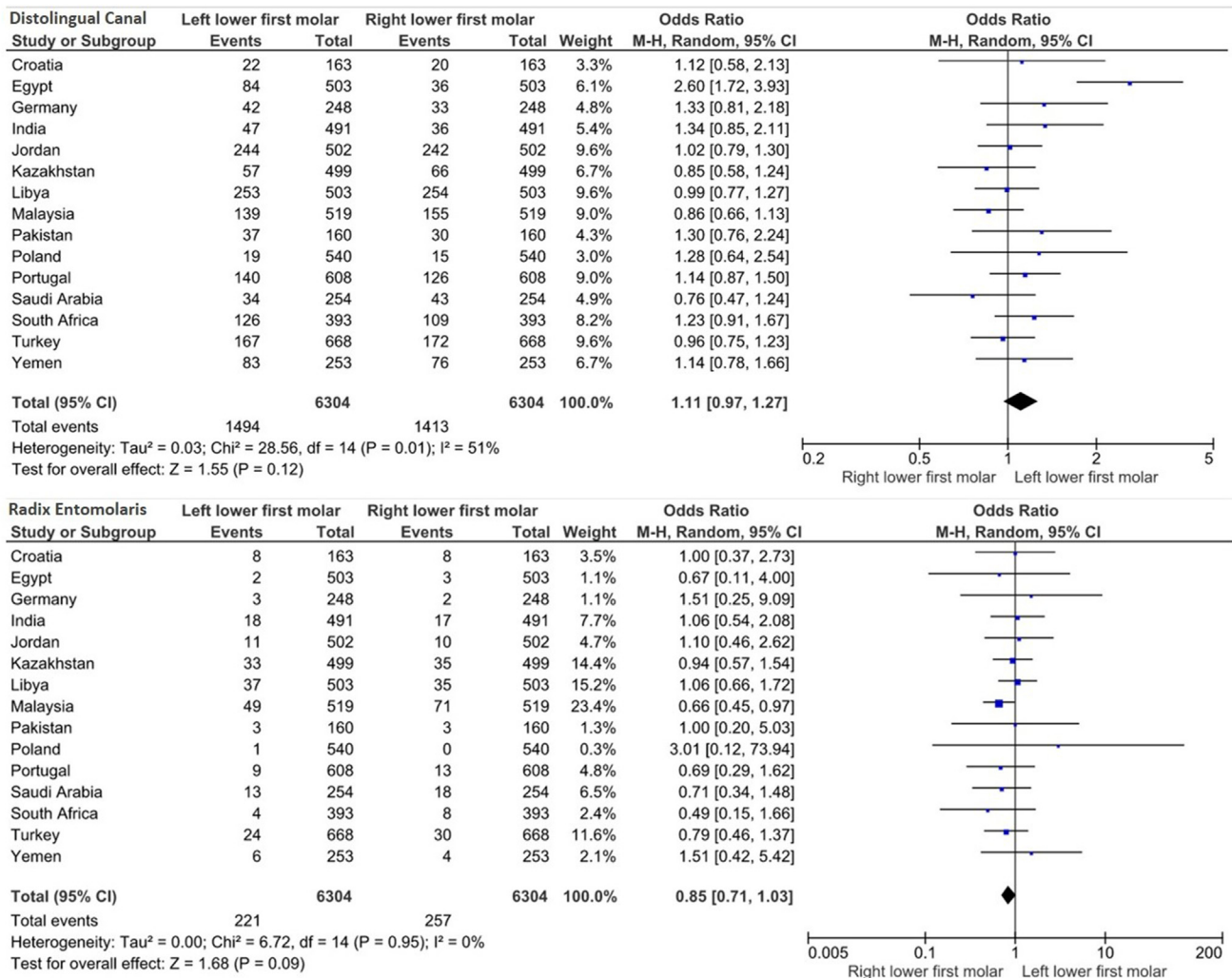
**FIGURE 2** – Forest plot presentation and depiction of RE prevalence by country.

the study, but no classification was given. The variation types of DLC were based on the study by Song, Kim<sup>15</sup>: Type I refers to no curvature, type II to curvature in the coronal third and straight continuation to the apex, type III to curvature in the coronal third and

additional buccal curvature from the middle third to the apical third of the root, small type to root length less than half of the DB root, conical type to cone-shaped extension without root canal. The DLC was accepted if there was a second canal with a completely separate canal

orifice from the distobuccal canal. The canals beginning with the single canal orifice of the distal canal and branching were not considered DLC.

The data received from countries were combined into a single sheet to facilitate



**FIGURE 3** – Forest plot representation of comparison of DLC/RE prevalence between left and right M1M.

nonconformity checking (performed by the study coordinator) and exported to statistical software. A representative image of the CBCT examinations is presented in [Supplemental Material S2](#). [Table 1](#) provides information regarding the exposure parameters and the origin of the devices used in every country.

### Statistical Analysis

Following data collection, data entry was performed using Excel (Microsoft, Redmond, WA), and data analysis was performed with SPSS 22.0 for Windows (SPSS Inc, Chicago, IL). Cramer's V was used to measure the association strength between left and right DLC and RE.

The standard error of prevalence was calculated using  $\sqrt{p(1-p)/n}$  formula where  $p$  is the observed prevalence and  $n$  is the

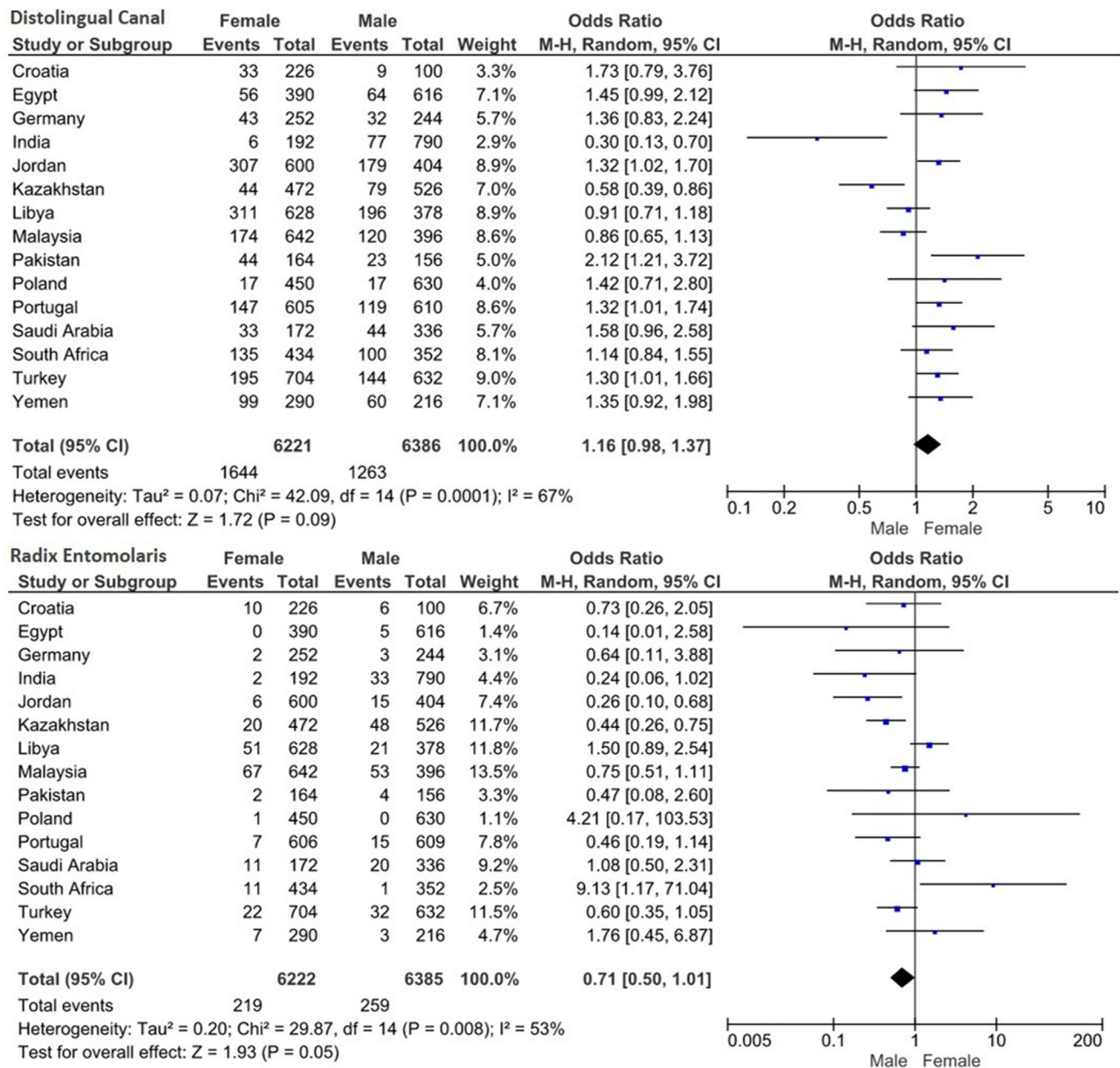
sample size<sup>16</sup>. Odds ratio (OR) and 95% confidence interval (CI) were used to estimate the association between left-right teeth, gender, and age groups. The overall prevalence and OR were assessed by meta-analysis software, RevMan 5.3 (The Nordic Cochrane Centre, The Cochrane Collaboration, Copenhagen, Denmark), and the forest plots were produced. Higgins I<sup>2</sup> test was used to estimate the statistical heterogeneity among studies and categorized as not significant (<30%), moderate (30%–50%), substantial (50%–75%), or considerable (75%–100%)<sup>17</sup>. A random-effects model with 95% CI was preferred as the meta-analysis model due to not achieving methodological, clinical, and statistical homogeneity together. To ensure the accuracy of the pooled outcomes and eliminate the effect of heterogeneity in different voxel sizes, sensitivity analysis was

conducted using the leave-one-out method. The robustness of the results was evaluated by removing studies with larger voxel sizes from the funnel plots. The level of significance was set at  $P < .05$ .

### RESULTS

A total of 23,134 CBCTs were examined based on the exclusion criteria, and 6304 CBCTs, including 12,608 M1Ms, were included in this study. A Strengthening the Reporting of Observational Studies in Epidemiology flowchart is presented in [Supplemental Material S3](#). Among the participants, 3111 (49.35%) were females, while 3193 (50.65%) were males. The mean age of the participants was  $32.87 \pm 13.74$  years.

Interobserver agreement was considered substantial (Fleiss' kappa



**FIGURE 4** – Forest plot representation of comparison of DLC/RE prevalence between genders.

DLC = 0.68, RE = 0.73) for DLC and RE detection<sup>18</sup>. Regarding to intraobserver reliability, for DLC detection, all countries achieved perfect or substantial agreement ( $k > 0.70$ ) while for RE detection, all countries achieved strong or perfect agreement ( $k > 0.80$ )<sup>19</sup>.

The prevalence of DLC ranges from 3% to 50% with an overall prevalence of 22% (95% CI: 15%–29%). Statistically significant differences were observed between countries ( $P < .05$ ). No significant difference was observed between the continents ( $P = .39$ ).

We found considerable statistical heterogeneity among the countries ( $\tau^2 = 0.02$ ,  $\chi^2 = 1875.53$ ,  $I^2 = 99\%$ ,  $P < .0001$ ), and for each continent ( $I^2 \geq 99\%$ ,  $P < .0001$ ) (Fig. 1). The prevalence of RE ranges from 0% to 12% with an overall prevalence of 3% (95% CI: 2%–5%). Statistically significant differences were observed between countries ( $P < .05$ ). No significant difference was observed between the continents ( $P = .17$ ). We found considerable statistical heterogeneity among the countries ( $\tau^2 = 0.00$ ,  $\chi^2 = 413.91$ ,

$I^2 = 97\%$ ,  $P < .0001$ ), and for each continent ( $I^2 \geq 95\%$ ,  $P < .0001$ ) (Fig. 2). Figures 1 and 2 depict the prevalence of DLC and RE by country, respectively.

There was no significant difference between left and right M1M in the presence of DLC (OR = 1.11, 95% CI: 0.97, 1.27,  $P = .12$ ) and RE (OR = 0.85, 95% CI: 0.71, 1.03,  $P = .09$ ). A substantial level of statistical heterogeneity, but not a significant level, was observed for both DLC ( $I^2 = 51\%$ ,  $P = .32$ ) and RE ( $I^2 = 0\%$ ,  $P = .95$ ) (Fig. 3). There was no statistically significant difference between

**TABLE 2** - Correlation Between the Right and Left Arches Regarding the Presence of Radix Entomolaris

Radix entomolaris 36	Radix entomolaris 46			Cramer's V
	None	Available	Total	
None	5987	96	6083	0.66*
Available	59	162	221	
Total	6046	258	6304	

\*>0.50 strong correlation.

gender for either DLC (OR = 1.16, 95% CI: 0.98, 1.37;  $P = .09$ ) and RE (OR = 1.71, 95% CI: 0.50, 1.01;  $P = .05$ ). Substantial statistical heterogeneities were observed for DLC ( $I^2 = 67\%$ ,  $P < .0001$ ) and RE ( $I^2 = 53\%$ ,  $P = .008$ ), respectively (Fig. 4).

In those over 50 years of age, the likelihood of having DLC was significantly lower than in other age groups (OR = 0.83, 95% CI: 0.72, 0.94;  $P = .005$ ) (Supplemental Material S4e). As for the other age groups, no significant differences were observed ( $P > .05$ ) (Supplemental Material S4a-d). The DLC and RE detection were not significantly affected by different voxel sizes ( $P > .05$ ) (Supplemental Material S4f-g).

Sensitivity analyses were conducted for DLC and RE. After studies with 200 voxel sizes were removed, the overall estimates remained statistically similar for DLC (25%, 95% CI [0.15, 0.34],  $P < .001$ ) and RE (4%, 95% CI [0.02, 0.06],  $P < .001$ ). Similarly, after removing studies with 170 and 200 voxel sizes, the estimates for DLC (24%, 95% CI [0.13, 0.34],  $P < .001$ ) and RE (5%, 95% CI [0.03, 0.07],  $P < .001$ ) were still statistically similar. Even after removing studies with 160, 170, and 200 voxel sizes, we still observed statistically similar estimates for DLC (27%, 95% CI [0.13, 0.40],  $P < .001$ ) and RE (5%, 95% CI [0.02, 0.08],  $P < .001$ ) (Supplemental Material S5a-f).

Based on Cramer's V analyses, a strong correlation was found between the presence of DLC in the left and right arches ( $V = 0.78$ ) and RE ( $V = 0.66$ ) (Tables 2–4). Conversely, there was a weak correlation between the presence of RE and DLC ( $V = 0.07$ ) (Table 4).

## DISCUSSION

The findings of this study are informative regarding the importance of clinicians throughout the world having an understanding of anatomical variations. It is imperative to make an accurate diagnosis of anatomical variations, such as accessory roots (radix) or the presence of additional canals, in order to guide clinicians in modifying some endodontic techniques to avoid procedural errors. This can ultimately improve the success and prognosis of root canal treatment<sup>20</sup>.

Among the different methods available to examine tooth morphology<sup>3,10</sup>, mCT and CBCT imaging have proven to be the most valuable. However, mCT, which benefits from superior resolution to focus on pure anatomical descriptions and morphometric measurements, provides more detailed information; it can only be used *ex vivo*. Several studies suggest that CBCT is an appropriate tool for evaluating anatomic variations and visualize root canal morphology<sup>21</sup>, and it has been widely used to study large populations *in vivo* at low radiation levels<sup>8</sup>.

Despite the existing literature on the prevalence of DLC and RE<sup>12,22,23</sup>, only a single study has reported on their global prevalence<sup>9</sup>. Consequently, this study sought to assess the worldwide prevalence of RE and DLC in M1Ms by retrospectively screening 6,304 bilateral CBCTs, while also investigating the influence of sociodemographic factors, such as age and gender, on the prevalence of these conditions. Due to significant differences between the countries, the first null hypothesis was rejected.

The present study provides important insights into the worldwide prevalence of RE in

M1Ms and highlights the significant variation in prevalence rates observed between different countries. Despite RE being considered an ethnic trait in M1M<sup>14</sup>, Deng, Halim<sup>5</sup> reported that the prevalence of RE is independent of ethnicity. It has been suggested by Walker<sup>24</sup> that RE should be classified as a genetic trait rather than a developmental abnormality. It is important to note that the prevalence of RE observed in the current multicenter study (3%, range of 0%–12%) is consistent with rates reported in previous studies conducted in Portugal, India, Brazil, and Germany<sup>9,25</sup>.

However, higher prevalence rates (up to 30%) have been reported in other countries<sup>5,9,26</sup>, such as Malaysia, Yemen, and Egypt, which may be due to the racial differences among various populations as well as the method used to evaluate the additional canals/anatomy. While significant differences were observed between countries, no significant differences were observed among geographical region subgroups. Previously, the prevalence of RE in East Asia was noted to be significantly higher than in other regions in a study conducted in 23 countries<sup>9</sup>. This finding is in contrast with the present study and might be explained since we did not separate Asia into Western and Eastern parts. However, Malaysia, an East Asian country, had the highest prevalence (12%) of RE in the present study. Furthermore, the overall prevalence of both studies<sup>9</sup> are statistically similar (3% [95% CI, 2%–5%] vs 5% [95% CI, 4%–6%]). The meta-analysis method used in our study and in Martins, Nole<sup>9</sup> may allow us to obtain more reliable results and both indicate a higher prevalence of RE in East Asian populations.

Based on a cross sectional study by Costa, Pacheco-Yanes<sup>2</sup>, 98% of teeth with at least 1 untreated canal developed posttreatment apical periodontitis. Song, Kim<sup>27</sup> demonstrated that untreated canals were the second most common cause of treatment failure for all types of teeth and the primary cause for molars. If infected, canals that were missed and as such remained untreated may harbor bacteria in sufficient numbers to maintain or cause disease. If initially noninfected, untreated missed canals may serve as a potential site for reinfection and thereafter result in apical periodontitis. This fact emphasizes the need for clinical practitioners around the world to have a thorough understanding of tooth anatomy as well as anatomical variations in order to provide the best endodontic treatment for their patients.

According to our results, the prevalence of DLC was lowest in Poland (3%) and highest in the Libyan population (50%). The overall prevalence of DLC was 22% (95% CI: 15%–29%), significantly lower than the prevalence

**TABLE 3** - Correlation Between the Right and Left Arches Regarding the Presence of Distolingual Canal

Distolingual canal 36	Distolingual canal 46			Cramer's V
	None	Available	Total	
None	4614	210	4824	0.78*
Available	291	1203	1494	
Total	4905	1413	6318	

\*>0.50 strong correlation.

**TABLE 4** - Correlation Between the Presence of Distolingual Canal and Radix Entomolaris

Radix entomolaris	Distolingual canal			Cramer's V
	None	Available	Total	
None	9407	2722	12129	0.07*
Available	300	179	479	
Total	9707	2901	12608	

\*<0.30 weak.

reported in the study by Martins, Nole<sup>9</sup>, which evaluated 23 countries and reported an overall prevalence of DLC of 36.9% (95% CI: 32%–42%). Concerning the individual countries, similar results have been reported for Turkey (25%) and Yemen (3.4%) in previous studies<sup>12,26</sup>. In contrast, others<sup>9,22</sup> have reported a higher prevalence for Portugal (28%), Egypt (60%), South Africa (40%), Saudi Arabia (53.2%), India (29.6%), and Malaysia (19.5%). In almost all studies, CBCT imaging was used to detect RE and DLC, but differences in results may be attributed to a number of factors such as the sample size, the technical characteristics of CBCT, observer's differences, and the ethnicity of the population studied.

According to the findings of the present study, there were no significant differences between males and females, illustrating the need for clinical accuracy in detecting additional canals/roots in both genders. This finding is consistent with most previous studies<sup>9</sup>. Additionally, many other studies have demonstrated that gender does not affect the prevalence of RE<sup>22,25,28</sup> and DLC<sup>23</sup>. However, other studies have found a higher prevalence of RE<sup>5</sup> and DLC<sup>5</sup> among females.

Because roots are not expected to change over time, only the effect of age on DLC prevalence was investigated in this study. The second null hypothesis was rejected. Consistent with the study by Martins, Nole<sup>9</sup> the prevalence of DLC in elders was significantly lower than in the younger people. Completion of canal differentiation begins about 3–6 years after root differentiation. Between the ages of 12 and 20, teeth have mixed canal morphology, so this age range represents a transitional period for canal differentiation. During this period, secondary dentin accumulation in a mesiodistal direction within the canal in the cervical, middle, and apical thirds leads to separation of the canals. The deposition of secondary dentin mainly determines the shape and number of root canals. These divisions result in extensive differentiation of initially simple root canals<sup>29</sup>. However, it has

been stated that the prevalence of canals decreases with advancing age due to narrowing of canals with dentin accumulation as physiological and pathological dentin deposition increases<sup>30</sup>.

This study found no significant differences in RE and DLC prevalence between the left and right dental sides, which is in accordance with many other studies<sup>22,23,25,26,31</sup>. This finding is in line with the results of Plotino, Tocchi<sup>32</sup> that reported that the root canal anatomy and morphology of molars is similar to that of symmetrical teeth. Nevertheless, there are also studies that found a significantly higher prevalence of RE in either the right<sup>28,31</sup> or left<sup>33</sup> M1M.

This study found that RE was bilateral in 67% of the subjects. Cramer's V analysis yielded a significant correlation ( $V = 0.66$ ). The prevalence of bilateral DLC in this study was 82%, and a strong correlation was obtained in Cramer's V analysis ( $V = 0.78$ ), in agreement with Kim, Kim<sup>34</sup> reported this rate as 78%. The results of this study confirm the strong bilateral relationship seen in previous studies. Regardless of the population being treated, clinicians should take into account the possibility of bilateral RE and/or DLC occurrences when treating M1M. The coexistence probability of RE and DLC was very low ( $V = 0.7$ ), likely due to the fact that the prevalence of DLC is substantially higher than that of RE. While DLC is detected in 37% of teeth with RE, only 5.6% of teeth with DLC have RE.

Although it is possible to detect RE with 2D radiographs, CBCT have been reported to be superior in assessing RE presence<sup>8</sup>. It is our understanding that there is no standard voxel size for CBCT imaging when detecting DLC and RE. However, Mirmohammadi, Mahdi<sup>35</sup> reported that a FOV of 6\*6 and a voxel size of 125  $\mu$ m in CBCT imaging showed 96% accuracy in detecting the MB2 canal. It was also stated that CBCT images obtained with a voxel smaller than 200  $\mu$ m have higher accuracy than CBCT images obtained with a 300  $\mu$ m voxel. This study included CBCT images obtained with voxel sizes in the range of 100–200  $\mu$ m. There was no significant

difference between DLC and RE prevalence in CBCT images obtained with 150  $\mu$ m $\leq$  and 150  $\mu$ m $>$  voxel sizes. Based on the data obtained in this study, it can be said that CBCT images obtained with voxel sizes between 100 and 200  $\mu$ m can be used for RE and DLC detection.

The study has several strengths, including a large sample size that is larger than previous studies and the inclusion of 15 countries from multiple geographical regions improved the external validity of the findings. Additionally, the study evaluated the bilateral prevalence of RE and DLC. This research is also unique in that it investigated the prevalence of RE in Poland, DLC in Germany, and both RE and DLC in Croatia; Kazakhstan; Libya; and Jordan, which had not been previously studied. Setting uniform inclusion criteria, calibrating all observers before data collection, and establishing inter-observer reliability increased the homogeneity across studies. However, the study had some limitations that should be considered. One limitation was the substantial heterogeneity due to different observers, CBCT imaging devices, voxel sizes, and ethnicities, which can affect the reliability and comparability of the results. Various meta-analytical techniques, such as the random effects model, subgroup, and sensitivity analyses, have been employed to address heterogeneity. Additionally, we set a maximum CBCT voxel size of 200  $\mu$ m, which has been recognized in previous research as the upper limit for minimizing heterogeneity when studying root canal morphologies. By adhering to this criterion, we aimed to enhance the consistency and comparability of our findings<sup>9</sup>.

## CONCLUSION

The results of this cross-sectional study indicated that the overall worldwide prevalence of RE and DLC in M1Ms was 3% and 22%, respectively. There were no significant differences in the prevalence of either RE or DLC based on gender or side. However, the prevalence of DLC was significantly lower in individuals over the age of 50. The study also found that RE and DLC were predominantly bilateral in nature, but identified a weak correlation between the presence of RE and DLC.

## ACKNOWLEDGMENTS

We would like to thank following authors for their contributions.

Nessrin Taha from Jordan University of science and Technology Irbid, Jordan. Suha Alfirjani from Dental school/university of

Benghazi, Libya. Anna Paulina Lehmann from Poznań University of Medical Sciences Dept. of Conservative Dentistry and Endodontics Poznań, Poland. Tanvi Shah, from Nair Hospital Dental College, Mumbai, India. David Donnermeyer from Westphalian Wilhelms-

University, Münster, Germany. Silvana Jukić Krmek from University of Zagreb, Croatia. Abdulbaset Mofadhal from Sana'a University, Yemen.

The authors deny any conflicts of interest related to this study.

## SUPPLEMENTARY MATERIAL

Supplementary material associated with this article can be found in the online version at [www.jendodon.com](http://www.jendodon.com) (<https://doi.org/10.1016/j.joen.2023.06.011>).

## REFERENCES

1. Baruwa AO, Martins JN, Meirinhos J, et al. The influence of missed canals on the prevalence of periapical lesions in endodontically treated teeth: a cross-sectional study. *J Endod* 2020;46:34–39.e1.
2. Costa F, Pacheco-Yanes J, Siqueira J Jr, et al. Association between missed canals and apical periodontitis. *Int Endod J* 2019;52:400–6.
3. Harris SP, Bowles WR, Fok A, McClanahan SB. An anatomic investigation of the mandibular first molar using micro-computed tomography. *J Endod* 2013;39:1374–8.
4. Huang RY, Cheng WC, Chen CJ, et al. Three-dimensional analysis of the root morphology of mandibular first molars with distolingual roots. *Int Endod J* 2010;43:478–84.
5. Deng PU, Halim MS, Masudi SM, et al. Cone-beam computed tomography analysis on root and canal morphology of mandibular first permanent molar among multiracial population in East Coast Malaysian population. *Eur J Dent* 2018;12:410–6.
6. De Moor R, Deroose C, Calberson F. The radix entomolaris in mandibular first molars: an endodontic challenge. *Int Endod J* 2004;37:789–99.
7. Forner Navarro L, Luzzi A, Almenar García A, Hervás García A. Third canal in the mesial root of permanent mandibular first molars: review of the literature and presentation of 3 clinical reports and 2 *in vitro* studies. *Med Oral Patol Oral Cir Bucal* 2007;12:605–9.
8. Altun O, Duman SB, Bayrakdar IS, et al. Cone beam computed tomography imaging of superior semicircular canal morphology: a retrospective comparison of cleft lip/palate patients and normal controls. *Acta Odontol Scand* 2018;76:247–52.
9. Martins JN, Nole C, Ounsi HF, et al. Worldwide assessment of the mandibular first molar second distal root and root canal: a cross-sectional study with meta-analysis. *J Endod* 2022;48:223–33.
10. Versiani MA, Ordinola-Zapata R, Keleş A, et al. Middle mesial canals in mandibular first molars: a micro-CT study in different populations. *Arch Oral Biol* 2016;61:130–7.
11. Naing L, Nordin RB, Abdul Rahman H, Naing YT. Sample size calculation for prevalence studies using Scalex and ScalaR calculators. *BMC Med Res Methodol* 2022;22:1–8.
12. Miloglu O, Arslan H, Barutçigil C, Cantekin K. Evaluating root and canal configuration of mandibular first molars with cone beam computed tomography in a Turkish population. *J Dent Sci* 2013;8:80–6.
13. Fayad MI, Nair M, Levin MD, et al. AAE and AAOMR joint position statement: use of cone beam computed tomography in endodontics 2015 update. *Oral Surg Oral Med Oral Pathol Oral Radiol* 2015;120:508–12.
14. Calberson FL, De Moor RJ, Deroose CA. The radix entomolaris and paramolaris: clinical approach in endodontics. *J Endod* 2007;33:58–63.
15. Song JS, Kim S-O, Choi B-J, et al. Incidence and relationship of an additional root in the mandibular first permanent molar and primary molars. *Oral Surg Oral Med Oral Pathol Oral Radiol Endod* 2009;107:e56–60.
16. Hackshaw A, Paul E, Davenport E. Evidence-Based Dentistry: An Introduction. John Wiley & Sons; 2006.
17. Higgins JP, Altman DG, Gøtzsche PC, et al. The Cochrane Collaboration's tool for assessing risk of bias in randomised trials. *BMJ* 2011;343:d5928.
18. Landis JR, Koch GG. The measurement of observer agreement for categorical data. *Biometrics* 1977;33:159–74.
19. McHugh ML. Interrater reliability: the kappa statistic. *Biochem Med* 2012;22:276–82.

20. Cantatore G, Berutti E, Castellucci A. Missed anatomy: frequency and clinical impact. *Endod Topics* 2006;15:3–31.
21. Michetti J, Maret D, Mallet J-P, Diemer F. Validation of cone beam computed tomography as a tool to explore root canal anatomy. *J Endod* 2010;36:1187–90.
22. Pan JYY, Parolia A, Chuah SR, et al. Root canal morphology of permanent teeth in a Malaysian subpopulation using cone-beam computed tomography. *BMC Oral Health* 2019;19:1–15.
23. Wang Y, Zheng Q-H, Zhou X-D, et al. Evaluation of the root and canal morphology of mandibular first permanent molars in a western Chinese population by cone-beam computed tomography. *J Endod* 2010;36:1786–9.
24. Walker RT. Root form and canal anatomy of mandibular second molars in a southern Chinese population. *J Endod* 1988;14:325–9.
25. Schäfer E, Breuer D, Janzen S. The prevalence of three-rooted mandibular permanent first molars in a German population. *J Endod* 2009;35:202–5.
26. Senan EM, Madfa AA, Alhadainy HA. Root and canal configuration of mandibular first molars in a Yemeni population: a cone-beam computed tomography. *Eur Endod J* 2020;5:10.
27. Song M, Kim H-C, Lee W, Kim E. Analysis of the cause of failure in nonsurgical endodontic treatment by microscopic inspection during endodontic microsurgery. *J Endod* 2011;37:1516–9.
28. Tu M-G, Huang H-L, Hsue S-S, et al. Detection of permanent three-rooted mandibular first molars by cone-beam computed tomography imaging in Taiwanese individuals. *J Endod* 2009;35:503–7.
29. Peiris H, Pitakotuwage T, Takahashi M, et al. Root canal morphology of mandibular permanent molars at different ages. *Int Endod J* 2008;41:828–35.
30. Rathi S, Patil J, Jaju PP. Detection of mesiobuccal canal in maxillary molars and distolingual canal in mandibular molars by dental CT: a retrospective study of 100 cases. *Int J Dent* 2010;2010:291276.
31. Choi M-R, Moon Y-M, Seo M-S. Prevalence and features of distolingual roots in mandibular molars analyzed by cone-beam computed tomography. *Imaging Sci Dent* 2015;45:221–6.
32. Plotino G, Tocci L, Grande NM, et al. Symmetry of root and root canal morphology of maxillary and mandibular molars in a white population: a cone-beam computed tomography study *in vivo*. *J Endod* 2013;39:1545–8.
33. Gulabivala K, Aung T, Alavi A, Ng YL. Root and canal morphology of Burmese mandibular molars. *Int Endod J* 2001;34:359–70.
34. Kim S-Y, Kim BS, Woo J, Kim Y. Morphology of mandibular first molars analyzed by cone-beam computed tomography in a Korean population: variations in the number of roots and canals. *J Endod* 2013;39:1516–21.
35. Mirmohammadi H, Mahdi L, Partovi P, et al. Accuracy of cone-beam computed tomography in the detection of a second mesiobuccal root canal in endodontically treated teeth: an *ex vivo* study. *J Endod* 2015;41:1678–81.