

Emergency endovascular repair for ruptured abdominal aneurysms – a feasibility study and report of 10 cases

J. VAN MARLE, M.B. CH.B., M.MED. (CHIR.), F.C.S. (S.A.)

Medi-Clinic Unit for Peripheral Vascular Surgery, Department of Surgery, Pretoria Academic Hospital and University of Pretoria

Summary

Background. Endovascular aneurysm repair (EVAR) has been proved to be effective and safe in the elective management of abdominal aortic aneurysms (AAAs). Initial reports concerning endovascular management of ruptured aneurysms have been promising.

Objective. To determine the outcome of endovascular repair of ruptured aneurysms in the local setting.

Materials and methods. Patients who presented with ruptured AAAs were considered for endovascular repair if they were haemodynamically stable and had suitable aneurysm morphology for EVAR.

Results. Ten patients (9 males, 1 female) with a mean age of 74.9 years were treated. All aneurysms were successfully excluded using aorta uni-iliac stent grafts in 7 patients and bifurcated stent grafts in 2 patients. In 1 patient who had had a previous EVAR, a proximal extension device was used. Two patients died in the peri-operative period (30-day mortality of 20%) and 1 patient died after 2 months. Seven patients are still alive. No endo-leaks occurred in any of the survivors.

Conclusion. Endovascular repair of ruptured AAAs is feasible with acceptable peri-operative mortality and short- to medium-term results.

Endovascular repair has become an accepted modality for the elective treatment of abdominal aortic aneurysms (AAAs), with many reports¹⁻⁴ attesting to its feasibility and safety. Two recent randomised trials^{5,6} have reported a two-third reduction in the 30-day mortality rate with elective endovascular repair of AAAs compared with conventional open surgery (1.6% and 1.2% for endovascular aneurysm repair (EVAR) compared with 4.6% and 6% for conventional repair).

The reduction in the morbidity and mortality achieved by EVAR in the elective setting gave hope of improved results for ruptured AAAs (rAAAs) using the endovascular method. The first case report of successful endovascular exclusion of a rAAA was published in 1994.⁷ Since then, a number of larger series have confirmed the feasibility of endovascular repair of rAAAs.⁸⁻¹⁰

In 2003, having gained considerable experience with EVAR in elective repair of AAAs (68 cases), we decided to undertake a study on the feasibility of endovascular repair of ruptured AAAs. This is a report on the first 10 cases.

Material and methods

All patients who presented to our unit with a suspected rAAA were evaluated according to the algorithm in Fig. 1. We followed the following management protocol, as used in the Catharina Hospital, Eindhoven, Netherlands.¹¹

1. The management team consists of a vascular surgeon with endovascular expertise, and the full range of supporting personnel as appropriate for conventional open surgery for rAAAs.

2. Once the diagnosis of rAAA is considered, a policy of hypotensive resuscitation is followed where the systolic blood pressure is maintained between 70 mmHg and 100 mmHg. This prevents further retroperitoneal bleeding while maintaining cerebral and renal perfusion. The diagnosis is confirmed by spiral computed tomography (CT) scan, with the responsible surgeon being present during the examination. Immediate assessment of aorta iliac anatomy is made during CT examination (Fig. 2). Depending on whether the infrarenal neck appears suitable and access through one of the iliac arteries is possible, the operating team is notified whether open surgical or endovascular repair will be performed.

3. The standard preparation for treatment of rAAAs is performed, including adequate venous access, blood samples for routine laboratory studies, cross-matching of blood group, urethral catheterisation, etc.

4. The patient is transferred to the operating room where radial artery canalisation for continuous blood pressure moni-

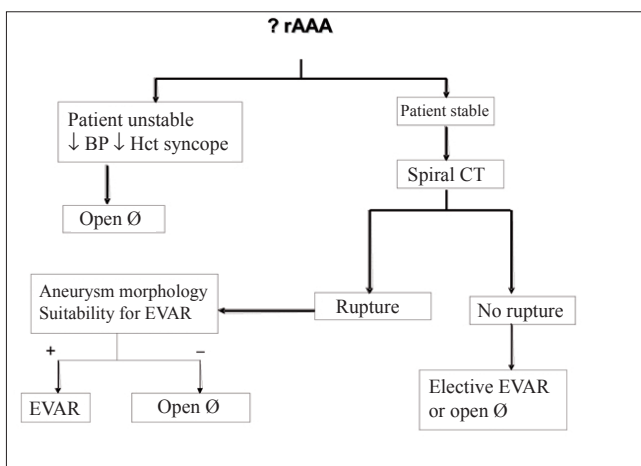


Fig. 1. Protocol for the management of patients with suspected ruptured AAAs (Ø = surgery).

toring is performed. Blood pressure is maintained below 100 mmHg and nitrates are used to treat pressures higher than that. Pain and anxiety are treated appropriately.

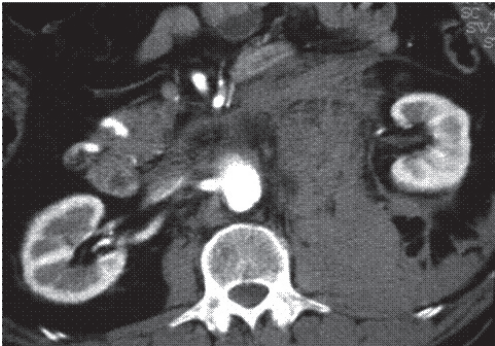

Fig. 2. CT scan of rAAA indicating position of right renal artery.

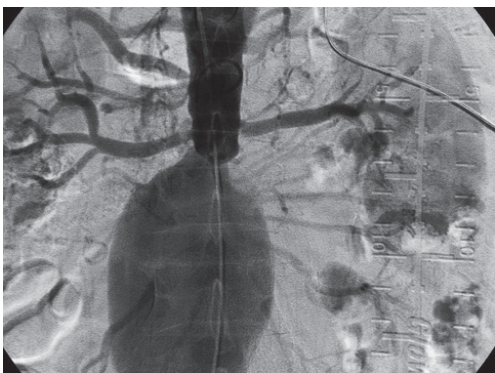


Fig. 3. Angiogram confirming the position of the renal arteries.

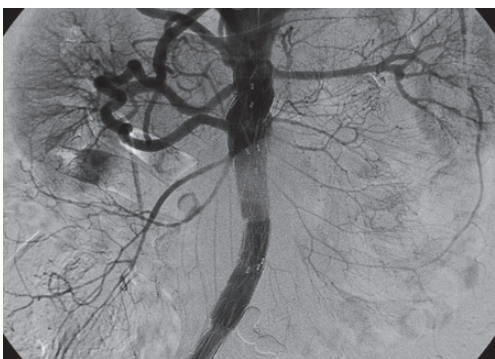


Fig. 4. Aorta-uni-iliac device in position.

5. The femoral artery on the side of the best iliac anatomy is exposed under local anaesthesia. An introducer sheath is placed in the artery and standard angiography is performed to visualise the level of the renal arteries (Fig. 3). The final decision is made as to whether EVAR is applicable, and if this is not the case, the team proceeds with open repair.

6. If the morphology and anatomy is suitable for EVAR a femoral arteriotomy is made and an appropriate proximal component of the aorta-uni-iliac device is introduced and deployed at the infrarenal position (Fig. 4). The second component of the endovascular graft is then selected and introduced into the distal part of the endograft and deployed within a suitable segment of either the common or external iliac artery. A completion angiogram is performed to confirm adequate sealing of the proximal and distal landing zones and to check for endo-leaks (Fig. 5). At this stage the site of rupture should have been sealed and no further serious bleeding should occur.

7. General anaesthesia may now be induced. The contralateral common iliac artery is occluded by using a closed stent graft (occluder). A femoro-femoral bypass is performed and the groin wounds are sutured.

8. The patient is admitted to the intensive care unit (ICU) and treated accordingly.

Patients who were shocked, haemodynamically unstable or with syncope and who were previously considered unfit for elective repair, were not accepted for endovascular treatment.

Results

A total of 10 patients received EVAR for rAAAs. There were 9 males and 1 female, with a median age of 74.9 years (range 68 - 84 years). The patients had the usual risk factors for atherosclerotic disease, viz. hypertension ($N = 8$), dyslipidaemia ($N = 4$), smoking history ($N = 9$), ischaemic heart disease ($N = 4$) and respiratory insufficiency ($N = 7$). There were no diabetics. All patients were haemodynamically stable, with initial blood pressures ranging from 80 mmHg to 140 mmHg. Blood pressures above 100 mmHg were treated with nitrates.

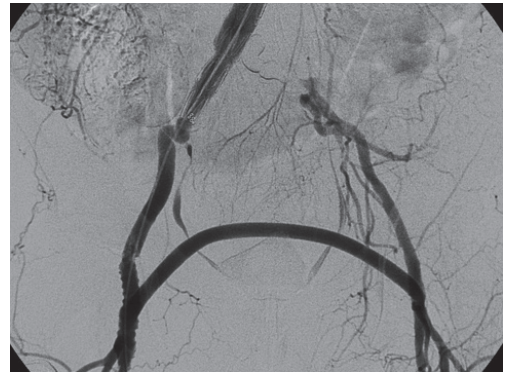


Fig. 5. Completion angiogram.

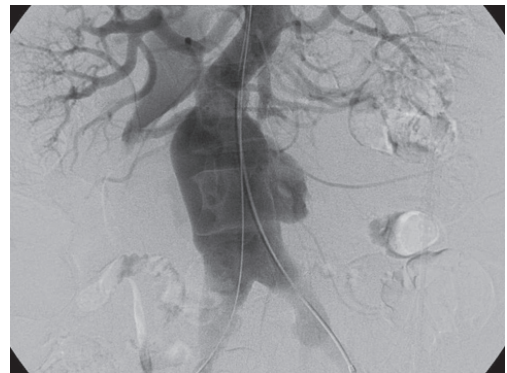


Fig. 6. Aortocaval fistula.

Mean haematocrit on admission was 32% (range 28 - 41%). A CT scan confirmed rupture as well as anatomical suitability for EVAR in all patients. Arteriography revealed an aortocaval fistula in 1 patient (Fig. 6).

The Talent (Medtronic AVE) aorta uni-iliac device with fem-fem crossover bypass was used in 7 patients and a bifurcated stent graft in 2 patients. One patient developed a ruptured aneurysm due to a type 1 endo-leak after a previous elective EVAR and this was managed by placing a proximal extension cuff. All aneurysms were successfully excluded. Two patients died in the peri-operative period, 2 and 6 days postoperatively (peri-operative mortality rate 20%). The median stay in the ICU was 3.4 days (range 2 - 11 days). The median total hospital stay was 7 days (range 5 - 16 days). One patient died after 2 months and 7 patients are still alive (70% survival), the longest survival being more than 3 years. No endo-leaks have been detected during follow-up.

Discussion

Elective repair of AAAs has become a relatively safe procedure, with the

30-day operative mortality ranging between 4% and 12%.^{12,13} In contrast rAAAs remain a medical and surgical catastrophe, with most centres reporting mortality rates of around 50% (ranging from 32% to 70%).¹⁴⁻¹⁸ Intra-operative mortality has remained almost constant at 20% over the past 5 decades. Some improvement has been made in postoperative mortality, which is attributable to improved care in specialist intensive therapy units.¹⁹ Surgical repair of rAAAs is also one of the most difficult of vascular surgical procedures and few individual surgeons repair more than 10 aneurysms annually.²⁰

Certain problems associated with conventional open repair of rAAAs contribute to the high morbidity and mortality and may be avoided by using endovascular repair. These include the following.

1. Open repair requires general anaesthesia, which causes relaxation of the abdominal muscles with subsequent loss of abdominal wall tamponade, which potentially increases haemorrhage. Patients with rAAAs are also usually in a state of compensated shock with maximal peripheral vasoconstriction. The release of the sympathetic tone on the induction of general anaesthesia may cause complete cardiovascular collapse. Lachat *et al.*²¹ have shown that the use of local rather than general anaesthesia during endovascular repair of rAAAs may favourably influence operative outcome.

2. Laparotomy leads to loss of abdominal wall tamponade and is also associated with intra-operative hypothermia (which exaggerates bleeding due to coagulopathy), third space fluid losses, postoperative ventilatory impairment, etc.

3. Dissection of the aortic neck may cause damage to the renal, adrenal, lumbar and gonadal veins. Up to 68% of patients who die in the peri-operative period have an associated iatrogenic injury, these injuries being more common in those patients presenting with hypotension.²²

4. Aortic cross-clamping increases cardiac stress with increased cardiac after-load. It also leads to visceral and renal ischaemia (after suprarenal clamping), and lower limb ischaemia with the systemic complications of ischaemia-reperfusion injury.²³

5. Opening the retroperitoneal haematoma converts a contained rupture into a free rupture which may cause additional blood loss.

EVAR has been shown to have fewer adverse effects on cardiac, respiratory and renal function.²³⁻²⁵ EVAR also has a reduced inflammatory (cytokine) response. Cytokines are implicated in the development of multiple organ failure, which is the leading cause of peri-operative mortality after surgery for rAAAs.^{26,27}

A number of studies, including 3 prospective studies, have reported on the use of EVAR in rAAAs. The average operative mortality was 24% (9.5 - 45%).^{8-11,28,29} In the prospective studies the comparative mortality for conventional open repair ranged from 41% to 50%.^{11,28,29} In the series by Buth *et al.*²⁸ the peri-operative benefit extended into the postoperative period, with a 74% 6-month survival in the ruptured EVAR group compared with 52% in the surgical group.

Technical aspects

Bifurcated stent grafts as well as aorta uni-iliac stent grafts with femoro-femoral crossover have been used in the treatment of rAAAs. Advantages of the aorta uni-iliac devices are that they are quick and easy to deploy and produce rapid haemorrhage control and can be used to exclude contralateral common

iliac aneurysms.^{30,31} Special devices have been developed, specifically for use in rAAAs. These stent grafts are of a modular uni-iliac configuration and consist of a variety of 'tops and bottoms' that can be fitted together intra-operatively. As few as 8 components (4 proximal and 4 distal) are required to cover the full spectrum of aortic morphology and are made available as a 'rupture kit'.

Anatomical considerations

Endovascular repair relies on certain anatomical requirements for complete aneurysm exclusion. Aneurysms that rupture are associated with larger diameters than their intact counterparts.³² It has been suggested that larger aneurysms have more adverse morphological features which may increase the technical difficulty and therefore reduce the applicability of the endovascular technique. Several authors,^{30,33,34} however, have reported the applicability of EVAR in about 60% of abdominal aortic aneurysms.

Morphological constraints centre on the suitability for creating an intact seal in the infrarenal aortic neck. Neck lengths of a least 15 mm and less than 30 mm in width are generally required. Deviation from these recommended criteria may increase the number of complications, with a higher secondary intervention rate.^{16,35,36} The Eindhoven group consider a neck of < 10 mm in length and > 30 mm in diameter, as well as inaccessible iliac arteries, as excluding criteria for endovascular repair.²⁸

Assessment of aneurysm morphology

Contrast-enhanced spiral CT has become the investigation of choice in the assessment of elective aneurysms for EVAR. Willmann *et al.*³⁷ have established that spiral CT can provide the necessary data for endograft planning in patients with rAAAs. The Nottingham and Eindhoven groups specifically rely on thin-slice spiral CT without any reconstructions.^{9,11} Ultrasound is unreliable for the diagnosis of rupture and has not been validated in the pre-operative assessment of intact aortic morphology, particularly of neck length and diameter.³⁸ The experience of Veith and Ohki⁸ suggests that digital subtraction angiography (DSA) may provide sufficiently accurate data on aneurysm morphology to successfully treat ruptures with the Montefiorri customisable aortic uni-iliac system, but whether it can be used reliably to predict aneurysm suitability and stent graft size for other commercially available devices remains uncertain.

Postponing treatment for pre-operative CT scanning may be a concern. In the Eindhoven and Zürich series it took 10 - 15 minutes to obtain an emergency spiral CT scan and during this investigation the operating room was prepared for the operative procedure, making the actual time delay even less.^{28,37}

Applicability rate

In the reported studies the applicability rate of EVAR in rAAAs varied from 27% to 78%.^{10,11,21,39,40} The concept of ruptured EVAR will lose much of its appeal if it can only be applied in the minority of patients. The current eligibility criteria for rAAA are based on the recommendations for elective EVAR, and it may be appropriate to consider less stringent anatomical criteria for patients with rAAAs. A prospective multi-centre study (the ERA study)⁴¹ was launched in 2003 to assess the applicability, clinical performance, safety and effectiveness of stent graft placement in rAAAs. These results are pending.

We have lost patients to the study because of delayed referral which caused them to arrive at our unit in an unstable state. We have also been unable to manage a number of patients because of the unavailability of the endograft rupture kit.

Long-term durability

The EUROSTAR data^{42,43} showed a cumulative rupture rate of aneurysms following EVAR of 1% per annum, with an annual secondary intervention rate of 10%. Although concerns about the durability of endovascular repair are justifiable in relatively fit patients with a long life expectancy, these concerns are of less relevance in patients with rAAAs where the major outcome is peri-operative mortality. Secondary procedures, if necessary, can be carried out in an elective setting usually via the endovascular route.⁴⁴

Conclusion

Endovascular repair of rAAAs is feasible and holds the promise of decreasing the mortality and morbidity of this devastating condition. This treatment modality is available in South Africa and should be considered for suitable patients. Patients with suspected rAAAs should be referred immediately to specialist units while adhering to the policy of hypotensive resuscitation. Appropriate 'rupture kits' should be available at all times.

REFERENCES

- Matsumura JS, Pearce WH. Early clinical results and studies of aortic aneurysm morphology after endovascular repair. *Surg Clin North Am* 1999; 79: 529-540.
- Cuyppers P, Buth J, Harris PL, et al. Realistic expectations for patients with stent graft treatment of abdominal aortic aneurysms. Results of a European multicentre registry. *Eur J Vasc Endovasc Surg* 1999; 17: 507-516.
- Thomas SM, Gaines PA, Beard JD. On behalf of VSSGBI and BSIR. Short-term outcome of endovascular treatment of abdominal aortic aneurysms: results from the prospective Registry of Endovascular Treatment of Aneurysms (RETA). *Eur J Vasc Endovasc Surg* 2001; 21: 57-64.
- Vallabhaneni SR, Harris PI. Lessons learned from the EUROSTAR registry on endovascular repair of abdominal aneurysms. *Eur J Radiol* 2001; 39: 34-41.
- Greenhalgh RM, Brown LC, Kwong GP, Powell GT, Thompson SG. Comparison of endovascular aneurysm repair with open repair in patients with abdominal aortic aneurysm (EVAR trial 1), 30 day operative mortality results: randomised controlled trial. *Lancet* 2004; 364: 843-848.
- Prinssen M, Verhoeven ELG, Buth J, et al. A randomized trial comparing conventional and endovascular repair of abdominal aortic aneurysms. *N Engl J Med* 2004; 351: 1607-1618.
- Yusuf SW, Whitaker SC, Shuter TA, et al. Emergency endovascular repair of leaking aortic aneurysms. *Lancet* 1994; 344: 1645.
- Veith FJ, Ohki T. Endovascular approaches to ruptured infra-renal aortoiliac aneurysms. *J Cardiovasc Surg* 2002; 43: 369-378.
- Hinchliffe RJ, Yusuf SW, Macierewicz JA, et al. Endovascular repair of ruptured abdominal aortic aneurysms – a challenge to open repair? Results of a single centre experience in 20 patients. *Eur J Vasc Endovasc Surg* 2001; 22: 528-534.
- Orend KH, Kotsis T, Scharrer-Pamler R, et al. Endovascular repair of aortic rupture due to trauma and aneurysm. *Eur J Vasc Endovasc Surg* 2002; 23: 61-67.
- Yilmaz N, Peppelenbosch N, Cuyppers PW, et al. Emergency treatment of symptomatic or ruptured abdominal aortic aneurysms: the role of endovascular repair. *J Endovasc Ther* 2002; 4: 449-457.
- Blankensteijn JD, Lindenburg FP, Van der Graaf Y, Eikelboom BC. Influence of study design on reported mortality and morbidity rates after abdominal aortic aneurysm repair. *Br J Surg* 1998; 85: 1624-1630.
- Arko FR, Lee WA, Hill BB, et al. Aneurysm-related death: Primary endpoint analysis for comparison of open and endovascular repair. *J Vasc Med Biol* 2002; 14: 297-304.
- Johansen K, Kohler TR, Nichols SC, et al. Ruptured abdominal aortic aneurysms: the Harbour view experience. *J Vasc Surg* 1991; 13: 240-247.
- Kniemeier HW, Kessler T, Reber PU, et al. Treatment of ruptured abdominal aortic aneurysms: a permanent challenge or waste of resources? Prediction of outcome using a multi-organ dysfunction score. *Eur J Vasc Endovasc Surg* 2000; 19: 190-196.
- Noel AA, Gloviczki P, Cherry KJ jun., et al. Ruptured abdominal aortic aneurysms: the excessive mortality rate of conventional repair. *J Vasc Surg* 2001; 34: 41-46.
- Prance SE, Wilson YG, Cosgrove CM, et al. Ruptured abdominal aortic aneurysms: selecting patients for surgery. *Eur J Vasc Endovasc Surg* 1999; 17: 129-132.
- Heller JA, Wineberg A, Arons R, et al. Two decades of aortic abdominal aneurysm repair: have we made any progress? *J Vasc Surg* 2000; 32: 1091-1100.
- Brown AJ, Sutton AJ, Bell PRF, Sayers RD. Meta analysis of 50 years of ruptured abdominal aortic aneurysm repair. *Br J Surg* 2002; 89: 714-730.
- Collin J. Has the mortality rate for ruptured aortic aneurysms changed over the last 50 years? In: Branchereau A, Jacobs M, eds. *Vascular Emergencies*. Amsterdam: Futura, 2003: 55-59.
- Lachat ML, Pfammatter T, Witzke HJ, et al. Endovascular repair with bifurcated stent grafts under local anaesthesia to improve outcome of ruptured aorta iliac aneurysms. *Eur J Vasc Endovasc Surg* 2002; 23: 528-536.
- Donaldson MC, Rosenberg JM, Bucknam CA. Factors affecting survival after ruptured abdominal aortic aneurysms. *J Vasc Surg* 1985; 2: 564-570.
- Baxendale BR, Baker DM, Hutchinson A, et al. Haemodynamic and metabolic response to endovascular repair of infra-renal aortic aneurysms. *Br J Anaesth* 1996; 77: 581-585.
- Boyle JR, Thompson JP, Thompson MM, et al. Improved respiratory function and analgesia control after endovascular AAA repair. *J Endovasc Surg* 1997; 4: 62-65.
- Cuyppers PWM, Gardien M, Buth J, et al. Randomized study comparing cardiac response in endovascular and open abdominal aortic aneurysm repair. *Br J Surg* 2001; 88: 1059-1065.
- Boyle JR, Goodall S, Thompson JP, et al. Endovascular AAA repair attenuates the inflammatory and renal responses associated with conventional surgery. *J Endovasc Ther* 2000; 7: 359-371.
- Brown MJ, Nicholson ML, Bell PR, Sayers RD. Cytokines and inflammatory pathways in the pathogenesis of multiple organ failure following abdominal aortic aneurysm repair. *Eur J Vasc Endovasc Surg* 2001; 22: 485-495.
- Buth J, Peppelenbosch N, Yilmaz N, Cuyppers PW, et al. Ruptured AAA: should endovascular treatment be the first choice? In: Branchereau A, Jacobs M, eds. *Vascular Emergencies*. Futura 2003: 61-70.
- Alsac JM, Desgranges H, Kobeiter H, Becquemont JP. Emergency endovascular repair for ruptured abdominal aortic aneurysms: feasibility and comparison of early results with conventional repair. *Eur J Vasc Endovasc Surg* 2005; 30: 632-639.
- Armon MP, Yusuf SW, Latief K, et al. Anatomical suitability of abdominal aortic aneurysms for endovascular repair. *Br J Surg* 1997; 84: 178-180.
- Chuter TA, Faruqi RM, Reilly LM, et al. Aortomonoiliac endovascular grafting combined with femero-femoral bypass: an acceptable compromise or a preferred solution? *Semin Vasc Surg* 1999; 12: 176-181.
- Szilagyi DE, Smith RF, De Russo FJ, et al. Contribution of abdominal aortic aneurysmectomy to prolongation of life. *Ann Surg* 1966; 164: 678-699.
- Woodburn KR, Chant H, Davies JN, et al. Suitability for endovascular aneurysm repair in an unselected population. *Br J Surg* 2001; 88: 77-81.
- Bayle O, Branchereau A, Rosset E, et al. Morphologic assessment of abdominal aortic aneurysms by spiral computed tomographic scanning. *J Vasc Surg* 1997; 26: 238-246.
- Stanley BM, Semmens JB, Mai Q, et al. Evaluation of patient selection guidelines for endoluminal AAA repair with a Zenith stent graft: the Australasian experience. *J Endovasc Ther* 2001; 8: 457-464.
- Kalliafas S, Albertini JN, Macierevicz J, et al. Incidence and treatment of intra-operative technical problems during endovascular repair of complex abdominal aortic aneurysms. *J Vasc Surg* 2000; 31: 1185-1192.
- Willmann JK, Lachat ML, Von Smekal A, et al. Spiral-CT angiography to assess feasibility of endovascular aneurysm repair in patients with ruptured aorto-iliac aneurysm. *Vasa* 2001; 30: 271-276.
- Schuman WP, Hastrip W jun., Kohler TR, et al. Suspected leaking abdominal aortic aneurysm: use of sonography in the emergency room. *Radiology* 1988; 168: 117-119.
- Van Sambeek MRHM, Van Dijk LC, Hendriks JM, et al. Endovascular vs. conventional open repair of acute abdominal aortic aneurysm: feasibility and preliminary results. *J Endovasc Ther* 2002; 9: 443-448.
- Verhoeven ELG, Prins TR, Van den Dungen JJAM, et al. Endovascular repair of acute AAAs under local anesthesia with bifurcated endografts: a feasibility study. *J Endovasc Ther* 2002; 9: 158-164.
- Peppelenbosch N, Zannetti S, Barbieri B, Buth J. On behalf of the ERA collaborators. Endograft treatment in ruptured abdominal aortic aneurysms using the Talent AUI stentgraft system. Design of a feasibility study. *Eur J Vasc Endovasc Surg* 2004; 27: 366-371.
- Harris BL, Vallabhaneni SR, Desgranges P, et al. Incidence and risk factors of late rupture, conversion and death after endovascular repair of infra-renal aortic aneurysms: The Eurostar Experience. *J Vasc Surg* 2000; 32: 739-749.
- Buth J, Laheij RJF. Early complications and endoleaks after endovascular aortic aneurysm repair: Report on a multicentre study. *J Vasc Surg* 2000; 31: 134-146.
- Hopkinson BR, Hinchliffe RJ. EVAR will take over emergency abdominal aortic aneurysm rupture. In: Greenhalgh RM, ed. *The Evidence for Vascular and Endovascular Reconstruction*. London: WB Saunders, 2002: 201-209.