

An unusual cause of dyspnoea – can you spot the diagnosis?

D Joseph, MB ChB MMed (Int Med) FCP (SA); N Pannell, MB ChB MMed (Int Med) Cert Pulm (SA);
G R Tintinger, MB ChB MMed (Int Med) PhD

Department of Internal Medicine, Steve Biko Academic Hospital and Faculty of Health Sciences, University of Pretoria, South Africa

Corresponding author: D Joseph (darren.joseph@up.ac.za)

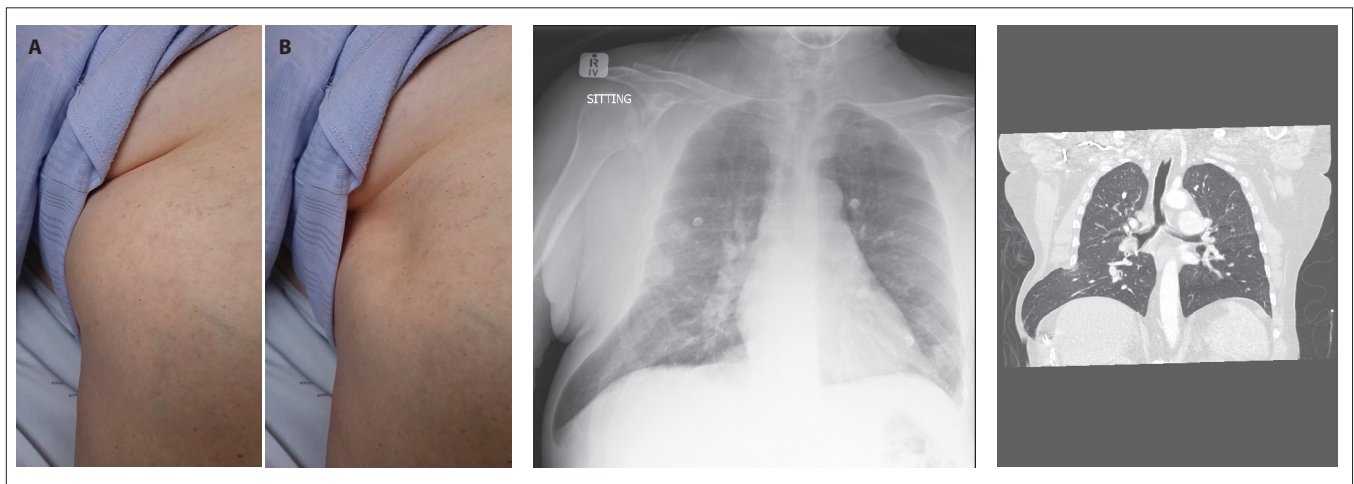
A 66-year-old man presented with a complaint of shortness of breath. He had a significant smoking history but no known medical conditions. Two years prior, he had been involved in a motor vehicle accident and sustained blunt trauma to his chest.

An obvious bulge was noted over the inferolateral aspect of his right chest with each expiration (Fig. 1A), as well as an obvious depression with each inspiration (Fig. 1B). The area was noted to be soft and spongy to touch. No crepitus was felt. There were breath sounds audible over the area.

A chest X-ray was performed which revealed an area of increased radiolucency in the right lower zone, extending beyond the thoracic cage that seemed to contain vascular markings (Fig. 2). A computed tomography (CT) scan was subsequently performed, which revealed previous right sided 7th, 8th and 9th posterolateral rib fractures with callus formation, as well as right lower lobe lung herniation through a lateral chest wall defect in the 8th intercostal space, consistent with a diagnosis of chronic post-traumatic intercostal lung hernia (Fig. 3).

Lung hernia is an uncommon entity, defined as the protrusion of the pulmonary tissue and pleural membranes beyond the confines of the thoracic cavity through an abnormal opening in the chest wall, diaphragm or mediastinum.^[1] They can be classified either by anatomic location or by aetiology (congenital and acquired).^[2] They can present acutely with symptoms ranging from dyspnoea to respiratory failure, or chronically which may be asymptomatic.^[3] The diagnosis is clinical and/or radiological.^[2] Conservative management can be considered in a select group of patients, however the majority should be surgically repaired to avoid complications, such as incarceration and strangulation of lung tissue, as well as paradoxical respiration and respiratory failure.^[3]

1. Detorakis EE, Androulidakis E. Intercostal lung herniation - the role of imaging. *Radiology Case* 2014;8(4):16-24. <https://doi.org/10.3941/jrcr.v8i4.1606>
2. Seder CW, Allen MS, Nichols FC et. al. Primary and prosthetic repair of acquired chest wall hernias: A 20-year experience. *Ann Thorac Surg* 2014;98(2):484-489. <https://doi.org/10.1016/j.athoracsur.2014.03.021>
3. Weissberg D, Refaely Y. Hernia of the lung. *Ann Thorac Surg* 2002;74(6):1963-1966. [https://doi.org/10.1016/s0003-4975\(02\)04077-8](https://doi.org/10.1016/s0003-4975(02)04077-8)



Figs 1A and 1B. Clinical examination of the chest demonstrating paradoxical respiration with obvious bulging over the inferolateral right chest during expiration (Fig. 1A) and depression during inspiration (Fig. 1B).

Fig. 2. Chest radiograph revealing an area of increased radiolucency in the right lower zone, that appears to extend beyond the thoracic cage and contain vascular markings.

Fig. 3. Computed tomography (CT) confirming right lower lobe lung herniation through a lateral chest wall defect in the 8th intercostal space.