

External jugular vein pierced by supraclavicular branches in a neonatal cadaver: a case report

Lané Prigge^{1,2,*}, Adrian T. Bosenberg³ & Albert N. van Schoor²

1. Department of Anatomy, School of Medicine, Sefako Makgatho Health Sciences University, Medunsa, PO Box 232, Ga-Rankuwa, 0204, Republic of South Africa
2. Department of Anatomy, School of Medicine, Faculty of Health Sciences, University of Pretoria, Pretoria, South Africa
3. Department of Anesthesiology and Pain Management, University of Washington and Seattle Children's Hospital, Seattle, WA, USA

Correspondence to Lané Prigge. Email: lane.prigge@smu.ac.za

Abstract

Anatomical variations in the venous structure and drainage patterns in the neck are not uncommon. However, this is the first known report on the external jugular vein being pierced by supraclavicular branches. In the lateral cervical region of a neonatal cadaver, the supraclavicular branches penetrated the external jugular vein superior to the clavicle, resulting in a circular venous channel formed around the nerve trunk. Variations such as these are important to note in order to minimize possible intra-operative complications sustained during surgical interventions such as venous catheterization or nerve grafts.

Keywords: Abnormalities; Anatomy; Cadaver; Embryology; Neck

Introduction

The external jugular vein mainly drains the scalp and face and is formed by the union of the posterior division of the retromandibular vein and the posterior auricular vein. This union occurs near the angle of the mandible, inferior to the auricle (Standring 2008; Moore et al. 2014). The external jugular vein descends deep to the platysma muscle and crosses the sternocleidomastoid muscle obliquely. Near the posterior border of the sternocleidomastoid muscle, it pierces the investing layer of the deep cervical fascia, which forms the roof of the lateral cervical region, before it terminates in the subclavian vein, in the inferior part of the lateral cervical region (Moore et al. 2014).

The cutaneous branches of the cervical plexus emerge at the midpoint of the posterior border of the sternocleidomastoid muscle, often referred to as the nerve point of the neck (Moore et al. 2014). The lesser occipital nerve, great auricular nerve and transverse cervical nerve arise from the nerve loop between the anterior rami of C2 and C3 nerve roots, while the supraclavicular nerves arise from the nerve loop formed between C3 and C4, to innervate the anterior and lateral aspects of the cervical skin (Standring 2008; Moore et al. 2014). The

supraclavicular nerves emerge as a common trunk, posterior to the sternocleidomastoid muscle. This trunk descends deep to the platysma muscle and divides into the medial, intermediate and lateral branches, prior to piercing the deep cervical fascia slightly superior to the clavicle (Standring 2008). The medial supraclavicular branches are closely related to the external jugular vein as they cross infero-medially to innervate the anterior cervical skin. In this case report, the trunk of two supraclavicular branches pierces the external jugular vein, prior to dividing into its terminal branches.

Case report

During microdissection of 51 pediatric formalin-fixed cadavers (42 neonates; eight infants, one 2-year old; 29 males and 22 females), an anatomical variation in the left lateral cervical region was observed in a stillborn, male neonatal cadaver. These dissections were performed in the Anatomy Department of the University of Pretoria, after ethical clearance was obtained (University of Pretoria, Research Ethics number: 77/2014), and in accordance with the ethical standards laid out in the 1964 Declaration of Helsinki and all subsequent revisions. The dissection of this neonatal cadaver followed the standard lateral cervical dissection technique where the skin, superficial fascia of the neck and platysma muscle were systematically removed. After the investing layer of the deep cervical fascia was removed, the superficial branches of the cervical plexus were observed where they emerged around the midpoint of the posterior border of the sternocleidomastoid muscle. The respective cutaneous branches of the cervical plexus were carefully exposed and followed to their endpoints.

During the dissection of the left cervical region, a rare case of perforation of the external jugular vein by the supraclavicular branches was observed. The medial and intermediate branches pierced the external jugular vein as a single trunk before branching. The lateral branch passed posterior to the external jugular vein without piercing the vein (Fig. 1). No other variations were observed in the distribution of these nerves or the remaining cutaneous branches of the cervical plexus.

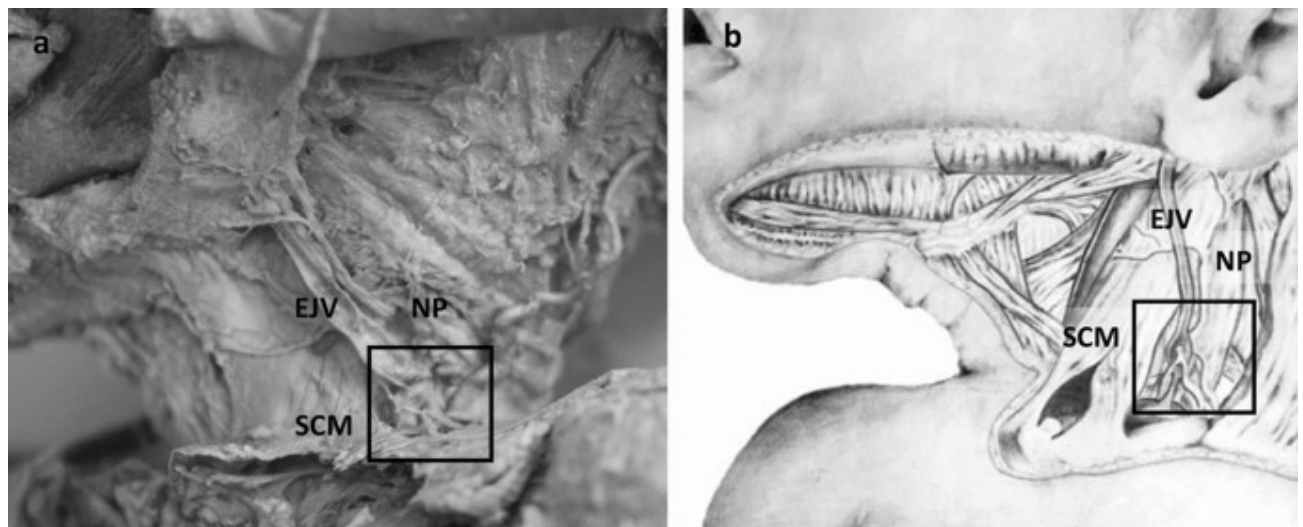


Fig. 1. a, b Supraclavicular nerves piercing the left external jugular vein in a neonatal cadaver. *EJV* External jugular vein, *NP* nerve point of the neck, *SCM* sternocleidomastoid muscle

As a result of the external jugular vein being pierced by a supraclavicular nerve trunk, the external jugular vein is temporarily split into two channels, forming a loop around the nerve. A narrowing in the external jugular vein can be observed prior to the formation of the two parallel channels, with the medial channel having a greater diameter than the lateral channel (Fig. 2). The united distal external jugular vein had a similar width as the proximal section of the vein. The external jugular vein drained into the subclavian vein normally.

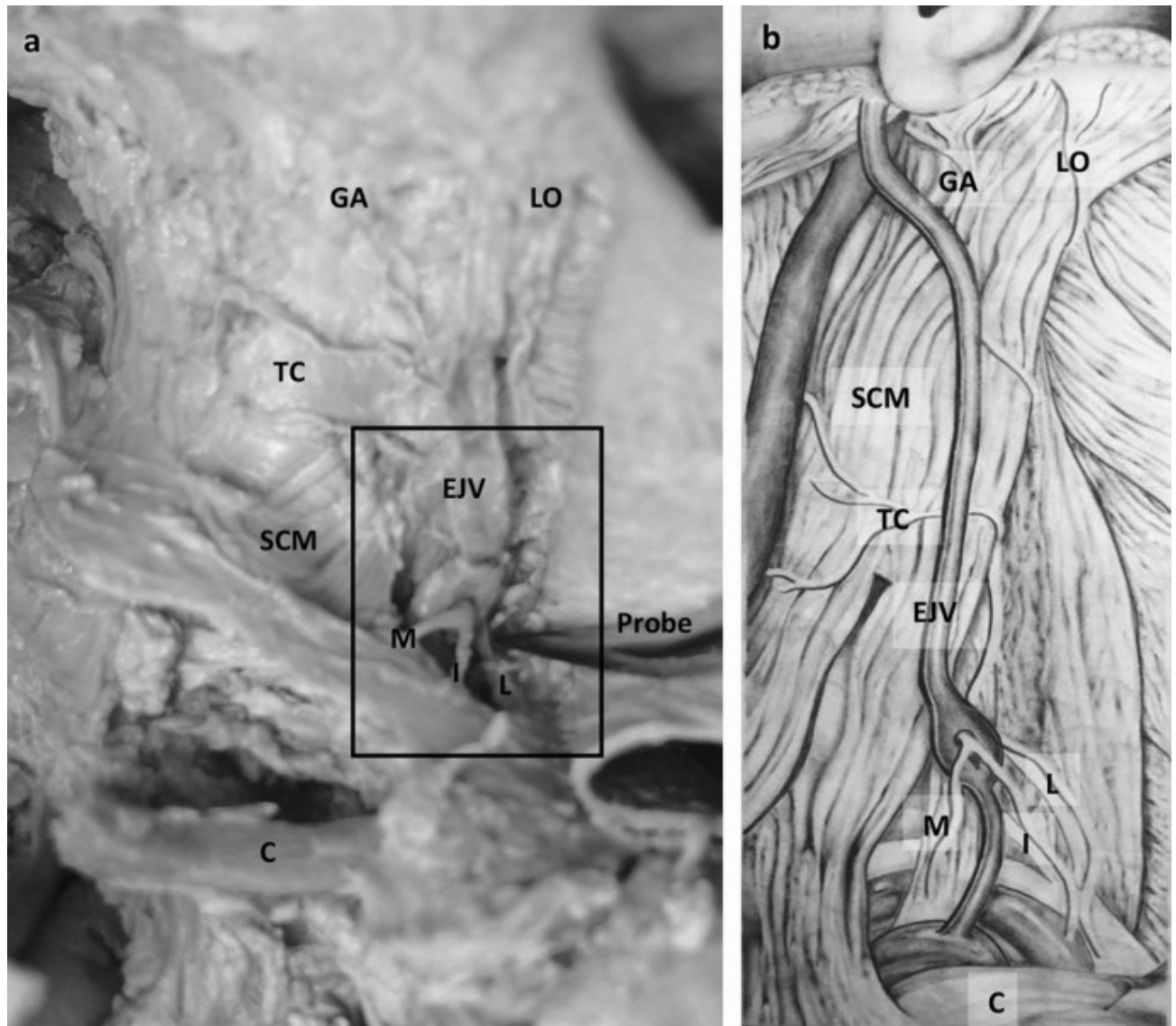


Fig. 2. a, b Enlarged view of external jugular vein perforation by common trunk of the medial ~ and intermediate supraclavicular nerves, with the lateral supraclavicular nerve emerging posterior to perforation, as indicated by the probe. *GA* Great auricular nerve, *LO* lesser occipital nerve, *TC* transverse cervical nerve, *EJV* external jugular vein, *SCM* sternocleidomastoid muscle, *C* clavicle, *M* medial supraclavicular nerve, *I* intermediate supraclavicular nerve, *L* lateral supraclavicular nerve

Discussion

The importance of sound anatomical knowledge is greatly emphasized throughout the literature and is necessary to ensure that clinical procedures are successfully performed in a safe manner (Van Schoor et al. 2005; Prigge et al. 2013). Anehosur et al. (2015) suggested that knowledge of variations in venous patterns in the face and neck is of paramount importance for head and neck surgeons to avoid unnecessary hemorrhaging during surgical procedures.

We describe a rare occurrence of the common trunk of two supraclavicular branches of the cervical plexus perforating the external jugular vein in a neonatal cadaver. Various anomalies regarding these neurovascular structures are reported in the literature. These include branches of the supraclavicular nerve piercing the clavicle (Tubbs et al. 2006; Rao et al. 2009), the external jugular vein bifurcating (Rao et al. 2018), as well as duplication of the external jugular vein (Comert and Comert 2009; Paraskevas et al. 2014).

Other examples of a nerve piercing a blood vessel have been noted in the literature, mostly related to the internal jugular vein and the spinal accessory nerve (Gardiner et al., 2002; Ibrahim et al. 2016). In these cases, a section of the internal jugular vein was duplicated, with the spinal accessory nerve passing between the window created by the partial duplication. This partial duplication can also be referred to as a fenestration, since the bifurcated vein reunites proximal to its final termination or drainage point (Ibrahim et al. 2016).

Roy and Sharma (2004) described a case where the medial cutaneous nerve of the forearm pierced the axillary vein and passed through a tunnel created by two narrow veins on either side of this tunnel. Apart from the different neurovascular structures involved, and different explanations provided, these cases are similar to the observations in this case.

A duplicated external jugular vein was observed in a female patient during a subtotal glossectomy and lymph node dissection. The right external jugular vein was duplicated in its middle third, forming a medial and lateral vein that united in a single vein near the posterior border of the sternocleidomastoid muscle, prior to penetrating the deep fascia of the neck (Comert and Comert 2009).

According to Rao et al. (2018), the complex embryological development of the vascular system can result in clinically relevant anomalies. These abnormalities can be unilateral or bilateral and are more often observed in the venous structures than the arterial distribution (Anehosur et al. 2015). Different theories with regard to these anomalies have been postulated. Prades et al. (2002) suggested that the venous duplications are not clearly explained by the embryology. The vascular embryological theory is the most common explanation. Duplication of the internal jugular vein, with the accessory nerve passing between the duplication may occur due to the nerves appearing after the vessels and that inadequate condensation of the embryonic capillary plexus results in the formation of this anomaly (Prades et al. 2002). This explanation can also be applied to the formation of the external jugular venous channels as presented in this study.

Roy and Sharma (2004) believe that the venous loop created around a nerve is not that uncommon. However, discrepancies are observed in the reporting of these nerve and vein relationships. They attribute these discrepancies to the modern dissecting technique which

calls for the venous structures to be removed in order to clear the dissection field (Roy and Sharma 2004).

The neurovascular anomaly described in this study has several clinical implications. The external jugular vein is often used for central venous catheterization (Comert and Comert 2009; Rao et al. 2009). It is also used as the recipient vein in free tissue transfers in the head and neck region (Comert and Comert 2009). Awareness of drainage patterns are particularly important in microvascular anastomoses (Anehosur et al. 2015; Rao et al. 2018).

The supraclavicular nerve can be used as a donor nerve for patients suffering from complete brachial plexus palsies (Ihara et al. 1996). The supraclavicular nerve can also be used in neurotization (nerve transfer) with the mental nerve in patients experiencing trigeminal nerve palsy after cerebrovascular accidents (Mucci and Dellon 1997).

In conclusion, the authors are not aware of any literature presenting a case such as this one, involving these specific neurovascular structures. Variations such as these usually remain undetected; however, it is important to inform surgeons and other clinicians of this potential relationship in order to prevent unforeseen complications during surgical interventional procedures.

Acknowledgements

The authors would like to thank the following persons without whose contributions this manuscript would not have been possible: Barbara Viljoen, for her valued assistance with language editing, Jade Naicker, for her artistic illustrations and Marinda Pretorius for final editing of figures and illustrations.

Ethics declarations

Conflict of interest

The authors declare that they have no conflict of interest.

References

- Anehosur V, Rajendiran S, Jayade GR, Kumar N (2015) An unusual observation during neck dissection. *J Maxillofac Oral Surg* 15:306–308
- Comert E, Comert A (2009) External jugular vein duplication. *J Craniofac Surg* 20:2173–2174
- Gardiner KJ, Irvine BW, Murray A (2002) Anomalous relationship of the spinal accessory nerve to the internal jugular vein. *Clin Anat* 15:62–63
- Ibrahim B, Berania I, Moubayed SP, Christopoulos A, Ayad T (2016) Internal jugular vein duplication: anatomic relationship with the spinal accessory nerve. *J Maxillofac Oral Surg* 74:1–4
- Ihara K, Doi K, Saikai K, Kuwata N, Kawai S (1996) Restoration of sensibility in the hand after complete brachial plexus injury. *J Hand Surg* 21:381–386

- Moore KL, Dalley AF, Agur AMR (2014) Clinically oriented anatomy, 7th edn. Wolters Kluwers, Lippincott, Williams and Wilkins, Philadelphia, pp 995–996
- Mucci SJ, Dellon AL (1997) Restoration of lower-lip sensation: neurotization of the mental nerve with the supraclavicular nerve. *J Reconstr Microsurg* 13:151–155
- Paraskevas G, Natsis K, Ioannidis O, Kitsoulis P, Anastasopoulos N, Spyridakis I (2014) Multiple variations of the superficial jugular veins: case report and clinical relevance. *Acta Medica* 57:34–37
- Prades JM, Timoshenko A, Dumollard JM, Durand M, Merzougui N, Martin C (2002) High duplication of the internal jugular vein: clinical incidence in the adult and surgical consequences, a report of three clinical cases. *Surg Radiol Anat* 24:129–132
- Prigge L, Van Schoor A-N, Bosman MC (2013) Evaluation of paediatric regional anaesthetic procedures in the head and neck region. MSc dissertation. University of Pretoria
- Rao TR, Shetty P, Roa S (2009) A rare case of looping of supraclavicular nerve branches around external jugular vein and transverse cervical artery. *Int J Anat Var* 2:48–50
- Rao S, Pandey S, Kumar Y, Rao S (2018) Bifurcation of external jugular vein: an anatomical variation during neck dissection. *Oral Maxillofac Surg* 22:475–476
- Roy TS, Sharma S (2004) Axillary vein perforation by the medial cutaneous nerve in the forearm. *Clin Anat* 17:300–302
- Standring S (2008) Gray's anatomy. The anatomical basis of clinical practice, 40th edition. Churchill, Livingstone, Elsevier, pp 407, 435, 436, 451
- Tubbs RS, Salter EG, Oakes WJ (2006) Anomaly of the supraclavicular nerve: case report and review of the literature. *Clin Anat* 19:599–601
- Van Schoor A-N, Boon JM, Bosenberg AT, Abrahams PH, Meiring JH (2005) Anatomical considerations of the paediatric ilio-inguinal/ iliohypogastric nerve block. *Ped Anesth* 15:371–377