








Mantle cell lymphoma, malt lymphoma, small lymphocytic lymphoma, and follicular lymphoma of the oral cavity: An update

Vivian Petersen Wagner^{1,2}  | Carla Isabelly Rodrigues-Fernandes¹  |
 Marcus Vinícius Ribeiro Carvalho¹ | Jean Nunes dos Santos³  | Marinez Bizarro Barra⁴ |
 Keith D. Hunter^{2,5}  | Jose Manuel Aguirre-Urizar⁶ | Willie F. P. van Heerden⁵ |
 Pablo Agustin Vargas^{1,5}  | Felipe Paiva Fonseca^{1,5,7}  | Manoela Domingues Martins^{1,8} 

¹Department of Oral Diagnosis, Piracicaba Dental School, University of Campinas, Piracicaba, Brazil

²Academic Unit of Oral and Maxillofacial Medicine and Pathology, Department of Clinical Dentistry, University of Sheffield, Sheffield, UK

³Department of Oral Pathology, School of Dentistry, Federal University of Bahia, Salvador, Brazil

⁴Pathology Service, Moinhos de Vento Hospital, Porto Alegre, Brazil

⁵Department of Oral Biology and Pathology, School of Dentistry, University of Pretoria, Pretoria, South Africa

⁶Unit of Oral Pathology and Medicine, Department of Stomatology II, University of the Basque Country/EHU, Leioa, Spain

⁷Department of Oral Surgery and Pathology, School of Dentistry, Universidade Federal de Minas Gerais, Belo Horizonte, Brazil

⁸Department of Pathology, School of Dentistry, Federal University of Rio Grande do Sul, Porto Alegre, Brazil

Correspondence

Vivian Petersen Wagner, Academic Unit of Oral and Maxillofacial Medicine and Pathology, 19 Claremont Cres, Broomhall, Sheffield S10 2TA, UK.
 Email: vivianpetersen@hotmail.com

Abstract

Background: Although uncommon, mature small B-cell lymphomas may arise in the oral/maxillofacial area and oral pathologists must be aware of the key characteristics of these neoplasms to perform an accurate diagnosis. In this manuscript, we attempted to integrate the currently available data on the clinicopathological features of follicular lymphoma (FL), mantle cell lymphoma (MCL), extranodal marginal zone lymphoma of mucosa-associated lymphoid tissue (MALT-L), and chronic lymphocytic leukemia/ small lymphocytic lymphoma (CLL/SLL) affecting these anatomical regions. **Methods:** An updated descriptive literature review was carried out and a detailed electronic search was done in multiple databases to gather all cases affecting the oral/maxillofacial region and palatine tonsils.

Results: We observed that MALT-L was the most frequently reported subtype, followed by FL, MCL, and CLL/SLL. The palate was affected in a high proportion of cases and the most usual clinical presentation was an asymptomatic swelling. MALT-L and CLL/SLL neoplastic cells were strongly associated with small salivary glands. FL showed no gender preference, while MCL and CLL/SLL were more prevalent in males and MALT-L in females. Overall, cases were more common in elderly individuals. Patients' treatment and outcome varied, with MCL being the most aggressive neoplasm with a dismal prognosis in comparison to FL and MALT-L.

Conclusion: Despite the poor documentation in many of the cases available, especially regarding the microscopic and molecular features of tumors, this review demonstrated that the oral mature small B-cell lymphomas investigated share similar clinical presentation, but carry different prognostic significance, demanding an accurate diagnosis.

Special issue "Lymphomas and lymphoid lesions of the oral cavity".

This is an open access article under the terms of the Creative Commons Attribution License, which permits use, distribution and reproduction in any medium, provided the original work is properly cited.

© 2021 The Authors. *Journal of Oral Pathology & Medicine* published by John Wiley & Sons Ltd.

KEYWORDS

follicular lymphoma, lymphocytic lymphoma, lymphoma, malt lymphoma, mantle cell lymphoma, oral cavity

1 | INTRODUCTION

Some mature B-cell lymphomas share a small-cell morphology, including follicular lymphoma (FL), mantle cell lymphoma (MCL), extranodal marginal zone lymphoma of mucosa-associated lymphoid tissue (MALT-L), and chronic lymphocytic leukemia/ small lymphocytic lymphoma (CLL/SLL). In the oral/maxillofacial area, these lesions are not as common as large B-cell lymphomas, yet they may comprise an important number of cases, and for this reason, knowing the clinicopathological features of these neoplasms is important to allow an accurate diagnosis.

Herein, we aimed to provide an updated review of the main topics of this heterogeneous group of neoplasms and to perform a detailed electronic search for published reports of mature small B-cell lymphomas affecting the oral/maxillofacial region and the palatine tonsils. In order to homogenize our literature review, only cases published from 2001 and that followed the World Health Organization

guidelines for hematolymphoid neoplasms were considered.¹ This study forms part of a special issue published by the Journal of Oral Pathology and Medicine covering the most important aspects of hematolymphoid lesions and neoplasms affecting the oral cavity and neighboring structures.

1.1 | Lymphomagenesis of mature small B-cell lymphomas

FL is associated with a recurrent chromosomal translocation, t(14;18) (q32;q21), resulting in the fusion of the IGH and BCL2 genes. This occurs in early pre-B cells in the bone marrow that will further engage in a process of re-entry into the GC and which may result in FL development (Figure 1).² Meanwhile, MCL is associated with a recurrent t(11;14)(q13;q32) translocation, leading to Cyclin-D1 deregulation. The event driving CCL/SLL is not fully understood, however,

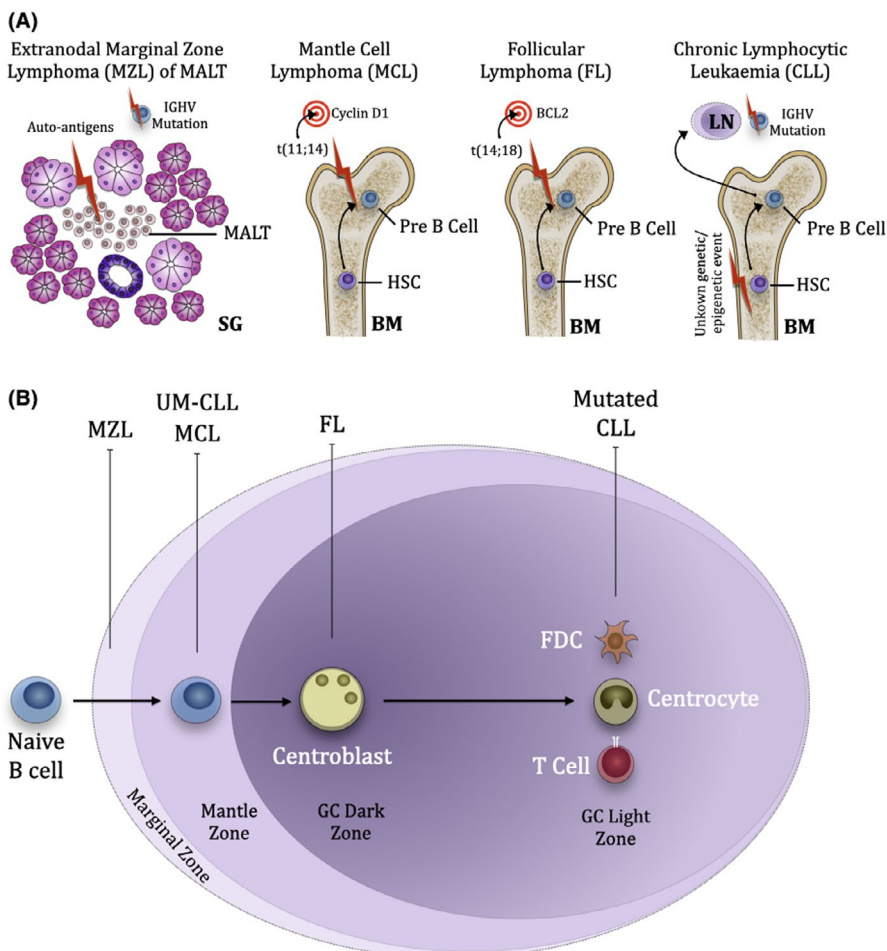


FIGURE 1 Schematic figure of mature small B-cell lymphomas development based on (A) early trigger event and (B) germinal center origin. Follicular lymphoma originates from a GC B cell; mantle cell lymphoma from a mantle zone B cell; marginal zone lymphomas from a marginal zone B cell; and chronic lymphocytic leukemia/ small lymphocytic lymphoma (CLL/SLL) have two possible origins: B cells that have not undergone GC differentiation or post-GC B cells. BM, bone marrow; CLL, chronic lymphocytic leukemia; FDC, follicular dendritic cell; GC, germinal center; MALT, mucosa-associated lymphoid tissue; SG, salivary gland; UM-CLL, unmutated CCL

about 80% of patients with CLL/SLL carry at least one of the following four chromosomal alterations: deletion in chromosome 13q14.3 (del(13q)), del(11q), del(17p), or trisomy 12.³ Moreover, a later event is the mutation in the immunoglobulin heavy-chain variable region (IGHV) gene. CLL/SLL with mutated IGHV originates from post-GC B cells, while non-mutated cases are thought to originate from pre-GC (naive) B cells or GC-independent antigen-experienced B cells.⁴

MALT-L development is acknowledged to have a chronic antigen stimulus, either of microbial origin or auto-antigens. The antigen does not directly transform the lymphoid cell, it rather increases the risk of lymphomatous transformation.^{1,5} The autoreactive B cells that progressively infiltrate salivary glands in Sjögren's Syndrome (SS) reproduce the architecture of mucosa-associated lymphoid tissue.^{6,7} The risk of SS patients to develop a NHL is estimated to be 4- to 19- fold higher than the general population.⁶ Several independent predictors have been described, such as salivary gland enlargement, anti-Ro/La autoantibodies, ectopic germinal centers, among others.⁸

1.2 | Follicular lymphoma

FL is the second most common subtype of non-Hodgkin lymphoma (NHL) in western countries.^{9,10} Within the oral cavity, this frequency pattern seems to be maintained.¹¹⁻¹⁴ In our review, we retrieved information of 22 cases of oral/maxillofacial FL with enough demographic or clinic-pathologic data (Table S1). We observed a male:female ratio of 1.2:1 and a mean age at diagnosis of 67 years (ranging from 38 to 92 years) (Table 1), in line with the overall literature.⁹

The palate ($n = 14$) and gingiva ($n = 3$) were the most affected oral sites (Table 1) usually demonstrating a localized swelling as the most frequent clinical appearance. The most common manifestation of FL is a widespread disease without B symptoms.^{1,2} Four cases reported simultaneous involvement of lymph nodes and one reported widespread bone marrow involvement. No description of B symptoms was identified. Only eight cases described the Ann Arbor stage. Early stage disease was reported in 50% of cases, contrasting with the overall tendency of FL, which is about 10–25% of patients with early stage disease.^{1,15} According to the last WHO classification,¹ grading of FL should be performed according to the Lugano classification, in which the designation of a case as A or B (asymptomatic or symptomatic) is no longer required.

Microscopically, FL is characterized by a predominant follicular growth pattern, but a partial or complete absence of a follicular pattern might also be encountered, especially in small biopsies. The classical appearance is of closely packed, spread follicles, effacing the normal architecture of the affected tissue. The neoplastic follicles are poorly defined, with attenuated or absent mantle zones, and lack of polarization (Figure 2A). A monomorphic cellular phenotype is observed, with a predominance of centrocytes, and scattered centroblasts.^{1,2,16} FL grading is performed based on the number of centroblasts per high-power field: Grade 1 (0–5); Grade 2 (6–15); Grade 3A (>15); and Grade 3B (>15 with solid sheets of centroblasts present). Clinical behavior differs among grades, being more aggressive

TABLE 1 Summary of main clinical features and outcome of oral small B-cell lymphomas

	M:F ratio	Age (mean and range)	Preferred oral site(s)	Clinical manifestation	B symptoms	AA Clinical Stage	Recurrence	Follow-up
Follicular lymphoma ($n = 22$)	1.2:1	67.13 38–92	Palate ($n = 14$)	Swelling/mass ($n = 8$)	Absent/ not described	Stage I- $n = 3$	Yes ($n = 2$)	Alive ($n = 13$) No disease relate death
			Gingiva ($n = 3$)	Widespread involvement ($n = 4$)		Stage II- $n = 1$	No ($n = 5$)	
Mantle Cell lymphoma ($n = 21$)	4.25:1	69.95 41–93	Palate ($n = 15$)	Non-ulcerated swelling ($n = 16$)	Rare Fever ($n = 1$)	Stage I- $n = 2$	Yes ($n = 3$)	Alive ($n = 7$) Disease relate death ($n = 5$)
			Bilateral involvement ($n = 5$)	Widespread involvement ($n = 11$)		Stage II- $n = 0$	No ($n = 7$)	
MALT lymphoma ($n = 60$)	1:2	56.9 7–87	Lip ($n = 17$)	Non-ulcerated swelling ($n = 41$)	Absent/ not described	Stage I- $n = 17$	Yes ($n = 6$)	Alive ($n = 45$) Disease relate death ($n = 3$)
			Palate ($n = 11$)	Ulcerated swelling ($n = 5$) Sjögren's syndrome ($n = 11$)		Stage II- $n = 4$	No ($n = 23$)	
CLL/SLL ($n = 16$)	4.3:1	63.9 43–83	Minor salivary glands ($n = 5$)	Swelling ($n = 8$)	Rare Fever/night sweats ($n = 1$)	Stage I- $n = 2$	Not described	Alive ($n = 10$) Disease relate death ($n = 2$)
			Palate ($n = 4$)	Pain ($n = 3$); Dysphagia ($n = 2$) Widespread involvement ($n = 7$)		Stage II- $n = 4$		

Note: Abbreviations: AA, ann arbor; CLL/SLL, chronic lymphocytic leukemia/small lymphocytic lymphoma; M:F, male: female. For full information refer to supplementary material.

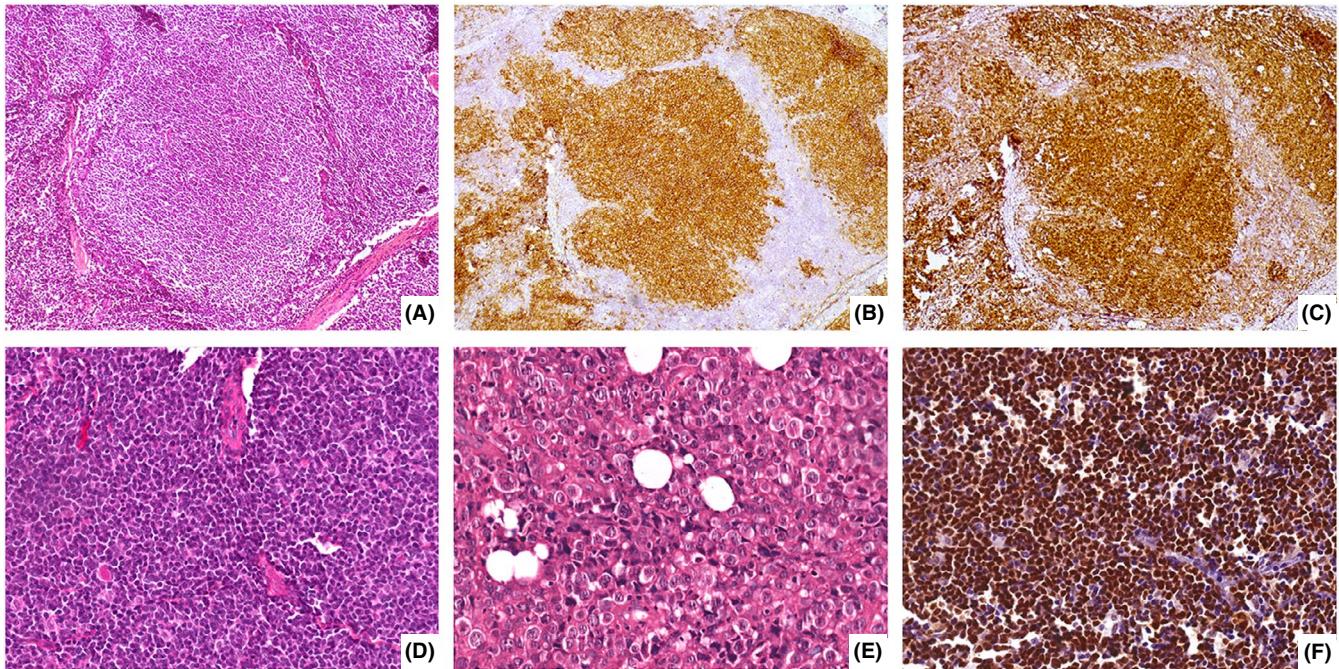


FIGURE 2 Microscopic and immunohistochemical features of follicular lymphoma (A-C) and mantle cell lymphoma (D-F). (A): Irregular, large neoplastic follicle, without the presence of tingible-body macrophages and the so-called “starry sky pattern.” Loss of polarization between the follicular margins is also observed (hematoxylin–eosin, $\times 100$). (B): Diffuse expression of CD10 antibody in the neoplastic cells (diaminobenzidine, $\times 100$). (C): Remarkable expression of Bcl-2 antibody in the central areas of the neoplastic follicles which were also positive to CD10 (diaminobenzidine, $\times 100$). (D): Microscopic aspect of classic mantle cell lymphoma, showing a sheet of small-sized cells with scant cytoplasm and condensed nuclei (hematoxylin–Eosin, $\times 200$). (E): Representative case of pleomorphic variant with large cells, pale cytoplasm and vesicular nuclei (hematoxylin–eosin, $\times 200$). (F): Diffuse expression of cyclin-D1 in the classic variant of mantle cell lymphoma (diaminobenzidine, $\times 200$)

in Grade 3B cases.¹⁷ In our review, 14 cases reported the histological grade: eight were grade 1, four were grade 2, and only two cases were graded as 3, in line with the literature.¹

Four architectural patterns are recognized: follicular (>75% of follicular architecture); follicular and diffuse (25–75% of follicular architecture); focally follicular / predominantly diffuse (<25% of follicular architecture); diffuse (absence of follicular areas, but micro-follicles remain present).¹ We did not identify any description of such patterns in the oral cavity cases.

FL immunophenotype is usually of CD20+, CD10+, BCL6+, BCL2+, CD23+/-, CD43-, CD5-, Cyclin D1- (Table 2).^{1,16} CD10 expression is typically stronger inside the neo-follicles compared to the interfollicular area (Figure 2B). Bcl2 expression, a result of t(14;18)(q32;q21), is useful to rule out reactive follicular hyperplasia (Figure 2C).¹ Fluorescence in situ hybridization (FISH) is the most sensitive method to detect the fusion gene. In the cases reviewed, seven were shown to be positive for the translocation, whereas five were negative and 11 did not perform/present the translocation status. As a low-grade tumor, Ki67 in FL is usually low, around 20% for grade 1 and 2 tumors.¹⁸

FL is known to regress and relapse over the years, requiring patients' careful surveillance and possible maintenance of their therapy.² In our review, only two patients presented recurrence during follow-up and no patient deceased due to the tumor.

1.3 | Mantle cell lymphoma

MCL represents 1.3% of all hematological malignancies.¹⁰ However, a US-population-based study observed that oropharyngeal MCL accounted for 7.8% of the cases.¹⁴ Likewise, a study of oral NHL found that MCL was the third most common type.¹¹ We identified 21 published cases of oral/maxillofacial MCL (Table S1). The male: female ratio was 4.2:1, in agreement with general literature.⁹ The average age at diagnosis was 69.95 years (range 41–93), which is slightly lower than the overall reported of 72.9 years (Table 1).¹⁰

The most common clinical presentation was a non-ulcerated swelling usually in the palate ($n = 15$). Cases concomitantly affecting the palate and other oral sites were also identified. Five patients (20%) presented with bilateral palatal swelling and 11 patients (52%) were diagnosed with widespread disease. Only one study reported a history of fever, while other systemic symptoms included nausea, loss of appetite, and abdominal pain (Table S1). Information about the stage was available for six cases: Four patients were diagnosed in advanced stages (III/IV) (Table 1), which seems to corroborate the literature.¹

MCL is classified into four major morphological variants: leukemic non-nodal, classic, blastoid, and pleomorphic. The WHO also recognizes small-cell and marginal-zone-like variants.¹ We

TABLE 2 Main immunohistochemical and molecular markers for the diagnosis of small B-cell lymphomas

	CD20	CD79a	CD10	BCL6	BCL2	CD23	IRTA1	MNDA	CD43	CD5	Cyclin D1	Sox 11	CD200
	Mature B cell	Mature B cell	Germinal center	Germinal center	Anti-apoptotic	FL dendritic cells	Marginal zone B Cell	Marginal zone B Cell	Pan T cell	T-cell marker	MCL	MCL	MCL
Follicular lymphoma	+	+	+(FLA)	+	+(FLA and IFA)	+/-	-	-	-	-	-	-	-
Mantle cell lymphoma	+	+	-(rare +)	-	+	-	-	-/+	+/-	+(5% negative)	+	+	-
MALT lymphoma	+	+	-(rare +)	-	-	+	+	+	+/-	-(rare +)	-	-	-
Small lymphocytic lymphoma	+	+	-	-	+	+	-	-	+	+	-	-	+

identified the classic variant as the most common ($n = 11$), followed by the blastoid ($n = 3$), small-cell ($n = 1$), and pleomorphic ($n = 1$).¹⁹

In classic MCL, the neoplastic cells are small to medium-size with moderately irregular nuclear contours. The chromatin is rather dispersed, nucleoli are inconspicuous, and cytoplasm scant (Figure 2D). Hyaline small vessels and epithelioid histiocytes are commonly observed and non-neoplastic reactive plasma cells may also be present. The number of mitotic figures is usually low to moderate.^{1,20} The architectural pattern of classic MCL varies between diffuse, vague nodules, interstitial, mantle zone growth, and even follicular.²¹ In the blastoid variant, malignant cells resemble lymphoblasts, being slightly larger with dispersed chromatin and the mitotic rate is considerably higher than classic MCL.¹ The pleomorphic variant presents large cells, with a round to oval nuclear contours, and pale cytoplasm (Figure 2E). The small-cell variant comprises small and round lymphomatous cells with compacted chromatin. The marginal-zone-like subtype exhibit foci of cells with abundant pale cytoplasm, resembling monocytoid cells.

Neoplastic cells present strong reactivity to CD20, and the Bcl2+, CD10- and Bcl6- phenotype helps to differentiate MCL from FL.²⁰ Residual GC cells (CD10+, Bcl6+) can be detected admixed with the neoplastic population. CD5 and Cyclin-D1 (Figure 2F) are important markers for MCL diagnosis (Table 2). In view of possible CD5 or Cyclin-D1 negativity, SOX11 has emerged as a marker to assist MCL diagnosis.²² We retrieved two oral cases lacking CD5 expression (Table S1). Classic and small-cell variants have considerably lower proliferation index, around 15%, compared to pleomorphic and blastoid variants (~28%), and the percentage of Ki67-positive cells may be associated with overall survival.²³

Cytogenetics typically reveals the translocation t(11;14)(q13;q32) in the vast majority (90%) of MCL cases, but with no prognostic impact.²⁴ The small percentage of Cyclin-D1-negative cases usually presents cyclin D2/cyclin D3 translocations. We found six positive cases for t(11;14)(q13;q32) or CCND1 rearrangement, however, most of the reports did not describe this information.

MCL is recognized as an aggressive lymphoma with poor response to conventional therapy.²⁵ Recurrences were described in three cases, while the status during follow-up was provided for 15 patients, in which seven were alive, five were deceased due to the tumor, and three were deceased due to unknown causes.

1.4 | Extranodal marginal zone lymphoma of mucosa-associated lymphoid tissue

MALT-L is the fourth most common type of NHL in the oropharyngeal region, representing 5.3% of all lymphoid malignancies in a population-based study conducted in the United States.¹⁴ Interestingly, MALT-L represents the most common type of NHL affecting the salivary glands,²⁶ most likely as a result of its association with SS. In our literature review, 60 cases of MALT-L in the oral/maxillofacial region were identified (Table S1). The male: female ratio

was 1:2, indicating that women are more commonly affected by oral MALT-L. The mean age at diagnosis was 56.9 years, ranging from 7 to 87 years (Table 1), corroborating with the general literature on this tumor.^{1,27} Among 39 oral/maxillofacial cases with available information, 10 patients (25.6%) had SS.

The most common site of oral MALT-L was the lip ($n = 17$). In four cases, the site of origin was described as minor salivary glands, without no further specification. Other common locations included the palate, buccal mucosa, and palatine tonsils. The majority of patients presented a localized swelling, with five patients also showing ulcerated areas. No case reporting B symptoms was found. Only 22 cases reported stage at diagnosis, with 21 cases at initial stages (I/II). Advanced stages represented 4.5% (Table 1), which is lower than in major salivary glands, where 23% of cases were previously diagnosed in stages III or IV.²⁸

MALT-L is microscopically characterized by the proliferation of monoclonal small to medium-sized cells resembling centrocytes, with irregular nuclei, dispersed chromatin and inconspicuous nucleoli, or with a monocytoid appearance (Figure 3A).¹ Neoplastic cells gradually replace the mixed inflammatory infiltrate present at the site, while the salivary duct structures persist as epimyoeplithelial islands.²⁹ Three or more aggregates of marginal zone cells might infiltrate the epithelial structures, resulting in lymphoepithelial lesions (LEL),¹ which may occur both in a reactive or neoplastic context.³⁰ A halo-like expansion of centrocyte-like or monocytoid B cells

around the LEL is recognized as a morphologic feature suggestive of an initial/emerging MALT-L.³¹ The presence of amyloid can also be observed in MALT-L, and we identified one report describing an amyloid-rich minor salivary gland case (Supplementary Table S1).³² When solid, sheet-like, or clusters proliferations (>20 cells) of transformed large cells are present, the tumor should rather be diagnosed as DLBCL.¹ A high number of plasma cells in some cases may simulate extramedullary plasmacytomas.

MALT-L neoplastic cells are usually CD20+, CD79a+, CD5-, CD10-, CD23-, and CD43+/- (Table 2, Figure 3B).¹ This phenotype is virtually identical to non-neoplastic marginal-zone B cells, thus a clonality evaluation is recommended.³¹ Typically, all neoplastic cells present with identical immunoglobulin heavy-chain IgH rearrangements, combined with the expression of a single immunoglobulin light-chain (IgL) restriction, although in the literature kappa/lambda restriction is not demonstrated in all cases by immunohistochemistry. During the multistep antigen-driven lymphomagenesis, lymphoid cell proliferation is thought to progress first to monoclonality and then, after gaining secondary genetic alterations, to MALT-L.³³ Thus, limited areas of monoclonal cells are associated with a borderline diagnosis between clonal LESA/MESA or MALT-L.³⁴ Conversely, as malignant transformation might occur in a particular location within the lesion, areas of polyclonal cells can persist in other zones and this should not eliminate the possibility of MALT-L.⁷ Recognition of the cellular

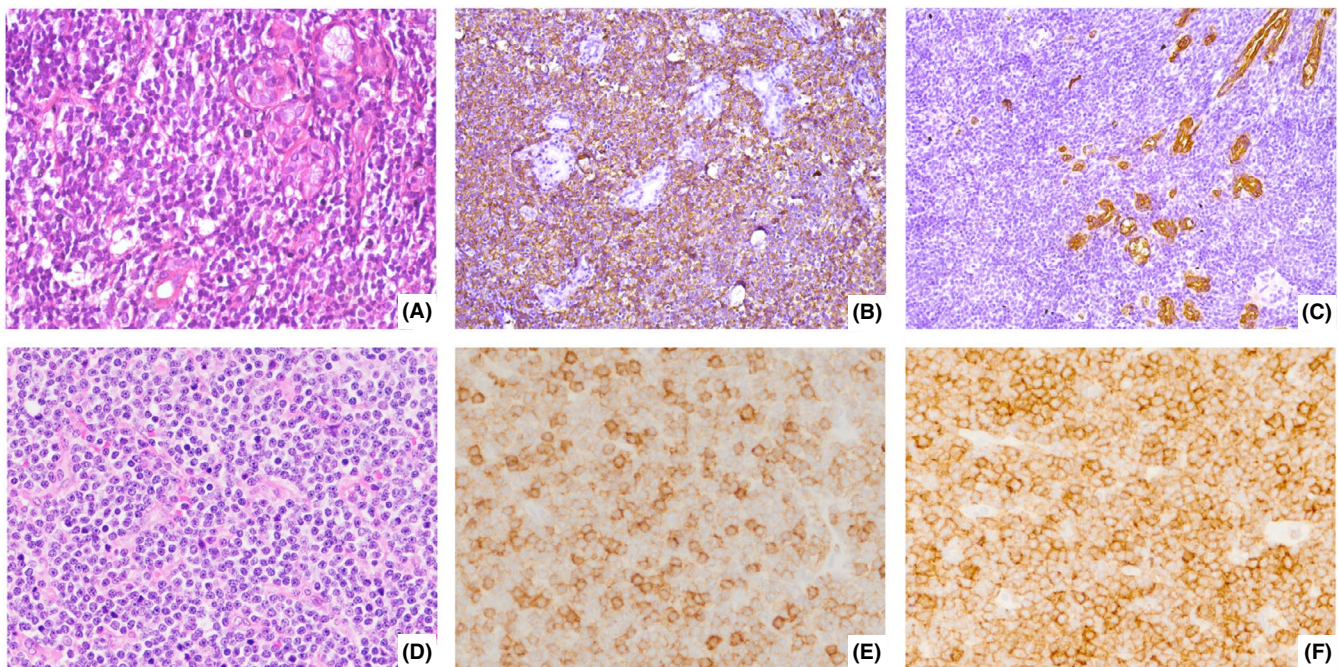


FIGURE 3 Microscopic findings and immunophenotype of MALT lymphoma (A-C) and chronic lymphocytic leukemia / small lymphocytic lymphoma (D-F). (A): Small and medium cells with a prominent monocytoid appearance. Reminiscent salivary ducts are also visualized (hematoxylin-eosin, $\times 400$). (B): Diffuse expression of CD20 antibody demonstrating the B-cell phenotype of MALT lymphoma (diaminobenzidine, $\times 200$). (C): Pan-cytokeratin (AE1/AE3) marker highlighting scattered salivary gland structures in contrast with the sheet of neoplastic cells (diaminobenzidine, $\times 200$). (D): Small and medium cells with clumped chromatin admixed with larger cells with dispersed chromatin (hematoxylin-eosin, $\times 400$). (E): Diffuse expression of CD5 antibody in the neoplastic cells (diaminobenzidine, $\times 400$). (F): Diffuse expression of CD23 antibody in the neoplastic cells (diaminobenzidine, $\times 400$)

immunophenotype might contribute in this regard as a higher number of CD3-positive cells would favor the diagnosis of a reactive lesion.^{29,30} In our review, the percentage of Ki67-positive cells in oral cases ranged from 5% to 30%.^{35,36}

MALT-L is recognized as a low-grade neoplasm. We observed that six patients (20.6%) presented with disease relapse: one at the same site (buccal mucosa), one in multiple oral sites, one in the lungs, and one in the gastric mucosa (Table S1). Localized low-grade MALT-L of the oral cavity and major salivary glands are usually excised and may not require any additional treatment besides an active monitoring.³⁷ We found that only three patients deceased during follow-up (in a mean time of 47 months).

1.5 | Chronic lymphocytic leukemia/small lymphocytic lymphoma

The WHO recognizes CLL and SLL as the same disease, which only differs according to the spread/location. CLL is characterized by a monoclonal B-cell count $>5 \times 10^9/L$ in the peripheral blood. The term SLL is used for cases with a cell count of less than $5 \times 10^9/L$ with extramedullary involvement¹ which is rare, and occurs most commonly in the skin or the central nervous system.³⁸ Sixteen cases of oral/maxillofacial CLL/SLL cases were retrieved from the literature—15 (93%) consisted of CLL and one was diagnosed as SLL (7%). We also found four articles describing the Richter's Syndrome (RS), a sudden transformation of CLL/SLL into a high-grade large-cell lymphoma (Table S1).³⁹

The male: female ratio was 4.3:1 (Table 1), in contrast with other studies that reported ratios of 1.88:1.^{9,10} The mean age at diagnosis was 63.9 years, similar to the 62-year mean age of extramedullary cases.³⁸ Five cases involved the minor salivary glands, although the exact oral site was not determined (Table 1). The most common clinical manifestation was swelling, and local symptoms included pain, dysphasia, and epistaxis (Table S1). Seven patients presented widespread involvement, most commonly to the lymph nodes. Only one case reported fever.

CLL is usually staged according to the Rai or Binet systems, while SLL is staged using the Ann Arbor staging scheme. In the context of CLL, Rai and Binet systems have higher prognostic value and thus are recommended.³ In our review, only two cases reported the stage based on these systems (Rai—0 and Binet—C), while eight patients were classified according to the Ann Arbor stage (Table 1).

Extranodal involvement of CLL or SLL is characterized by a vaguely nodular or sheet-like monotonous infiltrate of neoplastic cells with a round nucleus, condensed chromatin, and scant to moderate cytoplasm (Figure 3D).⁴⁰ The clumped chromatin is described as having a "soccer ball-like" or "block-like" appearance.^{41,42} Larger cells—prolymphocytes and paraimmunoblasts—can be found admixed in the background of small cells, and have clumped or dispersed chromatin, a single central nucleolus, and more abundant cytoplasm.⁴¹

CLL is characterized by the expansion of CD5+CD23+ monoclonal mature CD20+ B cells in the peripheral blood, secondary lymphoid tissues and bone marrow. In tissue samples, the co-expression of CD5

and CD23 in mature B cells is useful to confirm the diagnosis of CLL/SLL (Table 2, Figure 3E-F).^{1,3} CyclinD1/SOX11 negativity and CD200 positivity rules out the diagnosis of MCL.³ Ki67 expression is variable: it can range from 2% to 30–40%,^{43,44} but is usually below 50%.

CLL/SLL has no specific genetic signature.¹ IGHV gene status seems to have a prognostic value and is also associated with the stage of cell origin at the GC. It is estimated that 50–70% of CLL have mutated-IGHV (post-GC B cell origin) and 30–50% unmutated (pre-GC B-cell origin).¹ In our review, no report described the IGHV status.

The clinical outcome can vary from a very indolent clinical course with no need for treatment, to rapidly progression associated with death due to therapy-related and/or disease-related complications.³ In oral cases, one patient was managed with a "wait and watch" approach, and seven patients received chemotherapy. One patient deceased due to disease progression and another due to secondary infection. Ten patients were alive at the time of publication, but the follow-up period was short (12–18 months).

An aggressive form of disease progression is the RS, which can occur in either a DLBCL or a Hodgkin lymphoma.³⁹ In our review, all four cases that documented RS progressed to DLBCL. Three patients (75%) were females, with a mean age of 58.7 years. In all cases, the lesion affected the jawbones associated mucosa. Two patients deceased during follow-up, confirming the aggressive nature of this condition.

2 | CONCLUSIONS

Our literature review has compiled the available data of the main mature small B-cell lymphomas affecting the oral/maxillofacial region. We observed a significant amount of missing data, with a particular lack of immunophenotyping and genetic information, key features for an accurate diagnosis. SS status (for MALT-L cases), microscopic features, and follow-up data were also poorly described. Based on the limitations we faced for data analysis, our suggestions for future reports of mature small B-cell lymphomas in the oral/maxillofacial region are:

- Continue reporting new cases with full information, preferably with follow-up information;
- Ensure precise recording of all relevant demographic and clinical data, including the precise primary site;
- Include full information on microscopic analysis (subtype/grade) and immunophenotyping;
- Perform genetic analysis if possible
 - a. t(14;18)(q32;q21) investigation in FL cases
 - b. t(11;14)(q13;q32) investigation in MCL cases
 - c. IGHV gene status in CLL/SLL and MALT-L cases
- Report the Sjögren's syndrome status in MALT-L cases;
- Report CLL clinical stage following the Rai or Binet systems;
- If reporting a case series that contains mature small B-cell lymphomas, include full information about each case (in supplementary material if necessary).

ACKNOWLEDGEMENTS

The authors are grateful to the São Paulo State Research Foundation (FAPESP 2016/21785-4) for the student scholarship. Felipe Paiva Fonseca, Jean Nunes dos Santos, Pablo Agustin Vargas, and Manoela Domingues Martins are research fellows of the Brazilian National Council for Scientific and Technological Development (CNPq).

CONFLICT OF INTEREST

The authors declare no competing interest.

PEER REVIEW

The peer review history for this article is available at <https://publons.com/publon/10.1111/jop.13214>.

ORCID

Vivian Petersen Wagner  <https://orcid.org/0000-0002-1447-2135>

Carla Isabelly Rodrigues-Fernandes  <https://orcid.org/0000-0002-1290-6235>

[org/0000-0002-1290-6235](https://orcid.org/0000-0002-1290-6235)

Jean Nunes dos Santos  <https://orcid.org/0000-0001-7225-5879>

Keith D. Hunter  <https://orcid.org/0000-0002-7873-0877>

Pablo Agustin Vargas  <https://orcid.org/0000-0003-1840-4911>

Felipe Paiva Fonseca  <https://orcid.org/0000-0002-6657-4547>

Manoela Domingues Martins  <https://orcid.org/0000-0001-8662-5965>

[org/0000-0001-8662-5965](https://orcid.org/0000-0001-8662-5965)

REFERENCES

- Swerdlow SH, Campo E, Harris NL (eds). *WHO Classification of Tumours of Haematopoietic and Lymphoid Tissues* (4th edn). Lyon, France: IARC; 2017.
- Carbone A, Roulland S, Glohini A, et al. Follicular lymphoma. *Nat Rev Dis Primers*. 2019;5:83.
- Kipps TJ, Stevenson FK, Wu CJ, et al. Chronic lymphocytic leukaemia. *Nat Rev Dis Primers*. 2017;3:16096.
- Bosch F, Dalla-Favera R. Chronic lymphocytic leukaemia: from genetics to treatment. *Nat Rev Clin Oncol*. 2019;16:684-701.
- Borie R, Wislez M, Antoine M, Copie-Bergman C, Thieblemont C, Cadranel J. Pulmonary mucosa-associated lymphoid tissue lymphoma revisited. *Eur Respir J*. 2016;48:1252.
- Sagaert X, De Wolf-Peeters C, Noels H, Baens M. The pathogenesis of MALT lymphomas: where do we stand? *Leukemia*. 2007;21:389-396.
- Zucca E, Bertoni F. The spectrum of MALT lymphoma at different sites: biological and therapeutic relevance. *Blood*. 2016;127:2082-2092.
- Kapsogeorgou EK, Voulgarelis M, Tzioufas AG. Predictive markers of lymphomagenesis in Sjögren's syndrome: from clinical data to molecular stratification. *J Autoimmun*. 2019;104:102316.
- Teras LR, DeSantis CE, Cerhan JR, Morton LM, Jemal A, Flowers CR. 2016 US lymphoid malignancy statistics by World Health Organization subtypes. *CA Cancer J Clin*. 2016;66:443-459.
- NMRN Researchers. [hmrn.org](https://www.hmrn.org/statistics). Available at <https://www.hmrn.org/statistics>. 2019. Accessed on October 18, 2020.
- van der Waal RI, Huijgens PC, van der Valk P, van der Waal I. Characteristics of 40 primary extranodal non-Hodgkin lymphomas of the oral cavity in perspective of the new WHO classification and the International Prognostic Index. *Int J Oral Maxillofac Surg*. 2005;34:391-395.
- Kemp S, Gallagher G, Kabani S, Noonan V, O'Hara C. Oral non-Hodgkin's lymphoma: review of the literature and World Health Organization classification with reference to 40 cases. *Oral Surg Oral Med Oral Pathol Oral Radiol Endod*. 2008;105:194-201.
- Solomides CC, Miller AS, Christman RA, Talwar J, Simpkins H. Lymphomas of the oral cavity: histology, immunologic type, and incidence of Epstein-Barr virus infection. *Hum Pathol*. 2002;33:153-157.
- Rayess HM, Nissan M, Gupta A, Carron MA, Raza SN, Fribley AM. Oropharyngeal lymphoma: a US population based analysis. *Oral Oncol*. 2017;73:147-151.
- Dreyling M, Ghielmini M, Rule S, Salles G, Vitolo U, Ladetto M. Newly diagnosed and relapsed follicular lymphoma: ESMO clinical practice guidelines for diagnosis, treatment and follow-up. *Ann Oncol*. 2016;27:v83-v90.
- Choi SM, Betz BL, Perry AM. Follicular lymphoma diagnostic caveats and updates. *Arch Pathol Lab Med*. 2018;142:1330-1340.
- Horn H, Kohler C, Witzig R, et al. Gene expression profiling reveals a close relationship between follicular lymphoma grade 3A and 3B, but distinct profiles of follicular lymphoma grade 1 and 2. *Haematologica*. 2018;103:1182-1190.
- Koster A, Tromp HA, Raemaekers JM, et al. The prognostic significance of the intra-follicular tumor cell proliferative rate in follicular lymphoma. *Haematologica*. 2007;92:184-190.
- Ryan MA, Cheng T, Yoo DS, Fisher SR. Pleomorphic mantle cell lymphoma of the tongue base presenting with dysphagia. *Clin Med Insights Ear Nose Throat*. 2019;12:1179550619831058.
- Pileri SA, Falini B. Mantle cell lymphoma. *Haematologica*. 2009;94:1488-1492.
- Kim DH, Medeiros LJ, Aung PP, Young KH, Miranda RN, Ok CY. Mantle cell lymphoma involving skin: a clinicopathologic study of 37 cases. *Am J Surg Pathol*. 2019;43:1421-1428.
- Lee W, Shin E, Kim BH, Kim H. Diagnostic accuracy of SOX11 immunohistochemistry in mantle cell lymphoma: a meta-analysis. *PLoS One*. 2019;14:e0225096.
- Tiemann M, Schrader C, Klapper W, et al. Histopathology, cell proliferation indices and clinical outcome in 304 patients with mantle cell lymphoma (MCL): a clinicopathological study from the European MCL Network. *Br J Haematol*. 2005;131:29-38.
- Jares P, Colomer D, Campo E. Genetic and molecular pathogenesis of mantle cell lymphoma: perspectives for new targeted therapeutics. *Nat Rev Cancer*. 2007;7:750-762.
- Jain P, Wang M. Mantle cell lymphoma: 2019 update on the diagnosis, pathogenesis, prognostication, and management. *Am J Hematol*. 2019;94:710-725.
- Wolvius EB, van der Valk P, van der Wal JE, et al. Primary non-Hodgkin's lymphoma of the salivary glands. An analysis of 22 cases. *J Oral Pathol Med*. 1996;25:177-181.
- Juárez-Salcedo LM, Sokol L, Chavez JC, Dalia S. Primary gastric lymphoma, epidemiology, clinical diagnosis, and treatment. *Cancer Control*. 2018;25:1073274818778256.
- Jamal B. Treatment of parotid non-hodgkin lymphoma: a meta-analysis. *J Glob Oncol*. 2018;4:1-6.
- Ellis GL. Lymphoid lesions of salivary glands: malignant and benign. *Med Oral Patol Oral Cir Bucal*. 2007;12:E479-E485.
- Bacon CM, Du MQ, Dogan A. Mucosa-associated lymphoid tissue (MALT) lymphoma: a practical guide for pathologists. *J Clin Pathol*. 2007;60:361-372.
- Biasi D, Caramaschi P, Ambrosetti A, et al. Mucosa-associated lymphoid tissue lymphoma of the salivary glands occurring in patients affected by Sjögren's syndrome: report of 6 cases. *Acta Haematol*. 2001;105:83-88.
- Gabali A, Ross CW, Edwards PC, Schnitzer B, Danciu TE. Pediatric extranodal marginal zone B-cell lymphoma presenting as amyloidosis in minor salivary glands: a case report and review of the literature. *J Pediatr Hematol Oncol*. 2013;35:e130-e133.
- Jaffe ES. Lymphoid lesions of the head and neck: a model of lymphocyte homing and lymphomagenesis. *Mod Pathol*. 2002;15:255-263.

34. Quintana PG, Kapadia SB, Bahler DW, Johnson JT, Swerdlow SH. Salivary gland lymphoid infiltrates associated with lymphoepithelial lesions: a clinicopathologic, immunophenotypic, and genotypic study. *Hum Pathol*. 1997;28:850-861.
35. Bianco L, Solla SD, Parvis G, et al. Low-dose radiotherapy for extranodal marginal zone B lymphoma of the lip: case report and literature review. *Hematol Oncol Stem Cell Ther*. 2021;14:76-81.
36. Zotti F, Fior A, Lonardi F, Albanese M, Nocini R, Capocasale G. Oral MALT Lymphoma: something to remember. *Oral Oncol*. 2020;103:104564.
37. Alunno A, Leone MC, Giacomelli R, Gerli R, Carubbi F. Lymphoma and lymphomagenesis in primary Sjögren's syndrome. *Front Med*. 2018;5:102.
38. Ratterman M, Kruczek K, Sulo S, Shanafelt TD, Kay NE, Nabhan C. Extramedullary chronic lymphocytic leukemia: systematic analysis of cases reported between 1975 and 2012. *Leuk Res*. 2014;38:299-303.
39. Theofilou VI, Katsoulas N, Tosios KI, Sklavounou A, Nikitakis NG. Richter transformation in the oral and maxillofacial area: report of 2 cases and literature review. *Oral Surg Oral Med Oral Pathol Oral Radiol*. 2021;131:e14-e20.
40. Rao DS, Said JW. Small lymphoid proliferations in extranodal locations. *Arch Pathol Lab Med*. 2007;131:383-396.
41. Gupta D, Lim MS, Medeiros LJ, Elenitoba-Johnson KS. Small lymphocytic lymphoma with perifollicular, marginal zone, or interfollicular distribution. *Mod Pathol*. 2000;13:1161-1166.
42. Peters SM, Han C, Yoon AJ, Philipone EM. Chronic lymphocytic leukemia in association with a ranula: a report and review of the literature. *Oral Surg Oral Med Oral Pathol Oral Radiol*. 2017;123:e160-e163.
43. Rosado P, Fernández S, Junquera L, De Vicente JC. Synchronous squamous cell carcinoma and chronic lymphocytic leukemia of the palate. *J Craniofac Surg*. 2011;22:348-350.
44. Alessandrini M, Micarelli A, Mugnaini F, Padova A, Pavone I, Bruno E. Unusual case of oral chronic lymphocytic leukemia presenting as recurrent epistaxis and asymptomatic intraoral swelling. *Rev Stomatol Chir Maxillofac*. 2012;113:455-457.

SUPPORTING INFORMATION

Additional supporting information may be found online in the Supporting Information section.

How to cite this article: Wagner VP, Rodrigues-Fernandes CI, Carvalho MVR, et al. Mantle cell lymphoma, malt lymphoma, small lymphocytic lymphoma, and follicular lymphoma of the oral cavity: An update. *J Oral Pathol Med*. 2021;50:622-630. <https://doi.org/10.1111/jop.13214>