

# **The prevalence of intra-tumoral and distant thrombi, as well as tumor-cell emboli in canine neoplasia**

Paolo Pazzi<sup>1,\*</sup>, Anri Celliers<sup>1</sup>, Elizabeth C. du Plessis<sup>2</sup>, Annemarie T. Kristensen<sup>3</sup>,  
Amelia Goddard<sup>1</sup>

<sup>1</sup>Department of Companion Animal Clinical Studies, Faculty of Veterinary Science,  
University of Pretoria, Pretoria, South Africa

<sup>2</sup>Division of Pathology, IDEXX Laboratories, Kyalami, South Africa

<sup>3</sup>Department of Veterinary Clinical Sciences, Faculty of Health and Medical Sciences,  
University of Copenhagen, Copenhagen, Denmark

\*Correspondence to Paolo Pazzi, Department of Companion Animal Clinical Studies, Faculty  
of Veterinary Science, University of Pretoria, Pretoria 0110, South Africa. Email:  
paolo.pazzi@up.ac.za

## **Disclaimers**

None

## **Funding**

The author(s) received no financial support for the research, authorship, and/or  
publication of this article.

## **Conflicting Interests**

The author(s) declared no potential conflicts of interest with respect to the research,  
authorship, and/or publication of this article.

## **Data availability statement**

The data that support the findings of this study are available from the corresponding  
author upon reasonable request.

## **Abstract**

Macroscopic thromboembolic disease has been associated with canine neoplasia, whereas prevalence studies of concurrent microthrombi and tumor-cell emboli are lacking.

This retrospective study investigated microthrombi and tumor cell emboli by reviewing pathology records of dogs diagnosed with lymphoma, sarcoma, carcinoma and mast cell tumors with a concurrent description of thrombi or emboli. Pathology reports and medical records of cases with either tumor biopsies and/or post mortems with a diagnosis of neoplasia were reviewed for the presence of microthrombi, macrothrombi and/or tumor-cell emboli and the association with tumor type.

Of the 28895 canine cases in the database, 21252 (73.5%) were antemortem biopsy specimens and 7643 were post mortems (26.5%); 2274 solid tumors were identified, 2107 (92.7%) were antemortem biopsy diagnoses and 167 (7.3%) were post mortem diagnoses. The prevalence of solid tumor types in the database (28895 cases) was 872 (3.0%) lymphoma, 722 (2.5%) sarcoma, 455 (1.6%) carcinoma and 225 (0.8%) mast cell tumor. The prevalence of microthrombi associated with these tumors was 58/2274 (2.6%). Intra-tumoral microthrombi were reported in 53/2274 (2.3%) cases, the majority in sarcomas (37/53, 69.8%). No macrothrombi were reported. Tumor-cell emboli were identified in 39/2274 (1.7%) cases, 31/39 (79.5%) were extra-tumoral or distant emboli, and carcinoma the most commonly associated tumor (29/39; 74.4%).

Microthrombi were reported in 2.6% of cases, the majority in sarcomas and tumor-cell emboli were identified in 1.7% of cases, the majority carcinomas. Prospective investigations are necessary to explore the potential clinical and prognostic implications of microthrombi and tumor-cell emboli in canine neoplasia.

**Keywords:** cancer, emboli, metastasis, clot

## 1 Introduction

Thrombosis is the pathologic formation of a thrombus within blood vessels in tissues and organs. Parts of the formed thrombus may fragment, resulting in emboli circulating and lodging, leading to obstruction of blood flow at distant locations.

Thromboembolic disease is commonly reported as secondary to underlying illnesses.<sup>1</sup> In dogs, associated illnesses include immune-mediated hemolytic anemia, protein-losing diseases, neoplasia, infectious diseases and a combination of multiple concurrent diseases or factors.<sup>2,3</sup>

Approximately 10-15% of human cancer patients develop clinical evidence of thromboembolism, with fatal pulmonary embolism being three times more common in cancer patients than in patients without cancer.<sup>4-6</sup> Additionally, surgery, pregnancy, chemotherapy (including cisplatin, fluorouracil, L-asparaginase and corticosteroids), age and prolonged bed rest amongst others, have been shown to be risk factors for thrombosis in people.<sup>7,8</sup> In contrast, inflammation, protein-losing states, as well as excessive endogenous or exogenously administered corticosteroids, are more commonly recognised predisposing factors for thrombosis in dogs, while tumors are only associated with clinical macrothrombosis in a subset of dogs.<sup>9</sup> Tumors are common in dogs with incidence rates ranging from 310 to 958 cases per 100,000 dogs annually.<sup>10</sup> Approximately 16.5% of all deaths in dogs are attributed to neoplasia,<sup>11</sup> with the four most common canine solid tumor types being lymphoma, sarcoma, carcinoma and mast cell tumors.<sup>12</sup>

Microvascular thrombosis (microthrombi) are accumulations of fibrin and platelets into a thrombus-like structure within microscopic blood vessels that remain adherent to the blood vessel wall after tissue collection and processing and are only visible upon microscopic tissue evaluation. Vessel injury and dysregulation of the hemostatic and inflammatory pathways may result in microthrombus formation. If the initiating process is not eliminated or controlled, macrothrombosis may occur through a combination of events such as increased procoagulant elements, inhibition of anticoagulation mechanisms and inhibition of fibrinolysis.<sup>13,14</sup> The pathogenesis of cancer-associated coagulopathy is complex and involves tumor cell expression of procoagulant proteins including tissue factor, proangiogenic and growth stimulating factors, tumor neo-vascularization, shedding of procoagulant microparticles and inflammatory cytokines.<sup>15-18</sup> Microthrombi have been documented in tumor tissue of

dogs with gliomas (63%), meningiomas (66%) and mammary gland tumors (57%).<sup>19-</sup>  
<sup>21</sup> Experimentally induced pulmonary microthrombi have been reported to result in significant vascular injury and vessel permeability changes resulting in severe lung injury.<sup>22-24</sup> Microthrombi cannot be substantiated clinically as no single coagulation test is predicative for the detection of microthrombi.

Macroscopic thromboembolic disease (macrothrombi) of the pulmonary, portal and splenic vasculature as well as in the aorta and cranial vena cava has been associated with tumors in dogs.<sup>25-31</sup> Macrothrombi may be subclinical or result in clinical disease ranging from respiratory failure, cerebrovascular hypoxia or organ-associated failure dependant on the site of thromboembolic disease.<sup>5</sup> D-dimers have been identified as the most promising assay associated with the presence of macrothrombi, but a negative D-dimer is most commonly used to rule out thrombotic disease while other coagulation assays, including thromboelastography, have shown variable results.<sup>32-34</sup>

Tumor-cell emboli, defined as tumor cells in local tumor or distant blood vessels or lymphatics, is associated with a poorer prognosis in a number of canine cancers due to its association with metastasis.<sup>35-39</sup> Components of hemostasis, specifically the formation of platelet-tumor-cell emboli and subsequent local tissue hypoxia, play an essential role in metastasis, supporting the potential role of the detection of thrombi and tumor-cell emboli for the purpose of prognostication.<sup>40-43</sup>

The objectives of this retrospective study were to determine, within the study population, the prevalence of microthrombi, macrothrombi, and tumor-cell emboli reported in either tumor biopsy or post mortem reports in canine cancer patients with lymphoma, sarcoma, carcinoma and mast cell tumors; and determine the association of thrombosis and tumor-cell emboli with each tumor type. The findings of this study may contribute to our understanding of the pathogenesis of hemostatic disorders observed in canine cancer patients as well as our understanding of the role of thrombus formation and tumor-cell emboli in metastasis in dogs allowing initiation of early antithrombotic or chemotherapeutic intervention and potentially altering the course or duration of the disease process.

## 2 Materials and Methods

### 2.1 Case Selection

This retrospective descriptive cross-sectional study evaluated all canine tumor tissue samples submitted for antemortem histological examination (antemortem biopsy group) or post mortem (post mortem group), submitted to (\*removed for review) from September 2013 to April 2019. This study was approved by the (\*removed for review).

The (\*removed for review) pathology database was searched for keywords “lymphoma”, “sarcoma”, “carcinoma” and “mast cell tumour” to determine the number of cases in the case population. The identified case population was then searched using the keywords “thrombi”, “thrombosis”, “thrombus”, “emboli” and “embolic” to determine prevalence of thromboemboli in the case population. The term “infarction” was specifically not used for the case search as causes other than thromboembolic disease may result in infarction.

Cases were excluded if a keyword was mentioned in the pathology report but thromboembolic disease was not present or evident based on the report, or if there was insufficient information in the pathology report to determine the type of tissue submitted, disease process or final diagnosis for the case.

For cases matching the search criteria, microthrombi were defined as a mesh of cross-linked fibrin protein into a thrombus-like structure within microscopic blood vessels, with varying amounts of aggregated platelets, white blood cells and red blood cells, identified on histopathology of tissues examined. A blood clot would be washed away during tissue processing, while thrombi will not. Macrothrombi were defined as visible and palpable thrombi within macroscopically visible blood vessels identified during post mortem examination and confirmed on histopathology to be a mesh of cross-linked fibrin protein with varying amounts of aggregated platelets, white blood cells and red blood cells. Tumor-cell emboli were defined as the histological presence of neoplastic cells within the vasculature or lymphatic vessels of the tissues examined. The site of thrombi or tumor-cell emboli were defined as intra-tumoral if the thrombi or tumor-cell emboli were identified within the vasculature or lymphatic vessels of the tumor. Cases were identified as either antemortem biopsy samples or post mortem samples. For the antemortem biopsy and post mortem group, thrombi or tumor-cell emboli were classified as extra-tumoral if they

were identified in vasculature or lymphatic vessels draining the tumor within the same tumor biopsy sample submitted for histopathology. For the post mortem group, thrombi or tumor-cell emboli were classified as distant if they were identified in vasculature or lymphatic vessels in an organ apart from the primary tumor during the post mortem examination or histopathology evaluation of biopsy samples.

All antemortem biopsy samples and samples for histopathology from the post mortem group were placed in 10% buffered formalin, underwent standard haematoxylin and eosin (H&E) staining, and were evaluated by board-certified pathologists. All post mortems were performed or supervised by a board-certified pathologist. The tissues selected for histological evaluation by the pathologist in the post mortem group were dependant on case-specifics and were pathologist-dependant. Board-certified pathologists signed off on the pathology reports for all cases.

The pathology report for each identified case was comprehensively reviewed (by authors PP and AC) for the signalment of the dogs; presence of intra-tumoral, extra-tumoral or distant microthrombi, macrothrombi or tumor-cell emboli; presence of necrosis associated with microthrombi; final diagnosis; and the presence of macroscopically visible metastasis to the draining lymph node or distant organs (confirmed on histopathology) .

Comorbidities were identified from the post mortem report, and where available, medical records. Comorbidities were defined as any concurrent disease processes or conditions that were not the reason for submission of biopsy samples or the reason for euthanasia or death.

The medical records, where available, were reviewed to identify temporal therapeutic interventions known to interfere with hemostasis or contribute to thrombus formation (i.e. heparin, non-steroidal anti-inflammatory drugs, anti-platelet drugs, colloids, blood products, warfarin, corticosteroids, chemotherapeutics and Vitamin K<sub>1</sub>).<sup>44-48</sup>

## **2.2 Data Analysis**

Statistical analysis was performed using a commercial software package (SPSS Statistics version 25, IBM, New York, USA). From the canine pathology database, the percentage biopsy samples and the percentage post mortem samples were determined. The numbers of lymphoma, sarcoma, carcinoma and mast cell tumor

cases were determined and defined as the case population. The percentage of the antemortem biopsies and post mortems was calculated and compared for the solid tumor cases. The prevalence of diagnosis was calculated as the total number of cases of a solid tumor type identified in the pathology database divided by the total number of canine cases in the pathology database. Overall prevalence, and prevalence for intra-tumoral-, extra-tumoral- and distant microthrombi, macrothrombi or tumor-cell emboli were calculated for all solid tumors and each tumor type. Prevalence, in the context of this study, refers specifically to the case population used for this study, unless stated otherwise.

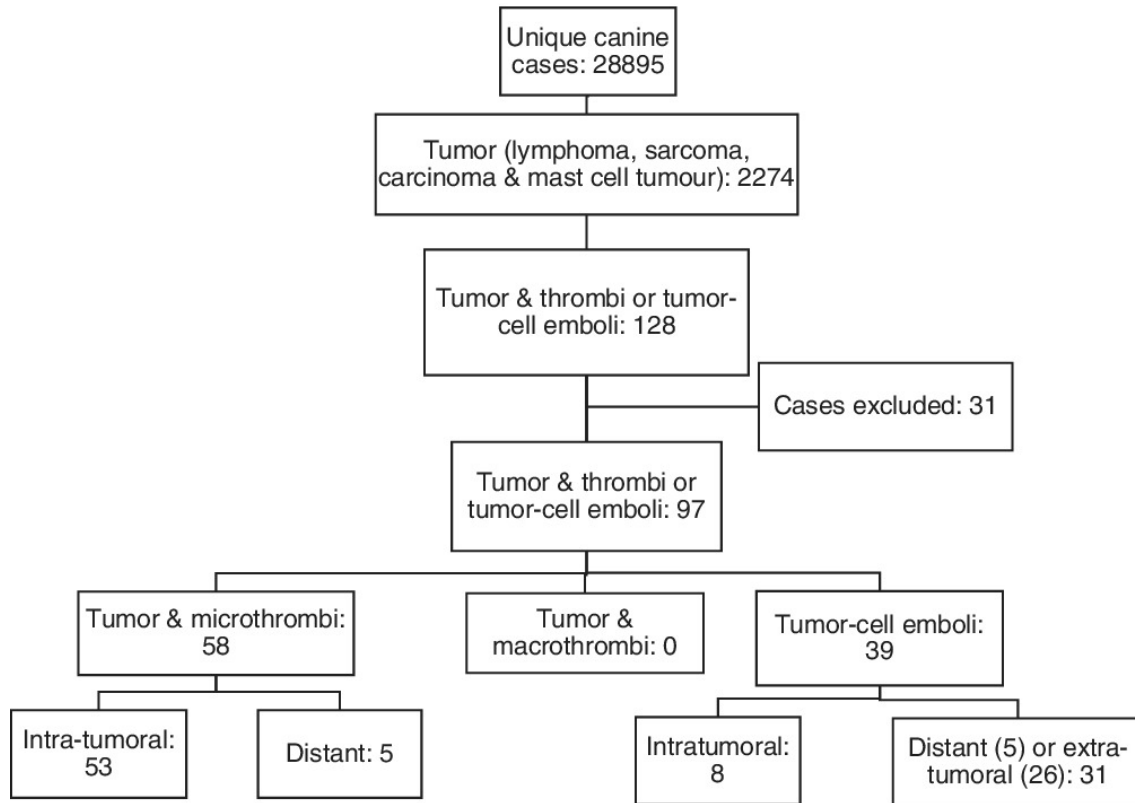
In addition, the following was calculated for the case population: 1) median age, sex distribution and breed for cases with microthrombi, macrothrombi and tumor-cell emboli; 2) frequency of association for each tumor type with microthrombi, macrothrombi or tumor-cell emboli. The latter was calculated as the total number of each solid tumor type with presence of microthrombi, macrothrombi and/or tumor-cell emboli divided by the total number of each type of tumor type in the database; 3) percentage of cases with necrosis and its association with microthrombi and tumor type; and 4) comorbidities and therapeutic interventions associated with the solid tumor-related microthrombi and macrothrombi.

### **3 Results**

#### **3.1 Study population**

The database yielded 28895 submitted unique canine antemortem biopsy or post mortem diagnoses of which 21252 (73.5%) were tissue antemortem biopsy samples and 7643 (26.5%) were post mortem tissue samples.

Of the 28895 cases, the keyword “lymphoma”, “sarcoma”, “carcinoma” and “mast cell tumour”, was identified in a total of 2274 cases (Figure 1). Of the 2274 cases, 2107 (92.7%) were antemortem biopsy diagnoses and 167 (7.3%) were post mortem tissue diagnoses. The prevalence of diagnosis of the specific solid tumor type in all retrieved tumor tissue samples (28895) was 872 (3.0%) for lymphoma, 722 (2.5%) for sarcoma, 455 (1.6%) for carcinoma and 225 (0.8%) for mast cell tumor.



**Figure 1.** The sequence of selection of cases and case numbers for each category of thrombi and tumour-cell emboli

Of the total 2274 solid tumor cases identified, 128 satisfied the additional inclusion criteria of one or more of the following keywords in the pathology report “thrombi”, “thrombosis”, “thrombus”, “emboli” or “embolic”. Thirty one of the 128 cases were excluded for one of the following reasons: keyword of thrombi or emboli mentioned in the pathology report but thrombi or emboli were not identified during post mortem or histopathological examination (27) and insufficient information in the pathology report (4) leaving a total of 97 cases for analysis.

### 3.2 Microthrombi

Of the 97 solid tumor cases, concurrent microthrombi were identified in 58 solid tumor tissue samples, with an overall prevalence of 58/2274 (2.6%); 53/2274 (2.3%) intra-tumoral and 5/2274 (0.2%) distant.

Of the 58 solid tumor tissue samples with identified microthrombi, 49 (84.5%) were identified in antemortem biopsy samples. The prevalence of solid tumors with microthrombi in the solid tumor antemortem biopsy group was 49/2107 (2.3%).



Nine of the 58 solid tissue samples (15.5%) were from samples collected during post mortem. The prevalence of solid tumors with microthrombi in the solid tumor post mortem group was 9/167 (5.4%). The prevalence of solid tumor samples with microthrombi identified in the post mortem group was 2.3 times more than in the antemortem biopsy group. Distant thrombi made up 5/9 (55.6%) of the microthrombi in the post mortem group. The median age, sex distribution and breeds of the dogs in the case population associated with concurrent microthrombi can be found in Table 1.

**Table 1.** Signalment of dogs with tumors associated with microthrombi or tumor-cell emboli.

	<b>Median age (IQR) in years</b>	<b>Sex</b>	<b>Breeds</b>
Tumor and concurrent microthrombi	9 (7-12), N = 43	FS: 17, FI: 7, MN: 11, MI: 8	Total of 24 breeds: Labrador retriever (5), Boerboel (4), Jack Russel Terrier (4), Dachshund (4), mixed breed (3), Border collie (2), Pug (2), Golden Retriever (2), Basset (2), German shepherd (2) and 1 each of American Pitbull terrier, Boxer, Sharpei, Rottweiler, Belgian Malinois, Doberman, Maltese poodle, Long haired dachshund, Fox terrier, Irish wolfhound, Italian greyhound, Huskey, Chihuahua, Scottish terrier
Tumor-cell emboli	10 (7-12), N = 34	FS: 14, FI: 11, MN: 4, MI: 5	Total of 25 breeds: Boerboel (3), Boxer (2), Labrador retriever (2), Maltese poodle (2), Jack Russel terrier (2), German shepherd (2), Border collie (2), Rottweiler (2) and one each of American Staffordshire Terrier, Staffordshire bull terrier, American Pitbull terrier, Wire haired Fox Terrier, Bullmastiff, Cardigan Corgi, Dachshund, Bull terrier, Australian cattle dog, Sharpei, Yorkshire terrier, Golden Retriever, Basset, Standard Poodle, Boston terrier, Miniature pinscher, Spaniel

N: number of dogs with available information; FS: female sterilised; FI: female intact; MN: male neutered; MI: male intact

Intra-tumoral microthrombi (53/58, 91.4%) were predominantly associated with sarcomas (37/53; 69.8%), followed by carcinomas (8/53; 15.1%) and lymphoma (8/53; 15.1%); intra-tumoral microthrombi were not associated with mast cell tumors (Table 2). Hemangiosarcoma in various locations (24/37; 64.9%) made up the majority of the sarcomas with intra-tumoral microthrombi.

**Table 2.** Category of tumor and specific tumor associated with intra-tumoral microthrombi.

Category of tumor	Tumor
Sarcoma (37)	Cutaneous hemangiosarcoma (16)
	Splenic or hepatic hemangiosarcoma (4)
	Right atrial hemangiosarcoma (2)
	Appendicular skeletal osteosarcoma (2)
	Anaplastic sarcoma (2)
	Renal hemangiosarcoma (1)
	<i>S. lupi</i> oesophageal osteosarcoma (1)
	Extra-skeletal osteosarcoma (1)
	Nasal chondrosarcoma (1)
	Oral hemangiosarcoma (1)
	Oral sarcoma (1)
	Intestinal leiomyosarcoma (1)
	Vaginal leiomyosarcoma (1)
	Oral histiocytic sarcoma (1)
	Cutaneous soft tissue sarcoma (1)
	Soft tissue sarcoma (1)
Carcinoma (8)	Mammary carcinoma (2)
	Nasal carcinoma (1), adenocarcinoma (1)
	Thyroid adenocarcinoma (1)
	Hepatocellular carcinoma (1)
	Transitional cell carcinoma (1)
	Anorectal adenocarcinoma (1)
Lymphoma (8)	Indolent B cell lymphoma (3)
	B cell lymphoma (2)
	T cell lymphoma (1)
	Indolent T zone lymphoma (1)
	Small cell lymphoma (1)

From the post-mortem group, distant sites of microthrombi included the lungs (2), splenic vasculature (1), lymphatics (1) and nasal turbinates (1). Sarcomas accounted for 3/5 (60%) of distant microthrombi in solid tumor cases (Table 3). No extra-tumoral microthrombi were identified in the antemortem biopsy or post mortem groups. Considering the sample prevalence, the frequency of association of all (intra-

tumoral and distant) microthrombi with sarcoma, carcinoma, lymphoma and mast cell tumor was 40/722 (5.5%), 9/455 (2.0%), 8/872 (0.9%) and 1/225 (0.4%) respectively.

**Table 3.** Site of distant microthrombi and the associated tumor.

Site of distant microthrombi	Tumor
Spleen (2)	Osteosarcoma Mammary haemangiosarcoma
Lung (1)	Colonic sarcoma
Nasal turbinates (1)	Renal carcinoma
Lymphatics (1)	Mast cell tumor

Necrosis of the tumor with associated microthrombi was reported in 23/58 (39.7%) of cases. Sarcomas were primarily associated with necrosis and microthrombi 16/23 (69.6%), followed by carcinoma 4/23 (17.4%) and lymphoma 3/23 (13.0%).

Of the 58 cases with tumor-associated microthrombi, information regarding comorbidities was available in 36/58 (62.1%) of cases. Of these cases, specific comorbidities were identified in 24/36 cases (66.7%) (Table 4). Nineteen of the twenty-four cases (79.2%) with comorbidities identified were in the sarcoma group. Three of the 24 (12.5%) cases with a comorbidity had distant thrombi.

Information on temporal therapeutic interventions was available in 32/58 (55.2%) cases. Seventeen of these cases had received therapeutic interventions at the point of biopsy or prior to death, of which 10 (31.3%) received therapeutics known to interfere with hemostasis, none received anti-cancer therapy (Supplemental Table 1). The majority of cases, 22/32 (69%), did not receive therapeutics known to interfere with hemostasis. Two of the 10 cases with a therapeutic intervention known to interfere with hemostasis had distant thrombi.

Of the 58 cases with microthrombi and for which information regarding comorbidities were known (36), a combination of more than one factor (comorbidity, therapeutic intervention and/or the presence of necrosis associated with the tumor) was identified 15/36 (41.7%) cases.

**Table 4.** Comorbidities identified in dogs with tumors and microthrombi.

\*Cases with a comorbidity and distant microthrombi

<b>Comorbidity</b>	<b>Primary tumor (submitted sample)</b>
<b>Neoplastic</b>	
Peri-anal gland carcinoma	Cutaneous haemangiosarcoma
Oral melanoma	Cutaneous haemangiosarcoma
Dermal malignant melanoma	Cutaneous haemangiosarcoma
Cutaneous mast cell tumor	Cutaneous haemangiosarcoma
Cutaneous melanoma and squamous cell carcinoma	Cutaneous haemangiosarcoma
Cutaneous vascular hamartoma	Anorectal adenocarcinoma
Right atrial mass	Hepatic haemangiosarcoma
<b>Inflammatory</b>	
Immune mediated haemolytic anaemia	Appendicular skeletal osteosarcoma*
Chronic non-healing wound on paw with osteomyelitis	Appendicular skeletal osteosarcoma
Intussusception	Intestinal leiomyosarcoma
Pyometra	Mammary carcinoma
Septic peritonitis	Bladder transitional cell carcinoma
<b>Cardiac</b>	
Stage B1 myxomatous mitral valve disease	Vaginal leiomyosarcoma
Myxomatous mitral valve disease (unstaged)	Cutaneous haemangiosarcoma
<b>Renal</b>	
Acute kidney injury	Colonic sarcoma*
<b>Combination of comorbidities</b>	
Hyperthyroid & hypertensive	Follicular thyroid adenocarcinoma
Anaemia	Cutaneous haemangiosarcoma
Previously diagnosed cardiac disease & chronic bronchitis & renal insufficiency	Renal haemangiosarcoma
Stage C myxomatous mitral valve disease, uveitis	Cutaneous haemangiosarcoma
Stage B2 myxomatous mitral valve disease, abscess at tumor site	Soft-tissue sarcoma
Stage B2 myxomatous mitral valve disease, marked haemorrhage around tumor	Anaplastic haemangiosarcoma of inguinal/mammary region*
<b>Miscellaneous</b>	
Haemabdomen	Splenic haemangiosarcoma
Haemoperitoneum and ancylostomiasis	Hepatocellular carcinoma
Pericardial effusion	Right atrial haemangiosarcoma

### **3.3 Macrothrombi**

No macrothrombi were described in any of the antemortem biopsy or post mortem tissue samples in any of the cases diagnosed with sarcoma, carcinoma, lymphoma or mast cell tumor.

### **3.4 Tumor-cell emboli**

Tumor-cell emboli were identified in 39 tissue samples with a prevalence in the solid tumor cases of 39/2274 (1.7%); 8/39 (20.5%) were intra-tumoral and 31/39 (79.5%) were either extra-tumoral (26/31, 83.9%) or distant (5/31, 16.1%) tumor-cell emboli.

Of the 39 samples with emboli, 30 (76.9%) were from the antemortem biopsy samples. The prevalence of tumor-cell emboli in the solid tumor antemortem biopsy group was 30/2107 (1.4%).

Nine of the 39 samples (23.1%) were from the samples collected during post mortem. The prevalence of solid tumors with tumor-cell emboli in the solid tumor post mortem group was 9/167 (5.4%). The prevalence of tumor-cell emboli identified in the post mortem group was 3.8 times more than in the antemortem biopsy group.

The draining lymphatics were the most common site of extra-tumoral cell emboli (24/31; 77.4%), followed by the draining vasculature (2/31; 6.5%). Distant sites of tumor-cell emboli included lung (5/31; 16.1%), with one of the five with additional tumor-cell emboli identified in the kidney. Of the nine post mortem cases with tumor-cell emboli, seven (77.8%) were identified with macroscopically visible metastasis in the draining lymph node or a distant organ (Table 5). The median age, sex distribution and breeds associated with tumor-cell emboli can be found in Table 1.

Tumor-cell emboli were predominantly associated with various carcinomas (29/39; 74.4%), followed by sarcoma (8/39; 20.5%), lymphoma (1/39; 2.6%) and mast cell tumor (1/39; 2.6%) (Table 5). Considering the sample prevalence, the frequency of tumor-cell emboli associated with carcinoma was 29/455 (6.4%), 8/722 (1.1%) for sarcoma, 1/872 (0.1%) for lymphoma and 1/225 (0.4%) for mast cell tumor.

**Table 5.** Category of tumor, and specific tumor identified with tumor-cell emboli.

Category of tumor	Tumor
Carcinoma (29)	Mammary carcinoma (9)
	Thyroid carcinoma (4)
	Bronchial carcinoma** (2)
	Transitional cell carcinoma (2)
	Nasal carcinoma (1)
	Pulmonary carcinoma* (1)
	Prostatic carcinoma (1)
	Squamous cell carcinoma (1)
	Hepatocellular carcinoma (1)
	Intestinal adenocarcinoma (1)
	Large intestinal adenocarcinoma* (1)
	Anorectal carcinoma (1)
	Comedo-carcinoma (1)
	Apocrine ductular adenocarcinoma (1)
	Spindle cell carcinoma (1)
	Sweat gland adenocarcinoma* (1)
Sarcoma (8)	<i>S. lupi</i> oesophageal osteosarcoma** (2)
	Haemangiosarcoma (bone) (1)
	Right Atrial haemangiosarcoma* (1)
	Cutaneous anaplastic sarcoma (1)
	Oral (maxilla) osteosarcoma (1)
	Botyroid rhabdomyosarcoma (1)
	Histiocytic sarcoma (1)
Mast cell tumor (1)	Cutaneous mast cell tumor (1)
Lymphoma (1)	B cell lymphoma (1)

\*Cases in the post mortem group with macroscopically visible metastasis (each \* represents one case).

## 4 Discussion

The overall prevalence of microthrombi in antemortem and post mortem tissue samples from dogs with the solid tumors sarcoma, carcinoma, lymphoma and mast cell tumor in this retrospective study of a pathology database was 2.6%. The majority were intra-tumoral microthrombi (91%) and were predominantly seen in sarcomas. The prevalence of tumor-cell emboli was 1.7% with draining lymphatics the most common site, and carcinomas the predominantly associated solid tumor type. Interestingly, macrothrombi were not identified in any of the solid tumor cases in this study.

Microthrombi are important in the pathogenesis of macrothrombi and cancer metastasis and may result in significant clinical complications. Studies on

experimentally induced pulmonary microthrombi in dogs have reported a significant drop in circulating platelet concentration with increased neutrophils and platelets within the pulmonary capillaries, increased mean pulmonary artery pressure and emboli-related arterial dilation, increased microvascular permeability to protein and severe lung injury.<sup>22-24</sup> In addition, microthrombi and tumor-cell emboli have been reported to result in localized ischemia and tissue hypoxia, both of which are directly linked to cancer metastasis through hypoxia-inducible factor target gene expression, inhibition of the transmembrane molecule E-cadherin, enhanced proteolytic activity at the tumor invasive front and increased cell motility towards the blood or lymphatic microcirculation.<sup>40,42,49</sup>

No prevalence studies of microthrombi in canine solid tumors have previously been reported, making results of this study difficult to compare, but the true prevalence is likely higher than the 2.6% reported here. Antemortem biopsy samples made up 73.5% of the case cohort evaluated, this group only represented samples from a single mass or organs without evaluation of the rest of the body that might have harbored microthrombi. Furthermore, the cases in the post mortem group would not have had histopathological examination of all the organs, and microthrombi are likely to have been missed. Five of the nine identified microthrombi in the post mortem group were from sites distant to the solid tumor indicating histological evaluation of all the organs is likely to have yielded a higher prevalence of microthrombi. Additional factors that may have resulted in a lower than expected prevalence are due to the low sensitivity of a retrospective study that did not allow for timely and standardized post mortem examination, multiple sections of histopathology samples were not evaluated and the lack of immunohistochemical staining with anti-CD61 and anti-fibrin antibodies.<sup>50</sup>

The prevalence of microthrombi identified in post mortem submissions in dogs with solid tumors was 2.3 times higher than in the antemortem biopsy samples. This was an unexpected finding. A higher prevalence of microthrombi in the antemortem biopsy group was expected based on the high prevalence of intra-tumoral thrombi identified in this study and the higher proportion of antemortem biopsy cases. Additionally, antemortem biopsy samples were most likely immediately placed in 10% buffered formalin preventing thrombi dissolution, while thrombi in post mortem cases are likely to have undergone rapid dissolution in the hours leading up to post mortem. In a previous canine study only 36% of the original volume of pulmonary

thromboemboli was recovered six hours after being artificially induced.<sup>51</sup> The low number of cases in the post mortem group, together with the identification of distant microthrombi are likely to have contributed to this unexpected finding. A prospective study with complete post mortem examination within 1-2 hours of death, evaluating all the organs of solid tumor cases would be required to determine the true prevalence of microthrombi. Early detection assays including D-dimers and thromboelastography may be useful in the clinical diagnosis of microthrombi and requires further investigation.

In this study, 91% of solid tumor associated microthrombi were intra-tumoral. Sarcomas were over-represented (69.8%) of which hemangiosarcomas represented the majority (65%). Hemangiosarcomas are reportedly associated with hemostatic dysfunction and thrombo-embolic disease.<sup>52,53</sup> Other solid tumors that have also been associated with haemostatic dysfunction includes carcinomas and lymphomas.<sup>53,54</sup> The blood pooling in a disorganized vasculature, procoagulant factor expression on the tumor vessel wall, altered blood flow within the neoplasm and a pro-inflammatory state of the affected endothelium within the neoplasm,<sup>55-59</sup> may result in upregulation of the hemostasis pathways and the subsequent development of a hypercoagulable state, likely resulting in intra-tumoral thrombi.<sup>20,27,36</sup> Intra-tumoral thrombosis can result in compromised blood flow, ischemia, and ultimately necrosis. Necrosis of the primary neoplasia is commonly associated with sarcomas, as seen in 70% of the dogs identified with microthrombi and necrosis in this study. Necrosis is thought to result due to a combination of disorganized vasculature, rapid growth with insufficient vascular supply, high internal pressures and the presence of microthrombi.<sup>60,61</sup> The severity of necrosis forms part of the grading system for sarcomas and the presence of necrosis contributes to prognostication.<sup>62,63</sup> In some solid tumors, the hypercoagulable state, microthrombi formation and necrosis may contribute to the eventual development of disseminated intravascular coagulation in some dogs.<sup>52,53</sup>

Distant thrombi and fibrin deposits have previously been described in 15 of 28 dogs with mammary tumors and a single thrombus was detected in one mammary adenoma.<sup>21</sup> Distant microthrombi were identified in four sites from five different solid tumors in our study. Interestingly, the prevalence of distant microthrombi in the current study (0.2%) is surprisingly low considering 10-20% of human cancer patients show clinical or post mortem evidence of thromboembolic disease.<sup>6,64</sup> This



may be explained by the majority of cases being antemortem biopsies without the availability of additional samples from distant sites that may have contained distant microthrombi. In a human study, carcinomas were identified as the most common tumors associated with pulmonary thromboemboli, and is most likely related to 90% of all human cancers being carcinomas.<sup>65,66</sup> Sarcomas accounted for 60% of distant microthrombi in solid tumor cases in our study while the overall frequency of association of microthrombi with sarcoma was 5.5%, but the number of distant cases of microthrombi were too low to draw any conclusions. As previously discussed, the true prevalence of distant microthrombi is likely to be higher.

Information regarding comorbidities was available in 62% of the cases and interestingly comorbidities were identified in 67% of these cases with cancer-associated microthrombi. Of these, 12.5% had distant thrombi. Seventy nine percent of identified comorbidities were in the sarcoma group and may have contributed to a higher prevalence of microthrombi in that group. Cancer, inflammatory and renal-related diseases, common comorbidities identified in this study, have been shown to result in hypercoagulable states in dogs, and the greater the number and severity of comorbidities, the higher the likelihood of hemostatic alterations.<sup>9,54,67,68</sup> The comorbidities in this study were not the reason for submission of the antemortem biopsy samples or for euthanasia or death in the post mortem group, and in some cases the comorbidities were a sequela of the primary solid tumor. Information regarding the clinical significance or severity of some of the comorbidities identified was not reliably available and their likely contribution to microthrombi formation in this study could not be accurately determined.

Previous studies have shown that up to 72% of dogs with thrombi have more than one disease process contributing to thrombus formation.<sup>25,30</sup> This is also reflected in our study where 42% of cases had more than one factor (comorbidity, therapeutic intervention known to interfere with hemostasis or tumor-related necrosis), besides the primary tumor, contributing to thrombus formation. This finding supports the suggestion that one or a combination of factors such as local tumor environment, systemic hypercoagulability, necrosis of the tumor, presence of comorbidities and treatment may contribute to thrombus formation. Information regarding therapeutic interventions was available in 55% of cases, of which 31% of dogs received at least one intervention known to interfere with hemostasis. Unfortunately, in most of the cases, due to the retrospective nature of the study, the

temporal association of the therapeutic intervention and thrombus formation is unknown, preventing a tentative connection between treatment and thrombus formation.

Surprisingly, macrothrombi were not associated with solid tumors in this study and may be related to the lack of focused evaluation of all blood vessels during a standard post mortem, fewer post mortems compared to antemortem biopsy samples in this study, as well as rapid dissolution of thrombi in the post mortem group.<sup>53</sup> Although previous reports of tumor-associated macrothrombi exist,<sup>24,27-29,41,42,53</sup> based on the current study, the prevalence of macrothrombi in dogs with solid tumors may be very low. Systematic prospective studies, specifically evaluating predilection sites for macrothrombi in dogs with solid tumors is required.

The majority of tumor-cell emboli were within the draining lymphatic vessels and by extension would imply draining lymph node involvement. Dogs with metastasis to regional lymph nodes have been shown to have shorter survival times in mammary tumors, osteosarcoma, oral and facial tumors and primary lung tumors, amongst others.<sup>35-39</sup> Micro metastasis refers to the systemic spread of small numbers of tumor cells, too few to be detected by standard screening tests, and is thought to be largely responsible for metastatic disease in patients originally diagnosed as node negative.<sup>43</sup> The identification of tumor-cell emboli within vasculature or lymphatic vessels does not necessarily mean that the embolus will lodge, survive and result in a metastatic tumor.<sup>69</sup> Interestingly, 78% of post mortem cases with tumor-cell emboli had concurrent macroscopically visible metastasis, but due to the small sample size further studies are required to support this finding. The metastatic incidence in the biopsy group could not be determined because the biopsy cases did not have consistent cancer staging.

Tumor-cell emboli were identified 3.8 times more in the post mortem group than the antemortem biopsy group. The true prevalence of tumor-cell emboli is likely underestimated in this study due to the higher proportion of antemortem biopsy samples for which draining lymphatics are not routinely submitted with the biopsy sample. In addition, not all organs underwent histological examination for the post mortem group and routine H&E staining has been shown to only detect between 65-90% of micro metastasis that were identified with cytokeratin AE1/AE3 or pancytokeratin (panCK) immunohistochemistry.<sup>6,9</sup> Further systematic prospective studies utilising immunohistochemistry, evaluating draining lymphatics as well as

histological examination of all organs are necessary to identify the true prevalence of tumor-cell emboli in tissues.

Carcinomas made up 74% of solid tumor cases with tumor-cell emboli in this study. Although each tumor has its own metastatic potential, generally, carcinomas have a greater potential to spread via the lymphatics, while sarcomas tend to spread via the hematogenous route.<sup>12</sup> This was evidenced in our study with the majority of tumor-cell emboli in draining lymphatics and the frequency of association of tumor-cell emboli in carcinomas of 6.3% and 1.1% for sarcomas, respectively.

In addition to the limitations already mentioned, the microthrombi from the antemortem biopsy group could not be correlated to the presence of systemic microthrombi. The definition and reporting of microthrombi or tumor-cell emboli as well as necrosis would have been dependent on the pathologist and may not have been reported consistently. Information regarding comorbidities and therapeutic intervention was available in the majority of cases, but not all cases. Despite the lack of historic or clinical information in 22 cases, excluding these cases would not give an accurate representation of the prevalence of microthrombi in dogs with tumors and more closely reflects the clinical scenario. Additionally, reasonable conclusions can be made from the majority of cases with microthrombi, for which information was available.

In conclusion, this retrospective descriptive review of antemortem and post mortem tissue samples highlights the prevalence of both microthrombi and tumor-cell emboli in common solid tumors in dogs. The majority of microthrombi were intratumoral and were predominantly seen in sarcomas. The most common site of tumor-cell emboli were the draining lymphatics, and carcinomas the predominantly associated solid tumor type. Prospective clinical studies, supported by full post mortem evaluations are required to determine the true prevalence, as well as the clinical and prognostic significance of thrombi and tumor-cell emboli in canine tumor patients.

## References

1. Winter RL, Sedacca CD, Adams A, Orton EC. Aortic thrombosis in dogs: presentation, therapy, and outcome in 26 cases. *J Vet Cardiol.* 2012;14(2):333-342.
2. de Laforcade A. Diseases associated with thrombosis. *Top Companion Anim M.* 2012;27(2):59-64.

3. Williams TP, Shaw S, Porter A, Berkwitz L. Aortic thrombosis in dogs. *J Vet Emerg Crit Car.* 2017;27(1):9-22.
4. Heit JA, O'Fallon WM, Petterson TM, et al. Relative impact of risk factors for deep vein thrombosis and pulmonary embolism: a population-based study. *Arch Intern Med.* 2002;162(11):1245-1248.
5. Lopez-Nunez JJ, Trujillo-Santos J, Monreal M. Management of venous thromboembolism in patients with cancer. *J Thromb Haemost.* 2018;16(12):2391-2396.
6. Sack GH, Jr., Levin J, Bell WR. Trousseau's syndrome and other manifestations of chronic disseminated coagulopathy in patients with neoplasms: clinical, pathophysiologic, and therapeutic features. *Medicine.* 1977;56(1):1-37.
7. Previtali E, Bucciarelli P, Passamonti SM, Martinelli I. Risk factors for venous and arterial thrombosis. *Blood Transfus.* 2011;9(2):120-138.
8. Haddad TC, Greeno EW. Chemotherapy-induced thrombosis. *Thromb Res.* 2006;118(5):555-568.
9. deLaforcade A, Bacek L, Blais MC, Goggs R, Lynch A, Rozanski E. Consensus on the Rational Use of Antithrombotics in Veterinary Critical Care (CURATIVE): Domain 1-Defining populations at risk. *J Vet Emerg Crit Car.* 2019;29(1):37-48.
10. Merlo DF, Rossi L, Pellegrino C, et al. Cancer incidence in pet dogs: findings of the Animal Tumor Registry of Genoa, Italy. *J Vet Intern Med.* 2008;22(4):976-984.
11. O'Neill DG, Church DB, McGreevy PD, Thomson PC, Brodbelt DC. Longevity and mortality of owned dogs in England. *Vet J.* 2013;198(3):638-643.
12. Withrow SJ, Vail DM, Page RL. *Withrow & MacEwen's small animal clinical oncology. 5th ed. Elsevier Health Sciences; 2012.*
13. Levi M, van der Poll T. Inflammation and coagulation. *Crit Care Med.* 2010;38(2 Suppl):S26-34.
14. Sobieszczyk P, Fishbein MC, Goldhaber SZ. Acute pulmonary embolism: don't ignore the platelet. *Circulation.* 2002;106(14):1748-1749.
15. Diakos CI, Charles KA, McMillan DC, Clarke SJ. Cancer-related inflammation and treatment effectiveness. *Lancet Oncol.* 2014;15(11):e493-503.
16. Falanga A, Marchetti M, Russo L. The mechanisms of cancer-associated thrombosis. *Thromb Res.* 2015;135 Suppl 1:S8-S11.
17. Falanga A, Marchetti M, Vignoli A. Coagulation and cancer: biological and clinical aspects. *J Thromb Haemost.* 2013;11(2):223-233.
18. Magnus N, D'Asti E, Meehan B, Garnier D, Rak J. Oncogenes and the coagulation system--forces that modulate dormant and aggressive states in cancer. *Thromb Res.* 2014;133 Suppl 2:S1-9.
19. de la Fuente C, Pumarola M, Blasco E, Fernandez F, Viu J, Anor S. Immunohistochemical evaluation of tissue factor, fibrin/fibrinogen and D-dimers in canine gliomas. *Vet J.* 2014;200(3):387-392.
20. Font C, de la Fuente C, Pumarola M, et al. Canine intracranial meningiomas: Immunohistochemical evaluation of tissue factor, fibrin/fibrinogen and D-dimers. *Vet J.* 2015;206(3):426-428.
21. Golombiewski A, Gutberlet K, Rudolph R. Immunohistological assessment of fibrin deposition and thrombus formation in canine mammary neoplasia. *J Comp Pathol.* 1997;117(2):177-183.
22. Beal SL, Reed RL, 2nd, Heimbach D, Chi E, Reynolds L. Pulmonary microembolism: a cause of lung injury. *J Surg Res.* 1987;43(4):303-310.
23. Kang MH, Park HM. Evaluation of autologous blood clot subsegmental pulmonary thromboembolism in minimally invasive experimental canine model. *Int J Exp Pathol.* 2013;94(5):329-335.

24. Schaeffer RC, Jr., Barnhart MI, Carlson RW. Pulmonary fibrin deposition and increased microvascular permeability to protein following fibrin microembolism in dogs: a structure-function relationship. *Microvasc Res.* 1987;33(3):327-352.
25. Johnson LR, Lappin MR, Baker DC. Pulmonary thromboembolism in 29 dogs: 1985-1995. *J Vet Intern Med.* 1999;13(4):338-345.
26. Lake-Bakaar GA, Johnson EG, Griffiths LG. Aortic thrombosis in dogs: 31 cases (2000-2010). *J Am Vet Med Assoc.* 2012;241(7):910-915.
27. LaRue MJ, Murtaugh RJ. Pulmonary thromboembolism in dogs: 47 cases (1986-1987). *J Am Vet Med Assoc.* 1990;197(10):1368-1372.
28. Laurenson MP, Hopper K, Herrera MA, Johnson EG. Concurrent diseases and conditions in dogs with splenic vein thrombosis. *J Vet Intern Med.* 2010;24(6):1298-1304.
29. Palmer KG, King LG, Van Winkle TJ. Clinical manifestations and associated disease syndromes in dogs with cranial vena cava thrombosis: 17 cases (1989-1996). *J Am Vet Med Assoc.* 1998;213(2):220-224.
30. Respass M, O'Toole TE, Taeymans O, Rogers CL, Johnston A, Webster CR. Portal vein thrombosis in 33 dogs: 1998-2011. *J Vet Intern Med.* 2012;26(2):230-237.
31. Van Winkle TJ, Bruce E. Thrombosis of the portal vein in eleven dogs. *Vet Path.* 1993;30(1):28-35.
32. Epstein SE, Hopper K, Mellema MS, Johnson LR. Diagnostic utility of D-dimer concentrations in dogs with pulmonary embolism. *J Vet Intern Med.* 2013;27(6):1646-1649.
33. Goggs R, Chan DL, Benigni L, Hirst C, Kellett-Gregory L, Fuentes VL. Comparison of computed tomography pulmonary angiography and point-of-care tests for pulmonary thromboembolism diagnosis in dogs. *J Small Anim Pract.* 2014;55(4):190-197.
34. Bauer N, Moritz A. Characterisation of changes in the haemostasis system in dogs with thrombosis. *J Small Anim Pract.* 2013;54(3):129-136.
35. Coletto AF, Wilson TM, Soares NP, et al. Prognostic Value of Occult Isolated Tumour Cells within Regional Lymph Nodes of Dogs with Malignant Mammary Tumours. *J Comp Pathol.* 2018;158:32-38.
36. de Araujo MR, Campos LC, Ferreira E, Cassali GD. Quantitation of the Regional Lymph Node Metastatic Burden and Prognosis in Malignant Mammary Tumors of Dogs. *J Vet Intern Med.* 2015;29(5):1360-1367.
37. Herring ES, Smith MM, Robertson JL. Lymph node staging of oral and maxillofacial neoplasms in 31 dogs and cats. *J Vet Dent.* 2002;19(3):122-126.
38. Hillers KR, Dernell WS, Lafferty MH, Withrow SJ, Lana SE. Incidence and prognostic importance of lymph node metastases in dogs with appendicular osteosarcoma: 228 cases (1986-2003). *J Am Vet Med Assoc.* 2005;226(8):1364-1367.
39. McNiel EA, Ogilvie GK, Powers BE, Hutchison JM, Salman MD, Withrow SJ. Evaluation of prognostic factors for dogs with primary lung tumors: 67 cases (1985-1992). *Journal of the American Veterinary Medical Association.* 1997;211(11):1422-1427.
40. Chan DA, Giaccia AJ. Hypoxia, gene expression, and metastasis. *Cancer Metastasis Rev.* 2007;26(2):333-339.
41. Evans CE, Palazon A, Sim J, et al. Modelling pulmonary microthrombosis coupled to metastasis: distinct effects of thrombogenesis on tumorigenesis. *Biol Open.* 2017;6(5):688-697.
42. Im JH, Fu W, Wang H, et al. Coagulation facilitates tumor cell spreading in the pulmonary vasculature during early metastatic colony formation. *Cancer res.* 2004;64(23):8613-8619.
43. Tuohy JL, Milgram J, Worley DR, Dernell WS. A review of sentinel lymph node evaluation and the need for its incorporation into veterinary oncology. *Vet Comp Oncol.* 2009;7(2):81-91.
44. Babski DM, Brainard BM, Ralph AG, Pittman JR, Koenig A. Sonoclot(R) evaluation of single- and multiple-dose subcutaneous unfractionated heparin therapy in healthy adult dogs. *J Vet Intern Med.* 2012;26(3):631-638.

45. Brainard BM, Meredith CP, Callan MB, et al. Changes in platelet function, hemostasis, and prostaglandin expression after treatment with nonsteroidal anti-inflammatory drugs with various cyclooxygenase selectivities in dogs. *Am J Vet Res.* 2007;68(3):251-257.
46. Gauthier V, Holowaychuk MK, Kerr CL, Bersenas AM, Wood RD. Effect of synthetic colloid administration on coagulation in healthy dogs and dogs with systemic inflammation. *J Vet Intern Med.* 2015;29(1):276-285.
47. Mount ME, Kim BU, Kass PH. Use of a test for proteins induced by vitamin K absence or antagonism in diagnosis of anticoagulant poisoning in dogs: 325 cases (1987-1997). *J Am Vet Med Assoc.* 2003;222(2):194-198.
48. Neff-Davis CA, Davis LE, Gillette EL. Warfarin in the dog: pharmacokinetics as related to clinical response. *J Vet Pharmacol Ther.* 1981;4(2):135-140.
49. Sullivan R, Graham CH. Hypoxia-driven selection of the metastatic phenotype. *Cancer Metastasis Rev.* 2007;26(2):319-331.
50. Wysokinski WE, Owen WG, Fass DN, Patrzalek DD, Murphy L, Mcbane II RD. Atrial fibrillation and thrombosis: immunohistochemical differences between in situ and embolized thrombi. *J Thromb Haemost.* 2004;2(9):1637-1644.
51. Moser KM, Guisan M, Bartimmo EE, Longo AM, Harsanyi PG, Chiorazzi N. In vivo and post mortem dissolution rates of pulmonary emboli and venous thrombi in the dog. *Circulation.* 1973;48(1):170-178.
52. Hammer AS, Couto CG, Swardson C, Getzy D. Hemostatic abnormalities in dogs with hemangiosarcoma. *J Vet Intern Med.* 1991;5(1):11-14.
53. Maruyama H, Miura T, Sakai M, et al. The incidence of disseminated intravascular coagulation in dogs with malignant tumor. *J Vet Med Sci.* 2004;66(5):573-575.
54. Kristensen AT, Wiinberg B, Jessen LR, Andreassen E, Jensen AL. Evaluation of human recombinant tissue factor-activated thromboelastography in 49 dogs with neoplasia. *J Vet Intern Med.* 2008;22(1):140-147.
55. Brat DJ, Van Meir EG. Vaso-occlusive and prothrombotic mechanisms associated with tumor hypoxia, necrosis, and accelerated growth in glioblastoma. *Lab Invest.* 2004;84(4):397-405.
56. Gruber EJ, Catalfamo JL, Stokol T. Role of tissue factor expression in thrombin generation by canine tumor cells. *Am J Vet Res.* 2016;77(4):404-412.
57. Verheul HM, Hoekman K, Lupu F, et al. Platelet and coagulation activation with vascular endothelial growth factor generation in soft tissue sarcomas. *Clin Cancer Res.* 2000;6(1):166-171.
58. Versteeg HH, Heemskerk JW, Levi M, Reitsma PH. New fundamentals in hemostasis. *Physiol Rev.* 2013;93(1):327-358.
59. Witter LE, Gruber EJ, Lean FZ, Stokol T. Evaluation of procoagulant tissue factor expression in canine hemangiosarcoma cell lines. *Am J Vet Res.* 2017;78(1):69-79.
60. Young JS, Llumsden CE, Stalker AL. The significance of the "tissue pressure" of normal testicular and of neoplastic (Brown-Pearce carcinoma) tissue in the rabbit. *J. Pathol Bact.* 1950;62(3):313-333.
61. Rooser B, Rydholm A, Persson BM. Internal pressure in soft-tissue tumors. *Acta Orthop Scand.* 1986;57(5):444-446.
62. Dennis MM, McSparran KD, Bacon NJ, Schulman FY, Foster RA, Powers BE. Prognostic factors for cutaneous and subcutaneous soft tissue sarcomas in dogs. *Vet Path.* 2011;48(1):73-84.
63. Kuntz CA, Dernel WS, Powers BE, Devitt C, Straw RC, Withrow SJ. Prognostic factors for surgical treatment of soft-tissue sarcomas in dogs: 75 cases (1986-1996). *J Am Vet Med Assoc.* 1997;211(9):1147-1151.
64. Saeger W, Genzkow M. Venous thromboses and pulmonary embolisms in post-mortem series: probable causes by correlations of clinical data and basic diseases. *Pathol Res Pract.* 1994;190(4):394-399.

65. Cooper GM. The cell a molecular approach. In: 2nd ed. Washington, D.C. Sunderland, Mass.: ASM Press; Sinauer Associates; 2000.
66. Sakuma M, Fukui S, Nakamura M, et al. Cancer and pulmonary embolism: thrombotic embolism, tumor embolism, and tumor invasion into a large vein. *Circulation J.* 2006;70(6):744-749.
67. Dudley A, Byron JK, Burkhard MJ, Warry E, Guillaumin J. Comparison of platelet function and viscoelastic test results between healthy dogs and dogs with naturally occurring chronic kidney disease. *Am J Vet Res.* 2017;78(5):589-600.
68. Marschner CB, Wiinberg B, Tarnow I, et al. The influence of inflammation and hematocrit on clot strength in canine thromboelastographic hypercoagulability. *J Vet Emerg Crit Car.* 2018;28(1):20-30.
69. Sprunger LK. Cunningham's Textbook of Veterinary Physiology, 6th ed. *Elsevier Health Sciences; 2020.*