

A mass guide for the harvest of cortico-cancellous bone from the posterior iliac crest for mandibular reconstruction

C. Ferretti^{a,b,h,*}, V. Premviyasa^c, J. Reyneke^{d,e,f,g} and U. Ripamonti^h

- a Department of Maxillofacial & Oral Surgery, University of Pretoria, Pretoria, South Africa
- b Formerly School of Oral Health Sciences, University of the Witwatersrand, Johannesburg, South Africa
- c Division of Maxillofacial & Oral Surgery, School of Oral Health Sciences, University of the Witwatersrand, Johannesburg, South Africa
- d Department of Oral and Maxillofacial Surgery, University of Florida, College of Dentistry, Gainesville, Florida, United States
- e Department of Maxillofacial and Oral Surgery, University of the Western Cape, Cape Town, South Africa
- f Division of Oral and Maxillofacial Surgery, Universidad Autonoma de Nuevo Leon, Monterrey, Mexico
- g Department of Oral and Maxillofacial Surgery, University of Oklahoma, College of Dentistry, Oklahoma City, OK, United States
- h Bone Research Unit, Department of Internal Medicine, Faculty of Health Sciences, University of the Witwatersrand, Johannesburg, South Africa

*Corresponding author at: P.O Box 75471, Gardenview, 2047, South Africa. Tel.: +27 116159595.

Abstract

This study sought to find the mass of particulate cortico-cancellous bone graft required per 1cm continuity defect of the mandible. Harvested bone was weighed, milled and maximally compressed in a syringe. The defect length (DL) was measured in centimetres, and the compressed bone volume (CBV) used was recorded. The wet bone mass (WBM) of bone required per centimetre of mandibular defect, and the mass of bone yielding 1cc of compressed bone was calculated. Results were analysed statistically to determine if clinically meaningful differences exist between male and female iliac crest. Forty three patient records were reviewed (28 female). Thirty patients had bilateral, and 13 patients had unilateral iliac crest harvest. Mean WBM used per centimetre of mandible defect was 6.9g. WBM required to produce 1cc of CBV was 2.0cc. For the bilateral harvest group the mean DL was 10.3cm, the mean WBM was 66.7g, and the mean CBV was 33.9cc. There was no significant difference in mean WBM between male (72.8g) and female (62g) patients. The mean CBV for males (39.7g) was significantly higher than females (29.5g). For patients who had unilateral harvest the mean DL was 7.7cm, the mean WBM harvested was 59.1g, and the mean CBV was 29.4cc. The mean wet bone mass of posterior iliac crest required to graft each centimetre of mandibular segmental defect is 6.9 grams. A unilateral posterior iliac crest harvest will yield on average 59.1 grams of bone whilst a bilateral posterior iliac crest harvest will yield on average 66.7 grams

Keywords: Mandibular reconstruction, posterior iliac crest, bone mass

To ensure successful reconstruction of a mandibular segmental defect with particulate cortico-cancellous bone (PCCB) graft, an adequate volume of highly cellular autologous bone is essential.¹ The posterior iliac crest (PIC) is the most apposite site to provide the quality and quantity of bone required.²⁻⁴ It has one major drawback: it is harvested whilst the patient is prone, requiring a mid-surgery change of patient position. An inadequate volume of bone discovered once the patient has been returned to the supine position would be problematic for the reconstructive team. One way to obviate this problem is to harvest as much bone as possible, which increases surgical time and morbidity.

Several studies have sought to determine the quantity of bone obtainable from the posterior iliac crest and have yielded remarkably divergent results. Cadaveric studies have found compressed bone volumes of 10.1 cc, 24.1 cc, and 30.3cc,⁵⁻⁷ whilst clinical studies reported uncompressed bone volumes from the posterior iliac crest of 25.5 cm³ and 88 ml.^{8,9} A study using 3 dimensional CT of the ilium predicted that 33.99 ± 7.74 ml should be obtainable from the posterior iliac crest.¹⁰ Finally a study comparing two different techniques of PIC harvest during spinal surgery found a mean of 36g of cortico-cancellous bone could be harvested from one PIC.¹¹ These variations are most likely due in large part to differences in harvesting technique, in particular the self-imposed limits by individual surgeons of what may be deemed safe. It is also unclear (in the clinical studies at least) if all the available bone was removed from each site in each instance.

The generally accepted rule of thumb to guide the surgeon when harvesting bone for mandibular reconstruction is that 10mls of uncompressed bone are required for every centimetre of mandibular defect.⁹ To the best of our knowledge this has never been verified experimentally. An added inconvenience is that determining uncompressed bone volume can only be done by volume displacement which is cumbersome, and immersion of bone into saline may also be detrimental to cellular viability.

The wet mass of bone required per centimetre of mandibular defect would be extremely helpful to guide the harvest of PIC. This study seeks primarily to determine the wet bone mass of PIC required to graft 1 centimetre of segmental mandibular defect. It will also measure the wet bone mass harvestable from the PIC, and what compressed bone volume is produced after milling and maximal manual compression. Finally it will seek to determine if sexual dimorphism influences bone graft mass and volume.

Materials and methods

A retrospective, observational, cohort study was conducted using the database of patients who had mandibular reconstruction with PCCB graft from the posterior iliac crest.

Permission to use the database was obtained from the Head of the School of Oral Health Sciences and ethical clearance was obtained from the Human Research Ethics Committee of the university. All patients with continuity defects of the mandible (secondary to resection of benign pathology, trauma or infection) requiring reconstruction were included in this study. Patient clinical records were allocated a study number to maintain anonymity. The patient's age and gender were documented.

Patients were prepared for grafting as previously described. To summarize, the tumour was resected, and a patient matched plate secured to the mandible.¹² A non-toxic, medical and food grade, soft silicone spacer was placed and secured to the reconstruction plate with 0.18-inch stainless steel wire.¹²

After a six to eight week healing period, a bone graft was harvested from the PIC, (unilateral or bilateral, guided by clinical impression of the bone volume required) while the patient was prone. The PIC was exposed via a curvilinear incision starting just medial to the midpoint of the ipsilateral posterior iliac crest curving medially and inferiorly over the posterior iliac crest terminating above the posterior superior iliac spine. The posterior iliac crest, spine and lateral

surface of the posterior ilium were exposed inferiorly to the sciatic notch and from the sacroiliac joint to the anterior limit of the bicortical portion of the posterior ilium. The outer cortical plate was removed and the subjacent cancellous bone was harvested with a curette. All the available bone was harvested from every donor site. The cortical and cancellous bone was weighed on a scale, recorded in grams and the mass designated the *wet bone mass* (WBM) (Figure 1). Once harvested, the bone was stored on ice, and the patient returned to the supine position. The mandibular defect was exposed via an extra-oral approach and the spacer removed. The defect length was measured with a flexible ruler, recorded in centimetres and designated the *defect length* (DL). The recipient soft tissue bed and the osseous interfaces were carefully debrided. Harvested bone was milled with a power bone mill (Stryker Leibinger, Michigan, USA), transferred into 20ml plastic syringes and maximally manually compressed to expel all blood, fat and air (Figure 2). The resultant volume was recorded in cubic centimetres and designated the *compressed bone volume* (CBV). The compressed cortico-cancellous graft was syringed into the recipient bed. If only a portion of the harvested bone was used this was recorded in cubic centimetres and designated the *compressed bone volume used* (CBVU). From these recorded data the following was calculated:

1. The wet bone mass WBM of bone used per centimetre of mandibular defect – designated WBM_DL in g/cc
2. The wet bone mass required to produce 1cubic centimetre of compressed bone – designated WBM_CBV in g/cc
3. The compressed bone volume used per centimetre of mandibular defect – designated CBV_DL in cc/cm.

The data would be used to determine if there is a clinically significant difference in the bone available to harvest between males and females, firstly by comparing the WBM in the BPIC

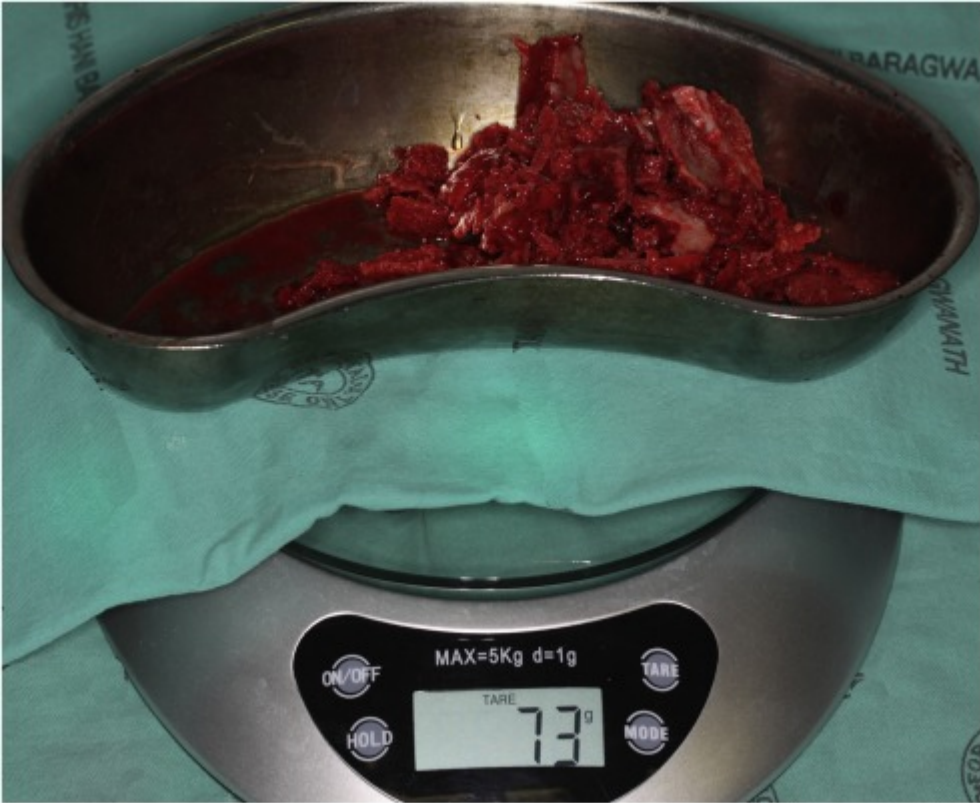


Fig. 1. Harvested bone weighed on a kitchen scale.

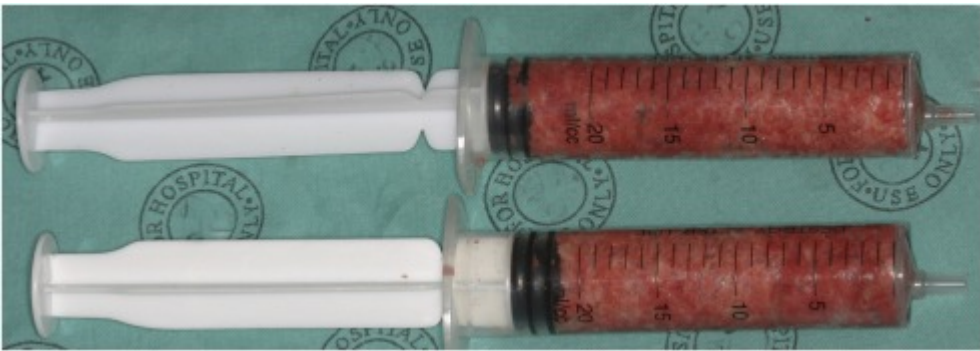

Fig. 2. Milled bone compressed manually in a syringe until all air, fat, and blood has been expelled.

and UPIC groups. Differences in bone density would be assessed by comparing the WBM_CBV in g/cc of male versus female bone. Data analysis was carried out using SAS version 9.4 for Windows. The 5% significance level was used throughout. Between-gender comparisons of WBM, CBV, and WBM_CBV were made using the independent samples t-test.

Results

Forty three patients' (15 male, 28 female) records were studied. Thirty patients had BPIC harvest (13 male and 17 female), and 13 patients had UPIC harvest (2 male and 11 female). Comparisons of WBM, CBV, and WBM_CV between genders were only performed for the BPIC group. Total WBM and CBV was calculated for the BPIC and UPIC, but not for the entire cohort. All numerical data is presented as mean \pm standard deviation (range).

The results are summarised in Table 1 and Table 2.

Results obtained from entire cohort (n=43):

The mean defect length was $9.5\text{cm} \pm 2.5$ (6 -16). Wet bone mass used per centimetre of segmental mandibular DL was $6.9\text{g} \pm 1.7$ (3.7 – 10.7). WBM required to produce 1cc of compressed bone volume $2.0\text{ g/cc} \pm 0.3$ (1.4 – 2.7). CBV used per centimetre of mandibular DL was $3.4\text{cc} \pm 0.8$ (1.5 - 4.9)

Results obtained from patients who had BPIC harvest (n=30):

The mean DL was $10.3\text{cm} \pm 2.4$ (6 – 16). The mean WBM harvested was $66.7\text{g} \pm 16.2$ (32- 100), and the mean CBV was $33.9\text{cc} \pm 9.0$ (20 – 52). There was no significant difference in mean WBM between male $72.8\text{g} \pm 15.4$ (47 - 98) and female patients $62\text{g} \pm 15.7$ (32 - 100)

Table 1. Harvest of bilateral posterior iliac crest in male and female patients (n = 43). Data are mean (SD) and range.

Variable	Wet bone mass (g)	Compressed bone volume (ml)	Wet bone mass/cm length of defect (g)	Wet bone mass/ml of compressed bone volume (g)	Length of defect (cm)
Total	-	-	6.9 (1.7) 3.7-10.7	2.0 (0.3) 1.4-2.7	9.5 (2.5) 6-16
Men (n = 13)	72.8 (15.4) 47-98	39.7 (8.8) 26-52	-	1.9(0.2) 1.4-2.1	-
Women (n = 17)	62 (15.7) 32-100	29.5 (6.3) 20-42	-	2.1 (0.3) 1.6-2.4	-
p value	0.069	0.001	-	0.001	-

Table 2. Comparison of harvest from bilateral and unilateral iliac crests. Data are mean (SD) and range.

Variable	Wet bone mass (g)	Compressed bone volume (ml)	Length of defect (cm)
Bilateral	66.7 (16.2) 32-100	33.9 (9.0) 20-52	10.3 (2.4) 6-16
Unilateral	59.1 (12.0) 40-78	29.4 (6.2) 20-42	7.7 (1.6) 6-10.5

($p=0.069$). However, the mean CBV for male patients of 39.7 ± 8.8 g (26 - 52) was significantly higher than that for females 29.5 ± 6.3 g (20 - 42) ($p=0.0010$). The mean WBM_CBV for male patients (1.87 ± 0.13 g/cc) was significantly lower than that for females (2.11 ± 0.13 g/cc) ($p=0.0010$).

For the entire cohort ($n=43$), there was no significant difference in mean WBM_CBV between male and female patients ($p=0.11$).

Results obtained from patients who had UPIC harvest ($n=13$):

The mean DL was $7.7\text{cm} \pm 1.6$ (6 - 10.5), the mean WBM harvested was $59.1\text{g} \pm 12.0$ (40 - 78), and the mean CBV was $29.4\text{cc} \pm 6.2$ (20 - 42).

Discussion

This study's primary goal was to find the mass of PCCB graft required to graft 1 cm of mandibular segmental defect, thereby providing surgeons an alternative to the generally accepted volumetric guide. The mean WBM used per centimetre of mandibular continuity defect was 6.9 grams. Disconcertingly, the range (3.7– 10.7 g/cm) was greater than one would have intuitively expected. It should be borne in mind that only 1 patient required less than 4g/cm, 2 patients more than 9 g/cm and 3 patients more than 10g/cm, but an attempt at explaining these extremes may be appropriate. Unwillingness to dispose of excess bone may have caused over enthusiastic packing of an unnecessarily large volume of bone into a defect. Despite this, in 6 patients harvested bone was excess to requirements and was discarded. We surmise that the highest value in the range (10.7 g/cm) may have been in shorter defects, smaller mandibles, or in patients with a large ilium, (thus allowing for more bone harvest) and would result in high volume ossicle (Figure 3), whilst the low value (3.7 g/cm), might be obtained from either a small ilium or a large defect (by reducing the amount of bone available

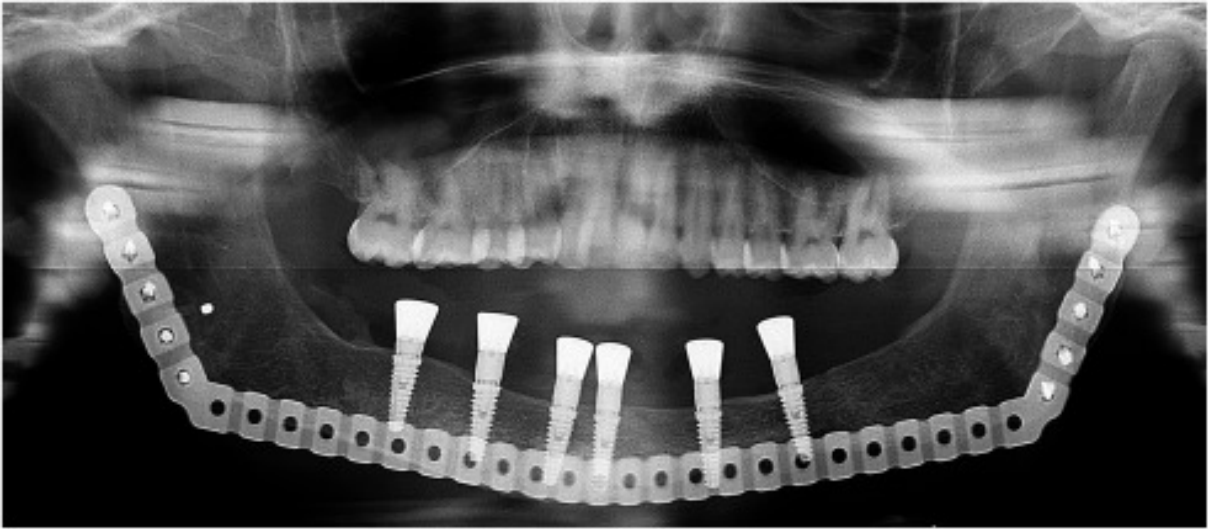


Fig. 3. A high volume ossicle.

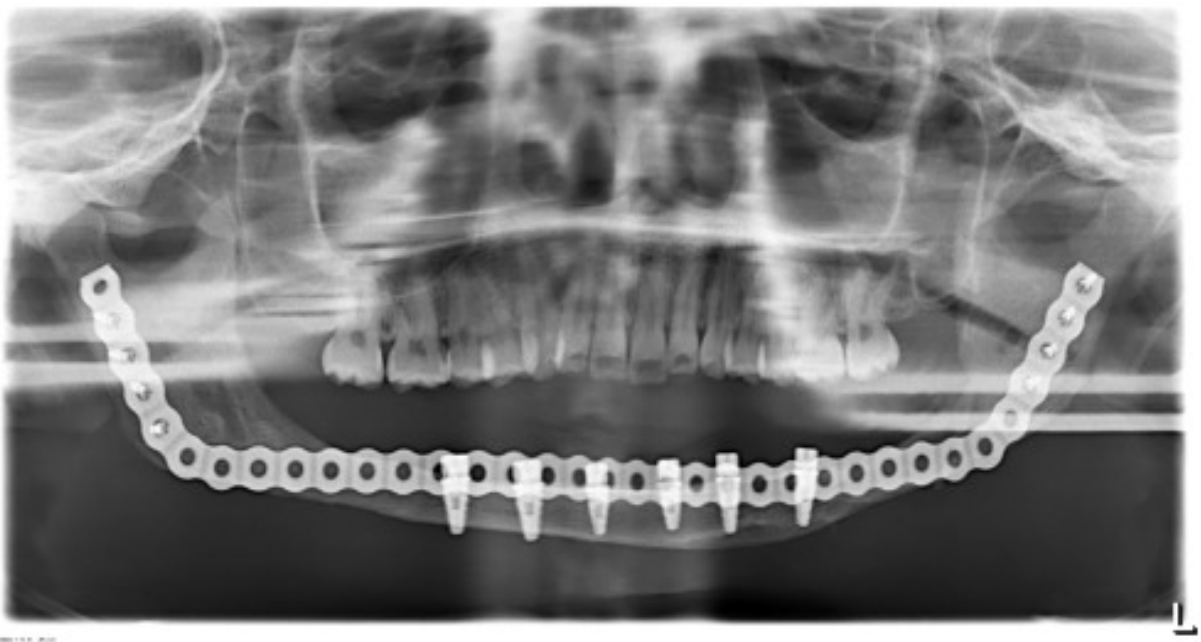


Fig. 4. A low volume ossicle.

per cm of defect length) and would result in a low volume ossicle (Figure 4). Nevertheless, all defects reconstructed (even those with 3.7 g/cm) yielded ossicles adequate for endosseous fixture placement.

Given that in each instance we harvested all the safely removable bone from every site, this study provided a secondary finding: the wet bone mass available from a single posterior iliac crest. The mean WBM in the UPIC group was $59.1\text{g} \pm 12.0$ (40 -78) and the range confirms that there are significant variations in ilium size. Counter-intuitively, the mean bone mass for the BPIC group was not double a UPIC, but $66.7\text{g} \pm 16.2$ (32-100). It is worth noting that the lowest WBM in the BPIC group (32g) was lower than the lowest value for the UPIC group (40g). The interpretation of this data is not as straightforward as one would like but if we suppose that in an individual patient the bone obtained from a bilateral harvest is double that of a unilateral harvest, then as a rough guide a unilateral harvest may yield as little 16g (half the lower limit of the BPIC range) or as much as 78g (upper limit of the UPIC range). The corollary is that a BPIC graft may yield as little as 32grams (the lowest mass in the BPIC group) and as much as 156 grams (double the highest mass in the UPIC group). Accordingly a BPIC may be required in a patient with small iliac crests and a BPIC may be avoided in a patient with large iliac crests. We could find only one study which measured the mass of bone obtainable from a PIC.¹¹ This study reported a mean bone mass of 36 grams from a single PIC. The harvest was for spinal surgery and the approach and technique for harvest may explain the significantly lower mass than found by this study. The other studies we could find only reported uncompressed and compressed bone volume. As we did not measure the former we can only compare the latter. We found a mean CBV of $29.4\text{cc} \pm 6.2$ (20 – 42) whilst others reported $10.1\text{cc} \pm 2.51$ (7-14),⁵ $24.11\text{cc} \pm 6.04$ (17-37),⁶ and $30.31\text{cc} \pm 3.42$.⁷

Finally the goal of assessing whether sexual dimorphism may play a role in affecting the bone mass available was constrained by the paucity of male patients in the UPIC group.

Within the BPIC group, whilst no difference was found in the wet bone mass between males and females, we found a statistically significant difference in the CBV (higher in males than females) and the wet bone mass required to produce 1cc of compressed bone (lower in males than females). This suggests that female bone may be less dense than male bone and thus more compressible. These results must be considered with caution due to the sample size.

Future studies should seek to correlate the compressed bone volume implanted to the resultant mature final ossicle volume. This will provide important information regarding volumetric changes during bone graft maturation. The extreme variations in ilium size found in this study will be a cause for concern for surgeons. A further goal for future research will be to combine pre-surgery three dimensional imaging of the iliac crest with actual graft mass and volume obtained to allow for improved planning.

This study found that the average wet bone mass of posterior iliac crest required to graft each centimetre of mandibular segmental defect is 6.9 grams. A unilateral posterior iliac crest harvest will yield on average 59.1 grams of bone but as little as 16 grams and as much as 78 grams.

References

1. Buchardt H. Biology of bone transplantation. *Orthop Clin North Am.* 1987; 18: 187-196.
2. Bloomquist DS, Feldman GR. The posterior ilium as a donor site for maxillo-facial bone grafting. *J Maxillofac Surg.* 1980; 8(1): 60-64.
3. Marx RE. Bone and bone graft healing. *Oral Maxillofac Surg Clin North Am.* 2007; 19(4): 455-466.
4. Marx RE. Bone harvest from the posterior ilium. *Atlas Oral Maxillofac Surg Clin North Am.* 2005 Sep;13(2):109-110. Boyne PJ. Osseous reconstruction of the maxilla and mandible. Chicago Quintessence Publishing. 1997; 52-67.
5. Engelstad ME, Morse T. Anterior iliac crest, posterior iliac crest, and proximal tibia donor sites: a comparison of cancellous bone volumes in fresh cadavers. *J Oral Maxillofac Surg.* 2010 Dec;68(12):3015-21.
6. Burk T, Del Valle J, Finn RA, et al. Maximum Quantity of Bone Available for Harvest From the Anterior Iliac Crest, Posterior Iliac Crest and Proximal Tibia Using a Standardized Surgical Approach: A Cadaveric Study. *J Oral Maxillofac Surg.* 2016; 74(12): 2532-2548.
7. Hall MB, Vallerand WP, Thompson D, et al. Comparative anatomic study of anterior and posterior iliac crests as donor sites. *J Oral Maxillofac Surg.* 1991; 49(6): 560-563.
8. Kessler P, Thorwarth M, Bloch-Birkholz A, et al. Harvesting of bone from the iliac crest – comparison of the anterior and posterior sites. *Br J Oral Maxillofac Surg.* 2005; 43(1): 51-56.
9. Marx RE, Morales MJ. Morbidity from bone harvest in major jaw reconstruction: a randomised trial comparing the lateral anterior and posterior approaches to the ilium. *J Oral Maxillofac Surg.* 1988; 46(3): 196-203.

10. Kilinc A, Korkmaz IH, Kaymaz I, Kilinc Z, Dayi E, Kantarci A. Comprehensive analysis of the volume of bone for grafting that can be harvested from iliac crest donor sites. *Br J Oral Maxillofac Surg.* 2017 Oct;55(8):803-808.
11. Mirovsky Y, Neuwirth MG. Comparison between the outer table and intracortical methods of obtaining autogenous bone graft from the iliac crest. *Spine (Phila Pa 1976).* 2000; 25(13): 1722-1725.
12. Ferretti C, Muthray E, Rikhotso E, et al. Reconstruction of 56 mandibular defects with autologous compressed particulate cortico-cancellous bone grafts. *Br J Oral Maxillofac Surg.* 2016; 54(3): 322-326.