

# MICRO-ENDODONTIC SURGERY PART 1: SURGICAL RATIONALE AND MODERN TECHNIQUES

SADJ April 2018, Vol 73 no 3 p146 - p153

HC Seedat,<sup>1</sup> PJ van der Vyver,<sup>2</sup> FA de Wet.<sup>3</sup>

## ABSTRACT

The discipline of endodontics has seen vast improvements in technology and clinical techniques over the past several years. One of the areas that has been characterized by new developments is the way in which endodontic surgery is performed. The gap between biological concepts and the ability to achieve clinically successful results has been narrowed down with the use of microsurgical and ultrasonic instruments, new retrograde materials and the use of the Dental Operating Microscope. This article will review the indications and contraindications for endodontic surgery, the use of Cone Beam Computed Tomography for diagnosis and treatment planning, and finally outline the modern technique for endodontic microsurgery.

## INTRODUCTION

Periapical pathosis occurs when the root canal system is breached and becomes exposed to the oral microflora, and these microbial invaders, or their by-products, egress into the peri-radicular area via the apical foramen or lateral canals.<sup>1,2</sup> The objectives of non-surgical endodontic therapy are to entirely remove pulpal debris, microbes and microbial by-products from the root canal system, and to three-dimensionally seal the affected root canal space.<sup>3</sup>

Endodontic treatment failure may occur as a result of persistent intraradicular microbial infections or secondary infections, and in some cases extra-radicular infections.<sup>4</sup> The failure of endodontic treatment may also be attributed to the inadequate shaping, cleaning and obturation of the root canal system, iatrogenic incidences during the endodontic procedure, or re-infection of the root canal system due to a breakdown in the coronal seal subsequent to endodontic therapy.<sup>5</sup> The clinical treatment options available for failed endodontically treated teeth are non-surgical endodontic retreatment, periapical surgery or extraction.<sup>5</sup> Dental extraction is considered when teeth are unrestorable, have non-treatable periodontal disease or root fractures.<sup>5</sup> Nonsurgical retreatment of failed endodontic cases should be considered as the first treatment option, and has proven to have a weighted average success rate of 95%.<sup>6</sup>

Indications for endodontic surgery include:<sup>7</sup>

1. Where peri-radicular disease persists in an endodontically treated tooth, and retreatment is unsuccessful or unfeasible.
2. The correction of iatrogenic errors such as the retrieval of separated instruments or root filling materials that have

1. **Hussein C Seedat**, BDS (Wits), PG Dip Dent (Endo), PG Dip Dent (Aesthet Dent), MSc Odont(Pret).\*

2. **Peet J van der Vyver**, BChD, PG Dip Dent (Endo), PG Dip Dent (Aesthet Dent), MSc, PhD(Pret).\*

3. **Francois A de Wet**: BChD, MSc, DSc(Pret).\*

\* Department of Odontology, School of Dentistry, Faculty of Health Sciences, University of Pretoria, Pretoria, South Africa

## ACRONYMS

CBCT : Cone Beam Computed Tomography

DOM : Dental Operating Microscope

UREP : ultrasonic root end preparation

3. protruded beyond the apex of the root.
3. The requirement of a biopsy to investigate a suspicious lesion, or when a clinical investigation is required to directly visualise a possible vertical fracture.
4. When a combined non-surgical and surgical approach is required, such as treatment of a possible radicular cyst.

Contraindications of endodontic surgery include:<sup>7</sup>

1. Dental factors which include an un-restorable tooth, inadequate root length or poor periodontal support.
2. Anatomical factors such as close proximity to a neurovascular bundle.
3. Surgical access factors such as limited mouth opening.
4. Patient factors such as psychological problems or systemic diseases.
5. Clinician factors which include the level of training, skill and experience of the operator as well as the availability of appropriate equipment.

The procedure of surgery at the apex is commonly referred to as an apicoectomy, however, this refers to only one aspect of the sequence of events required to carry out the operation (root-end resection).<sup>6</sup> The terms endodontic surgery or surgical endodontics are more appropriate as the objective of the procedure is to achieve three dimensional shaping, cleaning and obturation of the apical portion of the root canal system by accessing it via the raising of a surgical flap.<sup>8</sup> Since this surgical procedure is now more routinely carried out using the surgical operating microscope it is also referred to as endodontic microsurgery.<sup>9</sup> The sequence of procedures involved in periapical endodontic surgery are anaesthesia, flap design, incision and reflection of a full thickness flap, gaining access to the root apex, debridement of pathological periapical tissues, root-end resection, root-end cavity preparation, sealing off the root canal system with a root-end filling, flap replacement and suturing, postoperative instructions and care, removal of sutures and evaluation.<sup>10</sup>

Over the past two decades the traditional technique of performing endodontic surgery has evolved significantly and has emerged as a predictable treatment option to maintain the natural dentition. The modern technique involves the use of the operating microscope, micro-surgical instruments, refined hard and soft tissue management techniques, and the use of more biologically acceptable root-end filling materials.

### Cone Beam Computed Tomography (CBCT)

Until recently, radiographs have been the only means available to examine the anatomy of the tooth and surrounding structures.<sup>11</sup> Limitations of radiographs are that they do not offer three dimensional information, and areas of interest may be obscured by overlying anatomy (anatomic noise).<sup>12</sup> Cone beam computed tomography machines (Figure 1) were developed in the late 1990's. They produce three dimensional scans of the maxillo-facial skeleton, using significantly less radiation than conventional computed tomography.<sup>13</sup>

Cone beam computed tomography is a valuable diagnostic aid, and is recommended for treatment planning for endodontic surgery.<sup>14</sup> The anatomical relationship of the root apices to significant surrounding anatomical structures, such as the inferior alveolar canal, mental foramen and maxillary sinus, can be evaluated.<sup>11</sup> Furthermore, the exact inclination of the roots, presence of fenestrations, thickness of the cortical bone as well as the true size and extent of periapical lesions can be determined accurately.<sup>15</sup>



**Figure 1:** Orthophos SL 3D (Dentsply Sirona) capable of taking limited field of view images with a resolution of 80µm in the "endo" mode, ideal for endodontic applications.

### Dental Operating Microscope (DOM)

The DOM (Figure 2) has changed both non-surgical and surgical endodontics. Microsurgery can be defined as a surgical procedure performed on small, complex structures using a DOM.<sup>9</sup> In 1992, Dr Gary Carr introduced a DOM that had Galilean optics and was ergonomically configured for dentistry.<sup>16</sup> With Galilean optics, the light beams going to each eye are parallel and focused to infinity instead of being convergent, so that the operators' eyes are at rest, as though looking into the distance.<sup>17</sup> Because the illumination is coaxial with the line of sight, there are no shadows when viewing the surgical site, and there is no eye fatigue even during procedures that take several hours.<sup>17</sup>

When using surgical loupes and a headlamp, there is a tendency for the operator to bend over the patient, resulting in head, neck and shoulder strain.<sup>17</sup> In contrast and in addition to the enhanced magnification and illumination enjoyed with the use of the operating microscope, a more comfortable posture of the head, neck, spine and pelvis can be maintained by the operator, resulting in superior ergonomics.<sup>17</sup> The benefits of using the dental operating microscope during endodontic surgery include:<sup>9</sup>

1. Avoiding unnecessary trauma to the soft tissue during incision, reflection, retraction and suturing.<sup>18</sup>
2. The root apex can be examined under high magnification, making it possible to identify and manage anatomical complexities, perforations or fractures.
3. Diseased tissue can be precisely and completely removed.
4. The root tip can be easily distinguished from bone.

5. A smaller osteotomy can be made using magnification, resulting in quicker healing and less postoperative pain.
6. Fewer radiographs are required as the apex can be directly and precisely examined.
7. The procedure can be documented by video recording for educational purposes and communication with the referring dentist.



**Figure 2:** Dental Operating Microscope (Zumax, Japan) that provides a magnified, coaxial line of sight during surgical procedures.

### MICROSURGICAL ARMAMENTARIUM

Microsurgical instruments have been developed for endodontic microsurgery as traditional surgical instruments were found to be too large to use in small places, or too traumatic to soft and hard tissues.<sup>17</sup>

Micro-scalpels (N6900 Nordland blade, Micro Mini, Full Radius, G Hartzell & Sons, USA) (Figure 3) are used to create incisions, especially in delicate areas like the interdental papilla. Small, sharp, micro-surgical periosteal elevators (ZEPF Dental, Germany) (Figure 4) are then used under the DOM for atraumatic flap elevation.<sup>17</sup> Rubenstein retractors (JEDMED, USA) have a variety of serrated contact surfaces that are flat, notched or recessed to suit different anatomical areas, and are designed to retract both the flap and lip, and will keep the operators hand out of the view of the microscope as the blade is set at 110 degrees rotation to the handle.<sup>17</sup>



**Figure 3:** Comparison of a conventional 15C blade (top) with a micro-surgical blade (bottom).

Ultrasonic tips have been designed to prepare root-end cavities, and the introduction of micro-mirrors (ZEPF Dental, Germany) (Figure 5) make it possible to examine the apical preparation.<sup>16,17</sup>

Microsurgical suturing techniques that involve smaller gauged tapered needles and smaller sizes sutures (5-0 and 6-0) also requires the use of smaller micro-surgical tissue forceps (ZEPF Dental,



**Figure 4:** Comparison of a conventional periosteal elevator (top) with two micro-surgical periosteal elevators.



**Figure 5:** Size Comparison of a conventional front surface mirror (left) with a micro-surgical 9 mm rectangular mirror (middle) and a 5 mm micro-surgical round mirror that can be used to examine the bevelled root apex.

Germany) (Figure 6), needle holders (Microsurgery Instruments INC, USA)(Figure 7) and scissors (Microsurgery Instruments INC, USA) (Figure 8).

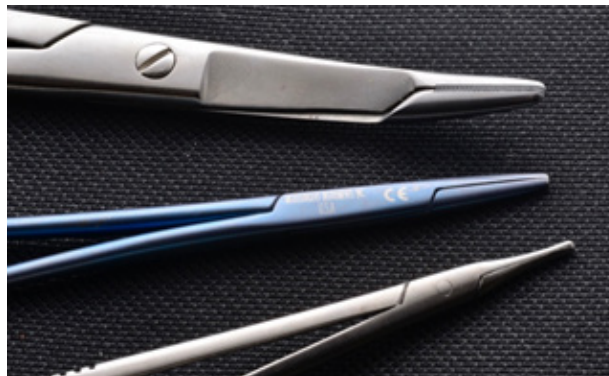

**Figure 6:** Size Comparison of a conventional (top) versus a micro-tissue forceps (bottom).

The Micro-Apical Placement System (MAP) (Dentsply Maillefer, Ballaigues, Switzerland) (Figure 9) or the Dovgan MTA Carrier (Quality Aspirators, Duncanville, Texas, USA) (Figure 10) allows accurate placement of root-end fillings, such as MTA into the root-end cavity preparation without spillage into the bony crypt.<sup>17</sup>

### ANAESTHESIA AND HAEMOSTASIS

The goals of local anaesthetic during endodontic surgery are



**Figure 7:** Size comparison of a conventional needle holder (top) versus micro-surgical needle holders.



**Figure 8:** Size comparison of a conventional surgical scissors (top) compared with a micro-surgical scissors (bottom).



**Figure 9:** The Micro-Apical Placement (MAP) System.



**Figure 10:** The Dovgan MTA Carrier.

anaesthesia pain control, haemostasis and post-surgical pain control.<sup>19</sup> An anaesthetic with a high concentration of vasoconstrictor, for example 1:50,000 epinephrine, is preferred to obtain adequate anaesthesia and prolonged haemostasis.<sup>9</sup> Kim and Kratchman (2006) recommend the application of epinephrine pellets into the bony crypt, followed by pressure to the pellets with sterile cotton pellets for two to four minutes to achieve prolonged haemostasis.<sup>9</sup> Should small bleeds occur from the bone, a cotton pellet soaked in ferric sulphate can be dabbed onto the area to further control haemostasis.<sup>9</sup> In a large osteotomy site, calcium sulphate paste packed into the bony crypt is effective in achieving haemostasis, and can be left in place as it is resorbable.<sup>9</sup>

### MANAGEMENT OF SOFT TISSUES

#### Flap Design

During endodontic surgery, the cortical bone needs to be exposed by incision, elevation and reflection of a full thickness flap consisting of periosteum, gingival and mucosal tissues.<sup>20</sup> The correct management of the soft tissues is necessary to obtain complete, recession-free healing of the gingiva with the avoidance of scar formation to obtain an aesthetically pleasing result.<sup>21</sup>

The once popular semilunar flap that was developed by Partsch in the late 1890's is no longer recommended, as it does not permit adequate access to the root apex, and results in excessive scarring (Figure 11).<sup>21,22</sup> The two flap designs currently recommended for

apical microsurgery are the full sulcular flap (Figure 12) in the posterior quadrants, and submarginal (Ochsenbein-Leubke) (Figure 13) in the anterior zone.<sup>23</sup>

The full sulcular flap is also known as the full thickness marginal flap, and includes a primary incision within the gingival sulcus following

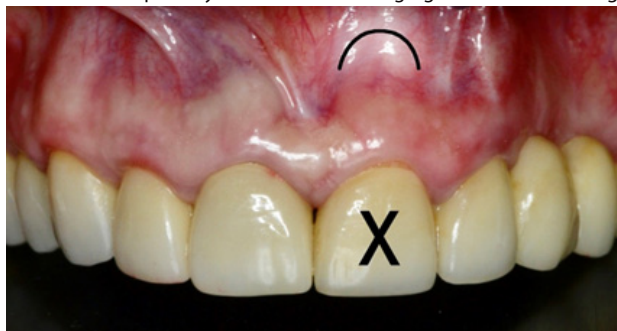

Figure 11: Semilunar flap design.

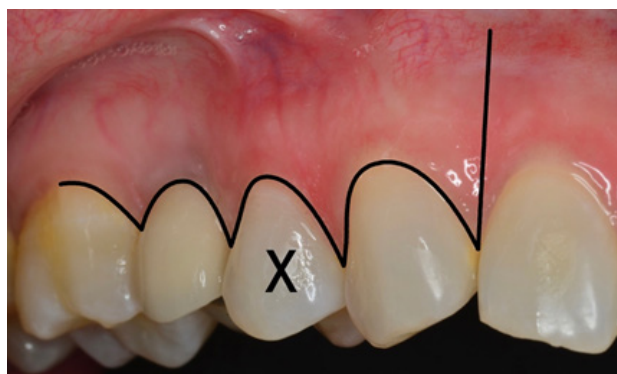

Figure 12: Full sulcular flap design.

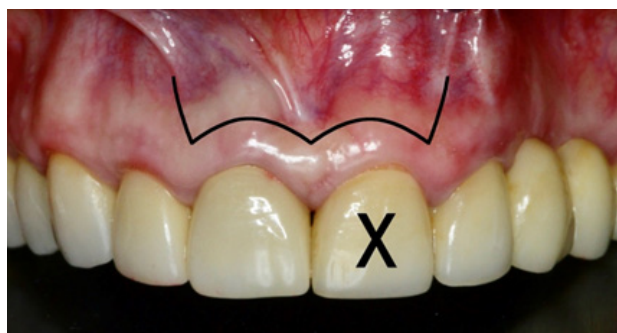


Figure 13: Submarginal (Ochsenbein-Leubke) flap design.

the contour of the teeth.<sup>7</sup> It is triangular if one vertical relieving incision is used, and rectangular when there are two such incisions.<sup>23</sup>

The submarginal (Ochsenbein-Leubke) flap is rectangular and comprises two vertical incisions and a scalloped horizontal incision within attached gingiva that follows the contour of the gingival margin and is about 3 mm from it.<sup>7</sup> A minimum thickness of 2 mm of attached gingiva is a pre-requisite to performing the submarginal flap.<sup>20</sup>

## SUTURING

Multifilament sutures such as 4/0 silk are no longer recommended as they accumulate plaque within the braids, and thus cause secondary inflammation and delayed healing.<sup>9</sup> Thinner monofilament sutures such as polyamide (5/0 and 6/0) (Figure 14) or polypropylene sutures are ideal for endodontic microsurgery as they attract less plaque and therefore result in a cleaner surgical site.<sup>9</sup> In the past it was customary to remove 4/0 silk sutures after 7 days.<sup>20</sup> Currently, the belief is that the monofilament sutures should be removed within 48 to 72 hours as resealing of the epithelium at the wound margin is visible after 2 to 3 days and an intense inflammatory response to the suture is seen after three days.<sup>9,21</sup>

## HARD TISSUE MANAGEMENT - OSTEOTOMY

Osteotomy involves the removal of the cortical and cancellous



Figure 14: Monofilament sutures size 5/0.

bone to gain access to the apical portion of the root.<sup>24</sup> The process can be carried out with an Impact-air 45 high speed hand-piece (SybronEndo, Orange, California, USA) or a similarly designed hand-piece. The head of the turbine is at a 45° angle to the shaft, making it easier to gain access to the apices of molar teeth.<sup>10</sup> Furthermore, the water spray is directed toward the surgical site and the air stream is ejected from the back of the hand-piece, thus eliminating the possible complications of air emphysema or air embolism.<sup>9,10</sup>

The traditional endodontic surgical technique involved creating an osteotomy that is 8-10 mm in diameter.<sup>9</sup> Rubinstein and Kim (1999) found that the rate of healing was faster when the size of the osteotomy was smaller.<sup>25</sup> The modern endodontic surgery advocates the osteotomy size to be 3-4 mm in diameter, which is just large enough for a retrograde ultrasonic tip to access the bone crypt and vibrate freely.<sup>9</sup> An advantage of using the dental operating microscope is that it allows the operator to clearly distinguish the root tip from bone within a conservatively prepared osteotomy.<sup>9</sup>

A constant stream of water or saline is required on the cutting surface of the bur to avoid overheating of the bone.<sup>24</sup> Eriksson and Albrektsson (1983) found that bone is irreversibly damaged when its temperature is raised above 47°C for one minute.<sup>26</sup>

The use of a diamond bur is not recommended, as the diamond grit traps bone particles and therefore increases frictional heat.<sup>24</sup> A round, steel bur with widely spaced flutes to minimise bone chips is recommended for bone removal.<sup>24</sup> The round bur, will however, be unsuitable for root-end resection. A Lindemann H151 (Brasseler USA, Georgia, USA) is a tapered steel surgical bur with widely spaced flutes and has been recommended by several authors for both osteotomy and root-end resection.<sup>24,27</sup> The selected bur should run parallel to the surface of the cortical plate with a light brushing action to reduce friction.<sup>27</sup>

A sharp bone curette is then used for surgical curettage of peri-radicular soft tissue lesions, which can then be saved as a biopsy to be sent for histopathological examination.<sup>22</sup>

## ROOT-END RESECTION

The complex apical portion of the root canal system harbours microorganisms, unless it has been accessed by root canal instruments and chemically disinfected.<sup>7</sup> This nidus of infection is removed by resecting the apical 3mm of the root.<sup>7</sup> Indications for root-end resection include:<sup>28</sup>

1. Removal of pathologic processes such as foreign bodies, retained micro-organisms or firmly attached soft tissue lesion.
2. In order to remove anatomic variations, at least 3mm of the root apex should be removed, as 93% of lateral canals and 98% of apical ramifications are located within that length.<sup>9</sup>
3. Removal or management of iatrogenic errors such as separated instruments, ledges, blockages, zips and perforations.
4. To enhance the removal of deeply placed soft tissue lesions.
5. To gain access to the root canal system that is inaccessible via orthograde treatment, and to inspect the apical seal or lack thereof.
6. To create an adequate apical seal by enhancing access and vision.

7. Reducing fenestrated root apices.
8. Evaluation of aberrant canals and root fractures by staining.

The process of resection may be carried out using a 170L tapered fissure bur in an Impact Air 45 turbine.<sup>10</sup>

### BEVEL ANGLE

Traditionally a bevel angle of 45-60° was advocated for the convenience of the operator so that the apex could be visualised and accessed for root-end preparation.<sup>9</sup> The modern technique advocates that the root-end be resected perpendicular to the root, resulting in a 0-100° bevel angle.<sup>7,9</sup> The advantages of not creating a bevel are that greater root length is preserved, and less dentinal tubules are cut, thereby reducing the leakage of microbes and their by-products from the root canal system.<sup>7,29</sup>

Further disadvantages of creating a bevel are the creation of a larger osteotomy, lingually positioned apices are missed, the root canal is elongated and the root is weakened because its diameter is reduced.<sup>9</sup>

### Inspection of the resected root-end

At this point the resected root-end is stained with methylene blue dye and inspected using the surgical operating microscope and micro-mirrors for isthmuses and for determining the canal morphology.<sup>9,10</sup> This step was completely neglected during the traditional endodontic surgical techniques.<sup>9</sup> Methylene blue (Vista Dental, USA) (Figure 15) has the ability to stain organic material only, and therefore demonstrates fractures, accessory canals, isthmus tissue and the periodontal ligament.<sup>28</sup>

The methylene blue should be applied for 10-15 seconds to allow its complete saturation, after which the surface should be rinsed and dried for inspection.<sup>28</sup>

### ROOT-END CAVITY PREPARATION

The aim of preparing a root-end cavity is to remove root canal filling material and to create a cavity that can be adequately filled.<sup>9</sup> The prerequisites for root-end cavity preparation include:<sup>9,28</sup>

1. A thoroughly cleaned and shaped Class 1 cavity at least 3 mm deep into the root-canal system.
2. The walls of the preparation should be parallel to and coincident with the outline of the root canal space.
3. There should be adequate retention for the root-end filling.
4. Isthmus tissue should be completely removed.
5. The remaining dentinal walls should not be weakened.

Traditionally the root-end cavity was prepared using rotary burs in a micro-handpiece.<sup>9</sup> The disadvantages of using these instruments to prepare the root-end cavity are:<sup>9</sup>

1. Accessing the root-end is challenging, especially when working space is limited.
2. The risk of perforation of the lingual root-end is high when the original pathway of the canal is not followed.
3. The 45 degree bevel required during resection exposes too many dentinal tubules.
4. Difficult to clean necrotic tissue in the isthmus area between canals.

In the early 1990's, Dr Gary Carr introduced specifically angulated ultrasonic retrograde tips for root-end cavity preparation.<sup>16</sup> The modern technique for preparing a root-end cavity involves the use of ultrasonic tips designed for anterior (Figure 16) and posterior teeth, driven by a piezoelectric hand piece.<sup>10</sup> There are a variety of ultrasonic retrograde tips available to favour different surgical access situations.

The advantages of using ultrasonic tips rather than burs for cavity preparation include:

1. The apical preparation is deeper, cleaner and runs parallel to the long axis of the root.<sup>30</sup>
2. The operator experiences superior control with ultrasonic tips.<sup>10</sup>
3. There is a lower risk of root perforation due to a greater ability to

stay central within the canal.<sup>31</sup>

4. The access to the root tip is easier.<sup>10</sup>
5. Preparation of the isthmus area between canal exits is easier.<sup>10</sup>

### ROOT-END FILLING

The prepared root-end cavity is filled with a root-end filling material



Figure 15: Methylene blue solution that can be used to define fractures, accessory canals, isthmus tissue and the periodontal ligament.

in order to provide a hermetic physical seal, thereby preventing the




Figure 16: ProUltra Surgical Ultrasonic Tips (no.1 and 2) (Dentsply Sirona).

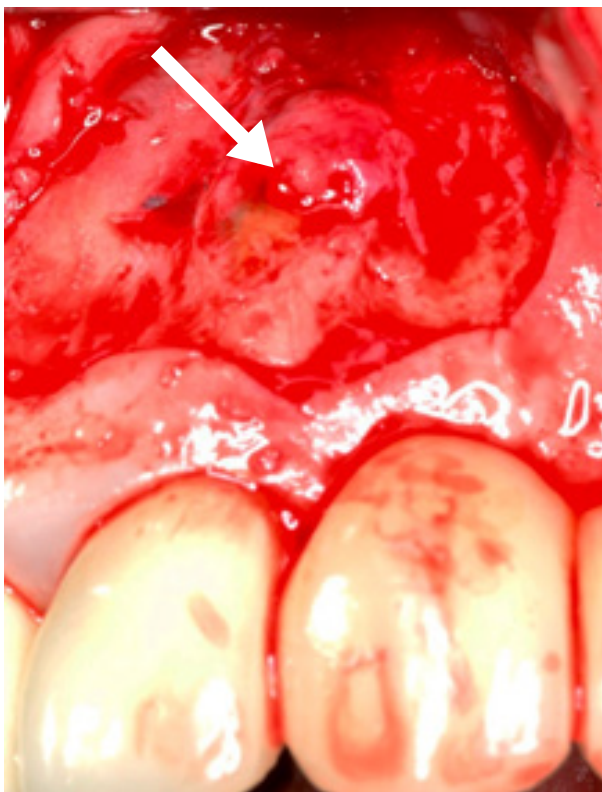egress of micro-organisms or their by-products from the root canal

system into the peri-radicular tissues.<sup>32</sup> Peri-radicular curettage alone, without root-end filling, eliminates only the effect of the leakage from the root canal system into the surrounding tissues, but not the cause, as most periapical lesions are caused by a leaky apical seal.<sup>9</sup> In order to ensure that healing that may occur does not regress, the root canal system should be resealed with an appropriate root-end filling. The materials that can be used include: Amalgam, Gutta-percha, Cavit, glass-ionomer cements, re-reinforced zinc oxide eugenol cements, composite resin, compomer, gold foil, Diaket, polycarboxylate cement, and bioceramic cements. All these materials will be discussed in detail in Part 2 of this series.

### Case Report Outlining the Clinical Technique

One of the main causes of failure after endodontic surgery is the failure to hermetically seal all the portals of exit,<sup>3</sup> often the result of inadequate lighting, visibility and technique.<sup>18</sup>

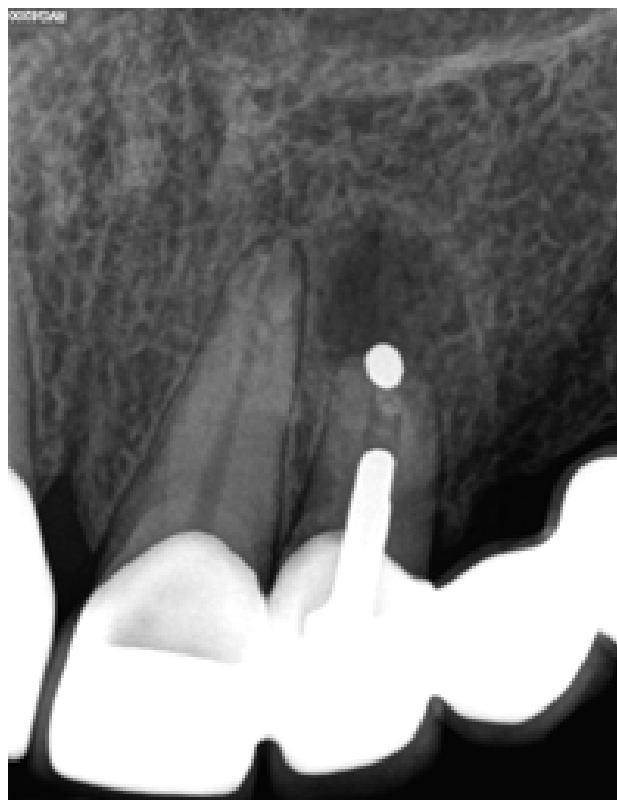Figure 17 illustrates a periapical radiograph of a failing apicoectomy on a right maxillary lateral incisor of a 45 year old female patient, three years after surgery. The tooth is part of a six-unit fixed bridge. It was evident that an amalgam retrograde was placed, but the surgeon failed to remove all the bacteria from the entire root canal system before placing the retrograde filling material. Several authors have confirmed that if the root canal space is not completely instrumented or inadequately treated, the outcome will be poor.<sup>34,35</sup> After anaesthesia, a submarginal flap was designed and the flap reflected using a micro-scalpel and micro-surgical elevators, under 10X magnification. Figure 18 depicts the clinical view after atraumatic reflection of the flap and clearly shows evidence of a large periapical



**Figure 18:** Evidence of a large periapical granuloma or cystic lesion (arrow) associated with the apex of the right maxillary lateral incisor.

Carr and Castellucci (2009) there is no longer any valid reason for using amalgam as a retrograde filling material due to the general controversy over the presence of mercury in amalgam.<sup>18</sup> Furthermore, amalgam is prone to corrosion and disintegration, can cause amalgam tattooing if excess particles are incorporated into the soft tissue, and the healing characteristics following an amalgam root-end filling are questionable.<sup>7,32</sup>

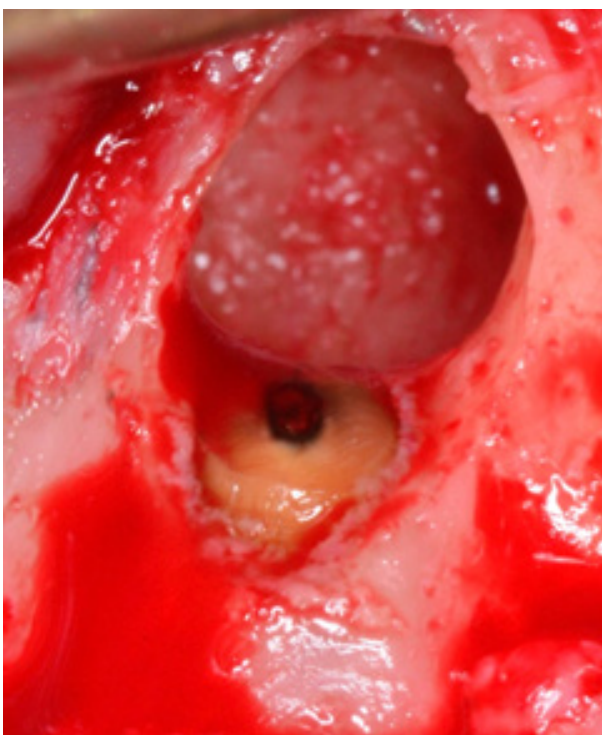
Upon inspection, it was found that the amalgam retrograde filling



**Figure 17:** Periapical radiograph of a failing apicoectomy on a right maxillary lateral incisor. Note the large periapical radiolucency and empty canal space between the metal post and the amalgam retrograde filling.

granuloma or cystic lesion associated with the apex of the tooth. mented or inadequately treated, the outcome will be poor.<sup>34,35</sup>

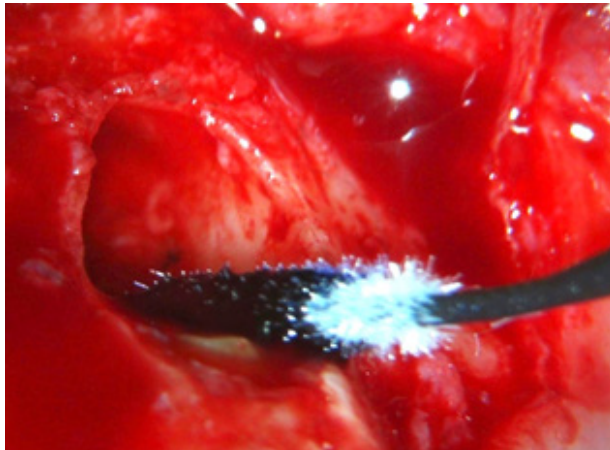
Periradicular curettage was done with a periodontal curette to remove the tissue for biopsy and to expose the root apex. Figure 19 shows the exposed root tip with evidence of a leaking retrograde amalgam filling with surrounding corrosion, at the apex of the root tip. Several studies indicate that amalgam retrograde performs consistently the poorest in leakage studies.<sup>36,37</sup> According to



**Figure 19:** Exposed root tip with evidence of a leaking retrograde amalgam filling with surrounding corrosion.

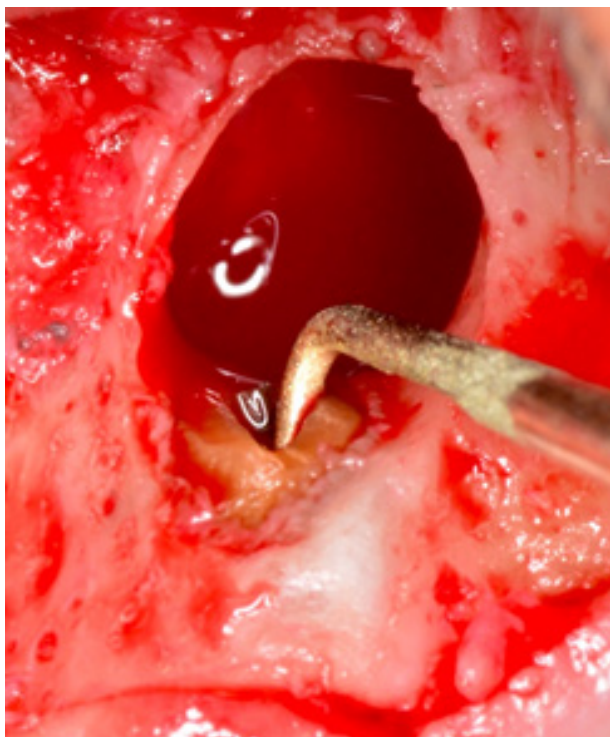was completely loose, and it was removed. The bevel on the root apex was redefined with a 171 carbide tapered fissure bur before the exposed root tip was dried, covered with methylene blue solution (Figure 20) and left for 30 seconds. The dye was gently removed by flushing sterile water over the area. There was no indication of a crack in the root.

An ultrasonic root end preparation (UREP) was done using the



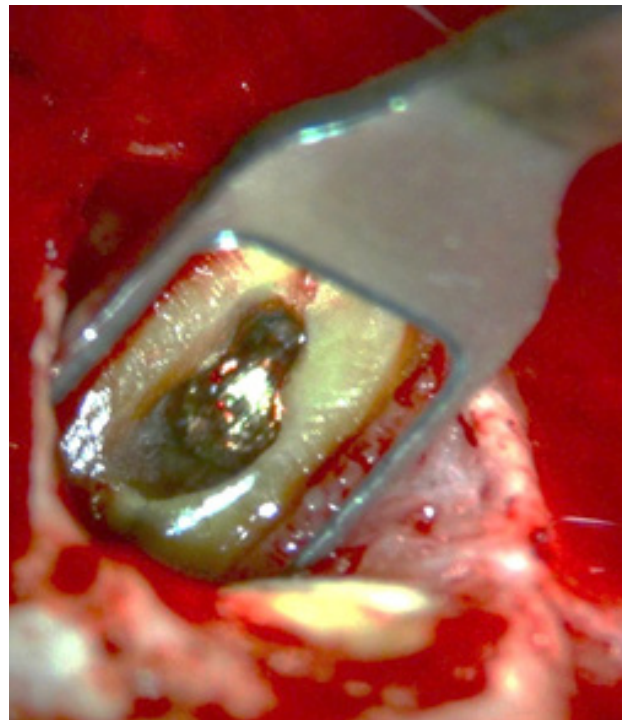
**Figure 20:** Application of methylene blue solution to the root tip.

ProUltra no.2 Surgical Ultrasonic Tip (Dentsply Sirona) (Figure 21) driven by an ultrasonic scaler (Satelec). These tips utilize port technology to deliver a constant stream of water directly to the working end of the tip. The design of the tips also ensures excellent vision for the operator during the cavity preparation under the DOM. The UREP was thoroughly rinsed with water, and dried with paper points.



**Figure 21:** ProUltra no. 2 Surgical Ultrasonic Tip (Dentsply Sirona) driven by an ultrasonic scaler (Satelec) was used to prepare the root end preparation.

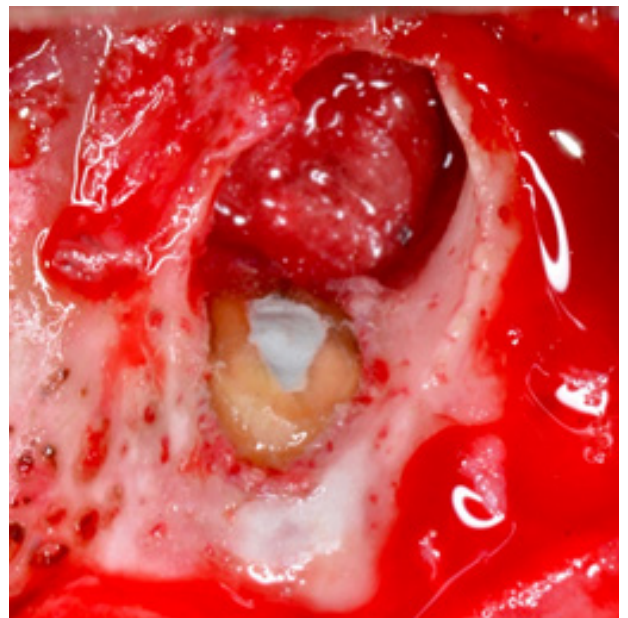A micro-mirror was used to inspect the UREP under different magnifications, to ensure complete removal of any remaining debris in the cavity (Figure 22). Finally, the UREP was etched with 37% phosphoric acid and rinsed with water to remove the smear layer. (Ultradent) material was mixed according to the manufacturer's instructions and loaded into a skinny syringe. The mixed material was directly dispensed into the UREP and excess material was removed to the level of the resected root.



**Figure 22:** Reflection in a micro-mirror of the prepared UREP showing the preparation up to the level of the gold post inside the root canal.

MTA Flow (Ultradent) material was mixed according to the manufacturer's instructions and loaded into a skinny syringe. The mixed material was directly dispensed into the UREP and excess material was removed to the level of the resected root (Figure 23).

Figure 24 shows the immediate postoperative radiographic result after closing and suturing of the soft tissue flap.



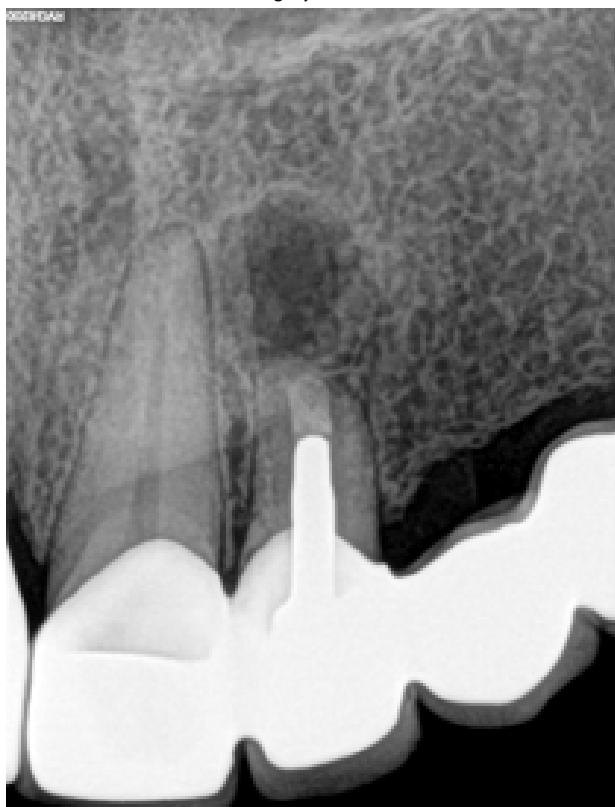
**Figure 23:** MTA Flow (Ultradent) material directly dispensed into the UREP and excess material removed to the level of the resected root.

## CONCLUSION

Tsesis et al. (2009) carried out a meta-analysis of the literature, and found that when the modern endodontic surgical technique is used, a successful outcome was achieved in 91.6% of cases more than one year postoperatively.<sup>38</sup>

Setzer et al. (2010) conducted a similar study of the literature, comparing the traditional root-end surgery technique with the modern endodontic microsurgery technique. The weighted pooled

success rates were 59% for traditional root-end surgery, and 94% for modern endodontic microsurgery.<sup>39</sup>



**Figure 24:** Periapical radiograph showing the immediate postoperative result. Note the placement of the MTA Flow right up to the post in the canal.

Endodontic surgery using modern surgical techniques and appropriate armamentarium and root-end filling materials significantly improves the treatment outcome compared with the traditional technique.

#### References

1. Kakehashi S, Stanley HR, Fitzgerald RJ. The effects of surgical exposures of dental pulps in germ-free and conventional laboratory rats. *Oral Surg Oral Med Oral Pathol.* 1965; 20: 340-9.
2. Nair PN. Pathogenesis of apical periodontitis and the causes of endodontic failures. *Crit Rev Oral Bio Med.* 2004; 15: 348-81.
3. Torabinejad M, Watson TF, Pitt Ford TR. Sealing ability of a mineral trioxide aggregate when used as a root end filling material. *J Endod.* 1993; 19: 591-5.
4. Siqueira JF, Jr. Aetiology of root canal treatment failure: why well-treated teeth can fail. *Int Endod J.* 2001; 34: 1-10.
5. Ruddle CJ. Non-surgical endodontic retreatment. *J Calif Dent Assoc.* 2004; 32: 474-84.
6. Von Arx T. Failed root canals: the case for apicoectomy (peri-radicular surgery). *J Oral Maxillofac Surg.* 2005; 63: 832-7.
7. Chong BS, Rhodes JS. Endodontic surgery. *Br Dent J.* 2014; 216: 281-90.
8. Castellucci A. Advances in surgical endodontics. *L'Informatore Endodontico.* 2003; 6: 1-16.
9. Kim S, Kratchman S. Modern endodontic surgery concepts and practice: a review. *J Endod.* 2006; 32: 601-23.
10. Rubinstein, Torabinejad M. Contemporary endodontic surgery. *J Calif Dent Assoc.* 2004; 32: 485-92.
11. Patel S, Dawood A, Pitt Ford TR, Whites E. The potential applications of cone beam computed tomography in the management of endodontic problems. *Int Endod J.* 2007; 40: 818-30.
12. Patel S. New dimensions in endodontic imaging: Part 2. Cone beam computed tomography. *Int Endod J.* 2009; 42: 463-75.
13. Mozzo P, Procacci C, Tacconi A, Tinazzi Martini P, Bergamo Andreis IA. A new volumetric CT machine for dental imaging based on the cone-beam technique: preliminary results. *Eur. Radiol.* 1998; 8: 1558-64.
14. Tsurumachi T, Honda K. A new cone beam computerized tomography system for use in endodontic surgery. *Int Endod J.* 2007; 40: 224-32.
15. Kazuhiko Nakata, Munetaka Naitoh, Masahiro Izumi, Kyoko Inamoto, Eiichi Aiji, Hiroshi Nakamura. Effectiveness of dental computed tomography in diagnostic imaging of peri-radicular lesion of each root of a multirrooted tooth: A case report. *J Endod.* 2006; 32 : 583-7.
16. Carr GB. Microscopes in endodontics. *J Calif Dent Assoc.* 1992; 20: 55-61.
17. Rubinstein R. Magnification and illumination in apical surgery. *Endod Topics.* 2005; 11: 56-77.
18. Carr B, Castellucci A. The use of the operating microscope in endodontics. *Endodontics Volume III, 2009, IL Tridente, Florence, Italy.*
19. Kenneth M, Hargreaves, Khan Asma. Surgical preparation: anesthesia & hemostasis. *Endod Topics.* 2005; 11: 32-55.
20. Velvart P, Peters Christine I, Peters, Ove A. Soft tissue management: flap design, incision, tissue elevation and tissue retraction. *Endod Topics.* 2005; 11: 78-97.
21. Velvart P, Peters Cl. Soft tissue management in endodontic surgery. *J Endod.* 2004; 31(1): 78-97.
22. Gutmann JL, Gutmann MS. Historical perspectives on the evolution of surgical procedures in endodontics. *J Hist Dent.* 2010; 58: 1-42.
23. Stropko JJ. Microsurgical Endodontics. *Endodontics Volume III, 2009, IL Tridente, Florence, Italy.*
24. Hoskinson AE. Hard tissue management: osseous access, curettage, biopsy and root isolation. *Endod Topics.* 2005; 11: 98-113.
25. Rubinstein R, Kim S. Short-term observation of the results of endodontic surgery with the use of a surgical operation microscope and super-EBA as root-end filling material. *J Endod.* 1999; 25: 43-8.
26. Eriksson AR, Albrektsson T. Temperature threshold levels for heat-induced bone tissue injury: a vital-microscopic study in the rabbit. *J Prosthet Dent.* 1983; 50: 101-7.
27. Gutman JL, Harrison JW. Posterior endodontic surgery: anatomical considerations and clinical techniques. *Int Endod J.* 1985; 18: 8-34.
28. Stropko JJ, Doyon GE, Gutmann JL. Root-end management: resection, cavity preparation, and material placement. *Endod Topics.* 2005; 11: 131-51.
29. Gilheany PA, Figdor D, Tyas MJ. Apical dentin permeability and microleakage associated with root end resection and retrograde filling. *J Endod.* 1994; 20: 22-6.
30. Wuchenich G, Meadows D, Torabinejad M. A comparison between two root end preparation techniques in human cadavers. *J Endod.* 1994; 20: 279-82.
31. Engel TK, Steiman HR. Preliminary investigation of ultrasonic root end preparation. *J Endod.* 1995; 21: 443-5.
32. Chong BS, Pitt Ford TR. Root-end filling materials: rationale and tissue response. *Endod Topics.* 2005; 11: 114-30.
33. Sommer RF. Essentials for successful root resection. *Am J Ortho. Oral Surg.* 1946; 3: 76-100.
34. Gutmann JL, Harrison JW. *Surgical Endodontics*, Boston, Blackwell Scientific Publications. 1991.
35. Ibarrola J, Knowles K, Ludlow M, McKinley B Jr. Factors affecting the negotiability of second mesiobuccal canals in maxillary molars. *J Endon.* 1997; 23: 236-8.
36. Aqrabwi J. Sealing ability of amalgam, super EBA cement and MTA when used as retrograde filling materials. *Br Dent J.* 2000; 188: 266-8.
37. Seedat HC; Van Der Vyver PJ. An *in-vitro* comparison of microleakage between three calcium silicate cements and amalgam. *SADJ.* 2016; 71:100-5.
38. Tsesis I, Faivishevsky V, Kfir A, Rosen E. Outcome of surgical endodontic treatment performed by a modern technique: a meta-analysis of literature. *J Endod.* 2009; 35: 1505-11.
39. Setzer FC, Shah SB, Kohli MR, Karabucak B, Kim S. Outcome of endodontic surgery: a meta-analysis of the literature--Part 1: Comparison of traditional root-end surgery and endodontic microsurgery. *J Endod.* 2010; 36: 1757-65.

new



**SENSODYNE** **RAPID RELIEF**

Fast relief in just 60 seconds

References: 1. Aaby M. *Int J Dent* 2002; 32:367-375. 2. [GSK Data on File 2017211](#). May 2017. 3. Accepted for presentation WDR2017, Montreal, 2020505. 4. [Parkinson CP et al. \*Am J Dent\* 2015 Aug 28;16\(10\):190-195](#). 5. [GSK Data on File 19431007](#). 6. To achieve research December 2016. For any product safety

Help patients **BEAT SENSITIVITY PAIN FAST**

**SENSODYNE** **RAPID RELIEF**

\*With twice-daily brushing

**No.1 DENTIST RECOMMENDED BRAND FOR SENSITIVE TEETH\***

As many as 1 in 3 people suffer from dentine hypersensitivity\*. **New Sensodyne Rapid Relief is clinically proven to deliver fast relief in just 60 seconds\*\* and long-lasting protection\*** from dentine hypersensitivity\*, helping to bring everyday improvements to your patients' lives.\*

gsk