Short communication

Ultrastructure of the Tubular Glands in the Isthmus region of the oviduct in Laying and Natural Molting Commercial Egg-Type Chickens

M.-C. Madekurozwa* and M.M. Mpango

Department of Anatomy and Physiology, University of Pretoria, Private bag X04, Onderstepoort 0110, South Africa.

*Correspondence:

Tel.: +27 12 529 8417; fax: +27 12 529 8320; e-mail: mary.madekurozwa@up.ac.za

With 4 figures.

Short version of title: Isthmus region of the chicken oviduct

Key words: avian, tubular glands, isthmus, molt, autophagy, necrosis, ducts

Summary

The study investigated the ultrastructural characteristics of tubular gland and duct cells, as well as luminal gland cells in the isthmus region of the oviduct of laying and natural molting hens. Tubular glands in laying birds were composed of type 1 and 2 cells. Based on the preponderance of each cell type, in relation to the location of a developing egg in the oviduct of the domestic fowl, these gland cells may represent different functional states of the same cell. The findings of the study on natural molting

birds suggest that autophagy is a process confined to the early stages of degeneration, while necrosis occurs in the terminal stages.

1. Introduction

Tubular glands in the isthmus region of the oviduct are responsible for the secretion of a double-layered shell membrane around the developing egg (Draper *et al*., 1972). In comparison with the other regions of the oviduct relatively few ultrastructural studies have been conducted on the isthmus (Draper *et al*., 1972; Solomon, 1975). However, this oviductal region has been studied extensively using the light microscope (Draper *et al*., 1972; Heryanto *et al.,* 1997; Jeong *et al*., 2013; Madekurozwa, 2013).

Molting is typically defined as the seasonal loss and replacement of body feathers, a process accompanied by the partial or complete regression of the reproductive tract (Berry, 2003). In commercial poultry production, feed and water deprivation are used to induce molting, which results in a temporary cessation of egg production (Webster, 2003; McCowan *et al*., 2006). Although molting is an integral component of poultry production there is currently a gap in knowledge regarding the morphological changes occurring in the oviduct during this process. Thus, the purpose of the current study was to detail ultrastructural changes in isthmic tubular glands and their associated ducts during natural molting.

2. Materials and Methods

2.1. Animals and management

Twenty commercial type hens (Hy-line W36) were utilized in this study. This type of chicken reaches peak production at 32 weeks, while natural molting commences at 65-75 weeks of age (Hy-line W36 commercial layers management guide 2016). Ten 32-week-old laying and ten 75-week-old natural molting hens were selected. The molting birds were known to have ceased egg production for 7 days. Laying and molting hens were obtained from the same commercial farm, but were maintained in separate poultry houses. All birds were fed layers mash and maintained under a light regime of 16h light: 8 h dark from 30 weeks of age as recommended by the breeder company. The birds were killed by decapitation. All the procedures used in this study were approved by the Animal Ethics Committee of the University of Pretoria (approval number AEC V002/17).

2.2. Transmission electron microscopy (TEM)

Tissue samples collected from the middle region of the isthmus were immersion-fixed in 2.5% glutaraldehyde in 0.075M phosphate buffer (pH 7.4) for 24 hours. Thereafter, the tissue samples were processed routinely for TEM. Semi-thin sections (300 - 350 nm) were cut using a diamond knife and stained with toluidine blue. The semi-thin sections were then viewed under an Olympus BX-63 microscope connected to a computer. Ultra-thin sections (90 – 100 nm) were cut using a diamond knife, stained with lead acetate and counter stained with uranyl citrate. The sections were viewed with a Philips CM10 transmission electron microscope (FEI, The Netherlands).

3. Results

3.1. Cells of the tubular glands and their associated ducts

Tubular glands opened onto the luminal surface either directly or via short ducts in both laying and natural molting birds (Fig. 1). The ducts were formed by non-ciliated cells, which were ultrastructurally distinct from the cells forming the tubular glands and luminal epithelium. In laying birds duct cells typically contained an irregular-shaped euchromatic nucleus and accumulations of mitochondria (Figs 2a and b). In addition, electron dense bodies, presumed to be secretory granules (0.46 μm to 0.81 μm in diameter) dominated the supranuclear regions of these cells (Fig. 2b). In general, the electron density of the secretory granules appeared to be less than those in the luminal non-ciliated and tubular gland cells. Arising from the apical plasma membranes of the duct cells were microvilli which extended into the lumen of the duct.

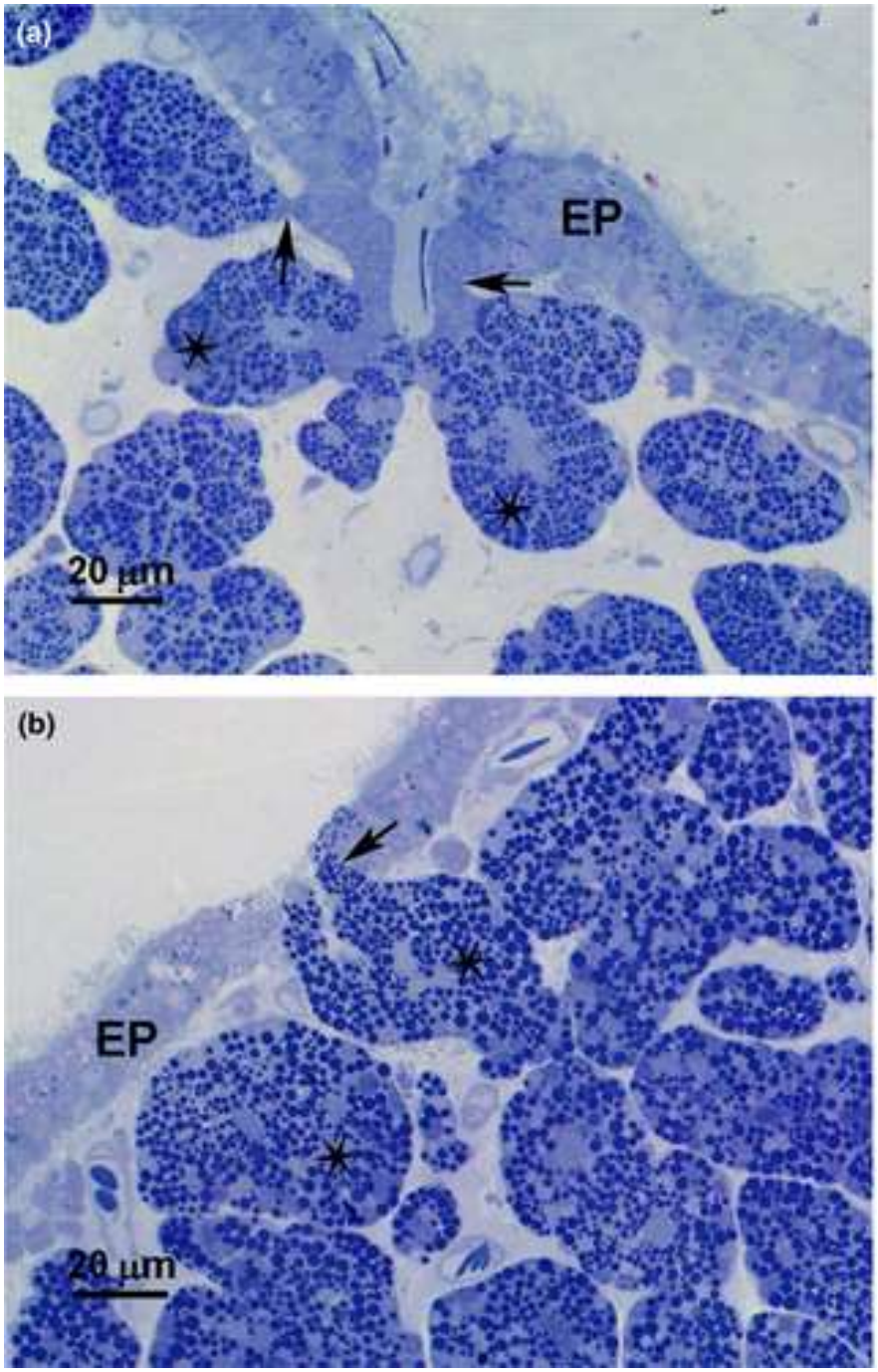

Figure 1. Light photomicrographs of toluidine blue-stained semi-thin sections of the isthmus in laying (A) and molting (B) birds.

A. EP: luminal epithelium. Arrows: ducts. Asterisks: tubular glands.

B. EP: luminal epithelium. Arrow: luminal gland cell. Asterisks: tubular glands.

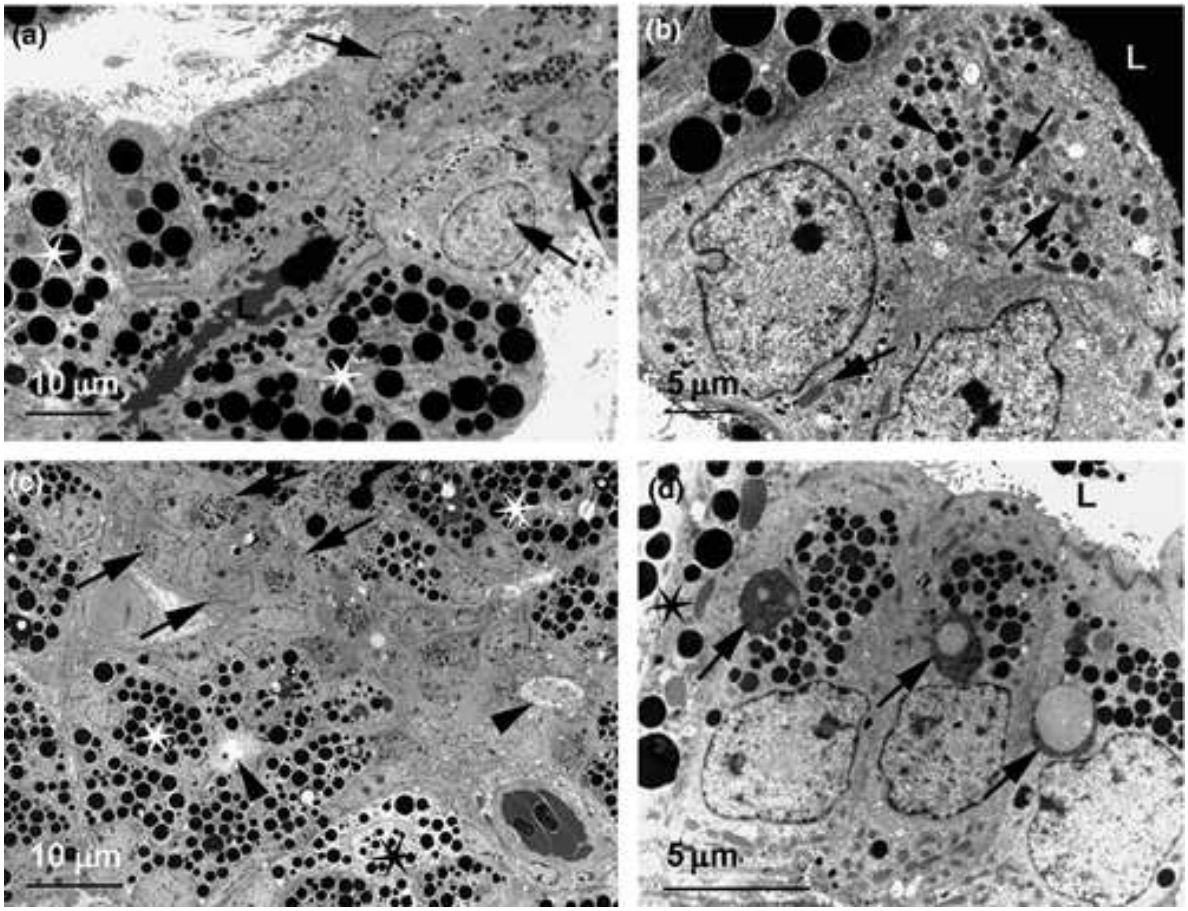

Figure 2. Electron photomicrographs of duct and tubular gland cells in laying (A-B) and molting (C-D) birds.

A. Arrows: duct cells. Asterisks: tubular gland cells. L: duct lumen.

B. L: duct lumen. Arrows: mitochondria. Arrowheads: secretory granules.

C. Arrows: duct cells. Asterisks: tubular gland cells. Arrowheads: lumina of tubular glands.

D. Arrows: autophagosomes in duct cells. Asterisk: tubular gland cell. L: duct lumen.

Ducts, composed of normal and regressing cells, connected tubular glands to the luminal surface in natural molting birds (Fig. 2c). Regressing duct cells were characterized by the presence of degenerating secretory granules and lipid droplet autophagosomes (Fig. 2d).

In laying birds, tubular glands were composed of two morphologically distinct types of cells (type 1 and 2). The basally-located nuclei in type 1 gland cells were round and euchromatic (Fig. 3a). The cytoplasm in these gland cells contained:

numerous secretory granules (1.50 μm to 2.30 μm in diameter) of various electron densities; elongated mitochondria and a few short profiles of rough endoplasmic reticulum (RER), which were distributed among the secretory granules. In contrast, type 2 gland cells contained a centrally-located euchromatic nucleus and a few secretory granules of predominantly intermediate electron density. Additionally, the cytoplasm in type 2 gland cells was dominated by numerous profiles of RER (Fig. 3a).

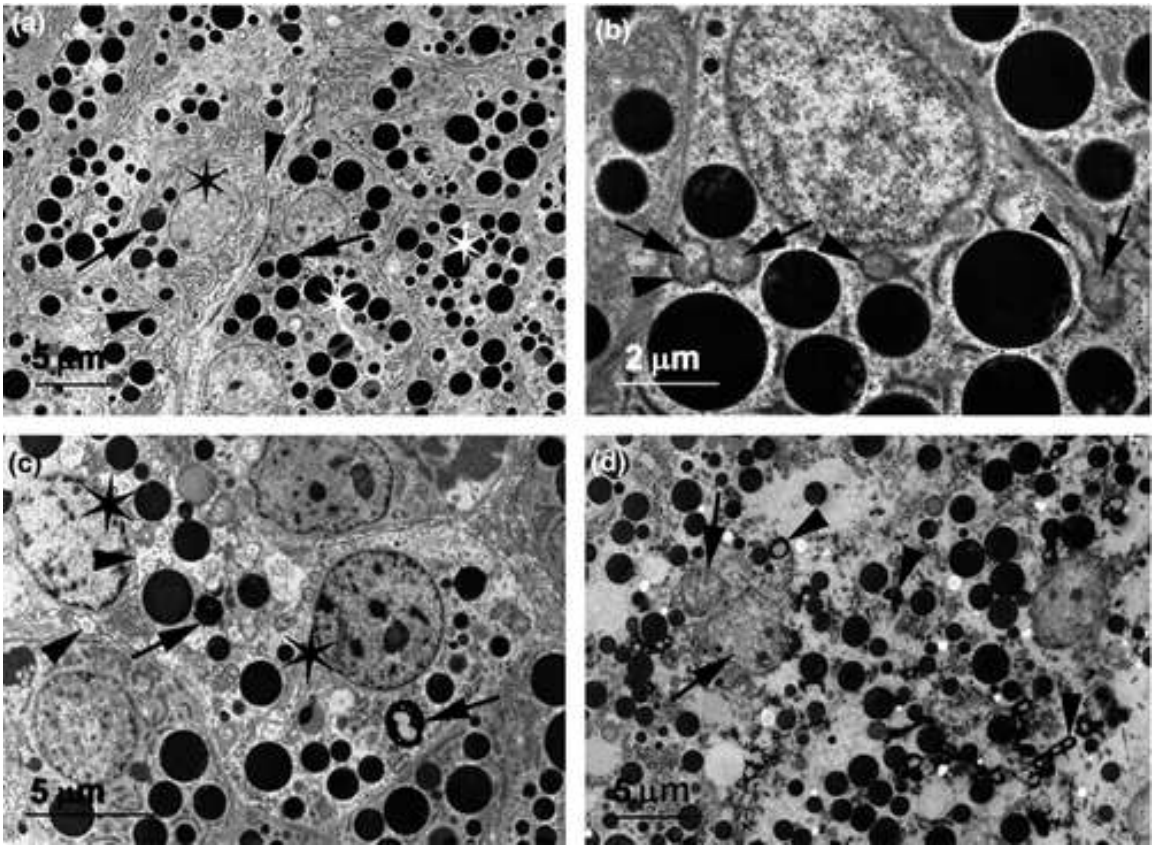

Figure 3. Electron photomicrographs of tubular gland cells in laying (A) and molting (C-D) birds.

A. Type 1 (white asterisks) and 2 (black asterisk) gland cells. Arrows: secretory granules. Arrowheads: RER cisternae.

B. Arrows: mitochondria. Arrowheads: RER cisternae.

C. The two cells indicated by asterisks lack intervening plasma membranes. Arrows: degenerating secretory granules. Arrowheads: dilated RER cisternae.

D. Note the absence of enclosing plasma membranes. Arrows: degenerating autophagosomes. Arrowheads: degenerating secretory granules.

Type 1 gland cells predominated when the developing egg was in the oviductal regions proximal to the isthmus. Conversely, more type 2 gland cells were observed when the developing egg either was in the isthmus or had passed through this oviductal region.

The entirety of tubular gland cells in the natural molting birds were classified as type 1 based on the presence of numerous electron dense secretory granules. The initial degenerative stages of the tubular gland cells were characterized by the progressive sequestration of swollen mitochondria by RER cisternae (Fig. 3b). In addition, autophagosomes were occasionally observed in these cells.

Gland cells in the intermediate stages of regression contained autolysosomes, degenerating secretory bodies, as well as dilated RER cisternae, with or without enclosed mitochondria. Occurrences of irregular-shaped nuclei with distinct perinuclear spaces, as well as the loss of lateral plasma membranes were common features of these cells (Fig. 3c).

The disintegration of apical, lateral, and basal plasma membranes occurred in the advanced stages of tubular gland degeneration. The regressing tubular gland mass contained degenerating autophagosomes, large vacuoles, as well as secretory granules displaying various degrees of degeneration (Fig. 3d).

3.2. Cells of the luminal glands

In addition to connecting to the lumen via ducts, some tubular glands opened directly onto the luminal surface in both laying and natural molting birds (Figs 1b and 4a). In these instances, tubular gland cells, herein referred to as “luminal gland cells”, intermingled with luminal epithelial cells (Fig. 4b).

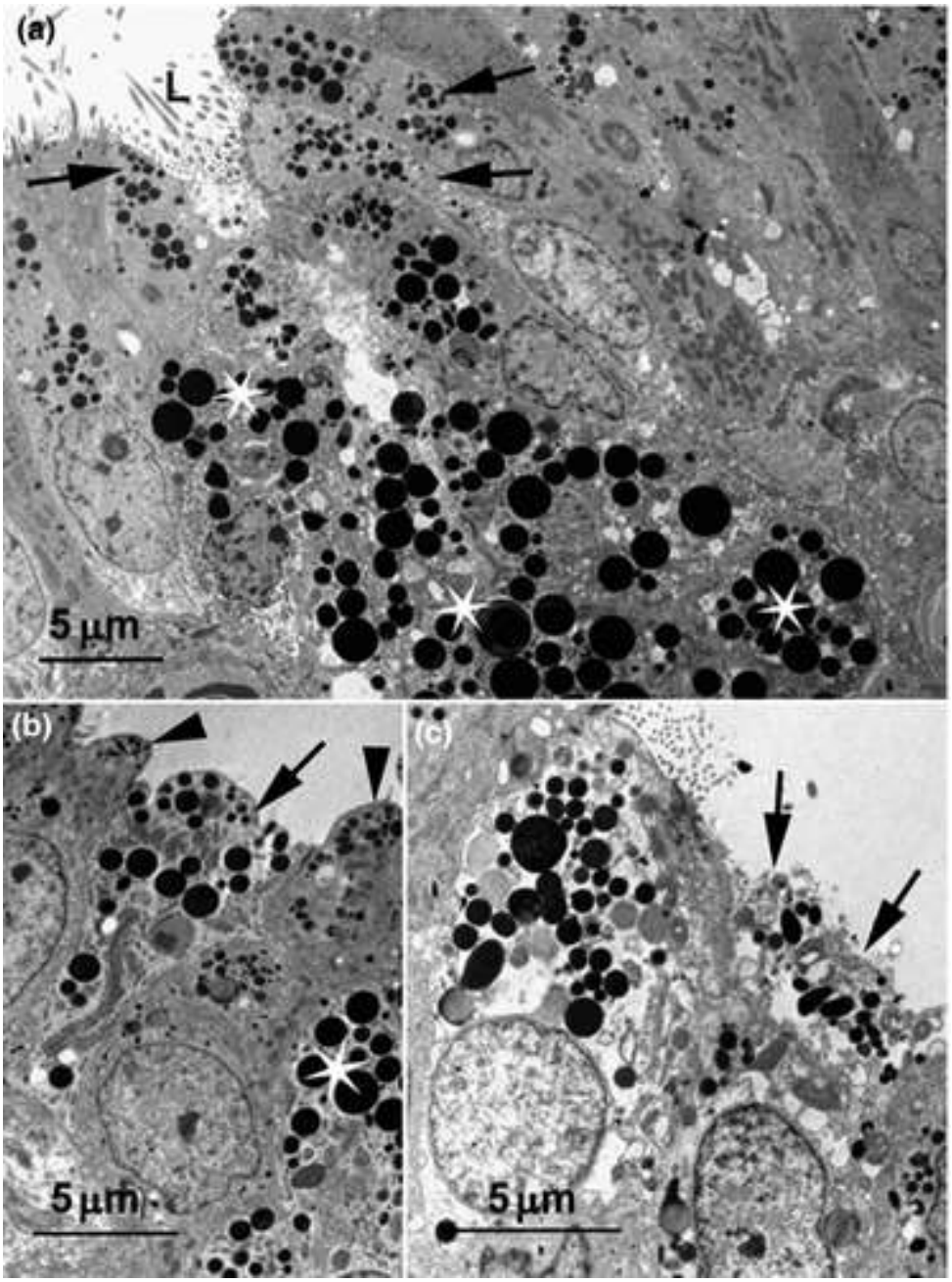

Figure 4. Electron photomicrographs of luminal and tubular gland cells in molting birds.

A. A tubular gland (asterisks) opening onto the luminal surface. Arrows: luminal non-ciliated cells. L: lumen of the isthmus.

B. Arrow: luminal gland cell. Arrowheads: luminal non-ciliated cells. Asterisk: tubular gland cell.

C. Arrows: ruptured apical surface membrane of a luminal gland cell.

Mitochondria, completely or partially surrounded by RER cisternae, were the most notable feature during the early stages of degeneration of the luminal gland cells

in natural molting birds. These cells also contained several lysosomes, lipid droplet autophagosomes and degenerating secretory granules (1.39 μm to 1.71 μm in diameter).

In the later stages of degeneration luminal gland cells contained euchromatic cytoplasm, swollen mitochondria, dilated RER cisternae and disintegrating secretory granules. Additionally, the presence of disrupted apical plasma membranes resulted in the release of cellular contents into the lumen of the isthmus (Fig. 4c).

4. Discussion

A study by Hoffer (1971) on the isthmus of the Japanese quail reported that as many as six tubular glands opened into short ducts, which were formed by invaginations of the luminal epithelium. However, a further investigation by Draper *et al*. (1972) refuted the presence of actual ducts, stating that the tubular glands opened directly onto the luminal surface. The descriptions of Hoffer (1971), as well as Draper and co-workers (1972) were based on light microscopic observations. The results of the current study, which were based on light and transmission electron microscopic observations, have shown that tubular glands open onto the luminal surface either directly, or via short ducts lined by non-ciliated cells. Furthermore, the results of the present study have shown that the cells forming the ducts are ultrastructurally distinct from isthmic non-ciliated luminal and tubular gland cells. Interestingly, the electron density of secretory granules in duct cells appeared to be lower than similar inclusions in both non-ciliated luminal and tubular gland cells. These findings may suggest that the secretory product of duct cells is different from that of non-ciliated luminal and tubular gland cells. However, additional studies are required to elucidate the biochemical composition of the secretory product in duct cells.

Regressing duct cells in natural molting birds contained lipid droplet autophagosomes, which were indicative of an autophagic process. Duct cells undergoing further stages of degeneration were not observed in the present study. This may have been due to samples being collected in the relatively early stages of molting.

Two forms of tubular gland cells, designated as types 1 and 2, were observed in the isthmus regions of laying hens sampled in the current study. In agreement with the observations of Solomon (1975), type 1 gland cells contained numerous secretory granules, while relatively few granules were observed in type 2 cells. Additionally, the preponderance and distribution of RER cisternae in type 1 and 2 cells differed (Solomon, 1975). Previous studies on tubular glands in the isthmus of the domestic fowl have shown that the ultrastructure of gland cells is influenced by the location of a developing egg in the oviduct (Draper *et al*. 1972; Solomon, 1975; Chousalkar and Roberts, 2008). The results of the current study concurred with these findings. Based on the findings of the present study and those of other authors (Draper *et al*. 1972; Solomon, 1975), it is likely that the ultrastructural appearance of type 2 cells is realized after type 1 cells have released secretory product into the glandular lumen.

In natural molting birds used in the present study, autophagy occurred during the early stages of degeneration of tubular gland cells, while necrosis was identified in the intermediate and advanced phases. This is contrary to the findings of studies by Heryanto *et al*. (1997), as well as Jeong and co-workers (2013) in which degeneration was heralded by the occurrence of apoptosis.

In the current study, a complete disintegration of apical and lateral plasma membranes occurred in the advanced stages of regression resulting in the extrusion of cellular components into the stroma. It is known that advanced stages of necrotic

cell death involve the lysis of plasma membranes and the subsequent release of cellular debris into the surrounding connective tissue (Majno and Joris, 1995; Trump *et al*., 1997; Elmore, 2007).

In the current investigation tubular glands opened onto the luminal surface either directly or via a duct. In the former instances degenerating luminal gland cells were observed among the typical cells of the luminal epithelium. The ultrastructural features displayed by these cells in the early stages of degeneration were in accordance with the typical characteristics of autophagy (Spornitz *et al*.,1994). Noteworthy among these autophagic features were the presence of mitochondria partially or completely enclosed by RER cisternae. The presence of dilated RER cisternae, swollen mitochondria and a disrupted apical plasma membrane were in accord with the classic characteristics of necrosis (Edinger and Thompson, 2004; Elmore, 2007). Thus, it is suggested that the advanced stages of regression in luminal gland cells occur via necrosis.

In conclusion, the results of this study suggest that the cell death processes of autophagy and necrosis are involved in the involution of tubular glands in the isthmus during natural molting. Further research in chickens, utilizing immunohistochemistry and molecular biology, is required to consolidate the aforementioned assumption.

Acknowledgements

The authors thank Antoinette Buys for her technical assistance. This study was funded by the National Research Foundation of South Africa (grant #N00188).

References

Berry, W.D., 2003: The physiology of induced molting. Poult. Sci. **82,** 971-980.

Chousalkar, K.K., J.R. Roberts, 2008: Ultrastructural changes in the oviduct of the laying hen during the laying cycle. Cell Tiss. Res. **332,** 349-358.

Draper, M.H., M.F. Davidson, G.M. Wyburn, and H.S. Johnston, 1972: The fine structure of the fibrous membrane forming region of the isthmus of the oviduct of *Gallus domesticus*. Quart. J. Exp. Physiol. **57,** 297-309.

Edinger, A.L. and C.B Thompson, 2004: Death by design: apoptosis, necrosis and autophagy. Curr. Opinion Cell Biol. **16,** 663-669.

Elmore, S., 2007: Apoptosis: a review of programmed cell death. Toxicol. Path. **35,** 495-516.

Heryanto, B., Y. Yoshimura, T. Tamura, and T. Okamoto, 1997: Involvement of apoptosis and lysosomal hydrolase activity in the oviducal regression during induced molting in chickens: a cytochemical study for end labeling of fragmented DNA and acid phosphatase. Poult. Sci. **76,** 67-72.

Hoffer, A.P., 1971: The ultrastructure and cytochemistry of the shell membrane-secreting region of the Japanese quail oviduct. Am. J. Anat. **131,** 253-287.

Hy-line International, Management guide. W-36 commercial layers. 2016. www.hyline.com

Jeong, W., W. Lim, S.E. Ahn, C-H. Lim, J-Y. Lee, S-M. Bae, J. Kim, F.W. Bazer, and G. Song, 2013: Recrudescence mechanisms and gene expression profile of the reproductive tracts from chickens during the molting period. PLOS one. 8, e76784.

Madekurozwa, M.-C., 2013: An immunohistochemical study of the oviduct in the domestic fowl (*Gallus domesticus*). Anat. Histol. Embryol. **42,** 48-56.

Majno, G., I. Joris, 1995: Apoptosis, oncosis and necrosis: an overview of cell death. Am. J. Pathol. **146,** 3-15.

McCowan, B., J. Schrader, A.M. Di Lorenzo, C. Cardona, and D. Klingborg, 2006: Effects of induced molting on the well being of egg-laying hens. J. Appl. Ani. Welfare Sci. **9,** 9-23.

Solomon, S.E., 1975: Studies on the isthmus region of the domestic fowl. Br. Poult. Sci. **16,** 255-258.

Spornitz, U.M., B.P. Rinderknecht, A. Edelmann, B. Scheidegger and F. Cairoli, 1994. Ultrastructure as a basis for dating of rat endometrium. Anat. Rec. **238,** 163-176.

Trump, B.F., I.K. Berezesky, S.H. Chang, P.C. Phelps, 1997: The pathways of cell death: oncosis, apoptosis and necrosis. Toxicol. Pathol. **25,** 82-88

Webster, A.B., 2003: Physiology and behaviour of the hen during induced molt. Poult. Sci. **82,** 992-1002.