Onderstepoort Journal of Veterinary Science and Animal Industry, Volume 23, Numbers 1 and 2, March, 1948.

Printed in the Union of South Africa by the Government Printer, Pretoria.

Cytauxzoon sylvicaprae gen. nov., spec. nov., a Protozoon Responsible for a Hitherto Undescribed Disease in the Duiker [*Sylvicapra grimmia* (Linné)].

By W. O. NEITZ, Section of Protozoology and Virus Diseases, and A. D. THOMAS, Section of Pathology, Onderstepoort.

Introduction.

On the 6th of March, 1943, a two year old duiker (*Sylvicapra grimmia*) which had been born and bred in captivity was brought to Onderstepoort for treatment. The owner stated that five years previously she had obtained a pair of duikers from the Vryburg district in the Cape Province. They were placed in a well-fenced paddock at the foot of the Magaliesberg not far from the Wonderboon Nature Reserve in the Pretoria District. The buck adapted themselves well to their new surroundings and each year a lamb was born. No difficulty was experienced in rearing the progeny. At the beginning of 1942, however, one of the young duikers died after having been sick for several days. It was stated that the cause of death was bronchopneumonia, which had resulted from grass-seeds penetrating into the thoracic cavity.

The duiker now presented was the second to sicken and had shown inappetence and listlessness for the past fortnight or so. A few days before it was admitted it became very weak, lying down all the time and on the day it arrived it was in a semi-comatose state. The breathing was slow and laboured, the heart-beat slow and weak, the pulse (femoral artery) hardly perceptible, the eyes sunken, the conjunctiva dark red in colour and the temperature 102·4° F. The eyelids and eyes showed a peculiar trembling and twitching often associated with heartwater.

A tentative diagnosis of heartwater was made, as it was known that this disease had caused the death of several springbuck [*Antidorcas marsupialis* (Zimm.)], on the Springbokflats in the Northern Transvaal (Neitz, 1944). In order to confirm this diagnosis the duiker was bled and 7·5 c.c. of blood was injected intravenously into two sheep susceptible to heartwater. The flow of blood from the jugular vein was extremely slow and great difficulty was experienced in collecting 15·0 c.c. of blood. Although it was quite evident that the duiker would die an attempt at treatment was made and 10 c.c. of a 10 per cent. solution of sodium uleron was administered intravenously. The next morning the animal was dead.

Laboratory Examination.

(a) *Post-Mortem Findings.*

The following changes were recorded: The lungs contained a larger amount of blood than usual, the organ being soft, inelastic and even friable. There was no increase of fluid either in the pericardial sac, the thoracic or peritoneal cavity. The liver was somewhat enlarged, greyish-yellow in colour with deep red mottling in the substance and under the capsule. The consistence was firm. The organ obviously looked abnormal and a pathological-anatomical diagnosis of hepatitis was made without hesitation. The bile ducts were patent and apparently normal (duikers have no gallbladder). The spleen was enlarged, the edges rounded, the capsule tense, the pulpa soft and dark bluish-black in colour. The kidneys had a purplish colour throughout and the zones were very indistinct. The wall of the abomasum including the mucous membrane was swollen and dark red in colour. The whole of the intestine was empty, but the mucosa and wall were swollen and had a deep red colour, so much so that a diagnosis of an acute gastro-enteritis was made at the time. It will be seen below that these changes were due to a passive engorgement of the splanchnic organs and not primarily to an inflammatory process.

Specimens collected included only the following organs: Liver, spleen, lung, kidney, brain, abomasum, intestine and heart. Smears were prepared from the blood, the endothelial cells of the jugular vein and from several of the mentioned organs.

(b) *Histological Examination.*

On examining the smears it was realized immediately that the tentative diagnosis of heartwater made clinically was incorrect. *Rickettsia ruminantium* Cowdry, 1925 could not be demonstrated in the intima smears prepared from the jugular vein and in sections from the brain. Furthermore the two sheep which received the duiker blood remained healthy for a period of two months. Blood smears from them were examined periodically but remained negative.

The organ and blood smears as well as the histological sections, on the other hand, showed the presence of parasites which resembled *Theileria parva* (Theiler, 1904). However, on closer examination it was found that the micro-organisms did not parasitize the lymphocytes, and that they did not belong to the genus *Theileria*, Bettencourt, Franca and Borges, 1907, but appeared to be a hitherto undescribed genus. In order to gain a clear conception of the developmental cycle of this parasite the histological findings will be described first.

1. *Blood Vessels.*

The most obvious and striking feature first noticed in the organs examined was the presence in the blood vessels of large multinucleated syncytial masses or aggregations of protoplasm (Figs. 4 and 5). In general they were attached to the inner wall of the vessel either by a broad base or by narrow stalks or even by thin strands. Most of them were elongated, and tailed off within the vessel lumen to a rounded or to a pointed free end, floating in the blood stream (Figs. 3, 4 and 5). They were found mostly in the arteries, in the pulmonary arteries, in the portal veins, and to a lesser extent in the systemic veins and capillaries. Unfortunately the larger arterial and venous trunks were not available for examination.

Measurement on the fixed, cut and stained preparations can give only a rough approximation of the size of these bodies, since it was difficult to establish when selected ones were cut along their entire length or not. On the other hand those in smear preparations were also liable to squashing, tearing and distortion. The range of the size can be taken as follows:—

> The smaller bodies were about 20·0 to 40·0 μ in diameter. The majority were elongated and finger-like, varying in width from 20·0 to 200·0 μ and in length from 200·0 to 660·0 μ. In arteries with lumina under 1·0 mm. in diameter anything from one to fifty of these bodies could be counted in the plane of the cross-section of a single artery.

The structure of these syncytial bodies is variable, a fact interpreted as due to different stages in the development of the parasite harboured. The more detailed study from smear preparations which follows below will deal with the life cycle of the parasite more fully.

In histological sections of the organs examined certain developmental stages of the syncytial bodies are apparent and may tentatively be considered as:—

i. *Invasion, Growth and Eruption.*—A cell or cells derived from the vessel wall starts to enlarge (Fig. 1). Its cytoplasm and nucleus grow, the latter soon multiplies and a syncytium results, which bulges into the lumen. It seems as if the cell in which infection or growth starts is situated in the *media* just below the *elastica interna.* In growing it has to break through the latter as well as the *intima* before it reaches and expands into the vessel lumen. Such a cell probably belongs to the histiocytic series. The disturbance in the appearance and in relationship of cells and structures in the vicinity is such that it is most difficult to ascertain the nature and the position of the original cell involved.

Increase in size takes place until the requisite and ultimate volume of protoplasm is reached. The nuclei are distinct, large, vesicular and are arranged quite irregularly either in a bunch, diffusely scattered or sometimes even in a ring. The cytoplasm has a fairly homogeneous, fine spongy appearance, with a distinctly basic staining affinity.

ii. *Division and Disintegration.*—The nuclei of the host cell become paler and more vesicular. In the syncytium globular floccules or " plasma bodies " become differentiated and are loosely held by a fine reticulate network. Small " specks " (merozoites) start to differentiate within the plasma bodies.

The nuclei of the host cell become ill-defined and often rupture. The pyknotic remnants together with " residual bodies " give rise to a sprinkling of amorphous chromatin blobs. The " plasma bodies " tend to separate. Their cytoplasm is more hyaline, pinkish staining (slightly eosinophilic) and contains the now distinct merozoites.

iii. *Some aggregations behave in a different fashion.* Instead of degenerating, the syncytial nuclei seem to separate each with its own cytoplasm into ordinary viable cells. The remaining cytoplasm disintegrates into irregular bits, but fails to show " plasma bodies ", and often becomes matted together into a thrombus-like mass containing red cells and fibrin. This phase may represent abortive parasitism with reversion of affected cells.

All the blood vessels show enlargement and distension. The vessel wall, especially that of the smaller arteries, besides distension, at times shows quite serious damage. The swelling affects the media mostly which may show quite extensive vacuolization and infiltration and the muscle cells appear shredded and displaced.

The intima is torn and ragged and many cells appear desquamated and thrombosis may be present. The origin and attachment of the syncytial masses is often associated with such changes. In and around the adventitia of larger blood vessels one often encounters numerous small syncytial masses impacted in between cells or capillaries. It is impossible to say whether these are the results of embolism in the vasa vasorum or whether they arise by outward growth from the media instead of inward growth toward the lumen.

Damage to the blood vessels is thus appreciable as is evidenced by thrombosis and by occasional haemorrhages seen in the brain. To what extent the blood-flow was impeded by the presence of parasitized aggregations in the blood vessels was well illustrated by the difficulty experienced in obtaining 15·0 c.c. blood from the jugular vein by an experienced bleeder.

2. *Liver.*

With the naked eye already it was clear that marked changes had taken place in this organ. Microscopically the portal veins were enormously distended and crammed nearly full with syncytial conglomerates. Their intima was much damaged and partial thrombosis frequent. There was also a fairly extensive blocking of the liver sinusoids by such bodies. Here also it was not clear whether this area arose by embolism or whether the parasitized bodies developed actually in the columnar spaces of the liver.

The central vein did not appear to be affected. As a result of such marked circulatory disturbance it was not unexpected nor difficult to find patchy stasis of blood accompanied by localized cyanotic atrophy of hepatic cells. These gave rise to the dark blotches seen in the liver substance. There was also irregular sublobular necrosis of a mild degree accompanied by karyolysis. The remaining hepatic cells themselves were not normal, but showed vacuolization, pressure and displacement by the impacted syncytials. In Glisson's capsule there was infiltration or proliferation of round cells, mostly histiocytes.

3. *Kidney.*

A fair amount of albuminous fluid could be seen in the glomeruli and tubules. The arteries were dilated and contained developing and full-grown syncytial bodies. For the rest the glomerular and other capillaries were engorged with blood, but showed very few impacted parasitized masses. A few necrosed areas could be seen in the cortex and cellular infiltration round the main blood vessels.

4. *Lung.*

There was distinct hyperaemia and oedema of the entire organ. About a quarter of the alveoli was filled with serous fluid, and the rest contained some too. The larger blood vessels (pulmonary arteries) contained many syncytial masses. The peribronchial and periarterial lung tissue was partly

consolidated owing to oedema sometimes mixed with fibrin. There was obstruction of the vascular lumen with or without thrombosis, capillary embolism or perivascular development of syncytials and cellular infiltration. Otherwise the alveolar capillaries in general were patent, but filled with blood, embolism being infrequent.

5. *Spleen.*

The large amount of blood in the pulpa with lymphoid centres widely espaced indicated stasis and engorgement of this organ. There were a few giant multinucleated masses in the pulpa, but many more could be found in the arteries along the trabeculae or even in one or two instances impacted in the pencil artery of the Malpighian corpuscle. Swelling of the arterial wall with damage and developmental stages of syncytials were seen here too.

6. *Myocardium.*

Blood vessels in general, but especially the muscular capillaries were remarkably free of embolism, though greatly engorged with blood. Only a few syncytials could be seen in the larger veins and arteries. In the latter there was also swelling and damage accompanying developmental stages. In parts there was a faint diffuse necrobiosis of the muscle.

7. *Brain.*

In general the arteries and arterioles of the pia mater were distended and often contained a few syncytial bodies. The capillaries were engorged but usually patent. Many, however, showed emboli, some of which were accompanied by infarction (necrosis). In parts haemorrhage had taken place, either along the course of the blood vessel or more diffusely into the surrounding cerebral tissue. Necrobiosis was most evident in the midbrain region. The vessels of the choroid plexus contained numerous syncytials.

8. *Abomasal and Intestinal Wall.*

The arteries and arterioles were much distended and contained great numbers of syncytial masses. However, there were very few in the veins and capillaries, whose lumina were greatly distended with blood. There was little embolism. Swelling and vacuolization of artery walls were frequently seen. There was no generalized process here whatever, but the tremendous blood stasis in all the abdominal organs readily explains and excuses the diagnosis of acute gastro-enteritis made at post-mortem.

(c) *The Life Cycle of the Parasite.*

In the spleen, liver, kidney and to a lesser extent in the lung smears stained with Giemsa, a large number of extra and intracellular plasma bodies, resembling Koch's bodies of *Th. parva* were observed. Careful examination showed that the extracellular plasma bodies had been liberated from individual or from aggregations of uni- or multi-nucleated host cells as the result of the mechanical injury during the process of preparing the smears. In some of the syncytial cells as many as 500 and even more schizonts were present.

The extra-cellular plasma bodies appear as blue masses of cytoplasm containing a varying number of red staining chromatin granules. It was possible to distinguish two types of plasma bodies The immature schizonts

(Fig. 6) are usually round and have a diameter of 5·0 to 25·0 μ, with an average of 10·0 μ. The smallest schizont is a round body about 5·0 μ in diameter and contain 1 to 5 nuclei. The schizont increases, in size, while the nuclei multiply by repeated division until 20 to 30 and sometimes even more are present. The chromatin granules appear as irregularly shaped bodies varying from 1·0 to 3·0 μ in size. The granules divide giving rise to as many as 100 and more small (0·5 to 0·75 μ) circular bodies, which are evenly distributed in the cytoplasm. The plasma bodies harbouring these small nuclei are the mature schizonts (Fig. 7), and in them one may notice that the cytoplasm arranges itself around the nuclei, and finally there are budded off a number of merozoites leaving a mass of residual cytoplasm. The fully mature schizonts (Figs. 8 and 9) then rupture and it is believed that the liberated merozoites (Figs. 10 and 11) either enter other host cells, in which the schizogonous cycle is repeated, or that they parasitize the erythrocytes. The free merozoites which are round vary in size from 0·9 to 2·5 μ in diameter, while the oval forms are 0·6 to 1·0 μ broad and 1·6 to 2·5 μ in length.

The intracellular schizonts are similar to the extracellular forms. Their situation in the cytoplasm of the host cell, however, partially protects them against the mechanical pressure in the process of making the smear with the result that they are smaller. The size varies from 5·0 to 15·0 μ in diameter with an average of 10·0 μ.

Difficulty was experienced in ascertaining the nature of the host cell. From the sections prepared from the different organs it was suggested that the parasitized cells might be histiocytes. Parasitized cells in various stages of development were seen in the smears. The uni-nucleated host cells were parasitized by as many as five schizonts. Some very young schizonts only harbouring one nucleus have been observed in this type of host cell. An infected multi-nucleated cell with eight nuclei harboured 50 and another one with 17 nuclei contained 200 schizonts. The uni-nucleated parasitized cell varied from 15·0 to 20·0 μ in diameter. The multi-nucleated host cells which had a round form varied from 25·0 to 40·0 μ in diameter, whereas the oval forms varied from 15·0 to 30·0 μ in width and 20·0 to 40·0 μ in length. The parasitized aggregations were very large varying from 50·0 to 100·0 μ in width and from 60·0 to 600·0 μ in length. The latter may harbour several hundred plasma bodies. In a round undisturbed multi-nucleated host cell 80·0 μ in diameter an extemely large number of merozoites (several thousand) and a relatively small number of residual bodies could be seen. Degenerated nuclei of the host cell were also present. This observation tends to indicate that the host cell ruptures after the schizogonous cycle has been completed.

It was interesting to note that as a rule the multi-nucleated cytoplasmic bodies harboured a very large number of schizonts, all of which had reached the same stage of development. This observation suggested two possibilities as regards the invasion and the growth of the host cell and the development of the parasites. In the first place the possibility must be considered, whether a normal host cell would be able to accommodate a very large number of sporozoites or merozoites should a massive invasion take place. From the histological examination described above, it is clear that the accommodation which can be offered is totally inadequate, and that the infection of this nature would undoubtedly lead to the destruction of the cell. The other possibility is that the host cell is invaded only by a few parasites which apart from completing their schizogonous cycle, also stimulate the growth

of the cell. At the time when the merozoites are fully developed it is assumed that the host cell may either rupture or continue to grow, with the result that the merozoites in their turn give rise to a further generation of schizonts. This explanation is apparently the correct one and is substantiated by the fact that host cells with one or two nuclei harbouring either one or two immature or mature schizonts, and in some instances fully developed merozoites have been seen in the organ smears.

As regards the hypertrophy of the host cells, it should be mentioned, that this phenomenon has also been observed in fishes and oligochaetes parasitized by protozoa belonging to the Cnidosporidia. Several species belonging to the order Microsporidia are known to develop in the hypertrophied leucocytes of oligochaetes. Another member of this order *Glugea anomala* (Moniez, 1887) is a parasite of the tissues and organs of various fresh-water fish (*Gasterosteus* spp.). The parasitized cell develops into a multi-nucleated cytoplasmic body 2 to 4 mm. in diameter. It has been suggested that the host cell in this case probably belongs to the leucocytic series. The systematic histological examination has shown that the host cell is invaded by one parasite, which develops into a schizont harbouring eight nuclei. The schizogonous cycle is repeated frequently and eventually the giant cell harbours several million spores . The degenerative process in the nuclei of the host cell has also been observed in this disease.

Although the parasite of the duiker described above and *G. anomala* have a similar influence on their respective host cells, there is, however, a distinct morphological difference between the two parasites. The characteristic spores of the Cnidosporidia possessing polar capsules were never observed in the smears prepared from the different organs of the duiker.

The blood smears showed that 5 per cent. of the erythrocytes were parasitized by micro-organisms resembling the free merozoites very closely. These endoglobular parasites (Figs. 12 and 13) appeared as small, circular, oval or comma-shaped bodies, with a faintly blue staining cytoplasm and a dark red staining nucleus situated at the periphery. The circular forms have a diameter of 2·0 to 2·5 μ, the oval forms are 0·8 to 1·0 μ in width and 1·5 to 2·0 μ in length, and the comma-shaped forms are 0·5 to 0·8 μ broad and 2·0 to 2·5 μ long. The erythrocytes usually harbour one parasite, but 2, 3 and even 4 parasites are not uncommon. The endoglobular forms also undergo a process of multiplication. Division into four (Fig. 13) producing the cross arrangement has been observed.

The Possible Source of Infection.

During the course of the study of this disease a visit was paid to the farm of origin in order to determine if possible the source of the duiker's infection. The remaining five duikers were healthy. Two of them were examined but no ectoparasites other than the louse, *Linognathus angulatus* (Piaget, 1885) in small numbers could be found. The microscopic examination of the blood smears prepared from these animals was negative. The owner stated that duikers and other antelopes were known to roam in the neighbourhood. Since no game-proof fences had been erected within a radius of several miles on the mountain it was possible that they could have come in contact with the domesticated duikers from time to time. Infected vectors of this disease, if such exist, could easily have been dropped along the fence. No further cases of this disease occurred during the ensuing three years.

Discussion.

It is realized that the description here given is far from complete, the studies having been conducted on one animal only, and that during the final stages of the disease. However, it was possible to demonstrate what we believe are the salient features in the development of the schizonts, the liberation of the merozoites, the morphological changes in and the proliferation of the parasitized host cell. From the material at our disposal it is not clear whether the parasites in the erythrocytes represent the final stage of the life cycle or not. Similar parasites which also resemble *Theileria mutans* (Theiler, 1906) very closely have been described in duikers by Bettencourt and Borges (1909) from Angola, by Bruce (1915) from Nyasaland and by Neitz (1931 and 1933) from Zululand. None of the workers found plasma bodies in their smear preparations. In this connection the following possibilities have to be considered. Firstly the micro-organisms of the duiker may be the final stage in the developmental cycle of the above-described parasite, secondly they may belong to the genus *Theileria* and thirdly a mixed infection may have been present. A correct interpretation of these three possibilities will become possible only when this disease is produced experimentally and studied under laboratory conditions. At present it is assumed that since the schizogonous cycle takes place in the cells of the haematopoietic system, and since the free merozoites (Figs. 10 and 11) resemble the endoglobular forms in the erythrocytes (Figs. 12 and 13) very closely that they are the final stage of the life cycle.

It is not only the recognition of the above described micro-organism as a new parasitic entity that is of interest. The clinical symptoms as well as the pathological changes in the various organs once more indicate the necessity of studying and comparing the disease of our domestic animals with those of wild animals. Take for instance the clinical nervous symptoms in this case resembling somewhat those of heartwater. On comparing the pathology of the two conditions one is bound to notice the possible similarity of disturbance in both cases, namely the injury to and interference with capillary blood flow caused in the case of heartwater by *Rickettsia ruminantium* and in the duiker by the syncytial parasitized cells.

Quite apart from the interest and value of learning something about wild animal diseases for their own sake, the fact is emphasized once again that very useful light may be thrown on similar diseases of stock and even of man. The pathogenesis of this disease is probably also unique in that we have been unable to trace reference to any extensive and generalized endarteritis and endophlebitis with such wide-spread interference of the blood flow caused by a protozoon parasite as in this case. Parasitic endarteritis, aneurism and embolism caused by filaria, strongylids, echinococcus and larvae of other worms, have of course been recorded, but come nowhere near comparison with the picture produced by the protozoon parasite.

To what extent this disease occurs in duikers and possibly in other antelopes is as yet unknown. It is hoped, however, that this account will encourage others to look out for similar cases and so add to our knowledge as regards occurrence, natural mode of transmission and if possible reproduction of the disease for further studies.

A consideration of the parasite, its morphology, location, life cycle, staining reaction with Giemsa and Haemalum-eosin, and the nature of the disease produced has led the authors to conclude that it is a hitherto

undescribed genus and species, for which the name **Cytauxzoon sylvicaprae* is proposed. If more material should become available for further studies, it might be possible to determine more accurately, the relationship between *Cytauxzoon* and other protozoa to which it bears a resemblance.

Classification.

Cytauxzoon sylvicaprae bears some resemblance to the genus *Theileria*. In some respects it appears to have a close relationship with *Theileria parva*. However, it is interesting to note the existing differences in the developmental phase and the morphology of *Cytauxzoon sylvicaprae* and the genera of the family Theileridae. The genus *Theileria* develops by schizogony in the cells of the lymphatic system, and by division in the erythrocytes. The genus *Rangelia* multiplies by schizogony in the endothelial cells and by binary fision in the erythrocytes, whereas the genus *Cytauxzoon* by schizogony in the cells of the histiocytic series and by division in the erythrocytes.

Summary.

1. A new genus and species of a protozoan parasite from the duiker (*S. grimmia*) is described. The name *Cytauxzoon sylvicaprae* is proposed for it and it is provisionally classed as a member of the family Theileridae, du Toit, 1918.

2. The symptomatology and the pathological changes of the disease produced by this parasite are detailed.

3. The attempt to transmit the disease to sheep was not successful.

4. The mode of transmission is unknown.

5. The importance of studying this and similar diseases in our wild animals is stressed, since valuable information may be brought to light on the life histories and the role played by such parasites in our stock diseases.

Acknowledgment.

Our thanks are due to Mr. Theo Meyer for the excellent photomicrographs reproduced.

REFERENCES.

BETTENCOURT, A., AND BORGES, I. (1909). Sur une Theileria parasite du Cephalophus *grimmi* (L.) *Arq. R.Inst. Bact., Camara Pestana*, Vol. 3, p. 19.

BRUCE, D., HARVEY, D., HAMMERTON, A. E., DAVEY, J. B., AND LADY BRUCE. (1915). Trypanosomes and other parasites of animals in Nyasaland. *Rep. Sleep. Sickn. Comm. Roy. Soc.*, Vol. 16, p. 203.

NEITZ, W. O. (1931). Blood parasites of game in Zululand. Preliminary Report. *17th Report of the Director of Veterinary Services and Animal Industry*, Union of South Africa. August, 1931, pp. 45–60.

NEITZ, W. O. (1933). Blood parasites of game in Zululand. Further Report. *Onderstepoort Jnl.*, Vol. 1, pp. 411–417.

NEITZ, W. O. (1944). The susceptibility of the Springbuck (*Antidorcas marsupialis*) to heartwater. *Onderstepoort Jnl.*, Vol. 20, No. 1, pp. 25–27.

*Cytauxzoon (Greek, Kytos = cell + auxē = an increase + zoon = animal).

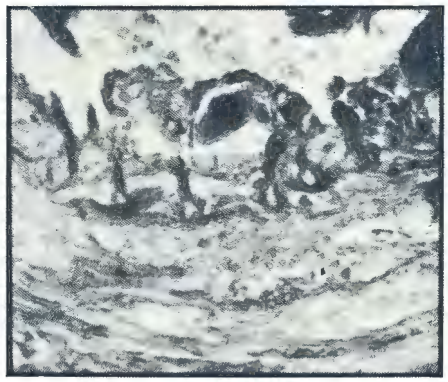

Fig. 1.—Section of the arterial wall, with early developmental stage of a parasitized cell below the elastica interna. (Magnification 500×.)

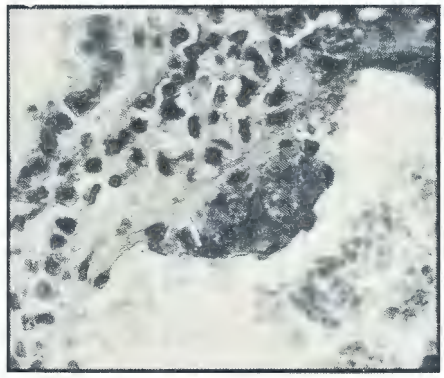

Fig. 2.—Arterial wall. A multinucleated mass grows into the lumen. (Magnification 500×.)

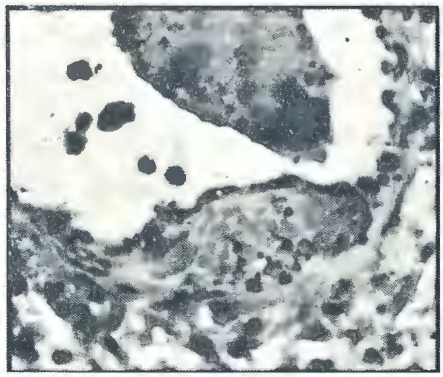

Fig. 3.—Blood vessel. A syncytial cell growing in the wall. Another lies in the lumen. (Magnification 500×.)

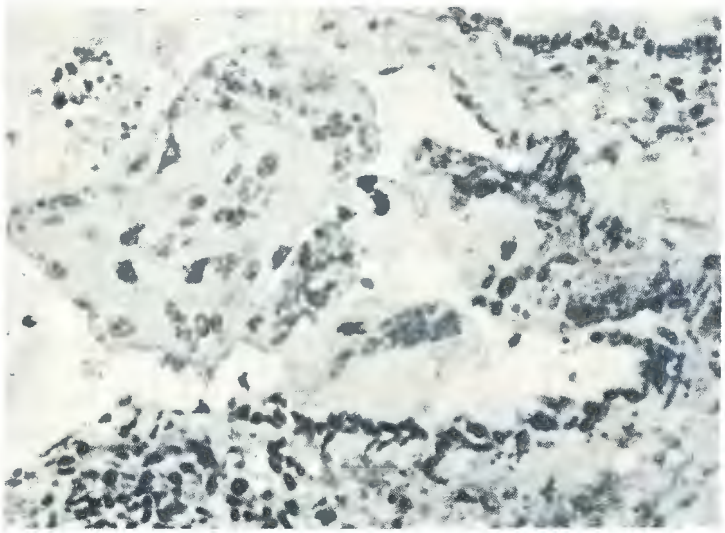

Fig. 4.—Pulmonary artery showing multinucleated types of syncytial bodies.
(Magnification 450×.)

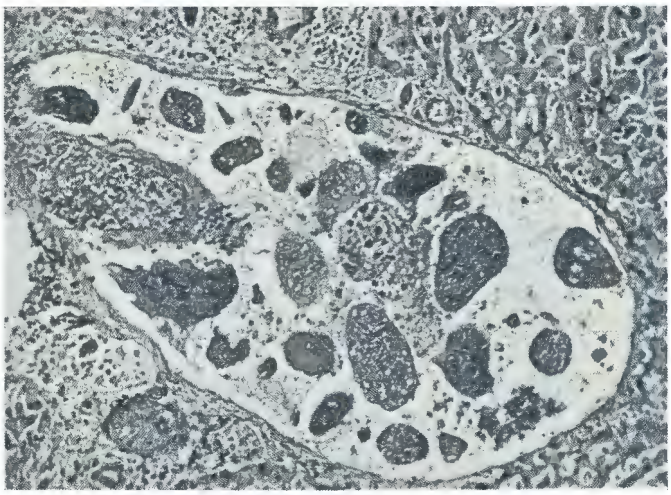

Fig. 5.—Portal vein showing various stages and sizes of syncytial bodies.
(Magnification 100×.)

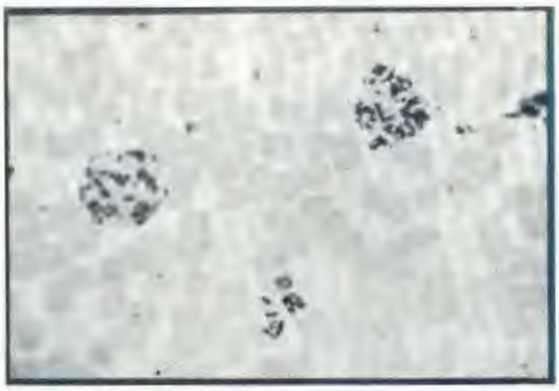

Fig. 6.—Immature extracellular schizonts found in the spleen smear. (Magnification 800×.)

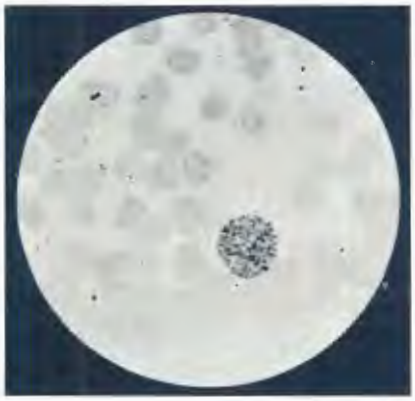

Fig. 7.—Mature extracellular schizont found in the spleen smear. (Magnification 800×.)



Fig. 8.—Mature extracellular schizonts liberating merozoites. (Magnification 800×.)

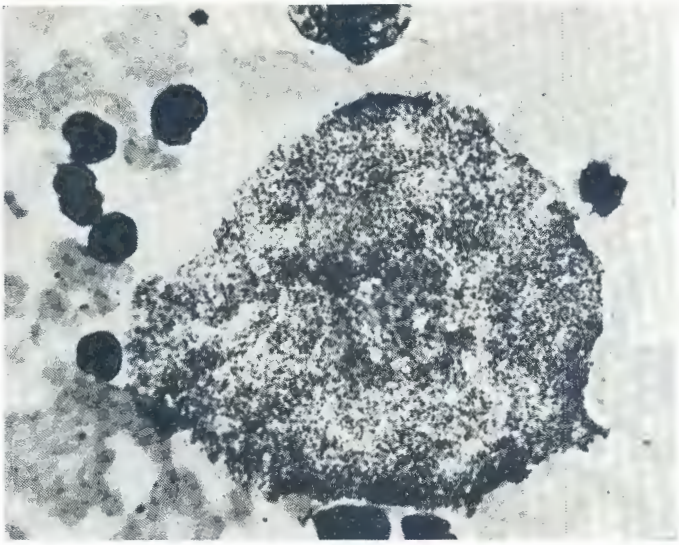

Fig. 9.—Numerous merozoites in a portion of a cell, broken away from a cellular aggregation.
(Magnification 800×.)

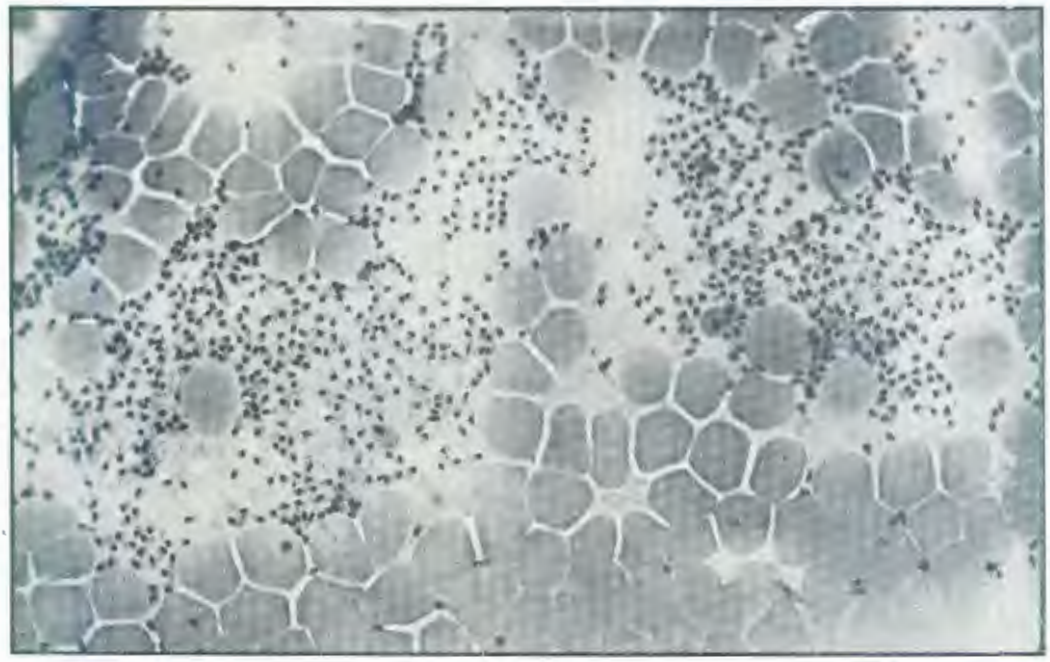

Fig. 10.—Free merozoites found in the lung smear.
(Magnification 1300×.)

Fig. 11.—Free merozoites found in the lung smears.
(Magnification 1300×.)

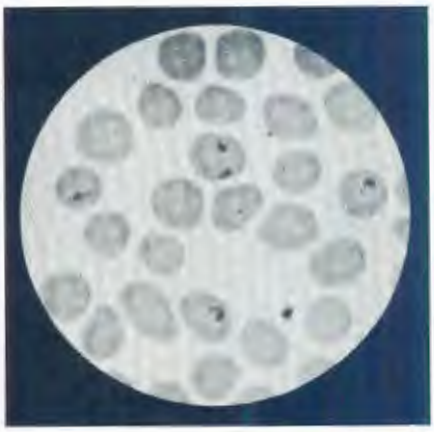

Fig. 12.—Parasites in the erythrocytes.
(Magnification 1300×.)

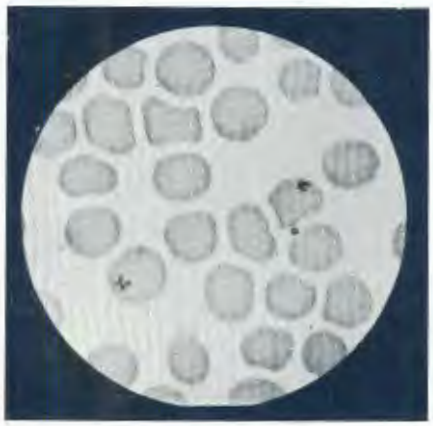

Fig. 13.—Parasites in the erythrocytes. Note the Maltese-cross form.
(Magnification 1300×.)