

Erosive Stomatitis of Cattle.

By J. H. MASON and W. O. NEITZ, Section of Protozoology and
Virus Diseases.

INTRODUCTION.

In June 1938 foot-and-mouth disease broke out in the cattle in the Nqutu Native Reserve, Natal. All infected and in-contact animals were slaughtered and buried, and the movement of cattle in the country immediately surrounding the "slaughtered-out area" was restricted until the authorities were satisfied that the disease no longer existed. Every animal in this "restricted area" (Klip River district) was examined ("mouthed") weekly and any deviation from the normal reported. In September, lesions, some slightly resembling, and others closely resembling, those of foot-and-mouth disease, were noted. A field laboratory was set up in the "slaughtered-out area", a few miles from the "restricted area". When once we had satisfied ourselves that the infection found in September was not foot-and-mouth disease, we carried out more detailed experiments at Onderstepoort.

THE DISEASE IN THE FIELD.

Two widely-differing forms of stomatitis were encountered. The evidence available indicates that these were not manifestations of the same disease. One, that will not be dealt with in detail, was, for convenience sake, termed "scaly" or "furry" tongue; the other, erosive stomatitis, was more common and formed the main subject of investigation.

"Scaly" Tongue.—A tongue, affected with this disease, had lost all or a portion of its superficial epithelium. When the epithelium was totally denuded, the tongue was smooth and cel-like. When only a portion was lost, a whorled appearance was produced because the scaling-off took place in an irregular fashion. The remaining epithelium could usually be removed by scraping with a finger-nail or a blunt scalpel.

Erosive Stomatitis.—Some lesions had a faint resemblance to old foot-and-mouth disease erosions; they were flatter than healing cuts, were covered with a greyish material, and when this was scraped away, a papilliform non-bleeding surface was left. In only a few animals were lesions seen, closely resembling those of foot-and-mouth

disease. Mr. A. M. Diesel*, Senior Veterinary Officer, Natal, describes one (later seen by one of us, J. H. M.) "When first seen (16.9.38), the tongue lesion in the 3-year-old black cow on Roosdal farm, was almost completely circular, about 4 cm. to 5 cm. in diameter, showed a regular papilliform and even base, clean-cut and regularly circular edges and was nearly 0.8 cm. deep. No change was observed in the mucous membrane of the mouth, nor did the animal show any foot lesions or any clinical symptoms of ill health. A day or two later, the lesion had become almost filled with a pseudo-membranous deposit, which when scraped away left a uniform reddened (no longer papilliform) base When seen about 16 days later, a circular scar about 3 cm. in diameter was seen The animal never, at any time, showed any general disturbances of the buccal mucous membrane and evinced no clinical signs of ill-health. No foot lesions were ever seen. Both (stock) inspectors maintained that it salivated copiously on the first day On the 21.9.38 a similar but slightly smaller lesion was seen in an 18-month-old animal on the same farm. It, too, showed the thick membranous greyish deposit after 36 hours and healed out in the same way, no changes being noticeable on the buccal mucous membrane or feet, and no clinical evidence of systemic disturbance was exhibited, also no copious salivation"

It was from the lesion in this bovine that material was obtained that gave successful artificial transmission.

In no affected animal were foot lesions, excessive salivation, or systemic disturbance observed. The spread of the disease from animal to animal was very slow, only the rare new case being detected at each new inspection, and the disease was confined, in the main, to bovines below the age of three years.

It is impossible to say whether "scaly tongue" was produced by the same agent that caused erosive stomatitis. At no time did we reproduce "scaly tongue" artificially with erosive stomatitis material.

Erosive stomatitis could be distinguished from foot-and-mouth disease on the following clinical grounds (we quote from Mr. Diesel's report)—

- (a) The absence of the truly irregular, jagged erosions of typical foot-and-mouth disease
- (b) Absence of that high degree of vascularity seen at the base of all foot-and-mouth disease lesions.
- (c) No "hotness" of the mouth and no copious salivation.
- (d) Absence of foot lesions.
- (e) Absence of systemic disturbances.
- (f) Apparent confinement of the condition to stock below the age of 3 years, and its failure to assume epidemic proportions."

* In a report to the Acting Director of Veterinary Services.

It is almost certain that the disease would have escaped notice if frequent inspection of the cattle in the "restricted area" had not been in force. It was because the stomatitis appeared in the cattle of such an area and because the Xqutu outbreak of foot-and-mouth disease had been of a mild, slowly-spreading nature that considerable effort was made to eliminate the possibility of its being foot-and-mouth disease.

EXPERIMENTS IN THE FIELD.

Attempts to infect guinea-pigs.

As attempts to infect guinea-pigs by the intraplantar inoculation of lesion scrapings failed completely, no point will be served by detailing the individual experiments. However, the following data indicate that a reasonably thorough attempt was made to prove the presence of foot-and-mouth disease. Material (scrapings of mouth lesions in buffer solution) from 18 bovines of 6 different farms was inoculated into 21 guinea-pigs. At least one passage, on three occasions 2 passages, and on one occasion 3 passages, of pad substance was carried out in fresh guinea-pigs. The pads were removed at the 48th to 72nd hour after the injection, ground-up in buffer solution and passaged. In a number of instances, scrapings from several bovines were pooled and injected intraplantarilly. In all, 51 guinea-pigs were used, without at any time an indication of vesicle formation being observed. The only reaction in the pad was a slight hyperaemia along the needle track.

Attempts to infect calves.

Three bovines were used, two from outside the restricted area and one from an infected farm (Roosdal). All were under 6 months old and showed no abnormality in the buccal cavity.

Calf 1.—Inoculated superficially (as for the intraplantar inoculation of guinea-pig pads) in 3 different places on the tongue with a suspension of scrapings of a tongue lesion of the calf on Roosdal farm (see calf noted in Mr. Diesel's report on page 160).

Observations:

After 24 and 48 hours: No abnormality.

After 72 hours: One inoculated area raised in the form of a pyramid, with the apex rounded: the base of the swelling was approximately 1.5 cm. in diameter and the height 0.75 cm.: no abnormality in the region of the other two areas.

After 96 hours: The swelling was ruptured, the opening small and the cavity filled with a dirty-grey cheesy material; the base of the cavity bled only very slightly when scraped and left a papilliform surface. A tiny superficial erosion was present at one of the other inoculation sites.

After 120 hours: Lesion flatter and filled with a dirty-grey cheesy material.

After 168 hours: Lesion flat and healing.

An emulsion of scrapings from the lesion of the Roosdal calf and from that of calf 1 failed to produce reactions when inoculated intraplantarilly into guinea-pigs.

Calf 2.—Inoculated intralingually, in 5 different areas, with emulsions or suspensions of the following materials—(1) culture (Gram-negative bacillus) isolated from the lesion of calf 1, (2) culture (staphylococcus) isolated from a “scaly” tongue, (3) culture (diphtheroid) isolated from a lesion on the tip of a bovine’s tongue, (4) emulsion of scrapings from a lesion on a bovine’s tongue (Potsdam case). No abnormality was noted during a 7 day observation period.

Calf 3.—Although guinea-pigs did not react when inoculated with scrapings from mouth lesions, the possibility existed that a virus was the cause of the naturally-occurring disease and that this virus could multiply in the guinea-pig pad without causing lesions. With this hypothesis in mind, an emulsion of scrapings of a lesion was passaged intraplantarilly 3 times in guinea-pigs and an emulsion of the hind pads of the third passage guinea-pigs was inoculated intralingually into calf 3. No reaction occurred during the 7 days the calf was under observation.

EXPERIMENTS CARRIED OUT AT ONDERSTEEPOORT.

Scrapings from lesions of 3 bovines were brought to the Institute in buffer solution (M/15 phosphate, pH 7.3) and infection experiments carried out in calves, sheep, guinea-pigs, rabbits, rats, and mice. It will save repetition if it is now stated no calf or sheep showed a thermal rise, obvious illness, foot lesions or excessive salivation as a result of attempted artificial infection. Most of the calves used were born at Onderstepoort and had been reared under tick-free conditions and were not older than 9 months; when the supply of these ran out, calves (one year old or under) from an adjoining farm, Kaalplaas, were used. The Kaalplaas animals were born and bred under veld conditions.

Throughout all the work, precautions were taken to prevent the spread of infection by clothing and hands. Rubber boots, gloves, and apron were worn and washed down with disinfectant between the examination of each calf. Rejected food, bedding, and excreta were placed in sacks and burned, and except in the first two experiments, a separate box was allotted to each calf.

Two experiments, to illustrate tongue, and lip and dental pad lesions respectively, will be recorded. Thereafter, summaries only will be given.

Experiment 1.—Three calves (7680, 7501 and 7571) were placed in the same box and each was inoculated in 3 different places on the tongue with emulsions of mouth scrapings brought from the field.

Calf 7680.—Inoculated with emulsion of scrapings from the tongue erosions of calf 1 (see p. 161). This material had been held in buffer solution for 11 days (9 days at refrigerator, and 2 days at room temperature).

Observations :

<i>Days after Inoculation.</i>	<i>Appearance of inoculated area.</i>
1	Apparently normal.
2	One area slightly raised, with small hole at summit.
3	Three erosions present in one inoculated area, oval or slightly elongated, 0·5 cm. to 1·0 cm. in longer diameter, edges ragged, no bleeding on scraping base, base papilliform, erosion filled with a grey cheesy material.
4	As day 3.
5	Erosions more extensive; one red but not raw at base; other two filled with greyish material.
6	Healing commencing. Erosions flatter.
7	Healing continuing. Calf killed.

NOTE.—No lesions developed on one area, on the 2nd, tiny erosions appeared on the 3rd day and followed a similar course, but in a miniature way, to that described above and the lesions developing on the 3rd area are those described. No lesions developed on any other part of the buccal mucous membrane and guinea-pigs, inoculated intraplantarilly with scrapings taken on the 3rd day, did not react.

The reaction obtained in calf 7680 was very similar to that got in calf 1 and the final erosion could not be distinguished from that present on the tongue of the original Roosdal bovine. To save repetition such a reaction will be recorded as typical tongue lesion.

Calf 7501: Inoculated with emulsion of scrapings of several lesions of a bovine on farm Potsdam. This material had been held in buffer solution for 10 days (8 days at refrigerator, and 2 days at room temperature).

No reaction occurred during the 7 days' observation.

On the 7th day, this calf was inoculated intralingually, on this occasion with material from the tongue erosions of calf 7680. During an observation period of a further 14 days, no lesion appeared on the tongue, but on the 4th day a crop of small, very superficial, nearly confluent erosions appeared on the muzzle, and on the 5th day 3 small erosions developed on the dental pad. On both sets of erosions greyish yellow crusts formed; these could be scraped off only with difficulty and left a very shallow depression with an entire edge and a pink non-bleeding base. Healing had occurred on the 11th day after the inoculation of the tongue.

Calf 7571: Inoculated with emulsion of scrapings of a lower lip erosion of a cow on farm Ntabeni. This material had been held in buffer solution for 9 days (7 days at refrigerator temperature and 2 days at room temperature).

No lesions developed at the points of inoculation on the tongue, but on the 7th day, 7 superficial erosions appeared on the dental pad and 7 on the lower lip. These varied in diameter from 0.25 cm. to 1.0 cm., were dirty greyish-yellow in colour, and followed the same course as those recorded for calf 7501.

Comment.—Calves 7501 and 7571 did not react on the tongue (inoculation site) but did react, after a considerably lengthened incubation period, on the muzzle, dental pad, and lower lip. As they were in intimate contact with a reacting bovine (7680), the chance is that they were infected through contact. To check this point, a fresh calf (7668) was placed in contact with two reacting bovines (7501 and 7700) for 14 days. Two tiny, shallow erosions developed on the dental pad and a number of pin-point depressions appeared on the muzzle. All healed in a few days. It is doubtful if this can be regarded as a positive result. The dental pad lesions appeared on the second day of contact, which is about one day too early for the development of the "pearly" precursor (to be discussed later) of an erosion even when the pad is deliberately infected by scarification; the muzzle lesions were tiny and required careful observation for detection.

Experiment 2: Calf 7592 was inoculated on the tongue by superficial injection and on the dental pad and lower by scarification, with an emulsion of scrapings of mouth lesions from artificially infected calves 7702 and 7585. This material represented the third passage in calves.

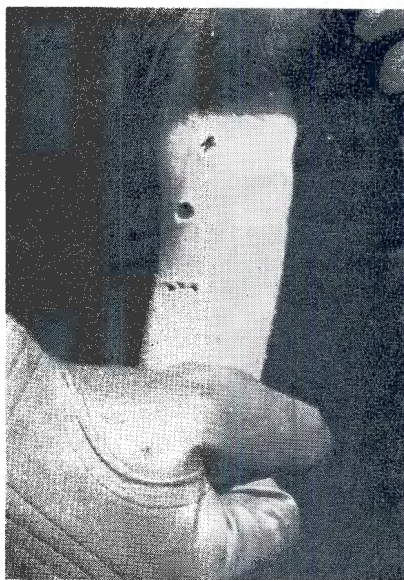
Observations:

<i>Days after Inoculation.</i>	<i>Appearance of inoculated areas.</i>
1	Apparently normal. Scarification marks visible.
2	As day 1.
3	<i>Dental pad:</i> 6 pin-head-sized whitish-yellow spots surrounded by a red border. The spots looked like tiny pearls under the mucous membrane. <i>Lower lip and tongue:</i> Apparently normal.
4	<i>Dental pad:</i> " Pearls " breaking down to form superficial erosions. <i>Lower lip:</i> " Pearls " commencing. <i>Tongue:</i> Apparently normal.

Days after Inoculation. *Appearance of inoculated areas.*

- 5 From now until the 10th day, when healing commenced, the erosions, at first small, superficial, with a white glistening base and a red border, coalesced to form fairly extensive erosions. These larger lesions resembled the smaller ones in appearance. The edges were ragged, the base glistening and moist, and the outline irregular. Healing occurred as for a traumatic injury, and if the original lesion had been large a visible scar was left.

The above description is fairly typical of those lesions which commenced with "pearl" formation. Occasionally, the "pearls" could be detected on the 2nd day after inoculation, especially if the lip or dental pad was vigorously rubbed with the finger. Erosion formation could be hastened and intensified by scraping a few "pearls" with a blunt knife.



Lesions on tongue of calf 7444 (artificial infection).

In Table 1, the passages carried out in calves are recorded. It will be seen that the disease was transmitted in series through 5 calves, and that lesions were produced in the tongue (the only site inoculated) of the first three animals and in the pad and lip only of the last 2 calves, although the tongue was also inoculated. The only tongue lesions obtained were in these first three calves.

TABLE I.
Passages in Calves.

Donor.	Recipient.	Inoculum.	Result.
Roosdal calf. (Natural infection)	Calf I.	T.-T.	(T.)
Calf I.	C. 7444	T.-T.	(T.)
C. 7444	C. 7966	T.-T.	(T.)
C. 7696	C. 7592	T.-T.P.L.	(P. & L.)
C. 7592	C. 7603	P.L.-T.P.L.	(P. & L.)

T.-T..... Tongue lesion scrapings inoculated into tongue only.
 T.-T.P.L..... Tongue lesion scrapings inoculated into tongue, dental pad, and lower lip.
 P.L.-T.P.L..... Dental pad and lower lip lesions inoculated into tongue, dental pad, and lower lip.
 (T.)..... Tongue lesions.
 (P. & L.)..... Dental pad and lower lip lesions.

The foregoing experiments merely showed that some infection was being passed from calf to calf but did not indicate the nature of the infection—whether virus or bacterium. To check this point, infectious material was passed through “Gradocol” membranes and the infective power of the filtrate tested on calves.

Gradocol Filtration.—A homogeneous suspension of scrapings of recently formed erosions was made in 10 per cent. (horse) serum-saline. This was spun at 4,000 r.p.m. for half-an-hour and the supernatant fluid re-spun at 13,000 r.p.m. for a further 20 minutes. The final crystal-clear supernatant was then passed through gradocol membranes; if 2 membranes of different pore size were used, the fluid was passed first through that with the larger pores. The pressure (one atmosphere) was obtained from a cylinder of compressed nitrogen and the temperature was between 22° C. and 25° C. The time required for filtration varied from 15 to 90 seconds and the volume of fluid filtered was 20 c.c. or more*. The filtrates were subjected to sterility tests on blood agar, chick-embryo-extract agar, serum-broth and meat-particle broth plus chick-embryo extract. The tubes of medium were incubated at 37° C., some aerobically and others anaerobically, for one week. No bacterial growth was obtained in any instance.

The results of injecting a number of filtrates into susceptible calves are recorded in Table 2.

Filtrates, sterile by bacteriological tests, produced typical lesions in 5 of the 6 calves inoculated. It will be noticed that the non-reactor received the inoculum in the tongue only and that in none of the 5 reactors was a tongue lesion produced. This confirms the results of “straight” passage, where the tongue appeared to be less susceptible than the lip or dental pad.

* For this, the filtration part of the work, we are indebted to our colleague, A. Polson.

TABLE 2.

Result of Injecting Gradocol Filtrates into Calves.

Donor.	Membrane. (mx.)	Site of inoculation.	Recipient.	Result.
C. 7444.....	1,350 Unfiltered.	T.P. & L.	C. 7702	R. (P & L.)
		T. only.	C. 7696	(R. (T.))
C. 7702.....	1,350 500 Unfiltered.	T.P. & L.	C. 7585	R. (P. & L.)
		T.P. & L.	C. 7711	? (P. & L.)
C. 7702 }.....	800 Unfiltered.	T.P. & L.	C. 727?	R. (P. & L.)
C. 7585 }.....		T.P. & L.	C. 7596	R. (P. & L.)
C. 7571 }.....	435 Unfiltered.	T.P. & L.	C. 7592	R. (P. & L.)
C. 7700 }.....		T. only.	C. 7443	N.
C. 7680 }.....	T. only.	C. 7444	R. (T.)	
Calf I. }.....	390 Unfiltered.	T.P. & L.	C. 7520	R. (P. & L.)
C. 7576 }.....		T.P. & L.	C. 7603	R. (P. & L.)

T.=tongue; P.=dental pad; L.=lower lip; N.=no reaction; R.=reaction.

It will be appreciated that no serious attempt was made to estimate the size of the infecting agent. Anything approaching an accurate end-point could have been reached only with the use of a much larger number of young susceptible calves than was at our disposal. The results did show that the causal agent readily passed through membranes with an A.P.D. of about 400 $m\mu$ and that it was not cultivatable in cell-free culture media.

Cultivation on the Chorio-allantoic Membrane of Eggs.—The technique employed has been described in detail by Alexander (1938). Fertile eggs containing 8-day-old embryos were used and, after inoculation of the membranes, were incubated at 37° C. for a further 5 to 6 days when a passage was made. The original inoculum was a bacteriologically sterile gradocol filtrate. Calves were inoculated on the tongue (intralingual injection), dental pad, and lower lip (scarification) with emulsions of the chorio-allantoic membrane. (Table 3 summarizes the results.)

TABLE 3.

*Cultivation of the Infective Agent on the Chorio-allantoic Membrane.**Series 1.*

The original inoculum, an 800 $m\mu$ filtrate from calves 7702 and 7585, was infectious for calf 7596 (see Table 2).

Calf.	Egg Generation.	Inoculum.	Result.
7570	1	C.A.M.....	Negative.
7588	2	C.A.M. & E.	? positive; tiny white spots with red borders on lower lip; did not form erosions.
7458	3	C.A.M.....	Negative.
7480	3	E.....	Neagtive.

Series 2.

The original inoculum, a 560 m μ filtrate from calf 7359 was not tested for infectivity.

Calf.	Egg Generation.	Inoculum.	Result.
7530	4	C.A.M.....	Positive; definite "pearls" on lip and pad on 2nd day. Broke down to form erosions. Nil on pad.
7550	9	C.A.M.....	Negative.

(C.A.M. = chorio-allantoic membrane; E. = embryo).

The results indicate that the infective agent, which will now be called the "virus", grew on the chorio-allantoic membrane of fertile eggs. The lesions produced in calf 7588 of series 1 were not typical and do not constitute a positive result. On the other hand, the lesions in calf 7530 of series 2 were definite and typical. The membranes were sterile bacteriologically so that a bacterium, as a cause, may be ruled out. The inoculum for calf 7530 was composed of membranes of the 4th egg passage so that it is unlikely that a carry-over of the originally-inoculated virus (gradocol filtrate) was responsible for the lesions.

Keeping qualities of virus.

As stated earlier, the virus survived 11 days (9 days at refrigerator, and 2 days at room temperature and, in subsequent work, it was shown to remain viable for 21 days at refrigerator temperature. As with most of the experiments in this investigation, we lacked sufficient calves to investigate fully the different properties of the virus. However, we were able to show that scrapings emulsified in 50 per cent. (horse) serum saline and dried from the frozen state and held at refrigerator temperature, remained infective for 6 weeks.

Immunity.

Calves which had fully recovered from artificial infection were subjected to a further inoculation on the tongue, dental pad, and lip. Table 4 records the results.

TABLE 4.
Immunity Tests in Calves.

Calf.	First Inoculation.	Result.	Second Inoculation.	Result.
7243.....	Nil	—	16/1/39 T.P. & L.	R. (P. & L.).
7700.....	12/10/38 on T. & P.	R. (P.)	T.P. & L.	R. (P. & L.).
7585.....	4/11/38 T.P. & L.	R. (P. & L.)	T.P. & L.	Negative.

(Abbreviations as in Table 1).

Owing to the small number of animals used, definite conclusions cannot be drawn, but the indication is that the immunity was either of very short duration or weak, or both.

The Clocolan Virus.

Our colleague, E. M. Robinson, investigated an outbreak of stomatitis in cattle at Clocolan in the Orange Free State. His description of the lesions tallied with that given earlier for those of the cattle in the Klip River district. Scrapings of mouth erosions, emulsified in buffer solution, were brought to Onderstepoort and inoculated into a susceptible calf (tongue, dental pad, and lower lip). Lesions, indistinguishable in evolution, course, and appearance from those described were obtained on the pad and lip and the disease was successfully passed to two more calves. Clinically, the two diseases were identical.

Attempts to infect Sheep.

No local or general reaction was produced when virus in the form of erosion scrapings was inoculated into the tongue, dental pad, or lower lip of bluetongue susceptible sheep or when blood of reacting cattle was inoculated intravenously. The chief reason for carrying out these transmission experiments was the findings of Bekker, de Kock and Quinlan (1934). From the blood of cattle, affected with stomatitis and dermatitis and living in a foot-and-mouth-disease-infected area, they were able to isolate bluetongue virus in sheep. Table 5 summarizes our findings.

No reaction, local or general, was produced when sheep were inoculated, either locally, in the buccal cavity, or intravenously, with emulsions of erosion scrapings taken at the height of the local reaction. Further, the intravenous injection of blood, taken from calves at the height of the reaction produced no obvious effect. No sheep, subjected to this treatment, was immune to bluetongue at a subsequent immunity test. The blood of the original Clocolan cattle given intravenously to sheep produced no reaction and did not immunize against bluetongue. And finally "Bekker" bluetongue virus applied to scarifications on the tongue, dental pad, and lower lip of 2 sheep produced no local reaction but did, in one sheep, cause a general reaction with resulting immunity.

Throughout all this work, we kept in mind the work of Bekker, de Kock and Quinlan (1934) de Kock, du Toit and Neitz (1937), and de Kock, van Heerden, du Toit and Neitz (1937). These groups of workers isolated bluetongue virus from cattle. In the case of the first group of workers, the virus originated from cattle affected with stomatitis, and with it the authors produced stomatitis in bovines; in the latter case, the blood was obtained from cattle without stomatitis, but living under veld conditions and affected with "Tzaneen" disease (for details, see original articles). The results recorded in Table 5 show that we could not demonstrate bluetongue virus in the local lesions or in the blood of cattle artificially infected with erosive stomatitis. Since then, we have attempted to repeat the work of Bekker *et al.* with what we consider to be negative

results (these experiments will be reported in more detail in another article), in spite of using the same strain of virus, " Bekker ", as they did. The Bekker strain is undoubtedly bluetongue virus, apparently caused stomatitis in cattle in the hands of Bekker *et al.* and failed to do so in our hands, although it did set up a " maladie inapparente " in cattle, being recoverable in the blood about 3 weeks after intravenous inoculation.

TABLE 5.
*Attempts to infect Sheep with the Viruses of
Erosive Stomatitis and Bluetongue.*

Sheep.	Inoculum.	Route.	Result.	Date.	B.T. Immunity Test (Bekker Virus).
52710	9/11/38, erosion scrapings C. 7702 and C. 7585	T.P. & L.	No reaction.	3/1/39	† B.T.
52671	As 52710.....	T.P. & L.	No reaction.	3/1/39	Reacted B.T. and recovered.
52906	13/10/38, erosion scrapings C. 7571	T. & P.	No reaction.	3/1/39	Reacted B.T. and recovered.
52960	As 52906.....	I.V.	No reaction.	3/1/39	Reacted B.T. and recovered.
52732	25/10/38, 10 c.c., blood, C. 7444	I.V.	No reaction.	3/1/39	B.T. killed in extremis.
52952	25/10/38, 10 c.c., blood, C. 7444	I.V.	No reaction.	—	—
52952	5/11/38, 10 c.c., blood, sh. 52732	I.V.	No reaction.	3/1/39	B.T. killed in extremis.
52886	15/10/38, Bekker B.T. blood, sh. 52903	T.P. & L.	No reaction.	15/1/39	B.T. killed in extremis.
52874	As 52886.....	T.P. & L.	Reacted with temperature 4th-10th day. No mouth lesions.	15/1/39	No reaction.
52697	11/1/39, 10 c.c., blood of Ciocolan cattle (field)	I.V.	No reaction.	1/2/39	Reacted B.T. and recovered.

(I.V. = intravenous; T.P. & L. = tongue, dental pad, and lower lip; † = died.)

In this article, we do not intend to discuss the possible reasons for the apparent discrepancy but will briefly record one experiment where heartwater and not bluetongue virus was isolated from the blood of a bovine infected with erosive stomatitis.

Bovine 7501

- 10.12.37, born Kaalplaas, a heartwater-infected farm.
 25.1.38, transferred to Camp 25 (Onderstepoort), heartwater-free camp.
 31.3.38, transferred to Camp 22 (Onderstepoort), heartwater-free camp.
 25.8.38, transferred to West Camp 61 (Onderstepoort), heartwater-infected camp.
 4.10.38, transferred to Stable 16 (Onderstepoort), heartwater-free stable.
 5 and 8.10.38. This calf became infected with erosive stomatitis at this period, probably through contact (experiment noted on p. 164) and was killed on 26.10.38. At no time during the period 4.10.38 to 26.10.38 did the temperature rise above normal limits and except for the stomatitis, the animal appeared to be perfectly healthy.

On 13.10.38, 10 c.c. of blood was given intravenously to sheep 52716; a thermal reaction and symptoms of heartwater was the result, with eventual recovery. This sheep did not react when tested at a later date with heartwater virus, but at a still later date, it died when inoculated with blue tongue virus (Bekker). Subinoculation of blood of sheep 52716 was carried out when the thermal reaction was at its height, and from the subinoculated sheep, further tests were made to determine the cause of the reaction. In brief the results were as follows:—The symptoms and post-mortem findings were those of heartwater; *Rickettsia ruminantium* was seen in the endothelial cells of the jugular vein; heartwater-immune sheep were immune to this disease and those immune to this disease were immune to heartwater; bluetongue-immune sheep were not immune to this disease and those immune to this disease were not immune to bluetongue.

Obviously at the time of the inoculation of sheep 52716, calf 7501 was either recovering from heartwater or suffering from an inapparent form of the disease. If, by chance, we had picked up bluetongue and not heartwater virus, we might, following the experience of Bekker *et al.*, have assigned to bluetongue virus the causal rôle in stomatitis.

Attempts to infect laboratory animals.—This work, entirely negative, was a continuation of that carried out in the field. Guinea-pigs and rats could not be infected on the hind pads or on the tongue nor rabbits on the tongue. No reaction was produced when known infective but bacteriologically sterile gradocol filtrates were injected intracerebrally into mice and guinea-pigs or intraperitoneally into mice.

DISCUSSION.

The disease described, erosive stomatitis, appears to be of no economic importance and warrants investigation only when it can be confused with foot-and-mouth disease. Uncertainty will arise only in circumstances such as those noted in this article.

Prentice (1913) described a similar disease in cattle shipped from Ireland to England. Constitutional symptoms and foot lesions were absent and in-contact sheep and pigs did not contract the disease. "Scaly" tongue was noted in many of the bovines. Norris and Mettam (1913) gave a more detailed description of this disease as it occurred in cattle in County Armagh. This description agrees in many points with that given for erosive stomatitis, but it would appear that "scaly" tongue lesions were more common. They were able to reproduce the disease by contact and by applying infective material to the scarified buccal mucous membrane, but pigs and sheep were not susceptible. Infection was not set up with bacteria isolated from lesions.

Ostertag and Bugge (1906) recorded a papular stomatitis in cattle. The disease could be transmitted by the subcutaneous injection of the blood of reacting cattle, the incubation period being 14 days or more. No fever or constitutional symptoms occurred. Small elevations surrounded by red zones appeared on the buccal mucous membrane. At first the elevations were red but soon became yellow-grey in colour; depressions appeared in them and erosions were produced. In one experiment they introduced fragments of lesions into pockets cut in the tongues of 5 calves. These animals reacted after 14 to 18 days but not at the points of inoculation. For this reason, we would suggest that the disease was not the same as erosive stomatitis.

Cadéac (1906) described a vesicular stomatitis, which appears to have much in common with erosive stomatitis. However, as no experimental work is recorded, a definite opinion cannot be given.

Finally, we have shown that bluetongue virus could not be isolated from either the blood or local lesions of bovines affected with erosive stomatitis and that bluetongue virus did not produce a stomatitis. On the evidence presented—filterability, growth on the chorio-allantoic membrane of the chick embryo, and failure of bacteria isolated from lesions to set up the disease—we are of the opinion that erosive stomatitis of cattle is a disease caused by virus, and has much in common with, if it is not the same as, "Armagh disease".

CONCLUSIONS.

1. A disease, erosive stomatitis of cattle, which has some resemblance to foot-and-mouth disease, is described.
2. It can be transmitted in series from bovine to bovine and is caused by a virus.
3. There is evidence that erosive stomatitis and "Armagh disease" are similar, if not the same.

ACKNOWLEDGMENTS.

We have pleasure in acknowledging our indebtedness to Dr. G. de Kock, Deputy-Director of Veterinary Services, for initiating this piece of research and for criticism and help in the conducting of it; to Mr. A. M. Diesel, Senior Veterinary Officer, Natal, for the help

and courtesy shown us during the field investigation and for permission to quote from his report on the naturally-occurring disease; and to Mr. J. H. B. Viljoen, Government Veterinary Officer, Ladysmith, for his unfailing willingness to find suitable material.

REFERENCES.

- ALEXANDER, R. A. (1938). Studies on the neurotropic virus of horsesickness VI. Propagation in the developing chick embryo. *Onderstepoort J.*, Vol II, pp. 9-19.
- BEKKER, J. G., DE KOCK, G. v. D. W., AND QUINLAN, J. B. (1934). The occurrence and identification of bluetongue in cattle—the so-called pseudo-foot and mouth disease in South Africa. *Onderstepoort J.*, Vol. 2, pp. 393-507.
- CADEAC, C. (1906). Stomatitè vésiculeuse. Pathologie Interne, Bouche-Pharynx-Estomac. *J.-B. Baillière et Fils*, Paris.
- DE KOCK, G., VAN HEERDEN, C. J., DU TOIT, R., AND NEITZ, W. O. (1937). Bovine Theileriosis in South Africa, with special reference to *Theileria mutans*. *Onderstepoort J.*, Vol 8, pp. 9-125.
- DE KOCK, G., DU TOIT, R., AND NEITZ, W. O. (1937). Observations on bluetongue in cattle and sheep. *Onderstepoort J.*, Vol. 8, pp. 129-180.
- NORRIS, J. H., AND METTAM, A. E. (1913). Reports of experiments conducted in connection with the suspected outbreak of disease in County Armagh. Appendix B. Report on Foot and Mouth Disease in Ireland in the year 1912. *Dept. of Agric. and Tech. Instruction for Ireland*. H.M. Stat. Office (Cd. 7103).
- OSTERTAG AND BUGGE. (1906.) Untersuchungen über eine maulseucheähnliche Erkrankung des Rindes ("gutartige Maulseuche", Stomatitis papulose bovis specifica). *Ztschr. Infektionkht.*, Vol 1, pp. 3-20.
- PRENTICE, D. S. (1913). Report by. Appendix A. Report on Foot and Mouth Disease in Ireland in the year 1912. *Dept. of Agric. and Tech. Instruction for Ireland*. H.M. Stat. Office (Cd. 7103).