

A New Piroplasm (*Sauroplasma thomasi* n.g., n.sp.) of a Lizard (*Zonurus giganteus*, Smith).

By P. J. DU TOIT, Section of Protozoology and Virus Diseases,
Onderstepoort.

UNTIL recently "piroplasms" had been observed in mammals only. Balfour, in 1907, had seen bodies resembling piroplasms in the blood of fowls suffering from spirochaetosis in the Sudan, but he failed to recognize their true nature. It was only in 1928 that Carpano first described a piroplasm of domestic fowls under the name *Aegyptianella pullorum*. The finding of what appeared to be a near relative of the mammalian piroplasms in birds showed that these unpigmented, endoglobular blood parasites had a wider distribution than was at first supposed.

In 1935 Brumpt and Lavie described a piroplasm (*Tunetella emydis*) from the blood of a tortoise (*Emys leprosa*), thus extending the known range of distribution of these parasites from the warm-blooded mammals and birds to the cold-blooded reptiles.

In the present article a parasite, which also seems to be a true piroplasm, will be described from the giant girdle-tailed lizard, *Zonurus giganteus*. It would seem, therefore, that the occurrence of piroplasms in reptiles is more general than was supposed at first.

Actually there is nothing very surprising in this finding of piroplasms in reptiles seeing that ticks, the sole transmitters of piroplasmosis, attack all classes of vertebrates living on dry land.

Before proceeding to the description of the parasite it may be useful to make a few remarks about the parasites of the red blood corpuscles of reptiles in general.

REVIEW OF LITERATURE.

For the purpose of this article it is unnecessary to review the literature in any detail. Suffice it to refer to the excellent summaries in some of the more recent text books on protozoology, such as that of Wenyon (1926) and Doflein-Reichenow (1929), and to discuss only the few articles which are of special interest to our subject.

All endoglobular blood parasites of reptiles (and other vertebrates) belong to the Sporozoa.

This large class is again sub-divided into many orders and families, but there is considerable difference of opinion between protozoologists about the details of this classification. These differences need not concern us here. For our purpose we may assume the validity of the families Haemoproteidae, Plasmodiidae, Haemogregarinidae, and Piroplasmidae (or Babesidae), to which most of the parasites in which we are now interested, belong.

The members of the two first-named families are characterized by the production of pigment in the host cells (the red blood corpuscles). The parasites belonging to this group can therefore be recognized fairly easily and cannot readily be confused with the piroplasms which are unpigmented. A large number of species of *Haemoproteus* and *Plasmodium* has been described from reptiles.

The haemogregarines are a somewhat ill-defined group containing, according to some authors, the single genus *Haemogregarina*, according to others, a considerable number of genera and even families belonging to the sporozoan order Adeleidea. Again this difference of opinion need not detain us. It is of interest though to note that a very large number of haemogregarines occurs in reptiles and particularly in lizards. The life-histories of many of these species are well known and their blood forms can easily be distinguished from piroplasms.

Of the piroplasmidae only one member has thus far been described in reptiles. Brumpt and Lavier (1935, b) observed in the blood of a tortoise (*Emys leprosa*) from Tunis an endoglobular parasite which they called *Tunctella emydis*. This parasite occurred in three forms: (1) large forms, 2-5 μ in diameter, round, oval or lobulated in shape, with one to three chromatin granules; (2) small forms, less than 1 μ in diameter, single or in groups; and (3) small inclusions, arranged in rosettes or in rows, appearing as basophilic spots, but without any chromatin granules.

The authors discuss the relationship between these different forms and come to the conclusion that they probably represent developmental stages of the same parasite. An attempt to transmit the parasites from the infected tortoise to fourteen other tortoises of the same species failed; the authors suspect that these specimens were immune.

Brumpt and Lavier then discuss the relationship between this parasite and other known parasites, particularly *Aegyptianella pullorum*, and they conclude that their parasite does not belong to this genus but should be placed in a separate genus.

One further parasite of reptiles, thus far recorded in the literature, can be said to have a resemblance to the piroplasms. I am referring to a blood parasite of a gecko, *Tarentola mauritanica*, described by Chatton and Blanc, (1914, 1916) under the name *Pirhemocyton tarentolae*. Three out of about forty geckos caught in the neighbourhood of Matinata and Metlaoui in Tunis were found to be infected.

When the fresh blood was examined the authors noticed, not the parasites themselves, but globular, albuminous, refractive bodies in the red blood corpuscles. One of these bodies seemed to be present whenever there was a parasite in the cell. There was also a direct relation between the size of the parasite and that of the globular body but otherwise the two objects seemed to be in no way related.

The parasites themselves varied from small anaplasmoid bodies of about 1μ in diameter, to larger round, oval or pear-shaped bodies 3 to 4μ in diameter. The authors distinguish anaplasmoid forms, some of which have a clear zone around them; spherical forms with a chromatin dot in the centre of the clear cytoplasm; other spherical forms with the chromatin more diffuse; and a variety of other forms. Some of these parasites are closely connected with the nuclei of the host cells; in fact in some cases a chromatin thread connects the nucleus of the parasite with the nucleus of the red blood corpuscle; and in others the parasite seems actually to be extruded from the cell nucleus.

The authors did not observe any multiplication forms of the parasites, and suggest that, as in *Theileria parva*, multiplication does not take place in the peripheral blood. (Spleen and marrow were not examined.) The relationship of these parasites to other known groups is discussed, and the authors come to the conclusion that there is no close connexion with the piroplasms.

The same conclusion is reached by Brumpt and Lavier (1935, a) in regard to a very similar parasite, *Pirhemocytion lacertae*, which they found in a green lizard, *Lacerta viridis*, obtained from Italy. They found the same forms of the parasite but did not observe the globular bodies which were so prominent in Chatton's and Blanc's cases. Brumpt and Lavier succeeded in transmitting the infection to another lizard of the same species; the incubation period was six days.*

PERSONAL OBSERVATIONS.

The parasites about to be described, were found in the red blood corpuscles of a lizard *Zonurus giganteus*, Smith. The first infected specimen was caught by Dr. A. D. Thomas of the Onderstepoort Veterinary Research Institute during a tour in connexion with the Zoological Survey of South Africa, on the farm Jacobsdal near the village of Wesselsbron, in the Orange Free State, in January, 1936. During a subsequent tour in November, 1936, Thomas found another infected specimen on the town lands of Odendaalsrust in the Orange Free State. At the time only blood smears were collected, so that it was impossible later on to examine either the fresh blood or other organs for possible developmental stages of the parasites.

* Mention should also be made of a parasite of the blood of fish (*Cottus bubalis* and *Cottus scorpius*) described by Henry (1910 and 1913) under the name *Haemohormidium cotti*. The parasites have a resemblance to piroplasms although Henry himself does not include them in this group but suggests some relationship to the haemogregarines.

The degree of infection of the blood of the first specimen was somewhat heavier than that of the second, and the first contained more divisional forms of the parasite than the second, but otherwise the two may be considered as identical.

The blood of both specimens showed a large number of infected blood cells. In the first specimen a count of 500 cells revealed a percentage infection of 56. In the second specimen the corresponding figure was 43 per cent. In the great majority of cases an infected erythrocyte contains a single parasite. Two parasites in a blood cell are very rare, and more than two were never seen.

The parasites are small in comparison with their host cells. Accurate measurements revealed a variation between 0.6μ and 4.5μ in diameter or length of the parasite. The majority are between 1μ and 2.5μ in diameter. (The red blood corpuscles of the host measure on an average about $20 \times 10\mu$.)

The micro-photographs and drawings accompanying this article will give an idea of the variation in size and shape of the parasites.

The smallest forms are either anaplasmod bodies consisting of a chromatin granule or small ring-shaped bodies. It would almost seem as if the ring-shaped bodies, in some cases at least, arise out of the anaplasmod bodies by the appearance and gradual enlargement of a "vacuole" or "lumen" in the centre of the chromatin granule. However, in other cases the ring-shaped bodies are formed as such, as we shall see below.

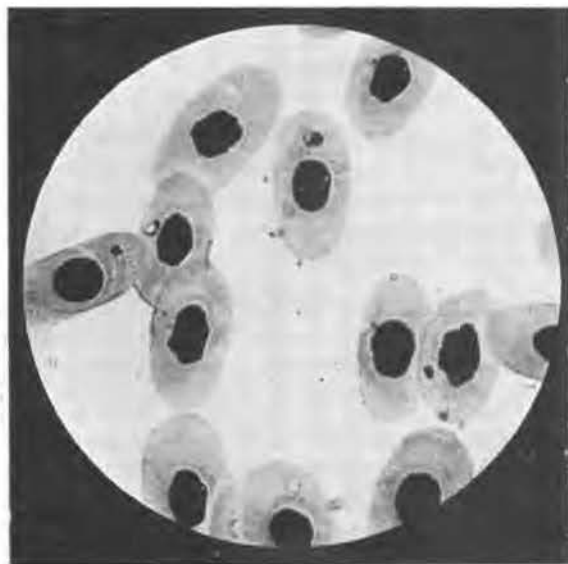

Fig. 1 (a).

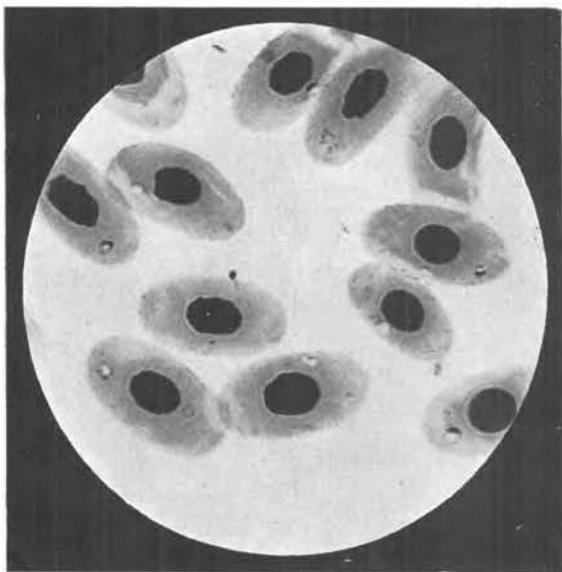


Fig. 1 (b).

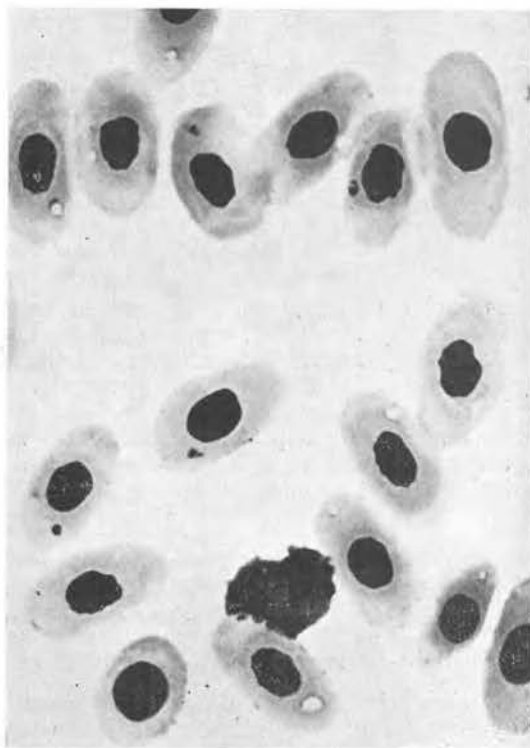


Fig. 1 (c).

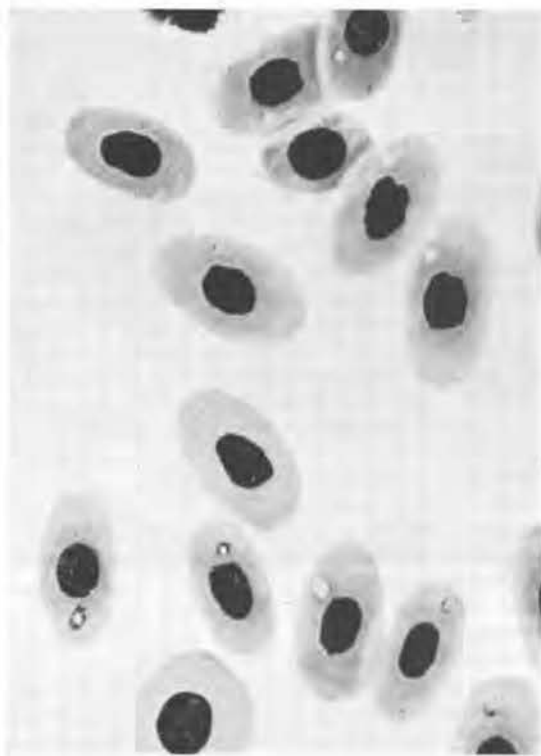

Fig. 1 (d).

Fig. 1 [(a), (b), (c) and (d)].—*Sairoplasma thomasi* in the blood of *Zonurus giganteus*. Note the large, clear "vacuoles" in some of the parasites. Magnification 1000 \times .

The great majority of parasites are more or less ring-shaped. Some are almost perfectly spherical, whereas others are irregular in outline. In most of the parasites the periphery of the ring is clearly marked, partly by well-stained cytoplasm, partly by nuclear material; however, in some the chromatin is only faintly visible. Frequently the nucleus sits like a cap on one side of the spherical parasite, giving it the appearance of a signet ring. In other instances the nuclear material almost or completely surrounds the cytoplasmic body.

The central portion of these parasites is almost invariably clear. Whether an actual vacuole is present cannot be stated with certainty, but this is the impression which is conveyed. Because of their clear centre, which lets the light through, these parasites are very easily recognized in stained blood smears.

In some parasites the degree of staining seems to be more intense, probably because of a relatively larger amount of nuclear matter. Such parasites appear as dark masses of round or irregular shape. Sometimes a small area of clear cytoplasm is visible.




Fig. 2.—Diagrammatic illustration of the process of multiplication in *Sauroplasma thomasi*. In the upper row division takes place by binary fission; in the lower row by a process of budding.

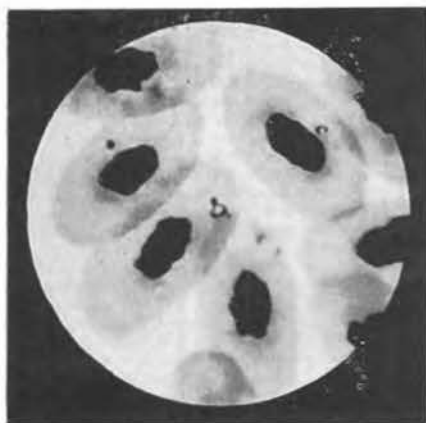The process of multiplication in these parasites is interesting. Apparently multiplication invariably takes place by a process of division into two. In the accompanying microphotographs and drawings the process is clearly illustrated. It would seem that there are two methods by which this division into two is achieved. In the first (see Fig. 2) the spherical parasite elongates; the nuclear material concentrates at the two opposite ends. Then a constriction appears in the middle of the elongated parasite. This constriction continues until two separate and approximately equal daughter cells are formed.

The same result is achieved by the second method which is a process of budding. On the outer surface of the spherical parasite a bud appears, which at first seems to consist of solid chromatin. Soon more material is extruded at this point so that the bud acquires a lumen. The bud continues to grow until it has approximately the same size as the mother cell when, by a process of constriction, the two cells become separated. It should be noted that this process is very similar to that by which multiplication takes place in many species of piroplasms.

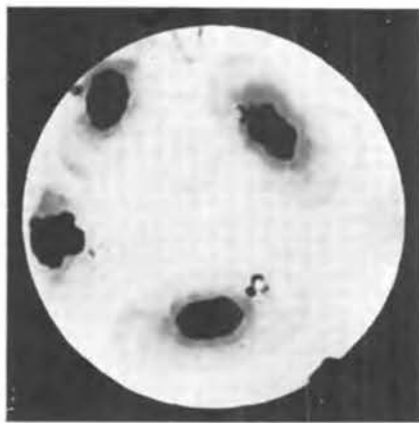
These two processes may be referred to as "binary fission" and "budding" respectively (see Figs. 3 and 4).

DISCUSSION.

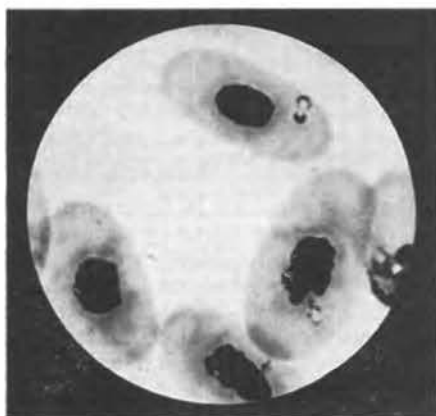The parasites here described seem definitely to belong to the family Piroplasmidae (or Babesidae). Their intracorpuseular situation, the absence of pigment, their mode of multiplication, their size and shape are all features which characterize the piroplasms.



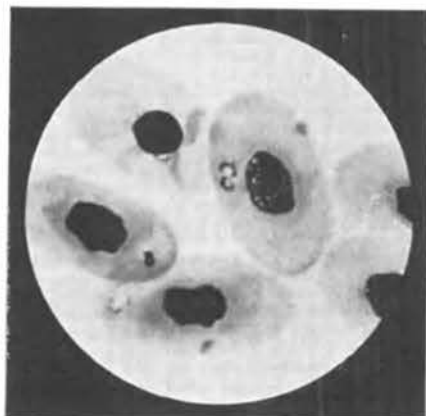(a)



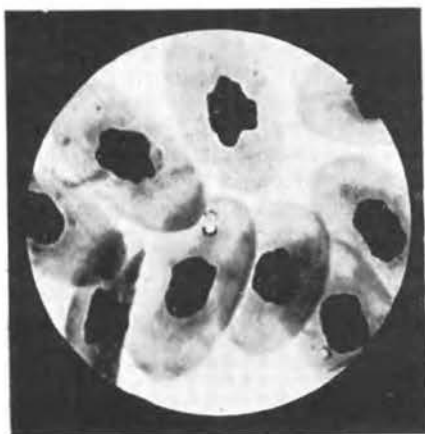(b)



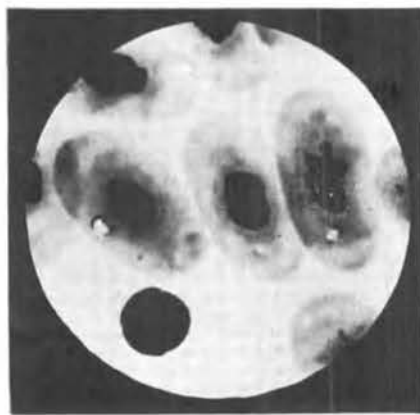
(c)



(d)



(e)



(f)

Fig. 3.—A series of microphotographs of *Sauroplasma thomasi* illustrating the process of "budding". (a) Appearance of small bud consisting of solid chromatin. (b) Enlargement of bud. (c) Appearance of lumen in bud. (d) Growth of daughter cell. (e) Two cells practically the same size. (f) Two daughter cells side by side. Magnification 1,250 \times .

When these parasites were first observed in the blood of the lizard it was thought that they might belong to the genus *Aegyptianella* of birds. However a closer study immediately revealed many points of difference. The most important of these is the absence of any process suggesting schizogony in the lizard parasite.

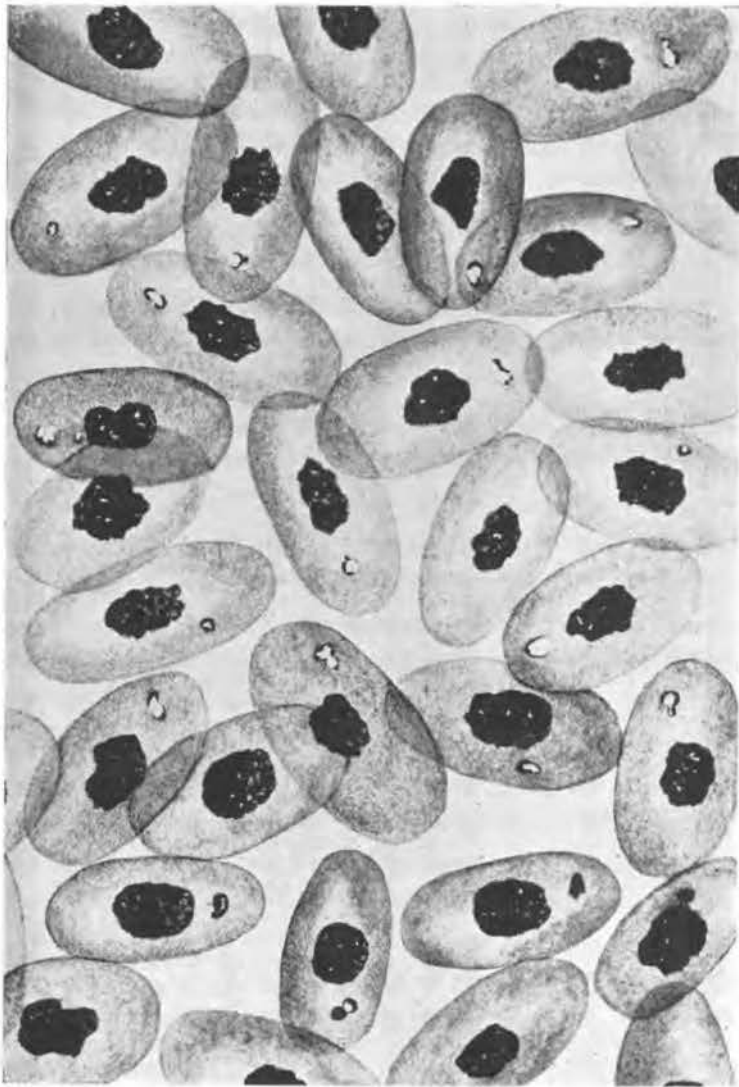

Fig. 4.—Composite drawing of red blood corpuscles of *Zonurus giganteus* infected with *Sauroplasmia thomasi*. Note the divisional forms; both the process of "budding" and that of "binary fission" are illustrated.

A comparison with *Tunetella emydis* of the tortoise also shows that the two parasites differ from each other in many respects. The large forms of *Tunetella* are much larger than the lizard parasites; and the small basophilic spots which form such an important feature of the infection in the tortoise have no counterpart in the lizard. Nothing resembling the "pseudo-schizogony" described by Brumpt and Lavie has been seen in the lizard.

Attention should here be directed to an article by Coles appearing in this Journal, in which a parasite of fowls is described that certainly shows a close resemblance to our parasite of the lizard. A comparison of the microphotographs of Coles' parasite with those appearing in this article will reveal the similarity.

The question whether these piroplasms of the lizard can be placed in any existing genus of the family Piroplasmidae (Babesidae) is difficult to answer in the present state of our knowledge. Many features seem to separate this species from the known piroplasms of mammals, and the differences which separate it from the genus *Tunetella* have already been referred to. It is therefore proposed to create a new genus for this parasite and to call it, in honour of Dr. A. D. Thomas who discovered the infection in the lizard, *Sauroplasma thomasi*.

The genus *Sauroplasma* could be defined as follows: Small, round or irregularly shaped unpigmented parasites of the red blood corpuscles of lizards. The typical form is that of a ring or signet ring with a large vacuole. Multiplication takes place by binary fission or by a process of budding.

It may be added that the two lizards in which these parasites were found appeared to be completely healthy. The infected blood showed no signs of anaemia. It would thus appear that in this case, as in so many other parasitic infections of wild animals, the parasites have no pathological effect on their host, but live in perfect harmony with the host.

A few further specimens of *Zonurus giganteus* which were examined showed no infection of the blood.

In regard to the mode of transmission of these parasites nothing is known at present. No ticks were seen on the specimens that were caught. Nevertheless it is regarded as most likely that *Sauroplasma*, like all other piroplasms, is transmitted by ticks.

SUMMARY.

A parasite is described which infects red blood corpuscles of the giant girdle-tailed lizard *Zonurus giganteus*, Smith. The relationship of this parasite to other organisms is discussed and the conclusion is reached that it represents a new genus of the sporozoan family Piroplasmidae (Babesidae). The name *Sauroplasma thomasi* is proposed for it.

LITERATURE.

- BALFOUR, A. (1907.) A peculiar blood condition, probably parasitic, in Sudanese fowls. *Jnl. Trop. Med. and Hyg.*, Vol. 10, p. 153.

- BRUMPT, E., AND LAVIER, G. (1935, a). Sur un hématozoaire nouveau du lizart vert, *Pirhemocytton lacertae* n. sp. *Ann. Parasit. hum. et comp.*, Vol. 13, pp. 537-543.
- BRUMPT, E., AND LAVIER, G. (1935, b). Sur un Piroplasmidé nouveau, parasite de tortue *Turdella emydis* n.g., n.sp. *Ann. Parasit. hum. et comp.*, Vol. 13, pp. 544-550.
- CARPANO, M. (1929). Su di un Piroplasma osservato nei polli in Egitto (*Aegyptianella pullorum*). *La Clinica veterinaria*, T. 52, pp. 339-351.
- CHATTON, E., AND BLANC, G. (1914). Sur un hématozoaire nouveau, *Pirhemocytton tarentolae*, du Gecko, *Tarentola mauritanica*, et sur les altérations globulaires qu'il détermine. *C. R. Soc. Biol.*, Vol. 77, pp. 496-498.
- CHATTON, E., AND BLANC, G. (1916). Précisions sur la morphologie de l'hématozoaire endoglobulaire de la Tarente: *Pirhemocytton tarentolae* Chatton et Blanc. *C. R. Soc. Biol.*, Vol. 79, pp. 39-43.
- COLES, J. D. W. A. (1937). A new blood parasite of the fowl. *This Journal*.
- DOFLEIN, F., AND REICHENOW, E. (1929). *Lehrbuch der Protozoenkunde*. Jena.
- HENRY, H. (1910). On the haemoprotozoa of British sea-fish. (A preliminary note). *Jnl. Path. and Bact.*, Vol. 14, pp. 463-465.
- HENRY, H. (1913). An intracorpuseular parasite in the blood of *Cottus bubalis* and *Cottus scorpius*. *Jnl. Path. and Bact.*, Vol. 18, pp. 224-227.
- WENYON, C. M. (1926). *Protozoology*. 2 Vols. London.