

Subpubic cartilaginous cyst: A rare cause of a pelvic soft tissue mass

Registrar: A Chacko* MBBCh(Wits), FC Rad Diag(SA)

Registrar: S Vedajallam* MBBChB(Stell), FC Rad Diag(SA)

Consultant: NZ Makhanya MBChB(Medunsa), MMed Diag Rad(Medunsa), FC Rad Diag(SA)

Department of Radiology, Steve Biko Academic Hospital, University of Pretoria, Pretoria

* Registrar at the time of writing this article, now in private practice in East London

Corresponding author:

Email: anithchacko@gmail.com

Abstract

We present a rare case of subpubic cartilaginous cyst in a multiparous female patient as a cause of a pelvic soft tissue (vulvar) mass. We discuss the relevant imaging and differential diagnosis as well as specific considerations in making the diagnosis of a subpubic cartilaginous cyst.

Key words: subpubic cartilaginous cyst, pelvic soft tissue mass, vulvar mass

Introduction

Subpubic cartilaginous cyst is an unusual, benign, cystic lesion arising secondary to degenerative change in the symphysis pubis. To our knowledge only 11 reported cases are present in worldwide literature. We describe the presentation and imaging findings, and discuss the differential diagnosis in a 61-year-old multiparous female.

Case report

The patient presented to the Gynaecology Department of our institution as a referral for work-up of a slowly enlarging painful mass deep to the labia. The mass had been present and enlarging slowly over approximately the past two years. The initial presumed diagnosis was a vulvar carcinoma.

The patient was thereafter referred to the Department of Radiology for a contrast-enhanced computed tomography study following an ultrasound, which showed a well-circumscribed mass under the symphysis pubis and within the mons pubis and underneath the labia.

Plain film radiography (*Figure 1*) showed a well-circumscribed soft tissue mass inferior to the symphysis pubis with no bony involvement. On computed tomography the well-circumscribed and cystic mass was demonstrated just inferior to the symphysis pubis and with a wide margin of contact with the symphysis being noted. Fluid within the cyst measured 28HU indicating a complex fluid consistency. No significant enhancement of the walls of the cyst was demonstrated (*Figures 2 and 3*). The study was otherwise unremarkable with no evidence of malignancy or lymphadenopathy.

A preliminary diagnosis of a subpubic cartilaginous cyst (SCC) was made on imaging findings with a differential diagnosis of pseudo-synovial cyst associated with the symphysis pubis and subchondral cyst formation.

Complete surgical excision was performed and the histology was confirmatory of a cystic structure with a thick fibrous wall. Contents were amorphous, scattered eosinophilia and overall chondrocytic. There were areas of scattered chronic inflammation within the wall with no malignancy present. The lesion was also noted to be associated closely to the pubic symphysis.

Subpubic cartilaginous cyst is an unusual, benign, cystic lesion arising secondary to degenerative change in the symphysis pubis. To our knowledge only 11 reported cases are present in worldwide literature

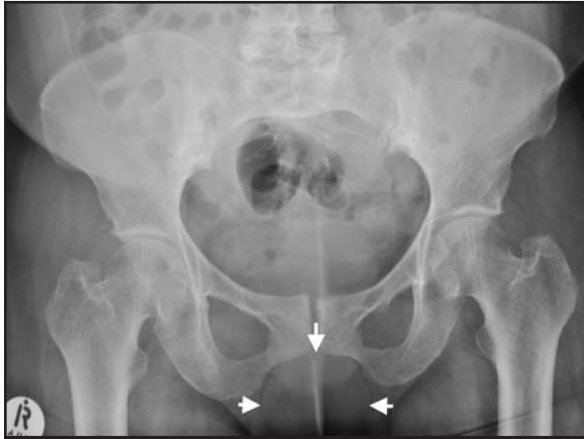

Figure 1. Antero-posterior plain pelvic radiograph shows well-circumscribed soft tissue mass just below the pubic symphysis.

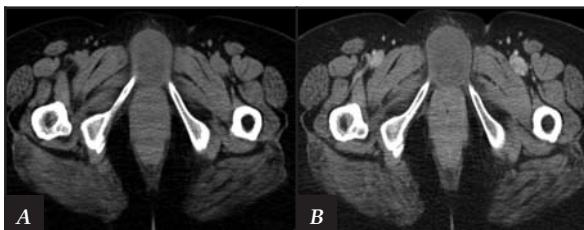


Figure 2. Axial non-contrast (A) and contrast enhanced (B) computed tomography images demonstrate the well-circumscribed nature of the cyst with no enhancement and homogeneous contents within.

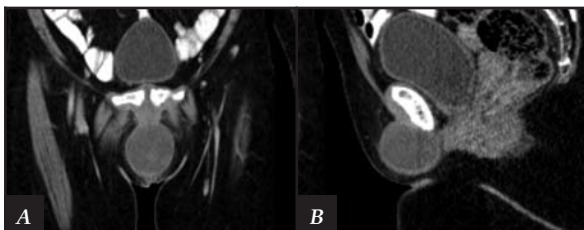


Figure 3. Coronal (A) and sagittal (B) post-contrast computed tomography images demonstrate the subpubic position of the cyst with its close relation to the pubic symphysis.

Discussion

Subpubic cysts are rare and poorly understood forms of ganglion cysts that originate from the symphysis pubis and are degenerate in nature. They are usually encountered in multiparous women and generally accompanied by narrowing, subchondral sclerosis and marginal spur formation of the symphysis pubis.¹

In general it is easy to differentiate between the various possibilities due to differences in actual location and radiological characteristics

Diagnosis is based upon clinical examination and radiological evaluation. The radiological diagnosis of the SCC depends on the demonstration of mucinous material and chondrocytic constitution of the contents. This results in a dense presentation on ultrasonography, a high density in computed tomography images and a heterogeneous intensity on T1 and T2 magnetic resonance imaging sequences.² The imaging characteristics as well as the location and close relation to the inferior surface of the symphysis pubis all enable an accurate radiological diagnosis.³

The differential diagnosis to consider in patients presenting with vulvar masses includes lipomas, nabothian, Bartholin's, Gartner's or paratubal cysts. Other malignant masses such as squamous cell carcinoma, Bartholin's gland carcinoma, basal cell carcinoma and vulvar melanoma should also be considered in the differential. In general it is easy to differentiate between the various possibilities due to differences in actual location and radiological characteristics. In terms of location only two other causes should be considered when the lesion occurs in close relation to the inferior border of and originates from the symphysis pubis, namely pseudosynovial cysts and large subchondral cysts.¹ Magnetic resonance imaging is particularly helpful in characterising and differentiating the various lesions.⁴

The treatment of choice is resection, as aspiration is not possible due to the bulky content of the cysts.¹ To our knowledge recurrences have not been reported in the literature.

Conclusion

Subpubic cartilaginous cysts occur rarely but should be considered in the differential diagnosis when multiparous female patients present with vulvar masses. Radiological diagnosis is clear on consideration of imaging characteristics and the anatomical location of the cyst. Surgical excision is curative.

The content of the article is the original work of the authors. No benefits of any form have been or are to be received from a commercial party related directly or indirectly to the subject of the article.

References

1. Hoogendoorn RJW, Kayser HWM, Weening JJ, Van Geloven AAW. Subpubic cartilaginous cystic lesion presenting as a vulvar mass: a case report. *J Med Case Rep* 2009;3:7294.
2. Ergun T, Lakadamyali H, Aydin O. Subpubic cartilaginous cyst: incidental finding detected by abdominopelvic computed tomography. *Radiat Med* 2008;26:46-49.
3. Kim CE, Beasley HS. MRI diagnosis of subpubic cartilaginous cyst. *AJR Am J Roentgenol* 2004;182:144-46.
4. Gilmour DT, Adams CL, Anderson PA, Gupta R, Parish B, Schmidt MH. Cartilaginous symphysis pubis cysts: report of two cases, technique for removal, and review of the literature. *Female Pelvic Med Reconstr Surg* 2010;16:71-76.

This article is also available online on the SAOA website (www.saoa.org.za) and the SciELO website (www.scielo.org.za). Follow the directions on the Contents page of this journal to access it.