

FURUNCULOSIS IN RAINBOW TROUT (*SALMO GAIRDNERI*) RAISED IN SEA WATER

J. BOOMKER¹, M. M. HENTON², T. W. NAUDÉ², and F. W. HUNCHZERMEYER²

ABSTRACT

BOOMKER, J., HENTON, M. M., NAUDÉ, T. W. & HUNCHZERMEYER, F. W., 1984. Furunculosis in rainbow trout (*Salmo gairdneri*) raised in sea water. *Onderstepoort Journal of Veterinary Research*, 51, 91-94 (1984).

Ulcerative skin lesions were encountered in rainbow trout raised in sea water by a commercial concern in the Western Cape, South Africa. Grossly, the lesions resembled furunculosis but, histopathologically, they differed from typical furunculosis in that bacterial colonies were rarely found in the organs, and also the kidneys and spleens were minimally involved. The causative organism was identified as an achromogenic *Aeromonas salmonicida* that shared characteristics with all 3 subspecies, *salmonicida*, *masoucida* and *achromogenes*. This is the first report of an outbreak of this disease in South Africa.

INTRODUCTION

A commercial trout concern in the Western Cape, which produces about 6 tons of fish per month, hatches local or imported eggs and raises the fry to fingerling size on the first farm where they have the required facilities but only a limited supply of suitable fresh water. The fingerlings are then transported by tanker to a second farm (c. 30 km away) with an abundant supply of suitable fresh water, where they are raised to a mass of c. 170 g. The fish are finally moved to the Atlantic ocean to a third property on the West Coast, a distance of c. 140 km away. After a short period of adaptation to sea water, they are raised to market size in large, portable plastic pools under roof in full sea water which is pumped from about 200 m offshore. The temperature of the sea water never exceeds 17 °C.

The fish are fed dry pelleted food until they are put into the sea water, when their diet is changed to a wet mash consisting of 50 % meal and 50 % fresh fish or crayfish scraps obtained from factories in the vicinity.

In January 1980, the trout concern encountered ulcerative dermatitis involving small numbers of fish on the second farm. Affected fish were culled as soon as the ulcers were seen, but the incidence increased and severe mortalities were eventually experienced. No fish were presented for investigation, but treatment of the feed with nitrofurantoin and oxytetracycline was instigated with reasonable success.

In September 1981, severe mortalities again occurred, but this time on the third farm at the sea. Mortalities were as high as 30 % per pool, but these were confined to only 3 out of the 40 pools in production at the time of investigation. During a passing visit to this farm, a tentative diagnosis of furunculosis was made, and, at our request, live, diseased fish from the third farm and fish from the first and second farms were air-freighted to the Veterinary Research Institute, Onderstepoort, for an investigation of the cause of the mortalities.

MATERIALS AND METHODS

Several live fish from each farm were received and immediately necropsied, and samples for bacteriology were taken. The latter consisted of swabs taken from the actual skin lesions as well as pieces of skin and muscle bordering the lesions. Various internal organs, the eyes and the fins of the fish from the first farm were also collected and initially cultured at 22 °C on blood tryptose agar (BTA)*, MacConkey-agar* and serum broth containing 10 % serum.

¹ Department of Parasitology, Faculty of Veterinary Science, University of Pretoria, P.O. Box 12580, Onderstepoort, 0110

² Veterinary Research Institute, Onderstepoort, 0110

Received 24 January 1984—Editor

Wet smears from the body surface, gills and intestines were prepared and immediately examined for the presence of parasites, using a microscope with Nomarski's differential interference contrast illumination.

Blood smears and impression smears of the spleen and kidney were made according to standard techniques (Wintrobe, 1947). Some impression smears were examined without prior staining, while others, together with the blood smears, were fixed in absolute acid-free methyl alcohol for 3 min. and stained with 5 % Giemsa stain buffered at pH 6.8-7.0 for 45 min.

Smears from the primary and subsequent bacterial isolates were also made and examined, either without prior staining, or after staining with the Gram stain.

Tissues for histopathology were collected in 10 % neutral buffered formalin. They were embedded in paraffin wax, sectioned at 5-6 µm and routinely stained with haematoxylin and eosin (HE). Tissue sections of selected cases were also stained with Wohlbach's modification of the Giemsa stain and the Humberstone stain (Thompson, 1970).

RESULTS

Parasitology

Apart from a few individuals of a *Trichodina* sp. found in the gill smears of some fish from the first and second farms, no parasites were encountered.

Gross pathology

Fish from the first farm showed tattered and necrotic fins only, a condition which was diagnosed as fin rot.

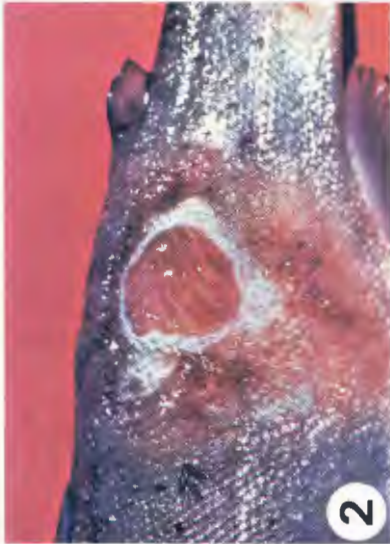Some fish from the second farm had mild exophthalmos and 2 had small shallow ulcers on the tip of the snout.

The most severe lesions were seen on the skins of fish from the third farm. The lesions were present laterally on the flanks between the dorsal and adipose fins, and varied from small vesicles, 1-3 mm in diameter, to large shallow ulcers, 10-15 mm in diameter (Fig. 1). Centrally, the ulcers consisted of exposed haemorrhagic muscles surrounded by a zone of greyish-white necrotic tissue. This in turn was surrounded by a zone of active inflammation, characterized by vesicles of various sizes and extensive petechiation (Fig. 2). The internal organs of these fish showed few gross changes. There was slight splenomegaly, slight yellow discoloration of the liver, and slight enlargement of the kidney.

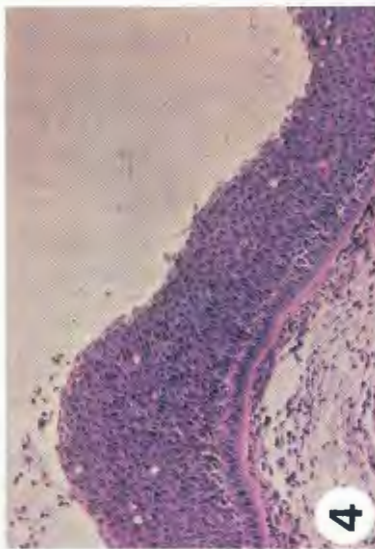
* Difco Laboratories, Detroit, USA



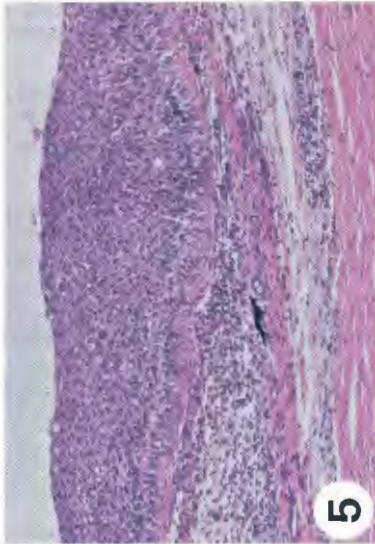
1



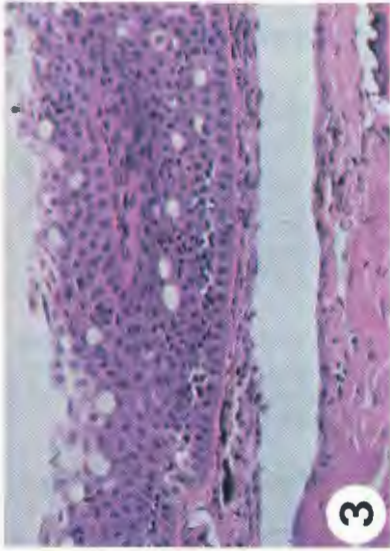
2



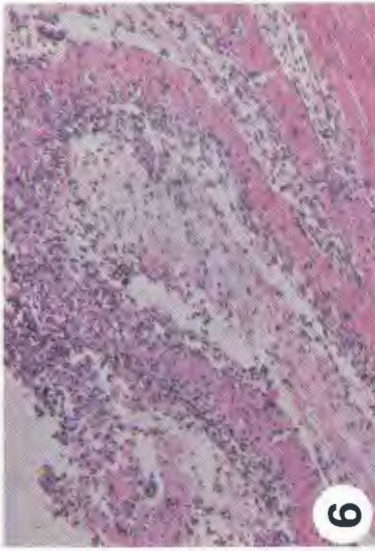
3



4



5



6



7

FIG. 1 Rainbow trout showing position and size of skin lesions

FIG. 2 Close-up of lesion, showing exposed muscles surrounding zone of active inflammation and vesicles (arrow)

FIG. 3 Cross-section of a vesicle, with zone of clear fluid separating hyperplastic epidermis and basal membrane from muscles: HE \times 400

FIG. 4 Clear fluid in vesicle is replaced by fibrinoid exudate containing many lymphocytes and macrophages: HE \times 200

FIG. 5 Hyperplastic skin, degeneration of basal membrane and early interstitial myositis: HE \times 200

FIG. 6 Extensive necrosis and sloughing of skin and superficial muscle layers: HE \times 200

FIG. 7 Ulcer, covered by thin layer of necrotic skin; note degenerative changes of muscles and wide separation of individual muscle bundles. There is virtually no cellular reaction: HE \times 200

Histopathology

No histopathologic lesions were encountered in the organs of the fish from the first farm.

The lesions on the snouts of the fish from the second farm were histologically similar to those seen in the skins of the fish from the third farm but were of a more chronic nature.

The initial lesion in the skins of trout from the third farm consisted of a small vesicle covered by a thickened epidermis. The basal membrane was intact and was separated from the underlying muscles by a clear fluid (Fig. 3). A few lymphocytes and macrophages were present in the hypodermis.

As the condition progressed, the epidermis became more hyperplastic and the clear fluid was replaced by a fibrinoid exudate containing many lymphocytes and macrophages (Fig. 4). The basal membrane was progressively destroyed and the cellular infiltration became pronounced. At this stage there also was an interstitial myositis of the upper muscle layers which was characterized by the influx of many lymphocytes (Fig. 5). Moderate to advanced degenerative changes were seen in the epithelial cells of the hypodermis and the superficial muscle cells. Necrosis ensued, and the cellular reaction became less marked (Fig. 6). Haemorrhages resulting from vascular destruction, though common, were limited to the hypodermis and superficial muscle layers (Fig. 6). The entire skin and parts of the superficial muscle sloughed, exposing the deeper muscles, which were widely separated from each other (Fig. 7). There was virtually no tissue reaction and although there was considerable tissue destruction, attempts at regeneration were not seen.

The spleens were severely congested, and there was some destruction of the ellipsoids. This, however, was very slight and only a few ellipsoids were involved.

In the middle third of the kidney slight vasculitis was encountered as well as early degeneration of tubular epithelium.

The liver was slightly congested, and a few small haemorrhages occurred in the parenchyma.

Bacterial colonies were very scarce, and were encountered only in sections of the skin.

Bacteriology

Pseudomonas aeruginosa and *Aeromonas punctata punctata* were isolated from the fins of the fish from the first farm. Both these bacteria are known to be associated with fin rot (Reichenbach-Klinke, 1966).

From the fish originating from the second farm, *P. aeruginosa* and *Aeromonas hydrophila hydrophila* were isolated from the eyes and internal organs, while *Aeromonas salmonicida* was isolated from the lesions on the snouts.

On primary isolation, the specimens from fish from the third farm yielded a virtually pure growth of greyish, non-haemolytic colonies, 1–2 mm in diameter, on the BTA plates. The colonies were yellow on MacConkey-agar. Smears stained with the Gram stain showed the organisms to be short, straight gram-negative rods. The organisms were pigmented pale golden-brown on unstained smears made directly from organs. The pigmentation of the organism was lost on culture, and visible pigmentation of colonies occurred only after 14 days' incubation at 22 °C, when they assumed a light beige colour.

The isolate grew well at 22 °C, both aerobically and anaerobically, but no growth occurred at 37 °C. It was positive for cytochrome oxidase and weakly positive for catalase. Both glucose and glycerol were fermented, but no gas was produced. Sugars that were fermented were galactose, sucrose, mannitol, arabinose, maltose and aesculin. Trehalose, dulcitol and inositol were not fermented. The nitrite test was positive, but indol was not produced, even after prolonged incubation. Gelatin was rapidly liquefied, but there was no growth in broth at pH 9. The bacterial isolate agglutinated in 0,85 % saline, but not in 0,05 % (1:2000) acriflavin.

On the basis of these characteristics the isolate was identified as *A. salmonicida* (Buchanan & Gibbons, 1974) and is henceforth referred to as the DH1950 isolate. However, it could not be identified as belonging to any of the subspecies *salmonicida*, *masoucida* or *achromogenes*, since it had characteristics common to all 3 subspecies.

Antibiograms proved the isolate to be highly sensitive to several tetracyclines, chloramphenicol, all the nitrofurans, polymyxin B, co-trimoxazole, and framycetin, and reasonably sensitive to virginiamycin.

DISCUSSION

Furunculosis is a disease of numerous fish species and has long been recognized. It is commonly seen in freshwater salmonids (McGraw, 1952; Herman, 1968) and has recently been recorded from cultured Atlantic salmon (Rolstein, 1975, cited by McCarthy & Roberts, 1980), amago (*Oncorhynchus rhodurus*) (Miyazaki & Kubota, 1975), Atlantic salmon that are returning to their spawning grounds (Weber & Zwicker, 1979, cited by McCarthy & Roberts, 1980), as well as from a number of non-salmonid sea fishes (Scott, 1968; Evelyn, 1971; Larsen & Jensen, 1979). As far as could be ascertained, this is the first report of furunculosis in rainbow trout raised in sea water. This is also the first report of the disease occurring in South Africa.

The most recent information on the bacteriology and pathology of furunculosis is provided by McCarthy & Roberts (1980), and from this it appears that the DH 1950 isolate is another in the rapidly increasing number of atypical *A. salmonicida*. This isolate is probably one of the achromogenic variants (McCarthy, 1975), since little pigment is produced and then only after prolonged incubation. In addition, it does not cause the extensive lesions in the spleen, kidney and heart as described for brown trout (Ferguson & McCarthy, 1978) or the changes in the spleen and kidney of rainbow trout, as described by Klontz, Yasutake & Ross (1966).

A possible cause of the variation in the lesions caused by different isolates of *A. salmonicida* has been forwarded by Ellis, Hastings & Munro (1981). They state that the lesions in the internal organs are probably the result of colonization by the bacteria, and that the kidney and spleen are usually affected because they are phagocytic filter beds. The muscle lesions result from the protease fraction of extracellular products produced by the bacteria, and the intracellular and lysosomal myoproteases that are released during muscle necrosis may enhance the effect of the bacterial proteases (Ellis *et al.*, 1981). The DH1950 isolate does not seem to colonize the tissues to the same extent as that described for other isolates, with the result that the kidney and spleen are minimally affected.

Ellis *et al.* (1981) stated that 2 features of furunculosis are prominent in the literature. These are the collagenolytic lesions and the eventual suppression of the leucocytic response to inflammation. These factors, together with haemolytic and inhibitory factors to normal cell behaviour, have been shown to be present in extracellular products produced by the bacterium *in vitro* (Munro, Hastings, Ellis & Liversidge, 1980). In view of the presence of muscular haemorrhages, the lack of leucocytic response to the inflammation in the skin lesions and the absence of attempts of regeneration of diseased tissues, we concluded that the DH1950 isolate also produces the extracellular factors described for many of the isolates (Klontz *et al.*, 1966; Munro *et al.* 1980; Fuller, Pilcher & Fryer, 1981).

It is possible that *A. salmonicida* was introduced into the country via contaminated eyed ova, and then carried through the various rearing stages. As susceptibility and stresses, such as stocking density, transport and adaptation to sea water, increase with the size and age of the fish, the presence of *A. salmonicida* was not detected earlier.

According to Wedemeyer & Wood (1974), stress is an important predisposing factor in outbreaks of furunculosis in trout. In fact, Hill (1981, personal communication) recommends as diagnostic procedure injections with prednisolone to bring out latent *A. salmonicida* infections.

The following control measures are recommended by Ghittino & De Kinkelin (1975): disinfection of ova as well as of empty tanks and equipment, antibacterial treatment of batches of fish at risk, vaccination, stress prevention and import control.

In the case under discussion, the following measures were applied successfully: treatment with oxytetracycline, 7.5 g of active substance/100 kg of fish/day for 10 days, disinfection of tanks after the removal of fish and the reduction of the stocking density. As additional measures, the water on the fresh-water sides was aerated to reduce stress, and nifurpirinol* at 0.01 mg/l in the recirculated water was used prophylactically during the adaptation period to sea water. These measures have led to the disappearance of the clinical signs and the control of the outbreak.

ACKNOWLEDGEMENTS

The authors wish to express their thanks to the staff of the Department of Pathology, Faculty of Veterinary Science, University of Pretoria, and that of the Section of Bacteriology, Veterinary Research Institute, Onderstepoort, for their technical assistance.

* "Furanace", Abbott Laboratories.

REFERENCES

- BUCHANAN, R. E. & GIBBONS, N. E., 1974. *Bergey's Manual of determinative bacteriology*. (8th ed.). Baltimore: Williams & Wilkins.
- ELLIS, A. E., HASTINGS, T. S. & MUNRO, A. L. S., 1981. The role of *Aeromonas salmonicida* extracellular products in the pathology of furunculosis. *Journal of Fish Diseases*, 4, 41-51.
- EVELYN, T. P. T., 1971. An aberrant strain of the bacterial fish pathogen *Aeromonas salmonicida* isolated from a marine host, the sablefish (*Anoplopoma fimbria*) and from two species of cultured Pacific salmon. *Journal of the Fisheries Research Board of Canada*, 28, 1629-1634.
- FURGUSON, H. W. & MCCARTHY, D. H., 1978. Histopathology of furunculosis in brown trout, *Salmo trutta* L. *Journal of Fish Diseases*, 1, 165-174.
- FULLER, D. W., PILCHER, K. S. & FRYER, J. L., 1977. A leucocytic factor isolated from cultures of *Aeromonas salmonicida*. *Journal of the Fisheries Research Board of Canada*, 34, 1118-1125.
- GHITTINO, P. & DE KINKELIN, P., 1975. Proposed control measures for the principal contagious diseases of fish. *Bulletin de l'Office international des epizooties*, 83, 689-715.
- HERMAN, R. L., 1968. Fish furunculosis. *Transactions of the American Fisheries Society*, 97, 221-230.
- KLONTZ, G. W., YASUTAKE, W. T. & ROSS, A. J., 1966. Bacterial diseases in the Salmonidae in the Western United States: pathogenesis of furunculosis in rainbow trout. *American Journal of Veterinary Research*, 27, 1455-1460.
- LARSEN, J. L. & JENSEN, N. J., 1979. An *Aeromonas* species implicated in ulcer disease of the cod (*Gadus morrhua*). *Nordisk Veterinär Medisin*, 29, 199-211.
- MCCARTHY, D. H., 1975. Fish furunculosis caused by *Aeromonas salmonicida* var. *achromogenes*. *Journal of Wildlife Diseases*, 11, 489-493.
- MCCARTHY, D. H. & ROBERTS, R. J., 1980. Furunculosis of fish—the present state of our knowledge. *Advances in Aquatic Microbiology*, 2, 293-341.
- McGRAW, B. M., 1952. Furunculosis of fish. United States Fish and Wildlife Services, Special Scientific Report, 84, 1-87.
- MIYAZAKI, T. & KUBOTA, S. S., 1975. Histopathological studies on furunculosis in amago. *Fish Pathology*, 9, 213-218.
- MUNRO, A. L. S., HASTINGS, T. S., ELLIS, A. E. & LIVERSIDGE, J., 1980. Studies on an ichthyotoxic material produced extracellularly by the furunculosis bacterium, *Aeromonas salmonicida*. Proceedings of the 3rd session of the EIFAL (FAO)/OIE Co-operative Programme of Research on Aquaculture: Fish Diseases, Munich, 1979. Berlin: Springer-Verlag.
- REICHENBACH-KLINKE, H.-H., 1966. *Krankheiten und Schädigungen der Fische*. Stuttgart: Gustav Fischer Verlag.
- SCOTT, M., 1968. The pathogenicity of *Aeromonas salmonicida* (Griffin) in sea and brackish waters. *Journal of General Microbiology*, 50, 321-327.
- THOMPSON, S. W., 1970. *Selected histochemical and histopathologic methods*. Springfield, Ill., U.S.A.: Charles C. Thomas.
- WEDEMEYER, G. A. & WOOD, J. W., 1974. Stress as a predisposing factor in fish diseases. U.S.D.I. Fish and Wildlife Services, Division Cooperative Research, Fish Disease Leaflet 38.
- WINTROBE, M. M., 1947. *Clinical haematology* (2nd ed.). Philadelphia: Lea & Febiger.