

***Sarcocystis oreamni*, n. sp. (Apicomplexa: Sarcocystidae) from the mountain goat (*Oreamnos americanus*)**

Rafael Calero-Bernal¹. Erna Van Wilpe³. Kevin White². Shiv K. Verma¹. Camila K. Cerqueira-Cézar¹. Jitender P. Dubey^{1,*}

¹United States Department of Agriculture, Agricultural Research Service, Beltsville Agricultural Research Center, Animal Parasitic Diseases Laboratory, Beltsville, Maryland 20705-2350, USA.

²Alaska Department of Fish and Game, Division of Wildlife Conservation, Juneau, Alaska, 99811, USA.

³Department of Anatomy and Physiology, Faculty of Veterinary Science, University of Pretoria, Onderstepoort, 0110, South Africa.

Running Title: Sarcocystis species in mountain goat

*Corresponding author: J.P. Dubey, jitender.dubey@ars.usda.gov

Abstract

Numerous species of *Sarcocystis* have been reported from wild ruminants but none has been named from the Rocky Mountain goat (*Oreamnos americanus*). Mature sarcocysts were found in frozen muscle samples of three of seven mountain goats from Alaska, USA. Two morphological types of sarcocysts were found; one had *Sarcocystis cornagliai*-like sarcocysts, previously named from the Alpine ibex (*Capra ibex*) from Europe. Two other goats were infected with a new species, *Sarcocystis oreamni*. *Sarcocystis oreamni* sarcocysts were microscopic with 2 µm-thick sarcocyst wall. By transmission electron microscopy, the sarcocyst wall had 1.7 µm-thick with unusual molar tooth-like villar protusions (vp), type 29. The vp had electron dense core and two disc-shaped plaques at the tip with fine microtubules. Bradyzoites were 8.6-9.1 µm long. Single nucleotide polymorphism (SNP) identified in *18S rRNA*, and *28S rRNA* loci of rDNA regions that suggested *S. oreamni* molecularly apart from related species. The phylogenetic analysis based on *18S rRNA*, and *28S rRNA* sequences suggested *S. oreamni* is related with *Sarcocystis* species that employ members of Canidae family as their definitive host..

Keywords

Mountain goat. *Oreamnos americanus*. *Sarcocystis*. Ultrastructure. Phylogeny.

Introduction

Mountain goat (*Oreamnos americanus*) is a Caprinae native species from North America; its dispersion range includes Western Canadian and US territories, specially on the Rocky Mountains. It is a sensitive species, susceptible to human activities and development. Flocks are largely protected from threats due to the inaccessible location of their habitats (Festa-Bianchet 2008).

Numerous species of *Sarcocystis* have been reported from wild ruminants but none has been named from the mountain goat (Dubey et al. 2015a). In two previous surveys, Mahrt and Colwell (1980) detected *Sarcocystis* sarcocysts in 11 of 15 Rocky mountain goats from Alberta, Canada, but did not describe the parasite. Foreyt (1989) found sarcocysts in 24 of 56 *O. americanus* from Washington State, USA. He described structure of the sarcocyst with distinctive type 24 sarcocyst wall (Dubey et al. 1989, 2015a), and performed extensive transmission experiments. None of the carnivores, including dog, cat and foxes excreted sporocysts. Here, we describe and name *Sarcocystis* sarcocysts isolated from mountain goat tissues from Alaska.

Material and methods

Samples collection

Small pieces (5 g) of skeletal muscle from seven adult Rocky Mountain goats (*O. americanus*) from different locations in Southeastern Alaska, USA, were collected between October 2013 and October 2014 and had been stored at -20 °C (Table 1). Animals were killed by hunters and archived by the Alaska Department of Fish and Game.

For the present study, samples were shipped frozen to the Animal Parasitic Diseases Laboratory, USDA, Beltsville, Maryland. Pieces of tissues (2 x 2 cm) were thawed and fixed in buffered formalin for histological examination.

Light (LM) and transmission electron (TEM) microscopy

Small pieces of frozen-thawed tissue were compressed in order to detect the presence of *Sarcocystis* sarcocysts; cysts were excised from the tissues and preserved in 20 µl sterile water until molecular analyses. Formalin-fixed tissues were embedded in paraffin, sectioned 5 µm thick and stained with hematoxylin and eosin (H and E). After examination of the H and E sections, cysts candidates for electron microscopy were excised with the help of a scalpel and processed as described by Dubey et al. (2015b).

Table 1 Mountain goats (*Oreamnos americanus*) from Alaska, USA: sample collection, and *Sarcocystis* spp. findings.

Animal #	Data of collection	Sex	Age (years)	Location in Southeast Alaska, USA (coordinates)	Muscle squash	H&E sections (# cysts/section)	TEM	Molecular characterization
1	August, 2014	Male	4	Rainbow Glacier (N59.1, W135.5)	Positive, thin-walled sarcocysts	Positive, striated thin wall (10)	Thin wall, molar-tooth like vp	NA
2	October, 2014	Female	NA	Sawmill Creek (N58.7, W134.9)	Positive, thin-walled sarcocysts	Positive, striated thin wall (7)	Thin wall, molar-tooth like vp	18S, 28S
3	September, 2014	Female	NA	Homesore (N58.3, W135.3)	Negative	Negative	NA	NA
4	October, 2013	Female	NA	Tracy Arm (N57.8, W133.2)	Negative	Negative	NA	NA
5	August, 2014	Male	NA	Rhine Peak (N58.2, W134.2)	Positive, striated, thick-walled sarcocysts	Positive, striated thick wall, long vp. (2)	Long vp, <i>S. cornagliai</i> -like	NA
6	November, 2013	Male	NA	William Henry Bay (N58.7, W135.2)	Negative	Negative	NA	NA
7	October, 2014	Female	NA	Sawmill Creek (N58.7, W134.8)	Negative	Negative	NA	NA

NA: no available; H and E: hematoxylin and eosin stain; TEM: transmission electron microscopy; Vp: villar protrusions.

Molecular analyses

Four individual cysts obtained from goats #1, #2, #4 and #5 (Table 1) were subjected to DNA isolation using DNeasy Blood and Tissue Kit (Qiagen Inc., Valencia, CA) according to manufacturer's instructions. Partial sequences of *18S rRNA*, *28S rRNA* and *ITS-1* were amplified as previously described by Yang *et al.* (2001), Gjerde and Josefsen (2015), and Gjerde (2014), respectively. Primer combinations 2L/2H/3H (in seminested PCR for *18S rRNA*), KL1/LS2R (in direct PCR for *28S rRNA*), and SU1F/5.8S (in direct PCR for *ITS-1*) yielded visible amplifications. Single amplicons of *18S rRNA* (~870 bp), *28S rRNA* (~925 bp), and *ITS-1* (~900 bp) were excised and purified using QIAquick Gel Extraction (Qiagen, Inc., Valencia, CA). Direct sequencing, in both directions and using same primers used for amplification, was carried out by external service (Macrogen Corporation, Rockville, MD). The resulting forward and reverse sequences were imported and edited, if necessary, using the software Geneious version 8.0.4 (Biomatters Ltd., Auckland, NZ). The sequences obtained were aligned against each other and the published sequences of various *Sarcocystis* spp. to detect interspecies variation at these loci respectively. Phylogenetic trees based on *18S rRNA* and *28S rRNA* sequences obtained from goat #2 were constructed separately by means of Geneious version 8.0.4 using the Tamura-Nei genetic distance model and Neighbor-Joining tree methods.

Results

Sarcocysts were found in three of seven goats (Table 1). Two morphologic types of sarcocysts with thin wall (variety A), and relatively thick wall (variety B) were found.

Variety A sarcocysts

These sarcocysts were seen in two goats. By LM, *Sarcocystis* sarcocysts from goats #1 (n=10 cysts studied) and #2 (n=7 cysts) had a 2 µm-striated wall with short villar protrusions (vp) (Fig. 1a); well defined molar tooth-like vp, type 29 were seen by Toluidine blue stain (Fig. 1b). Two sarcocysts were studied ultrastructurally. By TEM, the sarcocyst wall was 2 µm-thick and the parasitophorous vacuolar membrane (pvm) was wavy and lined by two electron dense (55-60 nm thick) layers of different density. The villar protrusions were more wide than long (1.5-1.7 x 1-6-1.9 µm). The vp contained a remarkable electron dense core (edc) (Fig. 2) connected by microfilaments (mf) to two disc-shaped multilayered plaques (ds) of 201 nm in diameter (167-235 nm; n=10) (Fig. 2c, d). The ground substance layer (gs) was

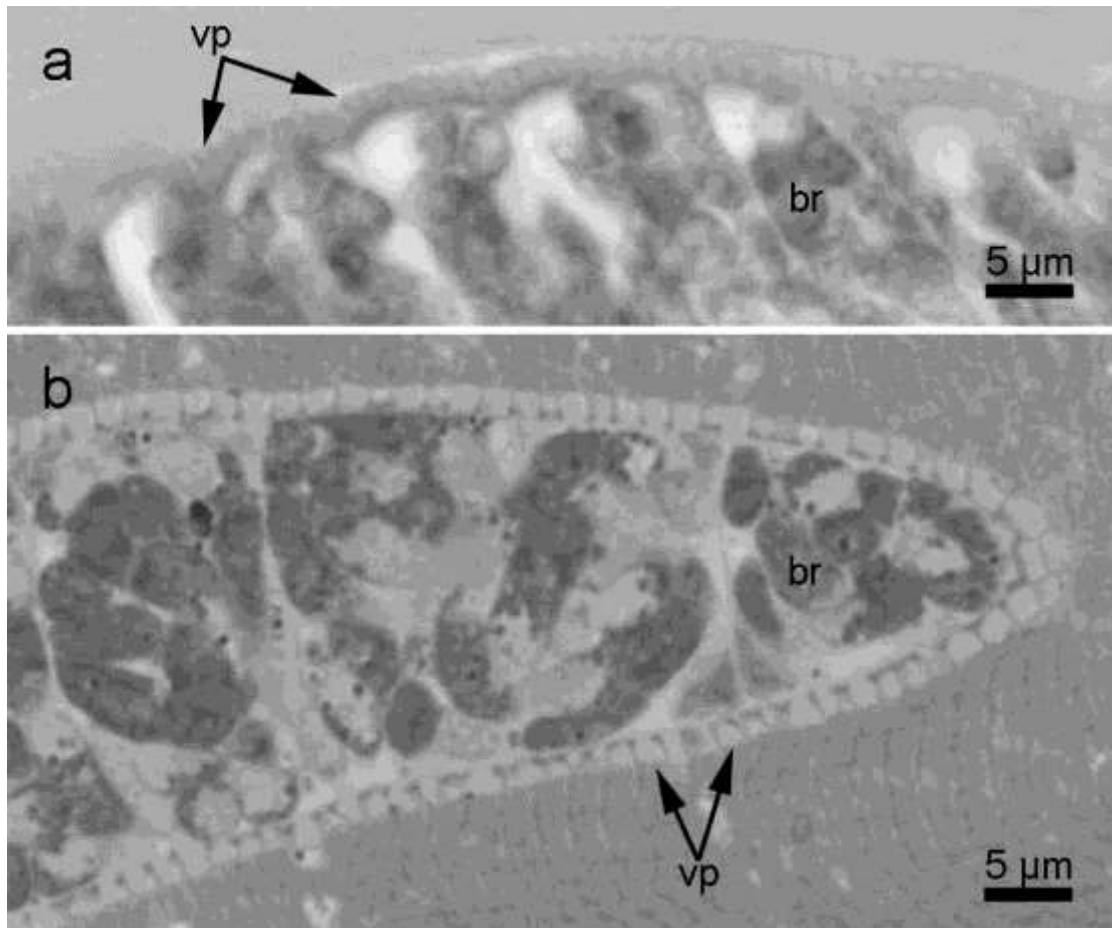


Fig. 1 *Sarcocystis oreamni* n. sp. detected in Mountain goats (*Oreamnos americanus*) #1 and #2 from Alaska, USA. **a** H and E stain. Short villar protrusions (vp) give striated appearance to cyst wall. **b** Toluidine blue stain. Aspect of the molar tooth-like vp of the cyst wall. Both are mature cysts containing bradyzoites (br)

300 nm thick and appeared smooth without microtubules (Fig. 2a, b). The bradyzoites were 8.6-9.1 µm long.

Based on unique morphological description, a new species, *S. oreamni*, is proposed for the unknown organism found in mountain goats from Alaska.

Taxonomic summary of *Sarcocystis oreamni* n. sp. (Figs. 1-2).

Diagnosis: Sarcocysts microscopic, up to 290 µm long and 40-50 µm wide, sarcocyst wall 2 µm thick. 1.7 µm long molar tooth-like villar protrusions, type 29 and containing two disc-shaped plaques at the tip (201 nm in diameter) and an electron dense core. The gs is thin (300 nm). Bradyzoites 8.6-9.1 µm long in TEM micrographs.

Etymology: Species named after the genus of its intermediate host.

Host: Rocky Mountain goat (*Oreamnos americanus*).

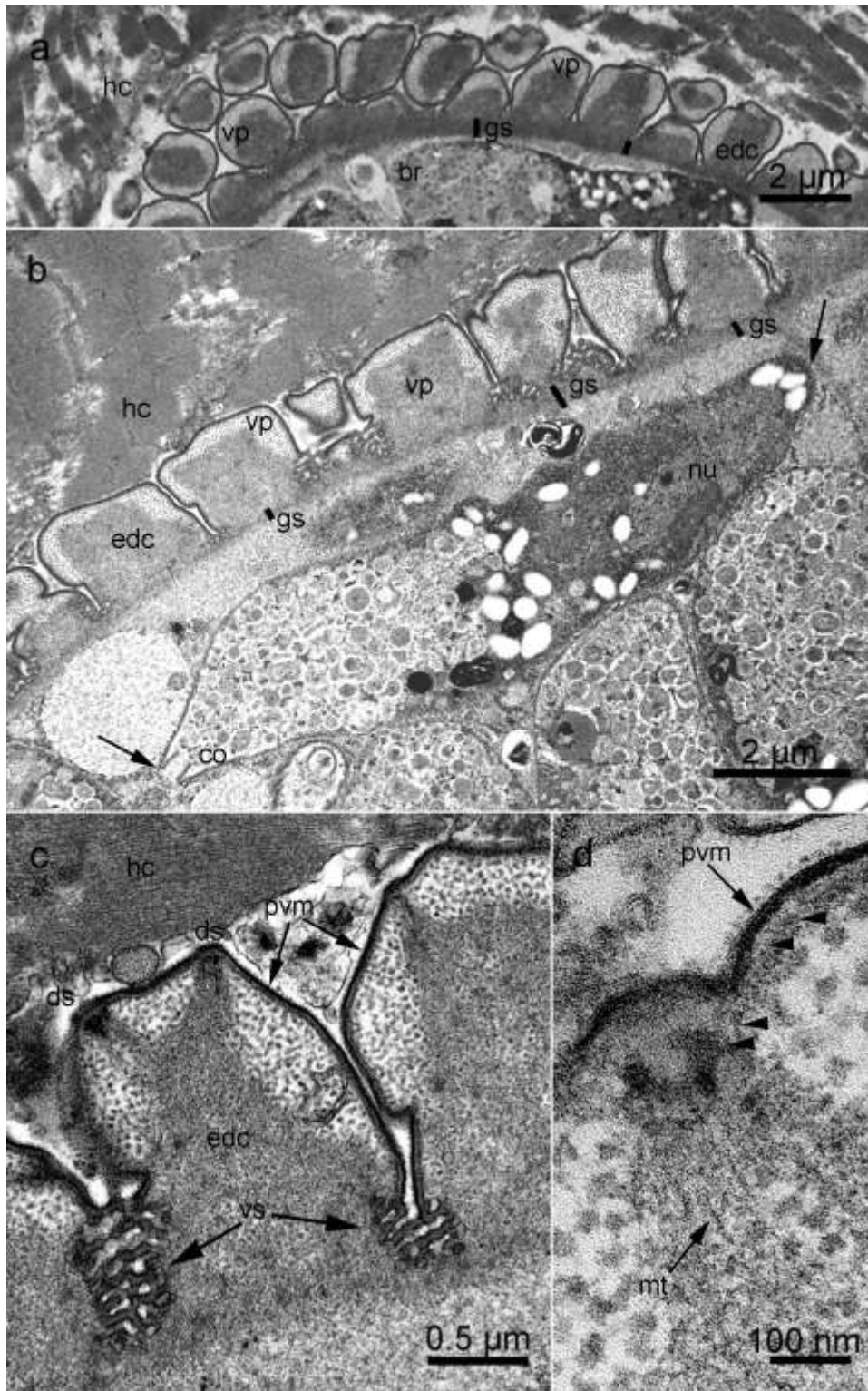


Fig. 2 TEM of *Sarcocystis oreamni* n. sp. **a** Detail of the cyst wall with electron dense core molar tooth-like villar protrusions (vp) and thin ground substance (gs). **b** Molar tooth-like villar protrusions (vp) with electron dense core and vesicles in their interspaces. Arrows point to a longitudinally cut bradyzoite (br) with visible conoid (co) and nucleus (nu). **c** Detail of a vp with an electron dense core (edc), parasitoforous vacuolar membrane (pvm), two disc-shaped plaques (ds) and vesicles (vs) at the bottom edge. **d** Detail of disc-shaped plaques presenting multiple layers (arrowheads) and connected to the electron dense core of the vp by microtubules (mt)

Distribution: Alaska (USA), probably other areas in North America.

Definitive host: Unknown, possibly Canidae.

Specimens deposited: Specimens deposited in the United States National Parasite Collection in the Division of Invertebrate Zoology and National Museum of Natural History, Smithsonian Institution, Washington, D.C. under (USNM Nos. 1283133, 1283134) include histological sections stained with H and E and Toluidine blue. Sequences were deposited in NCBI GenBank accession number KT225488 (*18S rRNA*) and KT2254489 (*28S rRNA*).

Variety *B sarcocysts*

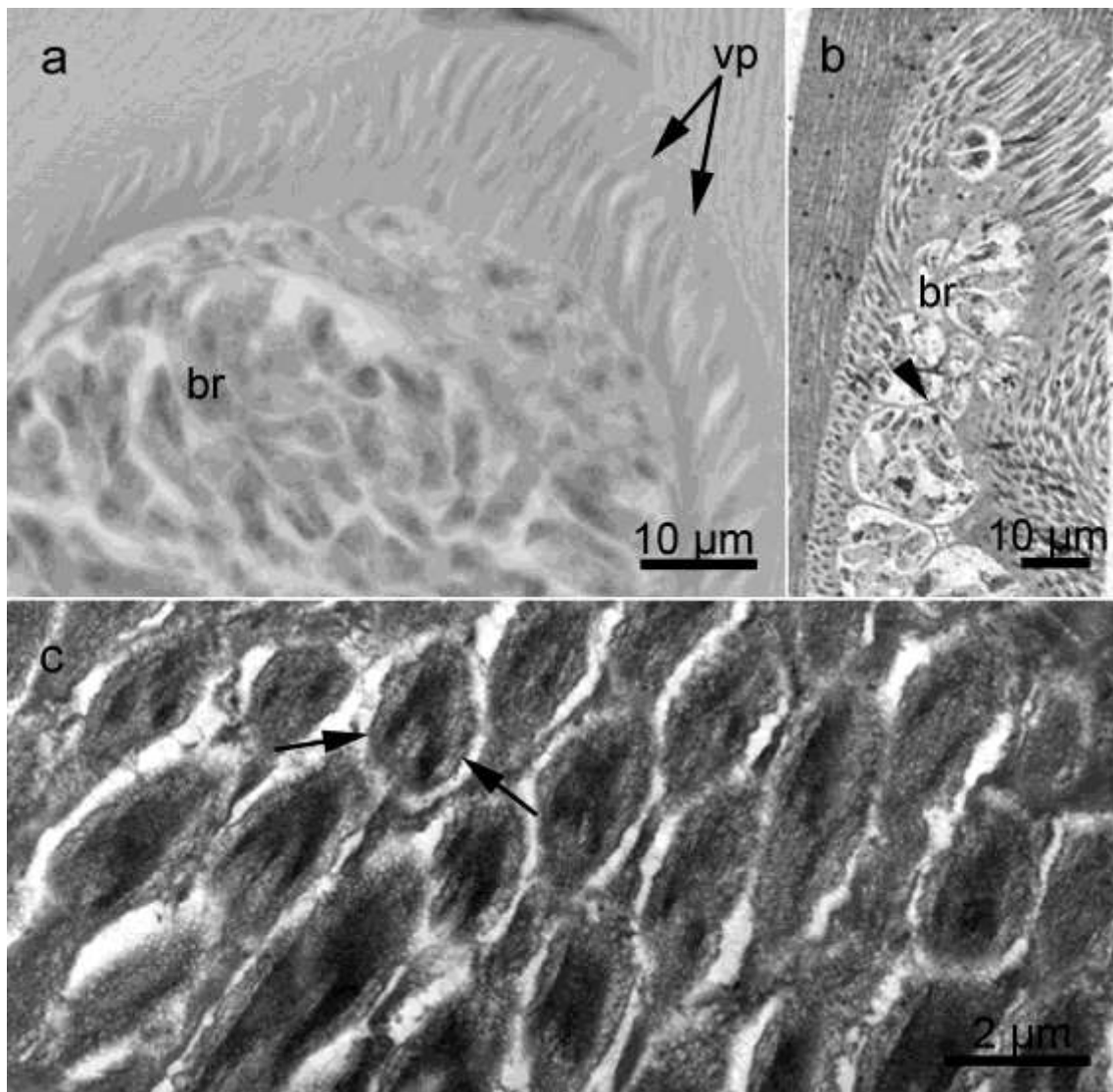


Fig. 3 Micrographs of *Sarcocystis sarcocyst* from mountain goat #5. **a** LM of a mature cyst resembling *S. coragliai*. Long villar protrusions (vp) and bradyzoites (br). H and E stain. **b** To note different appearance of cross sections of vp in a longitudinally cut sarcocyst; bradyzoites (br) grouped by septae (arrowhead). Toluidine blue stain. **c** TEM of cyst wall. Typical mushroom-like vp appearance on cross sections

Two sarcocysts were seen in goat #5. By LM, they had up to 15 µm-long villar protrusions (vp) (Fig. 3a). Cysts were mature, and tightly packaged bradyzoites were grouped by septae (Fig. 3b). By TEM, we were able to locate only 1 sarcocyst from the specimen processed from the paraffin block. This sarcocyst was too degenerated to resolve details but 11.8 x 2.0 µm sized mushroom-like villar protrusions were visible (Fig. 3c). In cross section of vp, electron dense core of tightly packed microtubules were present. The sarcocyst wall resembled type 24 proposed by Dubey et al. (1989, 2015a).

Molecular findings

The PCR amplification of the *18S rRNA* (~870 bp), *28S rRNA* (~925 bp), and *ITS-1* (~900 bp) regions was successful using DNA extracted from individual sarcocysts of mountain goat #2. DNA sequencing of PCR amplicons produced the unambiguous partial sequences of the *18S rRNA* (827 bp) and *28S rRNA* (457 bp). In the *28S rRNA* sequence chromatogram, both the forward and the reverse read displayed double peak at three particular positions in the mountain goat sequence; at 290 A and G, at 367 G and A, at 369 A and G (the first base was predominant and selected base call). Both sequences obtained from mountain goat #2 were submitted to NCBI GenBank with accession number KT225488 (*18S rRNA*), and accession number KT225489 (*28S rRNA*).

The *18S rRNA* partial sequence of *S. oreamni* (obtained from individual sarcocysts of mountain goat #2) shared 99% identity with sequences of *S. tarandivulpes* (EF467657), corresponding to nucleotide positions 122-949. The alignment of the *18S rRNA* partial sequence revealed that *S. oreamni* (KT225488) is distinguishable from *S. tarandivulpes* (EF467657) by one single nucleotide polymorphism (SNP); at nucleotide position 852 (*S. oreamni* has a T; *S. tarandivulpes* has a C). Additionally, the *18S rRNA* sequence of *S. oreamni* shared 95% identity with *S. tenella* (KC209734), 95 % with *S. alces* (EU282018), and 95 % with *S. capracanis* (L76472).

The partial *28S rRNA* sequences obtained from *S. oreamni* obtained from mountain goat shared the highest identity (90 %) with sequences of *S. capracanis* (AF012885). Alignment of both sequences revealed 53 of 457 variation sites between *S. oreamni* and *S. capracanis* (AF012885). Seven nucleotides insertions and ten nucleotides deletions in *S. oreamni* sequences were recorded with respect to *S. capracanis* (AF012885) sequence. In addition, 36 substitutions of nucleotides (both transition and transversion) were recorded in *S. oreamni* sequences chromatogram in the particular positions with respect to *S. capracanis* (AF012885). Additionally, the *28S rRNA* sequence of *S. oreamni* shared 89%




Fig. 4 Phylogenetic tree of 18S rRNA gene for *Sarcocystis oreamni* isolated from Mountain goats in Alaska, USA




Fig. 5 Phylogenetic tree of 28S rRNA gene for *Sarcocystis oreamni* isolated from Mountain goats in Alaska, USA

identity with *S. tenella* (AF076899), 89 % identity with *S. rangi* (KJ396590), 88 % identity with *S. alces* (KJ396587), *S. cruzi* (AF076903), and *S. arieticanis* (AF076904).

The PCR amplification of *ITS-1* resulted in single light band visible in gel image. However, sequencing of this PCR product was not successful. Further molecular study was not done to re-amplify and sequence the complete *18S rRNA*, *28S rRNA* and *ITS-1* loci because of limitation of sample quantity.

Phylogenetic analysis based on both the *18S rRNA* and the *28S rRNA* partial sequences of *S. oreamni* obtained from individual sarcocysts of mountain goat #2 confirmed its membership among species of *Sarcocystis* and indicated an especially close relationship to another parasite in this genus that employs Canidae as their definitive host i.e. *S. tarandivulpes*, *S. capracanis*, and *S. tenella* (Figs. 4 and 5).

No robust molecular results were obtained for sarcocysts isolated from mountain goat #5.

Discussion

Two morphological types of sarcocysts were found in the present study of the Rocky Mountain goat from Alaska. The sarcocysts found in goat #5 morphologically resembled the sarcocysts reported by Foreyt (1989) in mountain goats from Washington State, USA. We initially wished to name the sarcocyst reported by Foreyt but all materials used to describe the parasite (histological sections, TEM micrographs) had been discarded (Foreyt, personal communication to JPD-February, 2015). The specimens we found from Alaska in the present study were degenerated. Thus, we could not name it.

A review of literature (Dubey et al. 2015a) indicated that the Variety B sarcocysts found here and that described by Foreyt resembled *Sarcocystis cornagliai*-like parasite in chamois from Austria and Germany (Odening et al. 1996a). Further studies are needed to determine the identity of this parasite in mountain goat in the USA.

A new species, *S. oreamni*, is proposed for the cysts presenting molar tooth-like vp, type 29 found in 2 goats; they are clearly differentiated from *S. danzani* in the Mongolian gazelle (*Procapra gutturosa*) (Odening et al. 1996b), and from *S. phacochoeri* in the warthog (*Phacochoerus aethiopicus*) (Stolte et al. 1998), being respectively type 29a and type 29b (Dubey et al. 2015a). Main differences arise from the presence of electron dense core of vp, the extraordinary thin (300 nm) gs and two disc-shaped plaques, morphologically indistinguishable from those reported by Speer and Dubey (1986) for the *S. hemionilatrantis* of the mule deer (*Odocoileus hemionus*).

Sequences analysis at single marker alone may not be enough because some species have more intra-species sequences variation in a given region as demonstrated recently in *S. lutrae* (Gjerde and Josefsen 2015). Therefore, two nuclear DNA regions (*18S rRNA*, *28S rRNA*) of new species, *S. oreamni* were amplified and sequenced to identify and show relationship with other *Sarcocystis* species. Sequencing of amplified *ITS-1* fragment was unsuccessful possibly due to low quantity of PCR product. The *18S rRNA* sequence of *S. oreamni* showed high level of identity with sequences of *S. tarandivulpes* of reindeer (*Rangifer tarandi*) published by Dahlgren et al. (2007) from Iceland. Distributional range of caribou (the wild counterpart of the semi-domestic reindeer) in North America overlaps with mountain goat in some portions of their range (but not in southeastern Alaska – the area where our samples were collected). When analyzing *28S rRNA* sequences, similarities to those of *S. capracanis*, *S. arieticanis*, *S. tenella*, *S. rangi*, and *S. alces* from domestic goat and sheep, reindeer (*Rangifer tarandus*) and moose (*Alces alces*) respectively, were detected. Phylogenetic relationship indicated that *S. oreamni* is related to species with Canidae as definitive hosts; only wolves (*Canis lupus*) and coyotes (*Canis latrans*) are sympatric with mountain goats in southeastern Alaska.

In conclusion, new species *S. oreamni* described here from Rocky Mountain goat is related to the *Sarcocystis* species that employs members of the Canidae family as their definitive host. Single nucleotide polymorphisms (SNPs) identified in *18S rRNA*, and *28S rRNA* loci of rDNA regions suggested that *S. oreamni* is molecularly different to related species. The sarcocysts of *S. oreamni* are microscopic and have morphologically distinguishable wall structure previously classified as ‘type 29’.

Acknowledgements

The authors thank Mr. Efrain Pérez and Joseph Madary, Joint Pathology Center, Veterinary Services, U.S. Army, Silver Spring, Maryland for excellent technical help with electron microscopy. Jeff Jemison, Alaska Department of Fish and Game, Juneau, AK archived tissue samples. R. Calero-Bernal is a postdoctoral fellow (ref. PO12010) funded by the Department of Employment and Innovation of the Regional Government of Extremadura (Spain) and the European Social Fund.

References

Dahlgren SS, Gjerde B, Skirnisson K, Gudmundsdottir B. (2007) Morphological and molecular identification of three species of *Sarcocystis* in reindeer (*Rangifer tarandus tarandus*) in Iceland. *Vet Parasitol* 149:191–198. doi:10.1016/j.vpar.2007.08.015

- Dubey JP, Speer CA, Fayer R. (1989) *Sarcocystosis of animals and man*. CRC Boca Raton, FL, USA
- Dubey JP, Calero-Bernal R, Rosenthal BM, Speer CA, Fayer R. (2015a) *Sarcocystosis of animals and humans*, 2nd Edn. CRC Boca Raton FL, USA
- Dubey JP, Hilali M, van Wilpe E, Verma SK, Calero-Bernal R, Abdel-Wahab A. (2015b) Redescription of *Sarcocystis fusiformis* sarcocysts from the water buffalo (*Bubalus bubalis*). *Parasitology* 142:385–394. doi:10.1017/S003118201400122X
- Festa-Bianchet M. (2008) *Oreamnos americanus*. The IUCN Red List of Threatened Species. Version 2014.3. <http://iucnredlist.org>>. Accessed 22 April 2015
- Foreyt WJ. (1989) *Sarcocystis* sp. in mountain goats (*Oreamnos americanus*) in Washington: prevalence and search for the definitive host. *J Wildl Dis* 25:619–622. doi: 10.7589/0090-3558-25.4.619
- Gjerde B. (2014) Molecular characterisation of *Sarcocystis rileyi* from a common eider (*Somateria mollissima*) in Norway. *Parasitol Res* 113:3501–3509. doi:10.1007/s00436-014-4062-y.
- Gjerde B, Josefsen TD. (2015) Molecular characterisation of *Sarcocystis lutrae* n. sp. and *Toxoplasma gondii* from the musculature of two Eurasian otters (*Lutra lutra*) in Norway. *Parasitol Res* 114:873–886. doi:10.1007/s00436-014-4251-8.
- Mahrt JL, Colwell DD. (1980). *Sarcocystis* in wild ungulates in Alberta. *J Wildl Dis* 16, 571-576. doi:<http://dx.doi.org/10.7589/0090-3558-16.4.571>
- Odening K, Stolte M, Bockhardt I. (1996a) On the diagnostics of *Sarcocystis* in chamois (*Rupicapra rupicapra*). *Appl Parasitol* 37:153–160
- Odening K, Stolte M, Lux E, Bockhardt I. (1996b) The Mongolian gazelle (*Procapra gutturosa*, Bovidae) as an intermediate host of three *Sarcocystis* species in Mongolia. *Appl Parasitol* 37, 54-65
- Speer CA, Dubey JP. (1986) An unusual structure in the primary cyst wall of *Sarcocystis hemionilatrantis*. *J Protozool* 33:130–132. doi:10.1111/j.1550-7408.1986.tb05573.x
- Stolte M, Odening K, Quandt S, Bengis RG, Bockhardt I. (1998) *Sarcocystis dubeyella* n. sp. and *Sarcocystis phacochoeri* n. sp. (Protozoa: Sarcocystidae) from the warthog (*Phacochoerus aethiopicus*) in South Africa. *J Eukaryot Microbiol* 45:101–104. doi:10.1111/j.1550-7408.1998.tb05076.x
- Yang ZQ, Zuo YX, Yao YG, Chen XW, Yang GC, Zhang YP. (2001) Analysis of the 18S rRNA genes of *Sarcocystis* species suggests that the morphologically similar organisms from cattle and water buffalo should be considered the same species. *Mol Biochem Parasitol* 115:283–288. doi:10.1016/S0166-6851(01)00283-3