

Studies on the Photosensitisation of Animals in South Africa.

III. The Photodynamic Action of *Hypericum ethiopicum* var. *glaucescens* Sond. and *Hypericum leucoptychodes* (Syn. *H. lanceo- latum* Lam.).

By J. I. QUIN, D.V.Sc., Veterinary Research Officer,
Onderstepoort.

INTRODUCTION.

It is a well-known fact that several species of the genus *Hypericum*, when eaten by animals, cause photosensitisation of the unpigmented skin. Thus according to old Italian literature *Hypericum crispum* was regarded as dangerous for sheep, but only so if the animals had unpigmented white skins. Since that time various investigators have published accounts on the so-called "St. John's wort poisoning of animals". According to Marsh and Clawson (1930), who carried out experiments with *Hypericum perforatum*, collected in Northern California, cattle and sheep when fed on it develop a high temperature, rapid pulse and respiration; while the symptoms of photosensitisation were either absent or very mild. The conclusion which they arrived at was that St. John's wort could not be considered a serious stock poison in California.

Although in South Africa, *Hypericum* poisoning in stock has never been reported, it was thought advisable to conduct some experiments on sheep and goats with locally growing species, the object being to ascertain in how far the symptoms of photosensitisation corresponded with those seen in true geeldikkop caused by the Genus *Tribulus*, and possibly other plants. For this purpose two species of *Hypericum* were collected, both from the Transvaal, and feeding and drenching tests carried out on sheep.

A. Experiments with *Hypericum ethiopicum* var. *glaucescens* Sond. (National Herbarium No. 12953.

The plants were collected with the kind help of Mr. C. A. Smith during the summer (February) on the hill slopes round about Pretoria, and were in the late flowering stage. After allowing to dry, they were finely powdered up. In this form the material suspended in water, was dosed through a stomach tube to young Merino sheep, closely shorn and exposed to strong sunlight. Altogether six sheep were used.

One sheep dosed with 20 gm. in 3 litres water daily for two consecutive days, suddenly died after the second dose with symptoms of hurried respiration and ingesta running from the mouth. Post-mortem examination revealed generalised cyanosis and pulmonary oedema. In this case the dose had obviously been too bulky, so causing asphyxia.



Fig. 1. Acute photosensitisation after dosing *H. ethiopicum*.

Another sheep was dosed with 100 grams powder daily for two days. On the afternoon of the second day, the animal became slightly restless, occasionally rubbing the head against the fence, scratching the ears and licking the lips. On the third day at 10 a.m. it was dosed 250 gm. powder. During the course of the morning, marked symptoms of irritation were shown, scratching of the head, and flinching of the body, causing the animal to assume a crouching attitude (see figs. 1 and 2). The sun seemed to strike the animal along the spine and especially over the croup, and causing it to lie down and rise at frequent intervals. Later in the afternoon, swelling of the ears was clearly evident. The temperature rose from 101.2° F. in the morning to 105.6° F. in the afternoon, while the respirations became markedly accelerated. The animal was not dosed again. On the fourth day since starting the experiment, the ears were markedly swollen, while the other symptoms remained unabated. On the 9th day the swelling of the ears started to subside, although photosensitisation was clearly shown up to the 15th day, the symptoms appearing as soon as the animal was placed out in the sun. From the 16th day onwards there was a progressive hardening of the skin all along the back where the wool had been clipped short. When this part was

touched the animal showed marked flinching. The appetite and general health otherwise was good. By the end of a month large flakes of dried skin and wool could be removed from the back (see fig. 3). The temperature curve became normal from the 5th day onwards. Blood from the jugular vein was collected daily up to the 18th day, and after centrifuging, the serum was examined for bile pigments. At no time could these be demonstrated, the serum remaining practically water clear, neither were any clinical signs of icterus visible.



Fig. 2. Acute photosensitisation after dosing *H. ethiopicum*.

Another sheep was dosed 250 gm. powder. The following day the animal became restless and the ears started swelling. On the 3rd day photosensitisation was extreme and the body thrown into an abnormal crouching position. On the 5th day the sheep was only slightly sensitive. On the 6th day it was again dosed 250 gm. powder. Although this caused the animal to go off its food for a few days, no signs of sensitisation were again shown. The serum, as in the previous case, remained water clear.




Fig. 3. Chronic skin lesions after repeated dosing of *H. ethiopicum*.

EXTRACTION OF FLUORESCENT PIGMENT FROM THE DRY POWDERED PLANT.

According to Cerny, a deep red fluorescent pigment, which he named hypericin, is contained in various *Hypericum* species, while Hausmann and Zaribnický have shown that alcoholic extracts prepared from the flowers of *Hypericum perforatum* possessed a sensitising action on erythrocytes.

Extracts prepared by soaking the dry powdered *Hypericum ethiopicum* in acetone overnight, showed a striking deep red fluorescence. Spectroscopically two bands closely resembling those of oxyhaemoglobin were seen. On evaporation of the extracts a deep red slightly sticky residue was left behind. Of this residue 0.5 gm. dissolved in 20 c.c. distilled water and then filtered, was injected intravenously into a sheep. Within a few minutes after injection the animal started showing signs of sensitisation, shaking and scratching the head. Later in the afternoon diarrhoea set in and the animal was found dead the next morning. There were no visible lesions in any of the organs except a catarrh of the intestines.

DISCUSSION.

From experiments carried out with *Hypericum ethiopicum* drenched to sheep, it is clearly evident that this species, as is the case with several other species, contains a strong photosensitising principle capable of producing marked symptoms in sheep with unpigmented skins. When exposed to sunlight such animals exhibit irritation of the exposed parts to such extent, that the body is thrown into various abnormal attitudes, the animal continually seeking shade. There is marked swelling of the face and ears, followed in chronic cases by sloughing of the affected skin. Symptoms of icterus (clinical or blood) are not to be seen.

The plant contains a deep red fluorescent pigment soluble in alcohol, acetone and water. Crude extracts show absorption bands as follows: aqueous, 560 and 600A, acid ether 540, 568, 582; Amyl-alcohol 528, 540, 570, 583, and probably identical or closely related to that described by Cerny for other *Hypericum* species. This pigment causes photosensitisation when injected into sheep, with symptoms closely resembling those produced by injections of haematoporphyrin (Quin).

B. Experiments with *Hypericum Leucoptychodes* (Syn. *H. lanceolatum* Lam.) (Nat. Herbarium No. 11416).

Through the courtesy of Dr. E. P. Phillips, Division of Plant Industry, a good amount of the above plant was collected at Broederstroom, Northern Transvaal, towards the end of the summer. It was much taller than *H. ethiopicum* and also in the late flowering stage. As in the previous experiments the material was dried and finely powdered before being dosed to animals. One Angora goat and three Merino sheep were used. All the animals were closely shorn and exposed in the sun after dosing.

One Angora goat received 3,250 gm. of the powder in a period of 17 days. On the 10th day it started showing slight photosensitisation, which, however, passed off the following day. The animal, however, became progressively more dull each day, and the blood serum reached a fairly yellow tint. From the 18th day the animal started to purge severely and the dosing was stopped. Death took place on the 22nd day with marked exhaustion following on the severe purging. On post-mortem examination there was a marked catarrhal enteritis.

One Merino sheep dosed 200 gm. powder daily for three days, developed a progressive dullness lasting up to the 11th day, when recovery seemed complete. There were no signs of photosensitisation. The blood serum was definitely yellow from the 3rd to the 10th day.

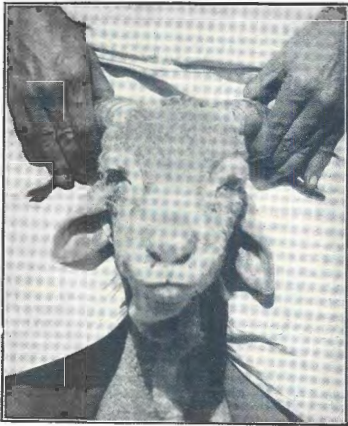


Fig. 4. Swelling of face and ears after dosing *H. leucoptychodes*.



Fig. 5. Swelling of face and ears after dosing *H. leucoptychodes*.

Another sheep dosed 150 gm. daily for 5 days suddenly died during the night of the 5th day without having shown any symptoms. On post-mortem the fore-stomachs were found to be markedly distended.

One Merino sheep was dosed 150 gm. daily for 4 days, followed by 200 gm. daily for 6 days. The animal showed no symptoms until the 9th day, when the ears were found to be markedly swollen, although obvious symptoms of irritation were absent. The oedematous swelling increased and also spread to the face (see figs. 4 and 5) and intermandibular space. On the 16th day the swellings were \pm completely subsided. The animal, however, became progressively weaker. On the 24th it was in extremis and consequently killed for post-mortem. Except for the marked atrophy of the muscles and poor condition of the carcass generally, no other pathological lesions were found.

DISCUSSION.

Hypericum leucoptychodes, when repeatedly drenched to sheep causes either no photosensitisation or a delayed and slowly progressive sensitisation to sunlight in the form of a well marked oedema of the subcutaneous tissues of the head and ears unaccompanied by the acute symptoms of irritation and flinching as noticed with *Hypericum ethiopicum*. It does, however, exert a toxic effect on the animal as shown by the severe purging and the progressive debility and inanition.

SUMMARY.

1. Dried pulverised *Hypericum ethiopicum* when drenched to Merino sheep was found to cause intense photosensitisation and oedematous swellings of the exposed parts of the skin. Such affected skin later became necrosed and was followed by sloughing.

2. A deep red fluorescent pigment, soluble in acetone, alcohol and water has been extracted from the dried plant.

3. This pigment when injected into sheep causes well marked photosensitisation.

4. The symptoms are not accompanied by icterus and resemble those produced by haematoporphyrin.

5. *Hypericum leucoptychodes* causes a much weaker and delayed photosensitisation, although diarrhoea is frequently noticed after repeated dosing of the plant to sheep.

LITERATURE.

- CERNY, C. (1911). Über das Hypericin (Hypericumrot). *Zeitsch. f. Phys. Chemie.*, Vol. 73, pp. 371-382.
- HAUSMANN W., AND HAXTHAUSEN, H. (1929). Die Lichterkrankungen der Haut. Urban u. Schwarzenberg, Berlin u. Wien.
- MARSH, C. D., AND CLAWSON, A. B. (1930). Toxic effect of St. Johnswort (*Hypericum perforatum*) on cattle and sheep. *United States Dept. Agric. Tech. Bull.* 202, Washington.
- QUIN, J. I. (1931). The photosensitising influence of haematoporphyrin on sheep and goats. *17th Rept. Dir. Vet. Serv. and Anim. Indust.*, Union of S.A., pp. 645-659.