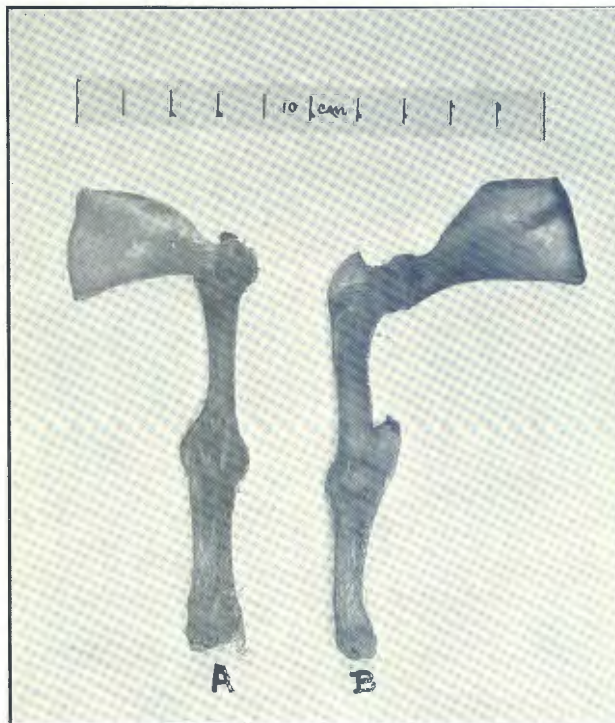


## **Anatomical Studies, No. 49: On a deformity of the shoulder joint in a pig.**

By H. H. CURSON, Dr. Med. Vet., F.R.C.V.S., Veterinary Research Officer, Onderstepoort.

ON 5th October, 1933, the Large White Sow, D.O.B. 809, gave birth to nine piglets, all of which were normal, except one that was deformed and born dead.\* This was the third litter of the sow and nothing unusual had occurred previously.

The piglet (Path. Book No. 14,295) on examination showed the following anomalies:—



\* Sow served on 15/6/33 by Large White Boar, D.O.B. 901.

- (a) The main lesion lay in the shoulder joint of the left thoracic limb. Later, on dissection, it was seen that the *angulus glenoidalis* did not bear a *cavitas glenoidalis*. Further, the humerus, instead of being directed the normal way, has its *facies cranialis* directed caudally. As a result the *antibrachium* and *manus* were also directed backwards. See figure.

Although the *articulatio scapulo-humeralis* possessed a joint capsule the lateral aspect of the *caput humeri* was attached to the *collum scapulae* by fibrous adhesions. Thus the joint instead of being diarthrodial was synarthrodial.

- (b) There was also distortion of the *columna vertebralis* in the cervical region.

I am indebted to Mr. G. N. Murray, of Onderstepoort, for the specimen.