

## Anatomical Studies, No. 41 : Prenatal Death in the Merino Ewe, associated with deformity of the Cervix Uteri.

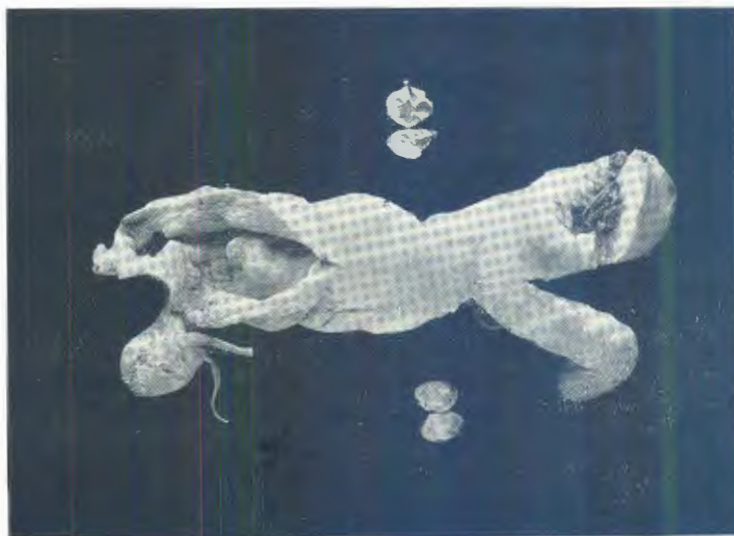
By

H. H. CURSON, Dr.Med.Vet., F.R.C.V.S., Veterinary Research  
Officer, Onderstepoort; and

C. E. BELONJE, University of Pretoria.

The object of this note is to draw attention not only to the somewhat frequent occurrence of prenatal death in the pregnant Merino ewe, but also in this instance to an unusual dilatation of the *canalis cervicis* (Quinlan, 1929). Corner (1923) has undertaken a thorough investigation into intrauterine mortality in the pig.

The specimen in question (see figure) was obtained on 18th August, 1933, through the kind offices of Messrs. G. Pilditch and Coetzee of the Pretoria Abattoir.



As is well known, the fate of a dead foetus may be as follows: (a) abortion, or (b) maceration generally accompanied by pyometra and even pyosalpinx and cervicitis, or (c) mummification. In this case twins had been present and death had taken place at about 2 months.

Each of the ovaries showed the embedded corpus luteum and in one instance some retrogression had taken place. Only portions of the oviducts had escaped the slaughterman's knife and these were much thickened. The uterus contained both bones and pus, but most of the latter had filtered through to a dilatation of the cervix. The foetal membranes and maternal cotyledons had disappeared and the uterine wall throughout was greatly thickened. It may be added that the dressed carcass of the ewe was in excellent condition.

In regard to the deformity of the cervix (see Curson, 1932), this was not only greatly dilated, but it contained only three valves, an anterior, which was pervious, and two posterior. On incision 20 c.c. of liquid pus escaped from the cervical dilatation and in this were several bony fragments.

#### REFERENCES.

- CORNER, G. W. (1932). The Problem of Embryonic Pathology in Mammals with Observations upon Intrauterine Mortality in the Pig. *Amer. Jl. Anat.*, Vol. 31, p. 523.
- CURSON, H. H. (1932). On two Anomalies of the *Cervix uteri* in a Merino Sheep. *18th Rept., Dir. Vet. Serv. and Anim. Indust.*, p. 1091.
- QUINLAN, J. B. (1929). Researches into Sterility of Cows in South Africa. *15th An. Rept., Dir. Vet. Serv.*, Pretoria, p. 980 (Case 62).