

# **Steroid-responsive idiopathic interstitial lung disease in two dogs**

Liza Koster<sup>\*1</sup>

Robert Kirberger<sup>2</sup>

<sup>1</sup>Department of Internal Medicine, Ross University School of Veterinary Medicine, Basseterre, Saint Kitts and Nevis

<sup>2</sup>Department of Companion Animal Clinical Studies, University of Pretoria, Pretoria, Gauteng, South Africa

\*Correspondence to Dr Liza Koster, [lizakoster@gmail.com](mailto:lizakoster@gmail.com)

## **SUMMARY**

Two dogs had a 3 to 4 week history of persistent pyrexia, reduced exercise tolerance, inappetence and coughing and failed to respond to repeated courses of antibiotics. Clinical examination detected adventitious lung sounds, pyrexia and submandibular lymphadenopathy. Haematology in both dogs revealed an inflammatory leukogram. Both dogs had radiological abnormalities consistent with a multifocal interstitial lung pattern. Computed tomography performed in one dog had characteristic changes of cryptogenic organising pneumonia (COP), an extremely rare idiopathic interstitial lung disease. The abnormal pulmonary findings included several parenchymal bands, multifocal patchy ground-glass opacities and multifocal subpleural and peribronchial hyperattenuating poorly defined nodular opacities throughout the lungs. Bronchoalveolar lavage analysis in both dogs revealed a sterile suppurative exudate, excluding eosinophilic bronchopneumopathy. There was rapid resolution of clinical and radiological signs with corticosteroids and relapse in one dog after discontinuation of steroids supporting the diagnosis of this rare condition. Lung biopsy, which was not performed in either case, is definitive but considered invasive with major complications reported including death.

## **BACKGROUND**

The aetiology of the lung pathology in these two dogs is believed to be cryptogenic organising pneumonitis (COP), a rare reversible inflammatory pulmonary condition that belongs to a group of diseases known as interstitial lung disease (ILD). The terms COP and bronchiolitis obliterans and organising pneumonitis (BOOP) have been used interchangeably in the literature although COP is thought to be more clinically precise and has been adopted in man by the American Thoracic Society (ATS)/European Respiratory Society (ERS) International Consensus on Idiopathic Interstitial Pneumonias (2002). In humans, ILDs are a poorly defined group of diseases that largely go

undiagnosed and are characterised by alveolitis (Crystal and others 1984). Many of these diseases are thought to originate from irritation (inhaled or haematogenous route) of the alveolar epithelial lining, specifically type I alveolar epithelial cells triggering a host inflammatory response (profibrocyte and pro-inflammatory cytokine release) with subsequent deposition of extracellular matrix and fibrosis (Norris and others 2002). Cryptogenic organising pneumonitis was first identified as early as 1878 and similar reports surfaced in the early twentieth century in which patients were diagnosed with alveolar pathology characterised by organizing exudate without a microbial infection (Cordier 2006; Woodhead and du Bois 1991). The clinical course of the disease in people is characterised by a short history of cough, malaise, fever and pleural chest pain. Diagnostic findings include audible crackles on auscultation with 'patchy lung lesions' on thoracic radiographs and reduced pulmonary lung function (Cordier 2006). Histopathology is characterised by a 'lung bud' (vascularised polyp or plug) or Masson bodies in the alveolar spaces (Cordier 2006, Li and others, 2006). The disease has a complete response to corticosteroids (Cordier 2006). The aetiologies of ILD in dogs have been reviewed (Corcoran and others, 1991). The most clinically relevant and common causes of canine ILD in dogs are eosinophilic bronchopneumopathy (EBP) and idiopathic pulmonary fibrosis (IPF) (Corcoran, 1991; Lobetti and others 2001). There are only three canine reports of COP which originate from the USA and China (Phillips and others, 2000; Norris and others, 2002; Li and others, 2006). The first was a case report of a dog that suffered from pulmonary hypertension and polycythaemia as sequelae to the interstitial lung disease (Phillips and others 2000). An 8-year-old spayed mixed breed, had a history of 1-month exercise intolerance and dyspnoea. Computed tomography (CT) demonstrated asymmetric air-space consolidation and the diagnosis was confirmed with a lung biopsy. The second report included two dogs and a cat with COP in a case series of ILD with a history of cough, fever and dyspnoea that underwent keyhole lung biopsies (Norris and others 2002). The third report of COP was a series of dogs that were used in an experimental study to determine the use of oleic acid as a vehicle for fat soluble drugs (Li and others 2006). The diagnosis of COP was made on post-mortem in four dogs. This was thought to be a systemic rather than

inhaled side-effect. The disease was strictly speaking not COP in these cases, but organising pneumonitis, since there was an apparent cause. The lesions described on histopathology in all three reports were limited to the alveoli extending into the terminal bronchioles. The pathology was described as alveolitis with typical fibrovascular polyps, high density capillary vasculature, necrosis and mixed inflammatory cells with intra-alveolar type II pneumocytes, foamy macrophages, protein rich fluid and neutrophils. Additionally there was bronchiolar wall smooth muscle hypertrophy with the lumen often obliterated by fibroblasts and exudate (Li and others 2006; Norris and others 2002; Phillips and others 2000).

This case report includes two dogs from different geographical regions that presented with classical clinical signs consistent with steroid responsive idiopathic interstitial lung disease. Additionally this report details the radiological and CT findings associated with this rare disease in an attempt to highlight the non-invasive diagnostic value of these modalities. The one dog that underwent thoracic CT as part of the investigation and offers one of the few reported CT descriptions of steroid responsive pneumonia in companion animal medicine.

## **CASE PRESENTATION**

### Case 1

An 11-year-old, spayed female Cocker spaniel, with a body mass of 17.8 kg that had lived in Hong Kong its entire life, was referred with a 3-week history of chronic cough, reduced exercise tolerance, weight loss and persistent pyrexia. The clinical signs had failed to respond to antibiotic treatment at appropriate dosages, including multiple courses of enrofloxacin (Baytril, Bayer, Leverkusen, Germany) and doxycycline (Doxyvet, Pfizer, New York City, USA), which had been discontinued 3 days prior to presentation. The dog was housed exclusively indoors and fed a commercial veterinary diet for the prevention of uroliths. There was no history of tick exposure and vaccination and parasite prophylaxis, including heartworm (*Dirofilaria immitis*) prevention, was current. Clinical examination revealed a pyrexia, mild submandibular lymphadenopathy, mild tachypnoea with mild expiratory effort and adventitious lung sounds (harsh crackles) on auscultation.

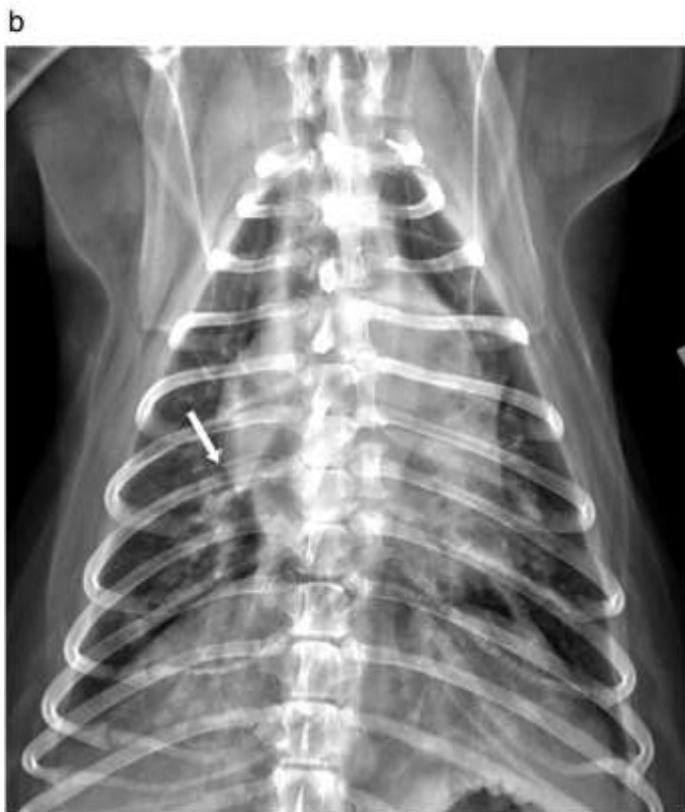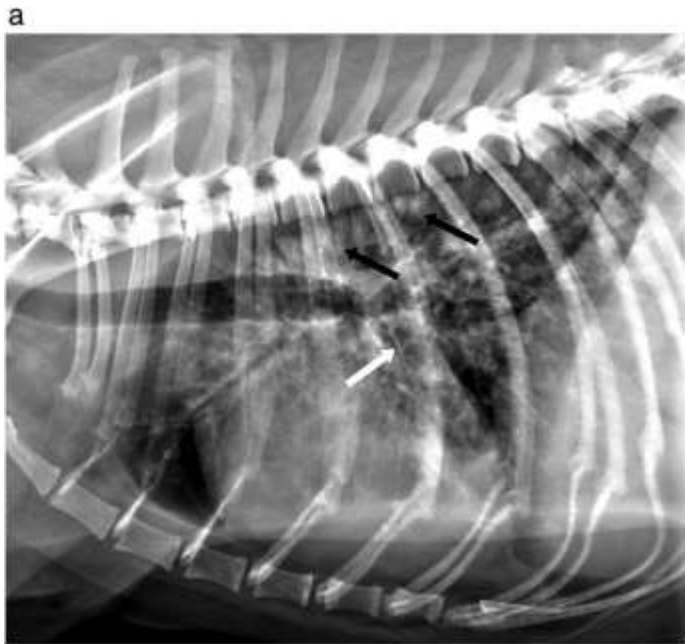## Case 2

A 2-year-old, female, spayed Border collie with a body mass of 17.4 kg was referred with a 1-month history of persistent pyrexia, inappetence, reduced exercise tolerance, cough, vulva discharge and submandibular lymphadenopathy. The dog had received several courses of antibiotics during this period including appropriate dosages of amoxicillin-clavulanic acid (Synulox, Zoetis, New York City, USA) cephalixin (Elli Lilly and Company, Indianapolis Indiana, USA) and enrofloxacin (Baytril, Bayer, Leverkusen, Germany) and a non-steroidal anti-inflammatory drug, carprofen (Norocarp, Norbrook laboratories Ltd, Carlisle, UK) without any clinical improvement. The owner reported what she thought was thoracic spinal pain on palpation. Radiographs made prior to referral were described as having perihilar pulmonary opacities. The dog's prophylaxis for parasites, including heartworm and lungworm (*Angiostrongylus vasorum*), and core vaccinations were all current. The dog was trained for agility, lived its entire life in Australia, spent much time outdoors in New South Wales and had travelled extensively regionally and in Queensland. Clinical examination revealed submandibular lymphadenopathy, pyrexia, mild tachypnoea and expiratory effort, reduced bronchovesicular sounds with soft crackles in the dorsocaudal lung field and a soft cough could be elicited on tracheal palpation. A vaginal speculum examination revealed pale, atrophied folds with the absence of a discharge, a hooded vulva and porphyrin staining of the fur of the perineum indicating licking of the region.

## **INVESTIGATIONS**

### Case 1

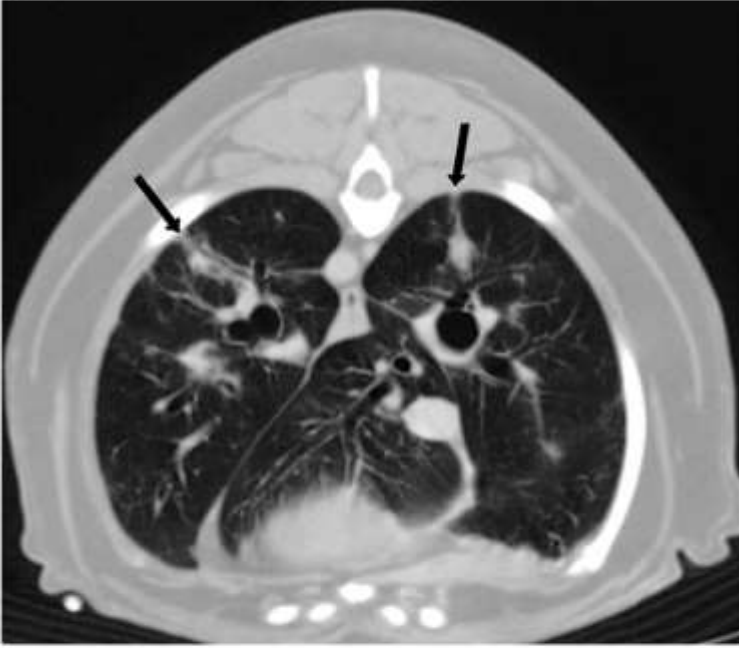
Thoracic radiographs, made using direct digital radiography (Definium™ 8000 X-ray system, General Electric Company, Waukesha Wisconsin, USA), showed a patchy interstitial lung pattern throughout with some focal areas of poorly defined nodular consolidation (Fig 1). A complete blood count (CBC) (Procyte Dx® Haematology Analyzer, IDEXX VetLab®, Westbrook Maine, USA) showed a moderate regenerative left shift neutrophilia (absolute neutrophil count  $26.16 \times 10^9/l$ , reference range  $2.95 - 11.64 \times 10^9/l$ ) and a mild monocytosis ( $1.28 \times 10^9/l$ , reference range  $0.16 - 1.12 \times 10^9/l$ ). Serum biochemistry screening (Catalyst®, Chemistry Analyzer, IDEXX VetLab®, Westbrook Maine, USA) revealed a moderately elevated alkaline phosphatase (ALP) activity (971 U/l, reference range, 23 – 212 U/l) with normal starved ( $22.5 \mu\text{mol/l}$ , reference range  $< 30 \mu\text{mol/l}$ ) and 2-hr postprandial bile acid concentrations ( $35.5 \mu\text{mol/l}$ , reference range  $< 50 \mu\text{mol/l}$ ) (SNAP® Bile Acids, SNAP shot Dx® Analyzer, IDEXX VetLab®, Westbrook Maine, USA). A *Dirofilaria immitis* antigen test (SNAP® 4Dx® Plus Test, IDEXX VetLab Analyzer, Westbrook Maine, USA) was negative. Urinalysis was normal. The



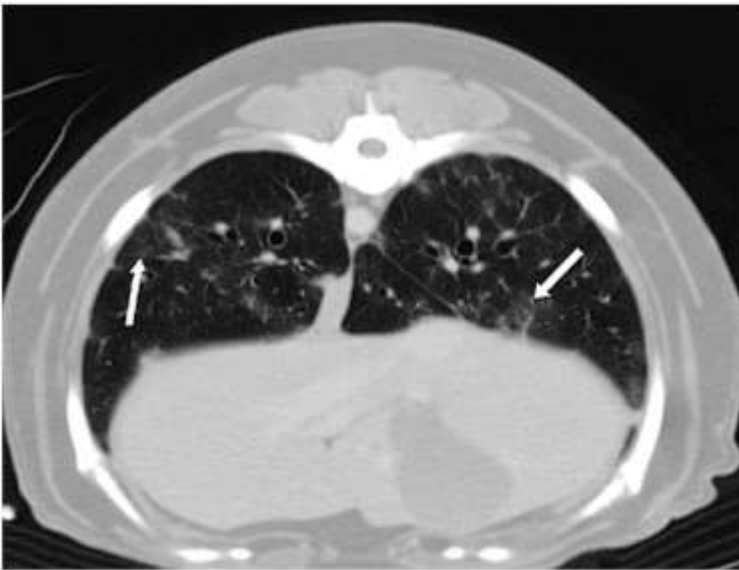**FIG 1:** Right lateral recumbent (A) and dorsoventral (B) thoracic radiographs of Case 1, an 11-year-old female spayed Cocker spaniel that presented with persistent pyrexia and coughing. Peace Avenue Veterinary Hospital, Hong Kong, with permission. There is a patchy interstitial lung pattern throughout the lungs with some associated nodular consolidation (black arrow). Pleural thickening as evidenced by feint fissure lines are seen at some lung edges (white arrow).

dog was placed on intravenous Ringer's lactate solution (Fresenius Kabi, Beijing, China) at 10 ml/kg/hr in preparation for general anaesthesia for special procedures. The dog was premedicated with butorphanol (butorphanol tartrate, Bristol-Myers Squibb, New York City, USA) at 0.4 mg/kg intravenously and induction achieved with propofol (Diprivan, AstraZeneca, London, UK) at 4.4 mg/kg intravenously to effect and maintained on 2% isoflurane (Forane, Baxter, Deerfield Illinois, USA). A thoracic CT using a helical dual slice scanner (General Electric Co., GE Health Care, CT Goldseal Hispeed NXI, Waukesha Wisconsin, USA) was performed in sternal recumbancy. Survey and post-contrast, manually injected iohexol (Omnipaque, GE Healthcare Inc., Waukesha Wisconsin, USA) at 600 mg Iodine/kg, made immediately after injection, CT images were acquired. Two mm thick slices were examined in transverse and multiplanar reformatted dorsal and sagittal planes in mediastinal and lung windows. Abnormal pulmonary findings included several parenchymal bands, multifocal patchy ground-glass opacities and multifocal subpleural and peribronchial hyperattenuating poorly defined nodular opacities bilaterally throughout the lungs (Fig 2). There was no evidence of intrathoracic lymphadenopathy. Bronchoscopy, using a 2.8 mm flexible bronchoscope (BF-XP160F, Olympus, Shunjuku, Japan), and bronchoalveolar lavage (BAL) were performed under the same anaesthetic. No abnormalities were seen during tracheobronchoscopy. The lavage fluid was submitted for cytology, aerobic and fungal culture and sensitivity. Both the culture and cytology was negative for micro-organisms but cytology revealed chronic active inflammation with 60% neutrophils, 35% monocytes, 5% small lymphocytes and scattered eosinophils within a background of mildly basophilic mucous strands. A presumptive diagnosis of COP was made based on the exclusion of bacterial or fungal infections, cytology that was not consistent with EBP and the typical history including vaccination status and clinical abnormalities. Mycoplasma infections were considered unlikely due to the lack of response to doxycycline therapy.

a



b



**FIG 2:** Transverse 2 mm thick thoracic computed tomography post contrast images in a lung windows (Window width, 1400; Window level, -400) of Case 1, an 11-year-old female spayed Cocker spaniel that presented with persistent pyrexia and coughing. Slice just caudal to the heart (A) and 4 cm further caudally (B). Peace Avenue Veterinary Hospital, Hong Kong, with permission. There are multifocal areas of ground glass opacities as well as areas of hyperattenuating poorly defined nodular opacities up to 7 mm in diameter throughout the lungs but more so subpleurally and peribronchially. These areas took up contrast increasing the HU by about 20-30 units indicating the areas to be vascularized. Mild bronchial wall thickening and parenchymal bands are seen.

## Case 2

Urinalysis and faecal flotation were normal. Haematology (Procyte Dx® Haematology Analyzer, IDEXX VetLab®, Westbrook Maine, USA) detected a mild left shift (immature neutrophils  $0.3 \times 10^9/l$ , reference range,  $0 - 0.24 \times 10^9/l$ , absolute neutrophil count  $7.6 \times 10^9/l$ , reference range  $4.06 - 9.36 \times 10^9/l$ ). Serum biochemistry and electrolytes (Catalyst®, Chemistry Analyzer, IDEXX VetLab®, Westbrook Maine, USA) were normal. Cytology of the left submandibular lymph node collected by fine needle aspirate was consistent with reactive lymphadenopathy. Computed radiography (FCR capsula X, Fujifilm, Tokyo, Japan) thoracic and thoracic vertebral radiographs were made under sedation. Radiographs revealed patchy areas of alveolar lung opacities with a mixed broncho-interstitial pattern hilarly and perihilarly. The vertebral radiographs were normal. A BAL performed by the referring veterinarian after the dog had been weaned off antibiotics, had a sterile purulent exudate confirmed by cytology, aerobic and fungal culture. The cytology was composed of 85% neutrophils and the remainder monocytes and small lymphocytes. The owner declined further investigation at this stage and a presumptive diagnosis was made based on the evidence collected.

### **DIFFERENTIAL DIAGNOSIS**

The differential diagnosis of steroid responsive idiopathic ILD in dogs include, COP,

EBP, histiocytosis X, sarcoidosis and hypersensitivity pneumonitis (Norris and others 2002).

### **TREATMENT**

#### Case 1

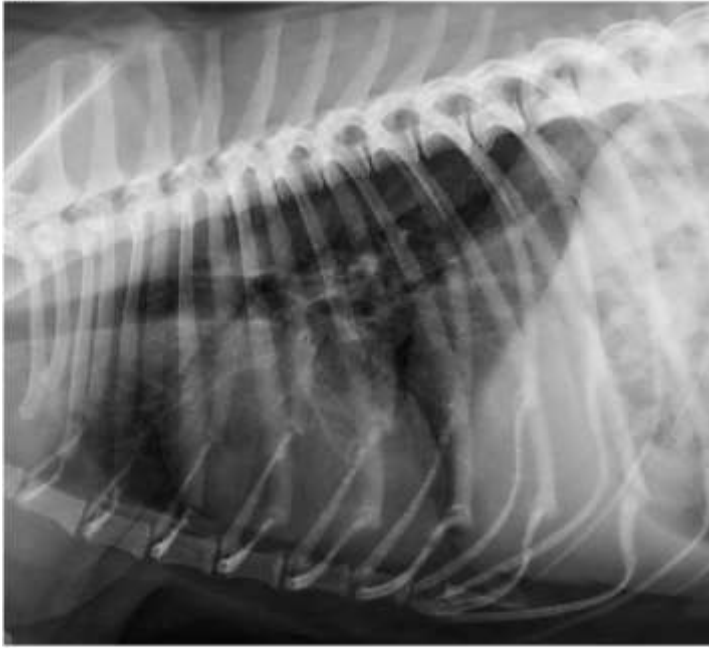
An immunosuppressive dose of prednisolone was started at 1 mg/kg, q 12 hr (Glaxo Smithcline, BD Ltd., Dhaka, Bangladesh) and clinical signs resolved within 48 hours. Follow up radiographs at this time showed a marked improvement.

#### Case 2

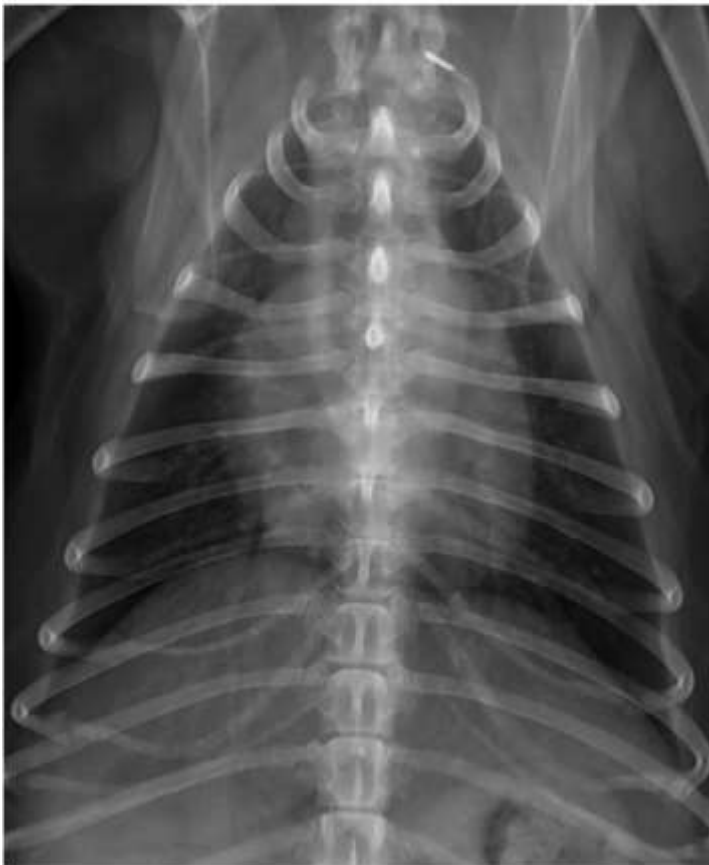The owner elected a steroid trial after informed consent. Prednisolone (Glaxo Smithcline, BD Ltd., Dhaka, Bangladesh) at 1 mg/kg, q 12 hr was started and 12 hours later the pyrexia, tachypnoea, inappetence and lymphadenopathy resolved. No cough was noted on exercise or tracheal palpation. The dog was discharged on the same dose of prednisolone.



a



b



**FIG 3:** Right lateral recumbent (A) and dorsoventral (B) follow-up thoracic radiographs made 2 months later of Case 1. Peace Avenue Veterinary Hospital, Hong Kong, with permission. The lung changes described in Figure 1 have resolved completely.

## **OUTCOME AND FOLLOW-UP**

### Case 1

The dog was re-examined 5 and 21 days later during which time the corticosteroid therapy was gradually tapered off. The owner reported no coughing since discharge, return to normal exercise tolerance and the rectal temperature, which was monitored on a daily basis, remained normal.

Follow-up thoracic radiographs at these examinations showed continuing improvement.

Radiographs made 2 months after the initial examination showed complete resolution of radiological changes (Fig 3). By 3 months after discharge the dog was completely tapered off the steroid therapy and had remained free of clinical signs. A telephonic update 3 weeks and 1 year later confirmed that, despite discontinuation of the prednisolone, there was no recurrence of clinical signs.

### Case 2

The owner reported side-effects of severe polyuria-polydipsia during the initial period. Repeat radiographs 3 days after discharge showed marked improvement in the lung pattern and repeat CBC revealed resolution of the mild inflammatory leukogram and the presence of a stress leukogram. The dose of prednisolone was reduced to 1 mg/kg body weight, q 24 hr, due to the reported side-effects and then tapered with a reduction of the dose by 50% every 2 weeks over 6 weeks. Three weeks after discontinuing steroids the dog represented with anorexia, pyrexia (rectal temperature of 40.1°C) and coughing. Thoracic radiographs showed a diffuse broncho-interstitial pattern with a lobar sign created by an alveolar pattern of the right cranial lung lobe. Prednisolone was started at 0.5 mg/kg of body weight, q 12 hr and 5 days later at recheck the clinical abnormalities and radiographic changes had resolved. The prednisolone was tapered to a dose of 5 mg orally q 24 hr and at the time of article submission, six months after initial evaluation, was still maintained on this dose.

## **DISCUSSION**

This case report highlights the lung patterns seen in steroid responsive interstitial lung disease in dogs. The lung pattern for COP in humans has been described as multiple, solitary or infiltrative alveolar opacities that vary from a nodule to lobar opacification with air bronchograms or as patchy air space consolidations (Chandler and others 1986; Cordier 2006; Lee and others 1994). The initial radiographs in these two dogs had patchy alveolar opacities and a diffuse broncho-interstitial lung pattern but these changes also fit a multitude of other potential causes. Computed tomography in

humans with COP have consolidated uni- or bilateral patchy sub-pleural or peribronchovascular consolidations in 77% of cases, haphazard ground glass opacities in 89% of cases or nodular infiltrates (Lee and others 1994, Lee and others 2010). In addition, the human cases show complete resolution of CT lesions after corticosteroid therapy with only in a few cases small residual remnant consolidations. The CT findings in the first reported case of canine COP were bilateral asymmetric areas of air space consolidation (Phillips and others 2000). A CT performed in case one had typical multifocal subpleural and peribronchial poorly defined nodular opacities, ground glass opacities as well as parenchymal bands. Some of these changes are also typical for IPF but the latter do not resolve post treatment. The radiological hallmarks for other rare ILD have been described in dogs and include sarcoidosis which is associated hilar lymphadenopathy and nodules, bullae or cysts and histiocytosis X which has nodular infiltrates and cystic changes, and were not found in either of the cases (Norris and others 2002).

The two dogs presented here shared historical, clinical, clinical pathological, radiological and in the case of the one dog, CT changes consistent with previous veterinary and human reports of COP. The mean age in humans that develop COP is 50 – 60 years (Cordier 2006), but our case report included a young dog. In the previous two canine reports the ages were 8 years in the single case report and a mean age of 7.7 years (range 2 – 16 years) in the case series (Norris and others 2002; Phillips and others 2000). Both our dogs had virtually identical presenting complaints to each other as well as previous reports which included, persistent pyrexia and cough, reduced exercise tolerance and submandibular lymphadenopathy. Many humans complain of arthralgia and this could explain the apparent back pain with lack of spinal radiological abnormalities in case two. The adventitious lung sounds were characterised by mild crackles which is similar to human cases of COP (Woodhead and du Bois 1991). Neither dog had a microbial infection or eosinophilia, both had vaccinations that were current, there was a lack of exposure to inhaled toxins or exposure to drugs prior to the onset of clinical signs and rapid resolution of clinical and radiological findings to corticosteroids. Differentials of idiopathic ILDs in dogs include IPF, EBP, COP, histiocytosis X, sarcoidosis and hypersensitivity

pneumonitis (Norris and others 2002). Cytology of BAL and/or radiographic findings can differentiate some of these ILDs. Idiopathic pulmonary fibrosis will have increased reticular interstitial markings with a bronchial pattern (Corcoran 1991). Histiocytosis X is characterised by nodular infiltrates on radiographs and atypical histiocytes on BAL, sarcoidosis is typified by lymphadenopathy, bullae and cysts with epithelioid cells, multi-nucleated giant cells, with lymphocytes and plasma cells (Norris and others 2002). Eosinophilic bronchopneumopathy could have alveolar, interstitial or bronchial lung pattern but BAL is distinctive in that there is an overwhelming eosinophilic inflammation (Corcoran 1991).

Results of BAL cytology in humans is typically lymphocytic (20%) and neutrophil percentage (10%) exceeding eosinophils (Cordier 2006). The BAL cytology in previously reported canine COP cases had increased mucus without an inflammatory leukogram to a mixed inflammatory to monocytic response (Norris and others 2002; Phillips and others 2000). The two cases in this report both had a sterile suppurative cellularity with a higher proportion of neutrophils to lymphocytes or monocytes unlike the description in of this disease in humans and previous reports of COP in dogs. The cytology pattern depicted in both the dogs described in our case report was predominantly neutrophils. This should indicate a more serious inflammatory process with possible tissue necrosis, alternatively it could depict a later stage of the disease. Interestingly histopathology, the definitive diagnostic test, does not correlate the degree of inflammation with the BAL cytology (Phillips and others 2000) and thus inferences regarding disease severity from BAL cytology should not be made.

In humans, diagnosis of ILDs relies on cytology of BAL, lung function tests and CT, precluding the need for biopsy in patients too old or frail for this procedure. However video-assisted thoracoscopic biopsy is considered a safe technique allowing biopsy from several lobes if transbronchial biopsies are too small and suffer from crush artefact (Cordier 2006). Collection of lung biopsies by a keyhole technique is described in dogs but the respiratory condition in two of the 11 dogs biopsied

deteriorated requiring euthanasia (Norris and others 2002). One of the three dogs with confirmed IPF, biopsied by thoracotomy died of respiratory complications intra-operatively (Lobetti and others 2001). Biopsy is important for ruling out neoplasia, confirming the diagnosis and prognosticating ILD or when the risk of using corticosteroids is considered high. However, a biopsy may have serious complications (Norris and others 2002).

Both cases were seen by the first author within 6 months of each other in different geographical locations. Although described as a rare condition in humans and dogs it appears to be not as uncommon as previously thought. Both dogs were presumptively diagnosed, non-invasively, by exclusion of all causes of interstitial and alveolar lung disease and rapid resolution of clinical signs in response to corticosteroid therapy.

#### **LEARNING POINTS/TAKE HOME MESSAGES**

- Cryptogenic organising pneumonitis is a rare condition in dogs, which has been described in the USA, China and now in Australia. This indicates that it should be considered worldwide as a differential diagnosis for ILD.
- More recently CT has become widely available and findings in case 1 is similar to the description in human and veterinary confirmed cases of COP and could be utilised as a non-invasive diagnostic technique, particularly if follow up CT shows resolution of the lung changes.
- Cryptogenic organising pneumonitis requires lung biopsy for definitive diagnosis, which is not always an option for veterinarians due to cost constraints and owner's perceived interpretation of risk and actual risk if the respiratory disease is advanced. A definitive diagnosis of COP could not be confirmed but EBP, the differential diagnosis, was ruled out based on BAL cytology.
- In cases with a history of persistent pyrexia and coughing with reduced exercise tolerance, an inflammatory leukogram on haematology, patchy alveolar pattern,

where BAL has excluded a microbial aetiology and EBP, steroids should be considered as a therapeutic option.

This case report includes a dog that relapsed after discontinuation of steroids and responded after reinstating therapy, possibly indicating the need for on-going therapy as in the case of primary immune-mediated disease. However one of the cases was cured and weaning off treatment should be attempted in all cases.

## REFERENCES

- AMERICAN THORACIC SOCIETY (ATS)/EUROPEAN RESPIRATORY SOCIETY (ERS) (2002) International Multidisciplinary Consensus Classification of the Idiopathic Interstitial Pneumonias. *American Journal of Respiratory and Critical Care Medicine* 165, 277-304
- CHANDLER, P. W., SHIN, M. S., FRIEDMAN, S. E., MYERS, J. L. & KATZENSTEIN, A. L. (1986) Radiographic manifestations of bronchiolitis obliterans with organizing pneumonia vs usual interstitial pneumonia. *American Journal of Roentgenology* 147, 899-906
- CORCORAN BM, T. K., HENFRY J.I., SIMPSON J.W., BURNIE A.G., MOONEY C.T. (1991) Pulmonary infiltrates of eosinophils in 14 dogs. *Journal of Small Animal Practice* 32, 9
- CORDIER, J. F. (2006) Cryptogenic organising pneumonia. *European Respiratory Journal* 28, 422-446
- CRYSTAL, R. G., BITTERMAN, P. B., RENNARD, S. I., HANCE, A. J. & KEOGH, B. A. (1984) Interstitial lung diseases of unknown cause. Disorders characterized by chronic inflammation of the lower respiratory tract. *New England Journal of Medicine* 310, 235-244
- LEE, K. S., KULLNIG, P., HARTMAN, T. E. & MULLER, N. L. (1994) Cryptogenic organizing pneumonia: CT findings in 43 patients. *American Journal of Roentgenology* 162, 543-546
- LEE, J.W., LEE, K.S, LEE.H.Y, YI.C.A., KIM.T.S. & CHUNG M.J. (2010) Cryptogenic organising pneumonia: Serial high-resolution CT findings in 22 patients. *American Journal of Radiology* 195, 916-922

LI, X., BOTTS, S., MORTON, D., KNICKERBOCKER, M. J. & ADLER, R. (2006) Oleic acid-associated bronchiolitis obliterans-organizing pneumonia in beagle dogs. *Veterinary Pathology* 43, 183-185

LOBETTI, R. G., MILNER, R. & LANE, E. (2001) Chronic idiopathic pulmonary fibrosis in five dogs. *Journal of the American Animal Hospital Association* 37, 119-127

NORRIS, C. R., GRIFFEY, S. M. & WALSH, P. (2002) Use of keyhole lung biopsy for diagnosis of interstitial lung diseases in dogs and cats: 13 cases (1998-2001). *Journal of the American Veterinary Medical Association* 221, 1453-1459

PHILLIPS, S., BARR, S., DYKES, N., SCRIVANI, P., KRAUS, M., RISHNIW, M. & VALENTINE, B. (2000) Bronchiolitis obliterans with organizing pneumonia in a dog. *Journal of the Veterinary Internal Medicine* 14, 204-207

WOODHEAD, M. A. & DU BOIS, R. M. (1991) Bronchiolitis obliterans, cryptogenic organising pneumonitis and BOOP. *Respiratory Medicine* 85, 177-178