

Imaging diagnosis of muscle herniation of the forearm

Dr Yacoob Omar Carrim¹ MBChB(UP), BCom(Hons)DSM

Dr Rene Truter² MBChB, MMed(Rad)(D) Stell

Dr Farhana Suleman¹ FCRad(D)(SA), MMed(Rad)(D) Medunsa

Prof Savvas Andronikou^{2,3} MBBCh(Wits), FCRad(Diag)(SA), FRCR(Lond), PhD(UCT)

¹Department of Radiology, University of Pretoria, Pretoria, South Africa

²Drs Schnettler, Corbett and Partners, Cape Town, South Africa

³Department of Radiology, Faculty of Health Sciences, University of the Witwatersrand, Johannesburg, South Africa

Correspondence:

Dr YO Carrim

Department Diagnostic Radiology

University of Pretoria

PO Box 14336

Laudium

0037

South Africa

Email: ycarrim@gmail.com

Tel: +2712 354 2406

Abstract

Muscle herniation is defined as a protrusion of muscle through an acquired or congenital defect of enclosing fascia. There have been 19 cases of symptomatic forearm muscle herniation reported in the literature. In this article we present a case of a 26-year-old factory worker who developed a traumatic forearm muscle herniation diagnosed on ultrasound and MRI, and we review the imaging of muscle hernias.

Key words: forearm, muscle herniation, ultrasound, MRI

Introduction

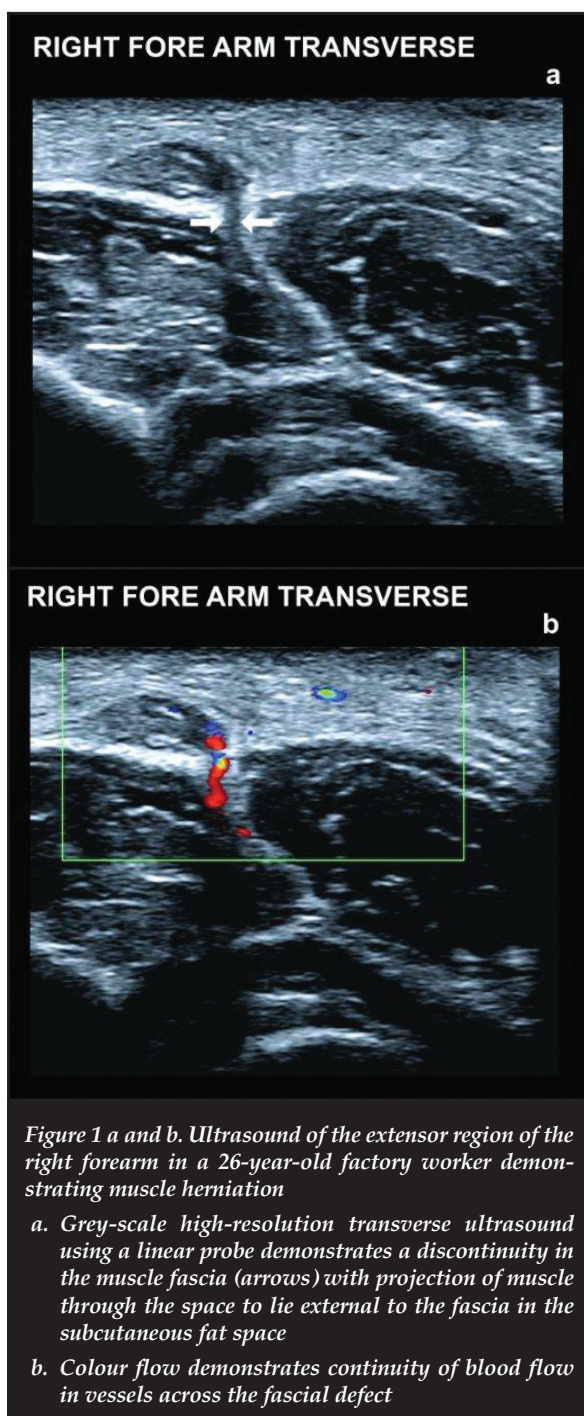
Muscle herniation is defined as protrusion of muscle through an acquired or congenital defect of enclosing fascia.¹ Fascial defects may be described as traumatic or constitutional. Traumatic causes may result from direct or indirect trauma¹ and fascial tears are caused by direct penetrating wounds or fascial ruptures produced by blunt trauma on a contracted muscle.^{2,3} Constitutional causes of fascial defects may be due to exertional fatigue² or may be secondary to vigorous exercise followed by hypertrophy and elevation of intracompartmental pressure.¹

We present the role of imaging for the rare situation where a factory worker developed a forearm muscle hernia, spontaneously, while lifting a heavy weight, and without having sustained any preceding injury.

The ultrasonographic findings were confirmed by MRI, using fast spin echo (FSE) images in the axial, coronal and sagittal planes before and after muscle contraction

Case report

A 26-year-old male factory worker felt a lump in the right elbow region, near the common extensor compartment, after the strenuous task of lifting a heavy weight. He presented to his physician with a non-tender soft tissue mass, measuring 3 cm over the medial left forearm. The patient showed full range of motion for the wrist and hand.



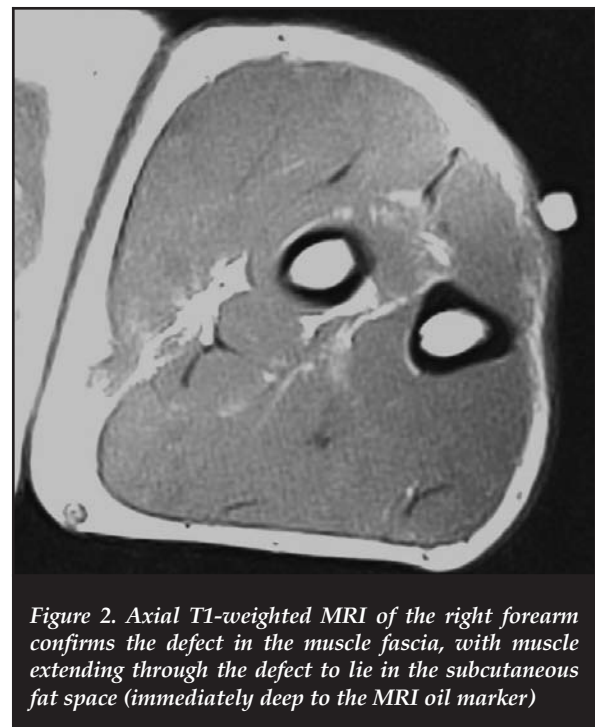
A facial defect with muscle herniation was noted using dynamic sonographic examination (*Figures 1a and b*). Colour Doppler sonogram also showed prominent vessels traversing the fascia at the site of the hernia. No ultrasound features of chronic exertional compartment syndrome were present.

The ultrasonographic findings were confirmed by MRI, using fast spin echo (FSE) images in the axial, coronal and sagittal planes before and after muscle contraction. MRI demonstrated the size of the muscle herniation and the extent of the fascial defect while the forearm was contracted (*Figure 2*). Again no features of chronic exertional compartment syndrome were present. The patient was advised of the diagnosis and referred to the orthopaedic department.

Discussion

Symptomatic muscle herniations in the lower extremities are much more common than in the upper limb, with the anterior compartment of the lower leg being the most common site.⁴ Symptomatic forearm muscle herniation is a rare entity¹ with only 19 cases described in the literature. Most are caused by trauma and only four reported cases were caused by strenuous exercise.⁴

The aetiology of muscle herniation is thought to occur secondary to muscle hypertrophy and increase in intra-compartment pressure from forced exertion of strenuous activity. The muscle usually herniates in areas of weakness, where the neurovascular bundles penetrate the deep fascia. Muscle herniation usually occurs secondary to trauma and rarely from strenuous exercise.⁴



Patients usually complain of pain or discomfort with pronation or supination of the hand¹ secondary to forced exertion or strenuous activity or following trauma. On physical examination a soft tissue swelling over the ventral forearm, which becomes prominent following the making of a fist, is characteristic.¹ The muscle bulge, usually located in the middle of the forearm,⁵ becomes tense after contraction in the area of the muscle defect^{1,6} and is effaced or shrinks when the muscle is relaxed.⁶ Most hernias are located in the mid-forearm and not the distal forearm.⁵ Proximal mid-forearm fascial defects overlie muscle that may protrude, causing a bulge with local muscle contraction. Distal fascial defects do not overlie muscle bellies and do not cause muscle hernia when there is a fascial defect and therefore do not cause a bulge.⁵ Pain is due to muscle protrusion as the hernia courses against the proximal fascial edge of the defect.⁵

The diagnosis of muscle herniation can be suspected clinically but radiological evaluation is useful for definitive diagnosis, especially in the cases with associated soft tissue oedema and/or hypertrophy of subcutaneous fat.^{1,7}

Radiographs reveal a focal soft tissue mass over the ventral medial forearm that becomes prominent with making a fist.¹ Plain films and CT may detect calcification and allow assessment of adjacent bony structures but, unlike ultrasound and MRI, do not offer much in the way of tissue characterisation.⁵

The diagnosis of muscle herniation can be suspected clinically but radiological evaluation is useful for definitive diagnosis

Ultrasound is performed using a high frequency linear transducer in the longitudinal and transverse planes and includes both static and dynamic examination of the forearm. Dynamic imaging involves rest, isotonic muscle contraction, and compression of the herniation for reduction.¹ The skin should be marked because the mass may be difficult to feel during sonographic examination.⁶ Coupling gel should be applied liberally, gain focus should be set to optimise the near field and the transducer should be applied lightly to avoid effacing the hernia.⁶ The contralateral forearm may also be examined.¹ Sonographic evaluation demonstrates the normal muscle fascia as a continuous hyperechoic linear structure with a mean thickness of 1 mm. Fascial defects and the muscle herniation can be demonstrated directly with dynamic sonographic examination.¹ Longitudinal sonogram shows the fascia is thinned and elevated by a small bulge.⁶ Colour Doppler sonogram shows prominent vessels traversing fascia at the site of the hernia.⁶ The advantage of ultrasound is its relative ease of application, relative increased access to all the muscle groups, low cost and reduced time required to make a diagnosis.^{2,8}

Sonographic features of muscle herniation are characteristic and exclude alternative clinical diagnosis such as tumours.^{6,8} Dynamic ultrasonography can successfully reduce the hernia during the examination by compression of the transducer over the tissue mass.^{1,3} Sonography can also determine the size of the hernia and the extent of the fascial defect. However, ultrasonography remains a user-dependent investigation. Ultrasonography post-exertional depth perception may also be useful as a non-invasive investigation complementing direct intramuscular depth perception to diagnose chronic exertional compartment syndrome.⁹

There have been limited reports of MRI for muscle herniation.^{1,5} Dynamic MRI may be useful for surgical planning. MRI is not operator-dependent, and its findings are reproducible. MRI may help in the evaluation of the amount of soft tissue oedema and the identification of the specific muscles and structures involved. MRI of a muscle hernia is a visualised local defect, with measurable size and extent of the fascial defect.² MRI of chronic exertional compartment syndrome may be noted as either a focal area of signal change or as an area of diffuse signal change within an osteofascial plane.

In asymptomatic patients with forearm muscle herniation, surgical options are best considered only after a trial of conservative management.¹⁰ Patients that present with symptomatic pain on extremity exertion or an unaesthetic bulge are candidates for surgery.⁵ Surgical management is by fascial repair, fasciotomy or anatomical repair of the fascial defect. Fascial repair, particularly in patients with lower limb muscle herniation, has been associated with chronic compartment syndrome.^{10,11} Fasciotomy may reduce the risk of compartment syndrome, but may leave an unappealing forearm deformity, and there have been reports of incomplete resolution of pain on extremity exertion. Anatomical repair with autologous inlay grafts and mesh have also been used in the management of forearm muscle herniation,⁷ but morbidity at the donor site is a drawback.³ Polypropylene mesh may allow early return to activities without undue concern for herniation.²

Conclusion

Forearm muscle herniation is a rare entity. When forearm muscle herniation is symptomatic, radiology through dynamic ultrasound and dynamic MRI, as in our patient, can make a definitive diagnosis and assist in surgical planning and management.

No funding or grants were used in the preparation of this manuscript.

Ultrasound is performed using a high frequency linear transducer in the longitudinal and transverse planes and includes both static and dynamic examination of the forearm

References

1. Kendi TK, Altinok D, Erdal HH, Kara S. Imaging in the diagnosis of symptomatic forearm muscle herniation. *Skeletal Radiol.* 2003;32:364-66.
2. Bruce J, Robertson, Sanders BS. Treatment of a symptomatic forearm muscle herniation with a mesh graft. *Sports health: a multidisciplinary approach* 2011;3:179-81.
3. Roberts JO, Regan PJ, Dickinson JC, Bailey BN. Forearm muscle herniae and their treatment. *J Hand Surg Br.* 1989;14:319-21.
4. Khalid KA, Mah ET. Case report - Treatment of a symptomatic forearm muscle herniation with a wrap-around fascia lata graft. *Journal of Hand and Microsurgery* 2009;1:54-59.
5. Olch CL, Watson HK. Symptomatic forearm fascial hernia. *J Hand Surg Am.* 1996;21:693-95.
6. Beggs I. Sonography of muscle hernias. *AJR Am J Roentgenol* 2003;180:395-99.
7. Golshani SD, Lee C, Sydorak R. Symptomatic forearm muscle hernia: repair by autologous fascia lata inlay. *Ann Plast Surg.* 1999;43:204-206.
8. King TW, Lerman OZ, Carter JJ, Warren SM. Exertional compartment syndrome of the thigh: a rare diagnosis and literature review. *J Emer Med;* 2010;39:e93-99.
9. Wassermann D, Oschmann Z. Role of ultrasound as a non-invasive method of diagnosis of chronic exertional compartment syndrome. *SA Orthop J.* 2011;10(4):59-65.
10. Miniaci A, Rorabeck CH. Compartment syndrome as a complication of repair of a hernia of the tibialis anterior: a case report. *J Bone Joint Surg Am.* 1986;68:1444-45.
11. Wolfort FG, Molvang LC, Piltzer HS. Anterior tibial compartment syndrome following muscle hernia repair. *Arch Surg.* 1973;106:97-99.

This article is also available online on the SAOA website (www.saoa.org.za) and the SciELO website (www.scielo.org.za). Follow the directions on the Contents page of this journal to access it.