

# THE USE OF ELECTRO-ENCEPHALOGRAPHY AND BRAIN BIOPSY IN THE CLINICAL DIAGNOSIS OF HEARTWATER

S. R. VAN AMSTEL<sup>(1)</sup>

## ABSTRACT

VAN AMSTEL, S. R., 1987. The use of electro-encephalography and brain biopsy in the clinical diagnosis of heartwater. *Onderstepoort Journal of Veterinary Research*, 54, 295-299 (1987)

Both electro-encephalography and brain biopsy were examined as possible aids in the confirmation of a clinical diagnosis of heartwater in field cases. Results showed that electro-encephalographic changes associated with heartwater were non-specific and probably caused by the associated brain oedema. Brain biopsy on the other hand appears to be a reliable technique for the confirmation of heartwater, and the technique if properly performed holds little risk for the animal.

## I. THE ELECTRO-ENCEPHALOGRAPH (EGG) AS A DIAGNOSTIC AID IN HEARTWATER

### INTRODUCTION

Changes in the normal resting potential of nerve cells result in action potentials or "impulses" which "fire" the cell resulting in electrical activity which in the central nervous system is converted into rhythmical discharges in the hypothalamus (Ganong, 1975). This rhythmicity is evidenced by surface electro-encephalographic recordings in the form of rhythmic waves (Ganong, 1975).

Diagnostic electro-encephalography has been widely used in human medicine (Remond, 1974). In veterinary medicine the EEG is extensively used as a diagnostic aid in small animal neurology whereas in cattle and sheep it has been used mainly to examine physiological phenomena of the central nervous system (Merrick & Scharp, 1971). A technique for EEG examination in the bovine has been described (Schneider, Gunstheimer & Eckold, 1978). In this study a similar technique was used. Characteristically the wave forms of the normal bovine EEG represent a low voltage fast activity pattern in all the electrode channels. According to standard analytical methods the normal bovine EEG has an alpha rhythm (8-13 waves/s) with a low amplitude (Schneider, Gunstheimer & Eckold, 1978).

The objectives of this study were firstly to determine whether heartwater was associated with any specific EEG changes which could be used as an aid in clinical diagnosis, and, secondly, to determine whether the EEG could be used to evaluate the effectiveness of the therapy employed.

### MATERIALS AND METHODS

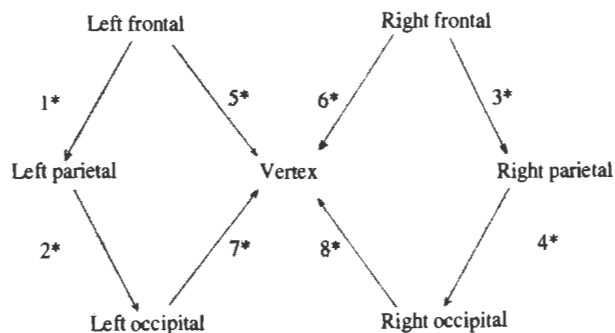
#### EEG recordings

EEG recordings were carried out using an eight channel mingograph (Elema-Schonander, Stockholm, Sweden). Placement of the electrodes is shown in Fig. 1.

The mingograph was used at a setting of 100 mV and a paper speed of 30 mm/s. A 15 Hz filter was employed. Analysis of the EEG was carried out using standard methods and described in terms of amplitude, frequency, waveform and location and incidence of abnormal waveforms. EEG recordings were made on animals which had been neither anaesthetized or tranquilized.

#### Experimental animals

EEG recordings were made on 4 normal calves and on 6 calves and 1 sheep with natural heartwater. Of these, 3 cases were confirmed on brain biopsies in live animals



\* Represents electrical channels

FIG. 1. Electrode placement for EEG recording in the bovine

whereas the diagnosis in the others were based on clinical signs (pyrexia, hyperaesthesia, hypermetria, recumbency with paddling and opisthotonus) and response to treatment. The same treatment was used in all cases including oxytetracycline<sup>1</sup> at a dose rate of 10 mg/kg once a day. This was given intravenously on the first occasion, then by the intramuscular route. Furosemide<sup>2</sup> at 1 mg/kg was given intramuscularly and repeated 6-8 hourly for 2-3 injections, and betamethazone<sup>3</sup> at 1 mg/kg was administered intravenously once only. EEG recordings of clinical cases were carried out shortly after presentation during the acute phase when all the animals showed neurological signs regarded as indicative of heartwater.

In three cases repeat EEG's were carried out after 24 h to evaluate EEG changes associated with response to treatment.

### RESULTS

EEG's obtained from normal bovines typically showed a low voltage, fast activity pattern (LVFA) in all the channels, classified as an alpha rhythm (8-13 waves/s) and is shown in Fig. 2.

EEG's obtained from normal bovines typically showed a low voltage, fast activity pattern (LVFA) in all the channels, classified as an alpha rhythm (8-13 waves/s) and is shown in Fig. 2.

EEG changes in response to treatment are shown in Fig. 4 and 5.

### DISCUSSION

The normal bovine EEG is characterised by a low voltage alpha-rhythm whereas clinical heartwater cases show a high voltage theta or delta rhythm with the absence of any discrete features. This suggests diffuse

<sup>(1)</sup> Department of Medicine, Faculty of Veterinary Science, University of Pretoria, Onderstepoort 0110

Received 28 April 1987—Editor

<sup>1</sup> Engemycin, Coopers Animal Health

<sup>2</sup> Lasix, Hoechst

<sup>3</sup> Betsolan, Milvet

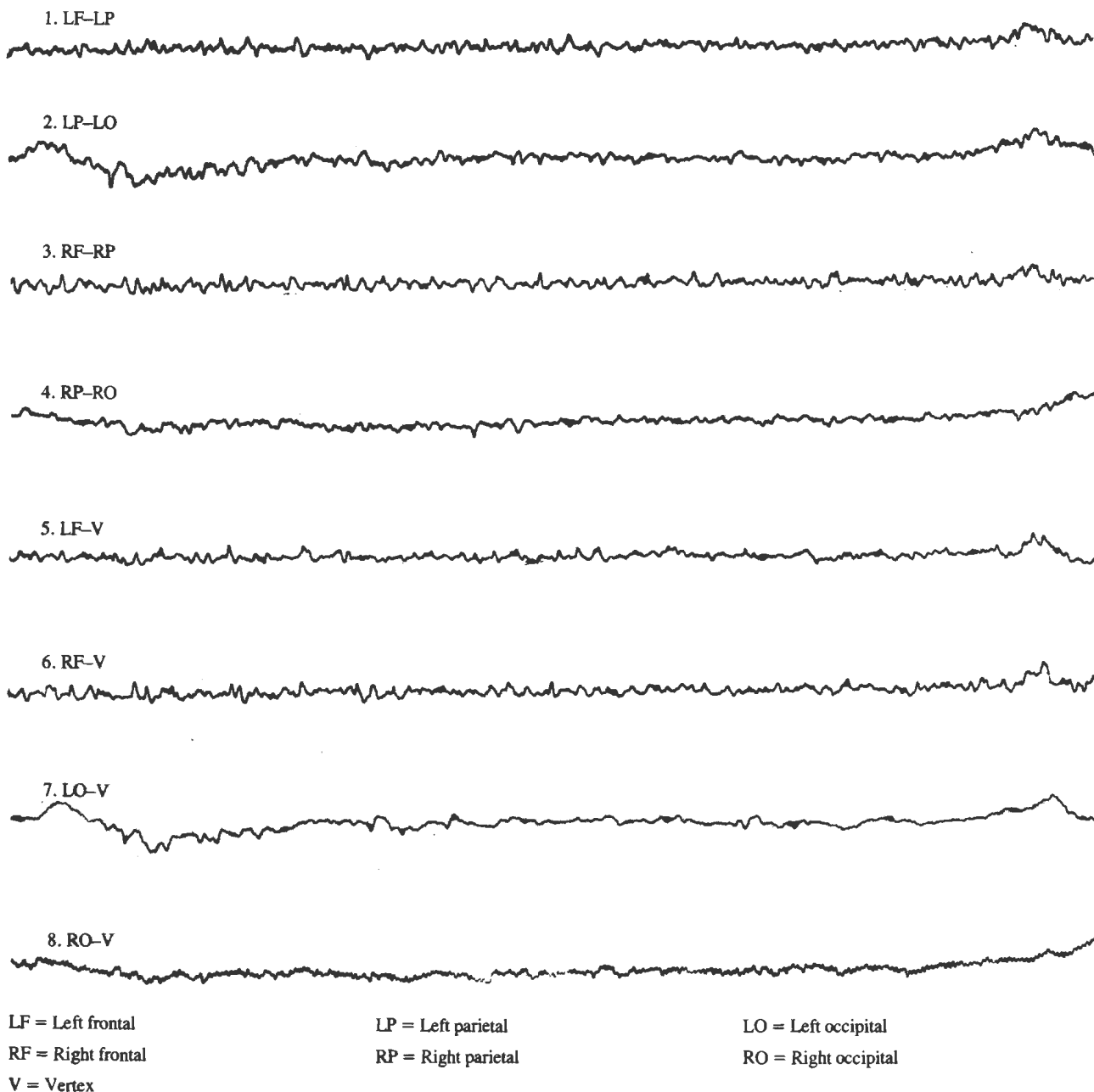


FIG. 2. EEG wave form in a normal bovine

brain involvement and is probably associated with the presence of cerebral oedema and congestion. This may be supported by the fact that the EEG changes described virtually reverted to normal 24 h after the implementation of specific and supportive treatment. As this HVSA is a non-specific change and regarded as the most common finding associated with CNS disease (Klemm, 1969), it can be of little value in the clinical confirmation of heartwater. The HVSA was present in all seven heartwater cases tested suggesting that it could be a fairly consistent finding which implies that it may be of value in the differential diagnosis of other clinical cases showing heartwater-like symptoms.

EEG changes associated with heartwater returned to near normal within 24 h in three cases which responded favourably to specific and supportive treatment. The diagnosis was confirmed in one case with a brain biopsy. These results suggest that the EEG might be used as a more objective aid in evaluating the response of CNS changes associated with heartwater to specific and supportive treatment regimes.

## II. BRAIN BIOPSY AS A DIAGNOSTIC AID IN HEARTWATER

### INTRODUCTION

A rapid reliable technique for the confirmation of heartwater in clinical medicine is desirable as there are several disease conditions which can resemble it closely (Camus & Barré, 1982). Furthermore, "atypical" cases of the disease are often encountered in the field. A technique to obtain brain material for demonstration of the causal organism has been described in goats (Synge, 1978). A similar study was undertaken in field cases of heartwater in ruminants in an effort to evaluate the ease and reliability of the technique.

### MATERIALS AND METHODS

#### *Experimental animals*

Brain biopsies were carried out in 7 field cases of suspected heartwater (5 calves, 1 sheep and 1 goat) given to the Department of Medicine, Faculty of Veterinary Science, University of Pretoria, Onderstepoort. Biopsies




FIG. 3. Typical EEG wave form obtained from bovines suffering from heartwater

were carried out once only, shortly after the animals were received. Seven cases were selected which showed severe clinical signs and in which the prognosis was regarded as poor. The seven cases showed some or all of the following clinical signs: lateral recumbency, clonic convulsions, opisthotonus, extensor rigidity of the front legs, hypersensitivity, paddling, harsh lung sounds and fever.

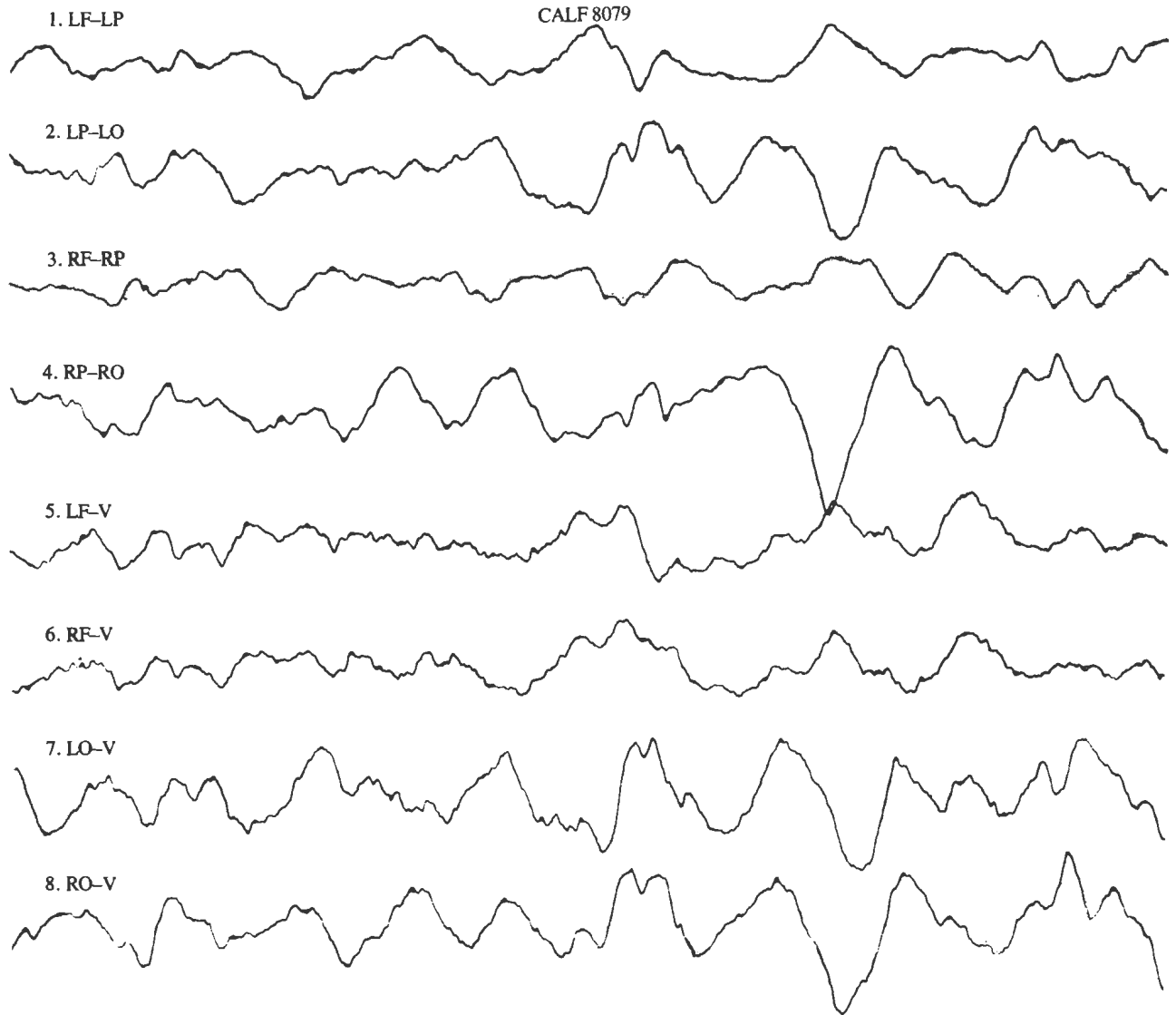
#### *Brain biopsy technique*

The technique used in the case of the sheep and goat was the same as that described by Syngé (1978). The following technique was employed in the case of the calves: the area between the supraorbital region ventrally, the crista temporalis laterally and the linea nuchalis dorsally was shaved and aseptically prepared. Local anaesthesia was carried out at the biopsy site which is located two thirds along a straight line connecting the medial canthus of the eye and the intercornual protuberance. This site allows entrance into the cranial cavity corresponding to the middle of the cerebral hemisphere. A small cut was made through the skin onto the skull at the biopsy site. A hole was drilled through the skull

using an orthopedic bonechuck and small steel pin of a size which just allows a 18 g hypodermic needle to pass through. Development of the frontal sinus should be considered during this procedure. In young calves only one bony layer is present whereas in older calves expansion of the frontal sinus results in the presence of two bony layers which will have to be penetrated before entrance into the cranial cavity can be effected. Once the meninges have been penetrated, a serosanguinous fluid will often escape through the biopsy hole indicating that the desired depth has been reached.

A 20 ml syringe with a 18 gauge needle was used to collect the brain material. First the 18 g hypodermic needle was put in place allowing the tip to penetrate into the cerebral cortex for a short distance (approximately half the length of the 35 mm needle remained visible). The 20 ml syringe was then attached to the needle and suction applied while the syringe and needle were removed at the same time. A small piece of cerebral cortex will enter the syringe or may remain in the needle and can then be blown out onto a glass slide for preparation of a smear. The skin is closed in a routine manner.

USE OF ELECTRO-ENCEPHALOGRAPHY AND BRAIN BIOPSY IN THE CLINICAL DIAGNOSIS OF HEARTWATER



LF = Left frontal                      LP = Left parietal                      LO = Left occipital  
 RF = Right frontal                      RP = Right parietal                      RO = Right occipital  
 V = Vertex

FIG. 4. EEG wave form obtained from a calf suffering from heartwater

TABLE 1. Results of the brain biopsies taken in seven field cases of suspected heartwater

Identification	Brain biopsy for heartwater	Days sick before biopsy	Post mortem diagnosis
F 9810 (calf)	Positive	3	Heartwater
F 9717 (sheep)	Negative	Unknown	Hepatositis
F 12387 (goat)	Positive	Unknown	Heartwater
F 13606 (calf)	Positive	3	Heartwater
F 14406 (calf)	Positive	3	Heartwater
F 14644 (calf)	Positive	2	Purulent meningitis negative heartwater
F 791 (calf)	Positive	2	Recover with treatment

RESULTS

The results of the brain biopsies are shown in Table 1.

DISCUSSION

There seems to be a good correlation between brain biopsies and post mortem results in field cases of heartwater. The high percentage of positive brain biopsies is probably due to the selection of cases showing severe clinical signs and the time lapse of two to three days

between the observation that the animal was sick and when the brain biopsy was carried out. Syngé (1978) had 7/11 positive brain biopsies on the third day of the febrile reaction in experimentally-induced heartwater in goats. In field cases a time lapse of several days is usual before animals are treated. Brain biopsy, in these circumstances, can be a reliable diagnostic tool. Only one case (F 14644), which had a positive brain biopsy, and which died five days later of a purulent meningitis, was negative for heartwater organisms on post mortem. This ani-

CALF 8079

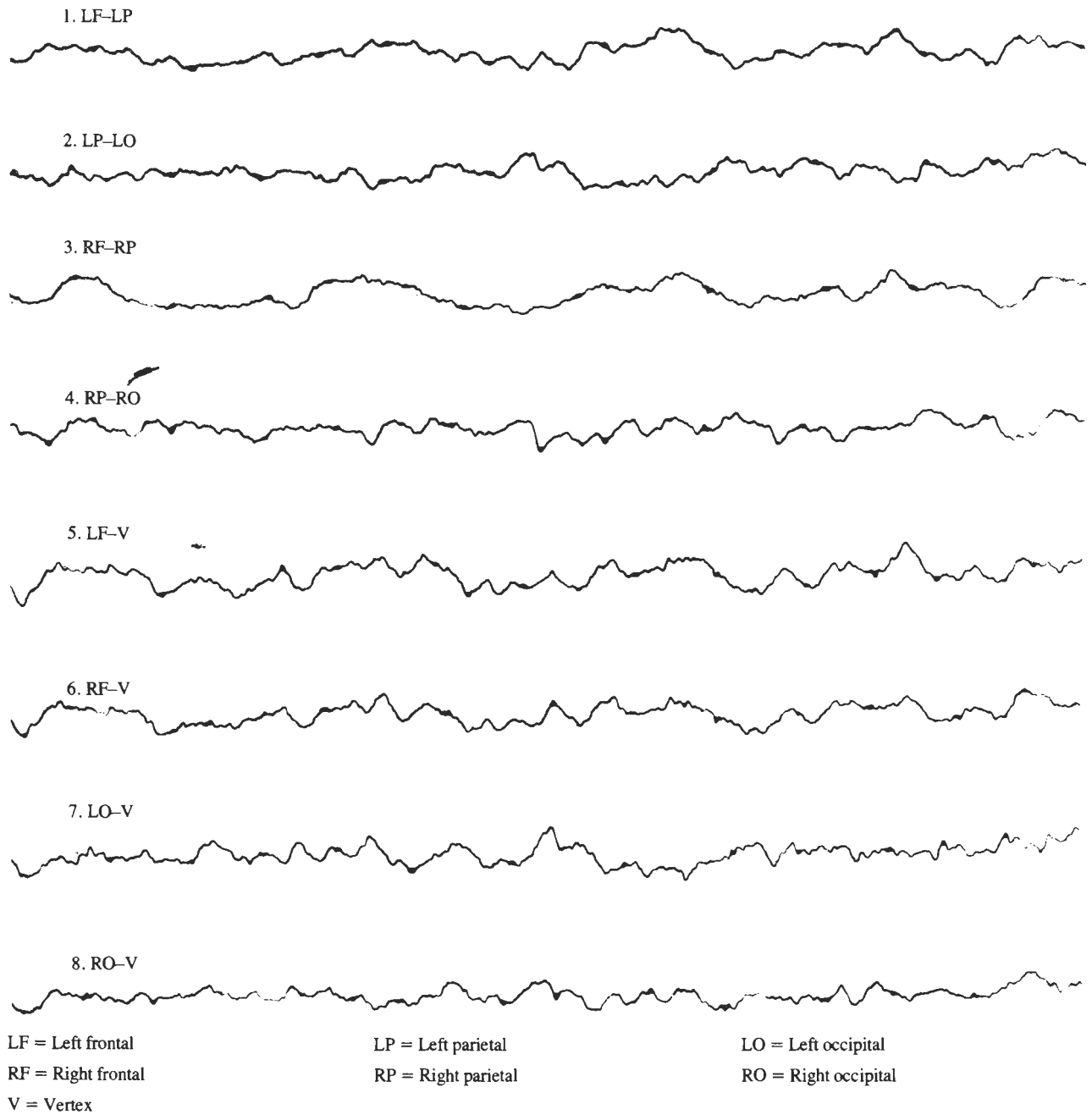


FIG. 5. EEG wave form obtained from a calf 24 h after heartwater treatment

mal initially responded very well to specific and supportive treatment but suddenly became sick again three days after the brain biopsy and died two days later. It was concluded that the purulent meningitis was a complication of the brain biopsy and stresses the necessity for an aseptic technique.

On the whole the technique for brain biopsy, as described, is not difficult and if performed properly and with skill, holds little danger for the animal.

#### REFERENCES

- CAMUS, E., & BARRÉ, N., 1982. La cowdriose (Heartwater). *Revue générale des connaissances. Institut d'Élevage et de Médecine Vétérinaire des Pays Tropicaux*, diagnosis, 2-4.
- GANONG, W. F., 1975. The reticular activating system, sleep, and the electrical activity of the brain. *In: GANONG, W. F., (ed.). Review of medical physiology*. Lange Medical Publications. Los Altos: California, 121-129.
- KLEMM, W. R., 1969. EEG correlates of pathologic changes. *In: KLEMM, W. R., (ed.). Animal electroencephalography*. Academic Press. New York, 245-249.
- MERRICK, A. W. & SCHARP, D. W., 1971. Electroencephalography of resting behaviour in cattle, with observations on the question of sleep. *American Journal of Veterinary Research*, 32, 1893-1897.
- REMOND, A., 1974. Handbook of electroencephalography and clinical neurophysiology. Volume 2. Part C. The neuronal generation of the EEG. Elsevier Scientific Publishing Company, 1-54.
- SCHNEIDER, J., GUNSTHEIMER, H. & ECKOLD, K. W., 1978. Die Bedeutung der Elektroenzephalographie in der Veterinärmedizin. Methoden zur Ableitung des Elektroenzephalogrammes beim Rind. *Archiv für Experimentelle Veterinärmedizin*, 32, 9-21.
- SYNGE, B. A., 1978. Brain biopsy for the diagnosis of heartwater. *Tropical Animal Health and Production*, 10, 45-48.