

Anaesthetic management of two Bengal tiger (*Panthera tigris tigris*) cubs for fracture repair

Authors:

Gareth E. Zeiler¹
Eva Rioja²
Charlie Boucher¹
Adrian S.W. Tordiffe^{1,3}

Affiliations:

¹Department of Companion Animal Clinical Studies, University of Pretoria, South Africa

²School of Veterinary Science, University of Liverpool, United Kingdom

³National Zoological Gardens of South Africa, Pretoria, South Africa

Correspondence to:

Gareth Zeiler

Email:

gareth.zeiler@up.ac.za

Postal address:

Private Bag X04,
Onderstepoort 0110,
South Africa

Dates:

Received: 25 Jan. 2013

Accepted: 18 June 2013

Published: 08 Nov. 2013

How to cite this article:

Zeiler, G.E., Rioja, E., Boucher, C. & Tordiffe, A.S.W., 2013, 'Anaesthetic management of two Bengal tiger (*Panthera tigris tigris*) cubs for fracture repair', *Journal of the South African Veterinary Association* 84(1), Art. #995, 5 pages. <http://dx.doi.org/10.4102/jsava.v84i1.995>

Copyright:

© 2013. The Authors.
Licensee: AOSIS
OpenJournals. This work is licensed under the Creative Commons Attribution License.

Read online:

Scan this QR code with your smart phone or mobile device to read online.

This case series describes the anaesthetic management of two sibling Bengal tiger (*Panthera tigris tigris*) cubs that were found to have spontaneous femur fractures due to severe nutritional secondary hyperparathyroidism. Both cubs received a combination of medetomidine (25 µg/kg) and ketamine (4 mg/kg) intramuscularly and were maintained with isoflurane in oxygen. An epidural injection of morphine (0.1 mg/kg) and ropivacaine (1.6 mg/kg) was administered to both tigers, which allowed a low end-tidal isoflurane concentration to be maintained throughout the femur fracture reduction operations. Both cubs experienced profound bradycardia and hypotension during general anaesthesia, and were unresponsive to anticholinergic treatment. Possible causes for these cardiovascular complications included: drug pharmacodynamics (medetomidine, morphine, isoflurane), decreased sympathetic tone due to the epidural (ropivacaine) and hypothermia. These possible causes are discussed in detail.

Introduction

Nutritional secondary hyperparathyroidism (NSH) in tigers has been described from as early as 1965 (Slusher, Bistner & Kircher 1965). A case report of a six month old tiger cub suffering from a spontaneous humeral fracture due to NSH described the medical management (Krook & Whalen 2010). Currently, to the authors' knowledge, there are no comprehensive case reports describing the management of general anaesthesia in tiger cubs.

The present case describes the anaesthetic management of two tiger cubs undergoing surgical reduction of femur fractures due to NSH.

Case Reports

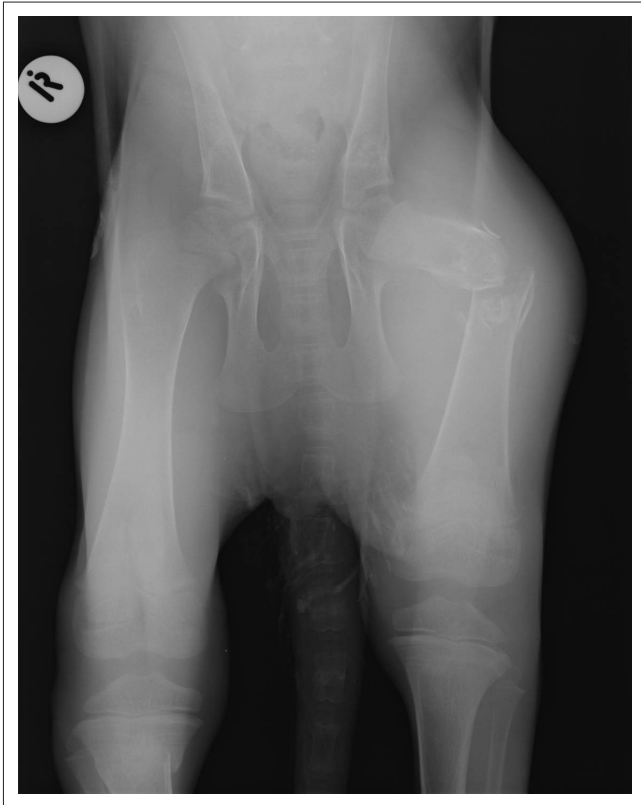History and diagnosis

Two five month old, emaciated, sibling Bengal tiger (*Panthera tigris tigris*) cubs were presented to the Onderstepoort Veterinary Academic Hospital (OVAH) for surgical repair of femur fractures. One was male and the other was female. These cubs had received medical management for 15 days at the National Zoological Gardens (NZG) prior to presentation. This was done to increase the cortical thickness of the femurs (Figure 1 and Figure 2) to allow for surgical stabilisation.

Anaesthetic management

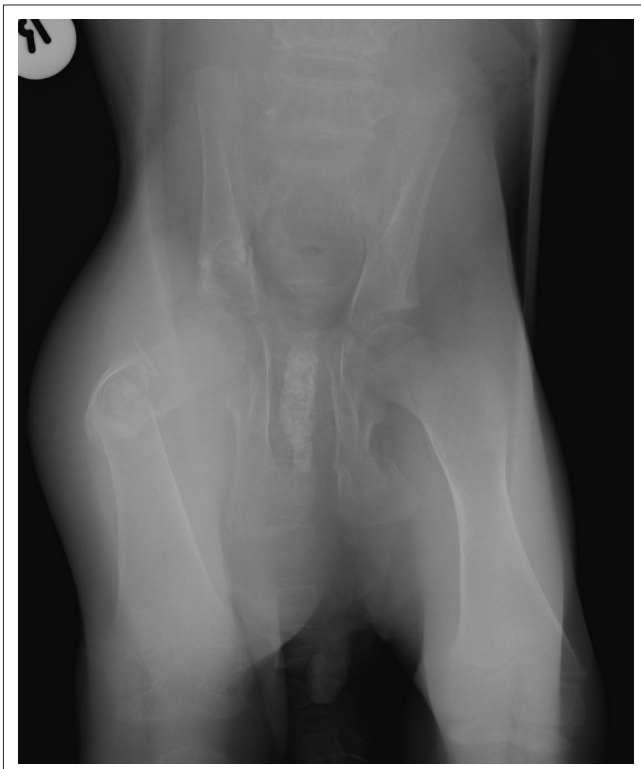
Both cubs were starved for 12 h prior to induction. The female cub received an intramuscular combination of 25 µg/kg of medetomidine (Domitor 1%; Pfizer Animal Health, South Africa) and 4 mg/kg of ketamine (Anaket-V 1%; Bayer Animal Health Division, South Africa). This was administered upon departure from the NZG veterinary hospital facility, 45 minutes prior to arrival at the OVAH. On arrival, the level of sedation was not sufficient to handle her safely, so a dose of 0.16 mg/kg of butorphanol (Torbugesic 1%; Fort Dodge Animal Health, South Africa) was administered intramuscularly to improve sedation and to allow cephalic intravenous catheterisation. Anaesthesia was induced with 2.4 mg/kg of propofol (Propofol 1% Fresenius Injection; Intramed, South Africa) and titrated intravenously to effect. Orotracheal intubation was performed using an 8 mm internal diameter cuffed endotracheal (ET) tube, which was immediately connected to a circle circuit. Anaesthesia was maintained with isoflurane (Isoflurane; Safeline Pharmaceuticals, South Africa) in 100% oxygen delivered via a precision vaporiser (Ohmeda Isotec 5; BOC Health Care, United Kingdom) set initially to 2% for radiographic evaluation.

After completion of the radiographic examination, the female cub was transferred to the theatre complex and maintained on isoflurane in oxygen, as described above. After aseptic preparation, a lumbosacral epidural injection was performed with a combination of 0.1 mg/kg of morphine (Morphine Sulphate Fresenius PF; Intramed, South Africa) and 1.6 mg/kg of ropivacaine 1%



Note: Long bone cortical areas show a double cortical line. There is marked osteopenia of all bones; a collapsed pelvic canal and left comminuted proximal femur diaphyseal fracture. These radiological findings are compatible with nutritional secondary hyperparathyroidism with pathological fractures.

FIGURE 1: Ventro-dorsal view of the pelvis of the female cub on initial examination.



Note: Long bone cortical areas show a double cortical line. There is marked osteopenia of all bones, a collapsed pelvic canal, a left ischial body fracture and a right comminuted proximal femur diaphyseal fracture. These radiological findings are compatible with nutritional secondary hyperparathyroidism with pathological fractures.

FIGURE 2: Ventro-dorsal view of the pelvis of the male cub on initial examination.

TABLE 1: Cardiopulmonary and expired gas values during anaesthesia of two Bengal tiger (*Panthera tigris tigris*) cubs undergoing surgical reduction of femur fractures.

Parameter	Female Cub		Male Cub	
	Mean \pm SD	Range	Mean \pm SD	Range
f_R (breaths/min)	10 \pm 0.86	8–11	17 \pm 6.42	11–30
HR (beats/min)	53 \pm 5.57	45–60	52 \pm 3.69	48–60
SAP (mmHg)	70 \pm 5.56	63–80	79 \pm 2.01	79–84
DAP (mmHg)	36 \pm 2.35	33–40	41 \pm 4.79	32–48
MAP (mmHg)	50 \pm 3.72	45–57	59 \pm 1.04	50–63
SpO ₂ (%)	98 \pm 2.20	92–100	98 \pm 1.57	95–100
PETco ₂ (mmHg)	38 \pm 1.95	35–40	35 \pm 1.67	32–36
PETco ₂ (kPa)	5.1 \pm 0.26	4.67–5.33	4.67 \pm 0.22	4.27–4.80
ET _{iso} (%)	1.1 \pm 0.18	1.0–1.9	1.0 \pm 0.05	1.0–1.1
Temp (°C)	33.4 \pm 0.96	32.3–34.9	35.1 \pm 0.66	34.4–36.0

Note: Date meaned over the duration of general anaesthesia.

f_R , respiratory rate; HR, heart rate; SAP, systolic arterial blood pressure; DAP, diastolic pressure; MAP, mean pressure; PETco₂, end-tidal carbon dioxide partial pressure; ET_{iso}, end-tidal isoflurane concentration; SpO₂, haemoglobin oxygen saturation; Temp, oesophageal temperature; SD, standard deviation; min, minutes.

(Naropin; AstraZeneca Pharmaceuticals, South Africa) using a 1.5 inch 22G spinal needle. Antibiotic cover was achieved by injecting 8 mg/kg of cefovecin sodium (Convenia; Pfizer Animal Health, South Africa) subcutaneously. A balanced crystalloid solution (Intramed Ringers-Lactate solution; Intramed, South Africa) was infused intravenously at 10 mL/kg/h throughout surgery.

Cardiopulmonary parameters and temperature were monitored using a multi-parameter anaesthetic monitor (Datex-Ohmeda S/5 Anesthesia Monitor; GE Healthcare, Finland). The following data were captured every 5 minutes: heart rate (HR); respiratory rate (f_R); peripheral haemoglobin oxygen saturation (SpO₂); end-tidal carbon dioxide tension (PET_{CO₂}); end-tidal isoflurane concentration (ET_{iso}); oesophageal temperature; and non-invasive blood pressure (BP) using an oscillometric BP cuff placed on the mid antebraechium. The measured parameters are summarised in Table 1. Intraoperative analgesia was achieved with 0.2 mg/kg of morphine, administered intravenously every two hours during the procedure. A single 0.2 mg/kg dose of meloxicam (Mobic; Ingelheim Pharmaceuticals, South Africa) was administered subcutaneously at the end of the procedure.

During anaesthesia, difficulty in maintaining body temperature, HR and BP was experienced. The temperature reached a nadir of 32.3 °C despite active warming techniques such as a warm water blanket, forced air warming device, heated intravenous fluids and warm water bottles. Warming efforts returned the temperature to 34.9 °C at the end of surgery. During anaesthesia, the HR decreased to a nadir of 45 beats/min and was associated with a mean arterial BP of 45 mmHg, which was unresponsive to three successive doses of 0.005 mg/kg of glycopyrrolate (Robinul; Pharmicare, South Africa) administered intravenously at 10 min intervals. The HR and mean arterial BP began to improve towards the end of general anaesthesia, achieving values of 60 beats/min and 56 mmHg respectively. An intraoperative blood glucose reading of 5.7 mmol/L was obtained 1 h 30 min into the operation. The cub experienced a delayed (1h) but otherwise uneventful recovery. Total anaesthesia and surgical time were 4 h and 2 h 30 min respectively.

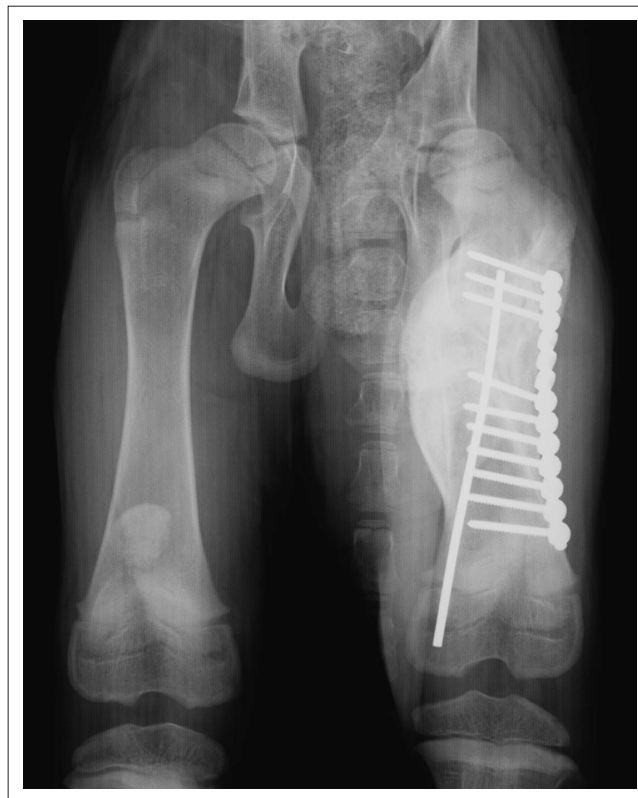Once the female cub had recovered from anaesthesia, the male was induced with the same intramuscular combination of medetomidine (25 µg/kg) and ketamine (4 mg/kg). Maximum effect of the drugs was achieved within 8 minutes and a cephalic intravenous catheter was placed. The male cub did not require further sedation with butorphanol or induction with propofol to achieve intubation. The anaesthetic protocol was otherwise the same as for the female cub. He then had radiographs taken, which was followed by the surgery. An intraoperative blood glucose reading of 5.9 mmol/L was obtained one hour into the operation. The male cub also developed intraoperative bradycardia (48 beats/min) and hypotension (mean arterial BP of 50 mmHg), which were unresponsive to two successive intravenous glycopyrrolate boluses (0.005 mg/kg). A temperature nadir of 34.4 °C was recorded and similar warming efforts were used as for the female in an attempt to restore temperature. Recovery was shorter (37 min) and uneventful. Total anaesthesia and surgical times were 2 h 45 min and 2 h respectively.

The cubs were managed post-operatively at the NZG. Radiographs taken on day 63 after surgery (Figure 3 and Figure 4) showed complete bridging calluses. Both cubs were discharged on day 71 and according to reports from the owner have continued to grow and develop normally.

Discussion

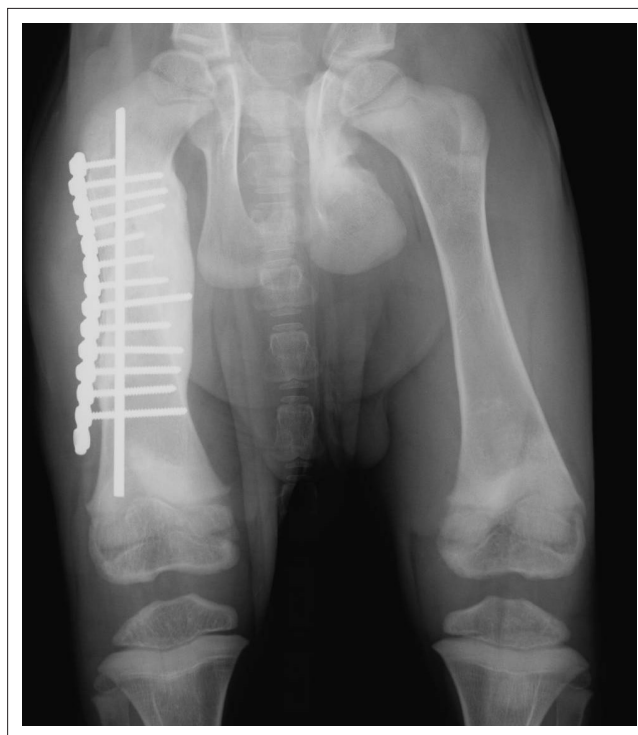
Induction of general anaesthesia in tigers is often achieved by administering an alpha₂-adrenoreceptor agonist in combination with a cyclohexamine anaesthetic agent (Curro *et al.* 2004; Forsyth, Machon & Walsh 1999; Ketz-Riley *et al.* 2004; Linnehan & Edwards 1991; Miller *et al.* 2003; Shilton *et al.* 2002; Steinmetz *et al.* 2010). The cubs received a single injection of a medetomidine and ketamine combination at recommended doses (Curro *et al.* 2004).

Both cubs experienced profound bradycardia and hypotension during anaesthesia. Multiple factors could have contributed to these effects. Bradycardia associated with hypertension was expected as a consequence of medetomidine and ketamine administration; on the contrary, the cubs were hypotensive. Thus, the bradycardia experienced in both cubs was unlikely to be due to the peripheral medetomidine effects causing vasoconstriction and hypertension. The peripheral vasoconstriction effects may have dissipated prior to measuring the blood pressure, thus the remaining bradycardia, which caused a decreased cardiac output, may partially explain the hypotension (Tranquilli, Thurmon & Grimm 2007). Centrally mediated effects of medetomidine may partially explain the bradycardia and hypotension, suggesting a relative overdose despite staying within the recommended dose ranges for adult tigers (Curro *et al.* 2004). Paediatric animals may be more sensitive to the pharmacodynamic effects of medetomidine than adult tigers (Tranquilli *et al.* 2007). Isoflurane and propofol are both vasodilators that cause a decrease in systemic vascular resistance (Tranquilli *et al.* 2007), which could have contributed to the hypotension. Morphine may also



Note: General bone density is within normal limits and there is a marked amount of callus formation associated with the proximal left femur fracture site, which is mature and bridging on the cranial and medial aspect of the fracture line. These radiological findings demonstrate satisfactory healing progress of the femoral fracture.

FIGURE 3: Ventro-dorsal view of the pelvis of the female cub on day 63 after surgical repair.



Note: General bone density is within normal limits. The left ischial body fracture is healing well with mature bridging callus formation, there is marked amount of callus formation associated with the proximal right femur fracture site, which is mature and bridging on the entire fracture line. These radiological findings demonstrate satisfactory healing progress of the ischial and femoral fractures.

FIGURE 4: Ventro-dorsal view of the pelvis of the male cub on day 63 after surgical repair.

cause bradycardia due to its direct stimulating effect on the central vagal nuclei, as well as hypotension due to vasodilation caused by depression of the vasomotor centres in the medulla, causing a decrease in the central sympathetic tone (Tranquilli *et al.* 2007). Local anaesthetics (ropivacaine), administered at high concentration and volume within the epidural space, are known to cause sympathetic blockade in the thoracolumbar region (Tranquilli *et al.* 2007), which may have contributed to the hypotension. Both cubs were also hypothermic during the procedure, which could have contributed to the bradycardia and hypotension due to a decrease in metabolism causing diminished cardiac muscle contractility and rate, and due to a hypothermia-induced increase in vagal tone (Tranquilli *et al.* 2007).

Typically, the body will release endogenous catecholamines in response to a hypotensive crisis in order to increase cardiac output and systemic vascular resistance to normalise BP. The intraoperative ET₅₀ concentrations for both cubs were under MAC_{BAR} (minimum alveolar concentration to block all autonomic responses) for domestic felines, reported to be 2.05% (March & Muir 2003). This suggests that if tigers respond in a similar fashion to isoflurane as domestic cats do, the normal physiological response to hypotension should have been activated. Hypothermia, medetomidine, butorphanol and morphine decrease adrenergic response to surgical stimulation and thus lower the MAC_{BAR} level in domestic animals (Tranquilli *et al.* 2007). It is therefore possible that the cubs were maintained at a MAC_{BAR} level despite the low ET₅₀.

The severe emaciation that they presented with could also partially account for the lack of normal physiological responses to hypotension due to either hypothalamic-pituitary-adrenal axis exhaustion and/or underdevelopment (Linda 2011). Cyclohexamine agents are potent cardiovascular depressants in the absence of endogenous catecholamines (Tranquilli *et al.* 2007); therefore, ketamine could also have contributed to the profound bradycardia and hypotension.

The mainstay treatment for bradycardia associated with hypotension unrelated to anaesthetic overdose is an anticholinergic agent such as glycopyrrolate. Both cubs were unresponsive to repeated standard small animal doses of glycopyrrolate to treat the bradycardia. Young animals are reliant on the chronotropic properties of the heart to maintain BP, as opposed to adults who rely more on the inotropic properties (Doherty & Valverde 2006). The treatment plan was to increase the HR in order to raise the cardiac output and consequently the BP. Due to the HR being under sympathetic rather than parasympathetic control, young patients tend to respond to a lesser degree to the effects of anticholinergic agents than adults (Tranquilli *et al.* 2007). Alternatively, atipamezole could have been administered to competitively antagonise the possible prolonged bradycardia induced by medetomidine, which may have improved cardiac output and blood pressure (Tranquilli *et al.* 2007). On the other hand, the normal BP in paediatric animals is lower than in adults, thus the hypotension could have been physiologically normal (Tranquilli *et al.* 2007).

However, paediatric HR is higher compared with adults. Medetomidine and ketamine were considered to be partially responsible for the cardiovascular derangements present in both cubs. A theoretically safer combination of alfaxalone, an opioid (morphine or butorphanol) and midazolam could have been considered as an alternative protocol for chemical restraint in these cubs. Physical restraint during induction was discouraged in these cubs due to the risk of inducing additional pathological fractures.

A multimodal analgesic approach was used, which included ketamine and medetomidine, intravenous morphine and lumbosacral epidural injection with morphine and ropivacaine. To the authors' knowledge, epidural administration of analgesic drugs has not previously been described in tigers. Morphine can provide up to 24 h (average 19.6 h) of analgesia when administered into the epidural space (Valverde 2008). Ropivacaine is a long-acting local anaesthetic that blocks sodium channels in nerves and therefore prevents noxious nerve impulses from reaching the central nervous system. This effect can last as long as four hours when the drug is administered into the epidural space of cats (Valverde 2008).

The ET₅₀ was maintained at a low level compared with case reports of tiger anaesthesia documenting ET₅₀ levels of 1.2% – 1.6% (Forsyth, Machon & Walsh 1999). The low ET₅₀ could have been due to a combination of factors including the epidural anaesthesia, intraoperative morphine and hypothermia. Meloxicam was also used in these tigers for post-operative analgesia, which has been used previously in tigers (Steinmetz *et al.* 2010).

Conclusion

The tiger cubs experienced bradycardia, hypotension and hypothermia during general anaesthesia with a combination of medetomidine, ketamine, propofol and isoflurane. Therefore, caution is advised when giving these combinations to tiger cubs, especially if they are suffering from a metabolic disease. Close monitoring of vital parameters and treatment of hypothermia are essential to avoid complications.

Acknowledgements

Publication of this article was sponsored by the Wildlife Group (<http://www.vets4wildlife.co.za>) of the South African Veterinary Association.

Competing interests

The authors declare that they have no financial or personal relationship(s) that may have inappropriately influenced them in writing this article.

Authors' contributions

E.R. (currently at the University of Liverpool) and A.S.W.T. (National Zoological Gardens of South Africa) are senior anaesthetists. C.B. (University of Pretoria) was responsible for the surgical repair of the femurs. G.E.Z. (University of Pretoria) was co-anaesthetist and wrote the case report.

References

- Curro, T.G., Okeson, D., Zimmerman, D., Armstrong, D.L. & Simmons, L.G., 2004, 'Xylazine-midazolam-ketamine versus medetomidine-midazolam-ketamine anesthesia in captive Siberian tigers (*Panthera tigris altaica*)', *Journal of Zoo and Wildlife Medicine* 35, 320–327. <http://dx.doi.org/10.1638/03-049>, PMID:15526886
- Doherty, T. & Valverde, A., 2006, *Manual of Equine Anesthesia and Analgesia*, Blackwell Publishing Ltd, Oxford. <http://dx.doi.org/10.1002/9780470753248>
- Forsyth, S.F., Machon, R.G. & Walsh, V.P., 1999, 'Anaesthesia of a Sumatran tiger on eight occasions with ketamine, medetomidine and isoflurane', *New Zealand Veterinary Journal* 47, 105–108. <http://dx.doi.org/10.1080/00480169.1999.36123>, PMID:16032083
- Ketz-Riley, C.J., Galloway, D.S., Hoover, J.P., Rochat, M.C., Bahr, R.J., Ritchey, J.W. et al., 2004, 'Paresis secondary to an extradural hematoma in a Sumatran tiger (*Panthera tigris sumatrae*)', *Journal of Zoo and Wildlife Medicine* 35, 208–215. <http://dx.doi.org/10.1638/01-087>, PMID:15305517
- Krook, L. & Whalen, J.P., 2010, 'Nutritional secondary hyperparathyroidism in the animal kingdom: Report of two cases', *Clinical Imaging* 34, 458–461. <http://dx.doi.org/10.1016/j.clinimag.2010.08.010>, PMID:21092876
- Martin, L.G., 2011, 'Critical illness-related corticosteroid insufficiency in small animals', *Veterinary Clinics of North America: Small Animal Practice* 41, 767–782. <http://dx.doi.org/10.1016/j.cvs.2011.03.021>, PMID:21757092
- Linnehan, R.M. & Edwards, J.L., 1991, 'Endometrial adenocarcinoma in a Bengal tiger (*Panthera tigris bengalensis*) implanted with melengestrol acetate', *Journal of Zoo and Wildlife Medicine* 22, 130–134.
- March, P.A. & Muir III, W.W., 2003, 'Minimum alveolar concentration measures of central nervous system activation in cats anesthetized with isoflurane', *American Journal of Veterinary Research* 64, 1528–1533. <http://dx.doi.org/10.2460/ajvr.2003.64.1528>, PMID:14672432
- Miller, M., Weber, M., Neiffer, D., Mangold, B., Fontenot, D. & Stetter, M., 2003, 'Anesthetic induction of captive tigers (*Panthera tigris*) using a medetomidine-ketamine combination', *Journal of Zoo and Wildlife Medicine* 34, 307–308. <http://dx.doi.org/10.1638/02-036>, PMID:14582797
- Shilton, C.M., Thompson, M.S., Meisner, R., Lock, B. & Lindsay, W.A., 2002, 'Nasopharyngeal myxosarcoma in a Bengal tiger (*Panthera tigris*)', *Journal of Zoo and Wildlife Medicine* 33, 371–377. PMID:12564536
- Slusher, R., Bistner, S.I. & Kircher, C., 1965, 'Nutritional secondary hyperparathyroidism in a tiger', *Journal of the American Veterinary Medical Association* 147, 1109–1115. PMID:5893859
- Steinmetz, H.W., Rütten, M., Ruess-Melzer, K., Ohlerth, S., Lischer, C., Oevermann, A. et al., 2010, 'Clinical course of a malignant peripheral nerve sheath tumor in a Siberian tiger (*Panthera tigris altaica*)', *Journal of Veterinary Diagnostic Investigation* 22, 970–975. <http://dx.doi.org/10.1177/104063871002200621>
- Tranquilli, W. J., Thurmon, J. C. & Grimm, K.A., 2007, *Lumb & Jones' Veterinary anesthesia and analgesia*, 4th edn, Blackwell Publishing, Ames, Iowa.
- Valverde, A., 2008, 'Epidural analgesia and anesthesia in dogs and cats', *Veterinary Clinics of North America: Small Animal Practice* 38, 1205–1230. <http://dx.doi.org/10.1016/j.cvs.2008.06.004>, PMID:18954681