

In vitro evaluation of root canals obturated with four different techniques.

Part 3: Obturation of lateral canals

SADJ July 2012, Vol 67 no 6 p264 - p269

FS Botha¹, C van der Merwe², PJ van der Vyver³, FA de Wet⁴

INTRODUCTION

According to Schilder,^{1,2,3} the main objective of endodontic treatment procedures should be the cleaning and filling of the root canal in its entire extent, including all lateral canals and apical ramifications.

It is very difficult to instrument and to irrigate lateral canals during endodontic therapy. Tissue left in these canals may allow for bacterial growth.^{4,5,6} Barthel *et al.* showed no correlation between unfilled lateral canals and inflammation of the periodontal ligament.⁷ However, other studies demonstrated potential pathogenicity after healing of peri-radicular lesions in relation to filling of lateral canals after root canal treatment.^{8,9} It has also been speculated that lateral canals harboring inflamed and/or infected material might cause pain during endodontic treatment.¹⁰

The ability of an endodontic obturation technique to ensure obturation and sealing of thin and irregular ramifications is an important clinical parameter.¹¹ Among different techniques proposed over the years, the Schilder's technique has been shown to effectively fill lateral canals.¹² According to Wu *et al.*, the warm vertical obturation technique is capable of obturating canal irregularities and accessory canals.¹³ Brothman demonstrated that vertical compaction of warm gutta-percha approximately doubled the number of filled lateral canals compared with lateral compaction with gutta-percha.¹⁴

Research has demonstrated that when the single cone technique is used with epoxy-resin cements, accessory and lat-

eral canals can be filled predictably, provided that the canals have been debrided both mechanically and chemically.¹⁵

Carrier-based obturation techniques have the ability to seal lateral and accessory canals,¹⁶ but carry the risk of extrusion of material beyond the apical extent of the preparation.¹⁷

The objective of this *in vitro* study was to evaluate four different root canal obturation techniques in respect of the potential of these techniques to obturate lateral canals.

MATERIALS AND METHODS

Ninety-six non-carious, recently extracted human teeth were collected from various dental clinics. The teeth were prepared according to the techniques outlined in Part 1 of this series¹⁸ and were divided into four groups.

The four different groups (n= 40 canals) were obturated using four different techniques:

- **Group A:** Single Cone Technique with Gutta-percha and Hybrid Root SEAL cement (Hybrid Root SEAL technique)
- **Group B:** Single Cone Technique with Gutta-percha and EndoREZ Cement (EndoREZ technique)
- **Group C:** Continuous Wave of Obturation with Gutta-percha and Pulp Canal Sealer (System B/ Obtura technique)
- **Group D:** Thermafil Obturators with Pulp Canal Sealer (Thermafil technique)

The specimens of each obturation group were randomly subdivided into two equal groups (n=20 canals). One group was used to determine apical leakage of the root canal obturation materials (Part 2 of this series) and the second group used to assess the ability of the root canal obturation techniques to obturate lateral canals. Each group represented canals from the following teeth (n=20 canals):

- one maxillary first molar (four canals);
- three maxillary premolars (two canals each);
- one maxillary canine (one canal);
- one maxillary central incisor (one canal);
- one mandibular molar (three canals);
- three mandibular premolars (one canal each);
- one mandibular canine (one canal);
- one mandibular central incisor (one canal).

1. **FS Botha:** Phytomedicine Programme, Department of Paraclinical Sciences, Faculty of Veterinary Sciences, University of Pretoria, South Africa.

2. **C van der Merwe:** Department of Odontology, School of Dentistry, University of Pretoria, Pretoria, South Africa.

3. **PJ van der Vyver:** Department of Odontology, School of Dentistry, University of Pretoria, Pretoria, South Africa.

4. **FA de Wet:** Department of Odontology, School of Dentistry, University of Pretoria, Pretoria, South Africa.

Corresponding author

Prof PJ van der Vyver:

P.O. Box 2609, Cresta, 2118. Tel: 011 781 1020, Cell: 082 4104 293, E-mail: peetv@iafrica.com.

Table 1: Mean, Standard Deviation and Coefficient of Variance of lateral canals filled with Hybrid Root SEAL, EndoREZ, System B/ Obtura techniques and Thermafil.

	Hybrid Root SEAL	EndoREZ	System B	Thermafil
Mean	1.3333	0.7273	0.8571	1.3750
Standard deviation	0.5164	.07862	1.4639	1.0607
Coefficient of Variance	38.730	108.11	170.78	77.139

Table 2: Significance of difference between the mean value of lateral canals filled with Hybrid Root SEAL, EndoREZ, System B/ Obtura and Thermafil techniques.

	EndoREZ	System B	Thermafil
Hybrid Root SEAL	p>0,05	p>0,05	p>0,05
EndoREZ		p>0,05	p>0,05
System B			p>0,05

In order to assess the number of lateral canals that were obturated by the different techniques, all the obturated root canals were required to be subjected to a clearing technique.

Root canal -treated teeth were handled according to the technique described by Venturi *et al.*¹⁹

Teeth were immersed in the following demineralising solution:

- Seven percent formic acid, three percent hydrochloric acid and eight percent sodium citrate in aqueous solution.
- The specimens were kept under continuous agitation in a Vibromatic (Secta, Spain) and the solution changed every three days.
- After 14 days the specimens were removed from the acid and rinsed in running tap water for two hours.
- The specimens were then immersed in 99 percent acetic acid overnight, rinsed in distilled water, dehydrated in ascending concentrations of ethanol of 30, 50, 70, 90 and 96 percent (30 min passage each), and finally cleared and stored in methyl salicylate.^{19,21}

Morphological analysis was performed using a stereomicroscope (Leica Microsystems, Heerbrugg, Switzerland) fitted with a graded lens to reveal details of any obturated lateral canals. Observations were performed by two independent observers who counted the number of visible lateral canals within the coronal, middle and apical thirds of the roots. The following scores according to Venturi *et al.*,¹⁹ were used to evaluate the filling of lateral canals:

- No filling (Grade 0):** filled with cement only <10 percent of their total length.
- Partial filling with cement without gutta-percha (Grade 1):** filled with cement but not up to their full length, or not three-dimensionally, leaving empty spaces.
- Complete filling with cement with or without evidence of gutta-percha (Grade 2):** filled three-dimensionally and up to their full length by cement, without presence of gutta-percha, or with gutta-percha up to 50 percent of their total length.
- Complete filling with cement and partial filling with gutta-percha (Grade 3):** filled three-dimensionally up to their full length by cement where gutta-percha penetrated between 50 and 90 percent of their total length.
- Complete filling with cement and gutta-percha (Grade 4):** totally filled with cement and gutta-percha.

All the data were collected, tabulated and statistically analysed using the Mann-Whitney U test.

RESULTS

The presence of filled lateral canals in the coronal, midroot and apical aspects of the four groups tested are presented in Figure 1.

The means, standard deviations and coefficients of variance for the presence of filled lateral canals in the four groups tested are presented in Table 1 and the significance of differences is presented in Table 2.

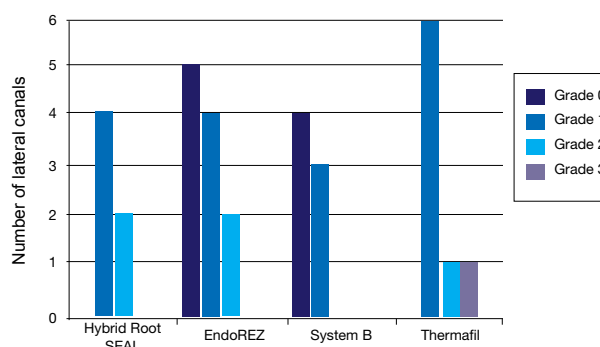


Figure 1: Number of lateral canals obturated with Hybrid Root SEAL, EndoREZ, System B/Obtura and Thermafil techniques.

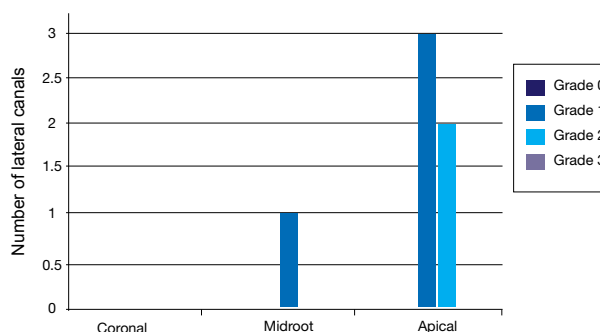


Figure 2: Number of lateral canals obturated with Hybrid Root SEAL in the coronal, midroot and apical aspects of the root canals.



Figure 3: A stereomicroscopic image (2,5X magnification) of a palatal root of an upper premolar that was obturated with gutta-percha and Hybrid Root SEAL cement. Note the presence of an apical lateral canal (Grade 1) (white arrow).

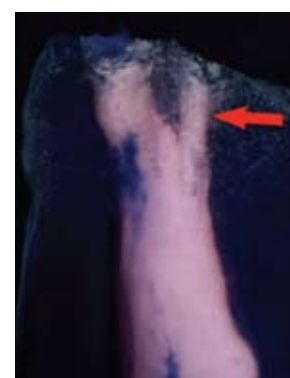

Figure 4: A stereomicroscopic image (5X magnification) of a buccal root of an upper premolar where the Hybrid Root SEAL cement obturated the entire length of the apical lateral canal (Grade 2) (red arrow).

Group A: Hybrid Root SEAL Technique (Figure 2)

Five lateral canals were observed in the apical aspects of the obturated root canals in this group. Three of these lateral canals were partially filled with cement without the presence of gutta-percha (Grade 1). Figure 3 (2,5X magnification) demonstrates a stereomicroscopic image of a palatal root

of an upper premolar that was obturated with gutta-percha and Hybrid Root SEAL technique. Note the presence of a lateral canal (white arrow) in the apical part of the root canal. Approximately 50 percent of the total length of the lateral canal is filled with Hybrid Root SEAL technique (Grade 1).

The other two lateral canals that were observed in the apical aspects of the obturated root canals in this group were completely

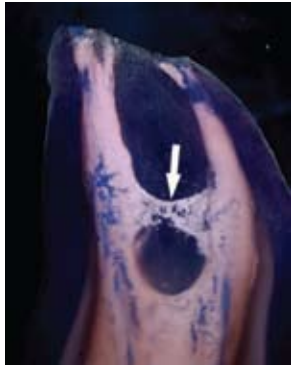


Figure 5: A stereomicroscopic image (5X magnification) of the root of an upper premolar where the root canals were obturated with Hybrid Root SEAL cement. A lateral canal (Grade 1) (white arrow) was observed in the midroot aspect.

filled three-dimensionally with cement without the presence of gutta-percha (Grade 2). Figure 4 (5X magnification) illustrates a stereomicroscopic image of a buccal root of an upper premolar where the Hybrid Root SEAL technique obturated the entire length of the lateral canal (Grade 2) (red arrow).

Only one lateral canal (Grade 1) (white arrow) was observed in the midroot aspect between the two root canals of an upper premolar of all the obturated root canals in this group (Figure 5).

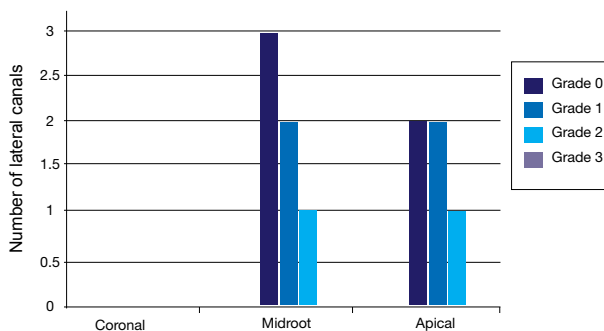


Figure 6: Number of lateral canals obturated with EndoREZ in the coronal, midroot and apical aspects of the root canals.

Group B: EndoREZ Technique (Figure 6)

In this group, five lateral canals were observed in the apical aspects of the obturated root canals. Two of the lateral canals were filled with cement, less than 10 percent of their total length (Grade 0). Another two of the lateral canals were partially filled with cement without the presence of gutta-percha (Grade 1) and only one of the lateral canals was completely three-dimensionally filled with cement without the presence of gutta-percha (Grade 2).

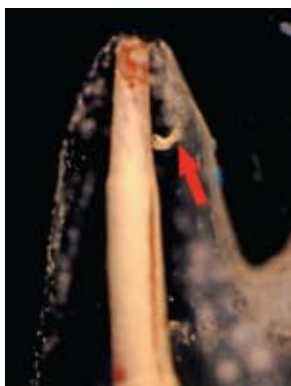


Figure 7: A stereomicroscopic image (2.5X magnification) of a palatal root of an upper premolar. Note the apical lateral canal that was completely filled with EndoREZ cement (Grade 2) (red arrow).

Figure 7 (2.5X magnification) shows a stereomicroscopic image of a palatal root of an upper premolar. The apical lateral canal (red arrow) is completely filled with EndoREZ cement (Grade 2).

Six lateral canals were observed in the midroot aspect of the obturated root canals in this group. Three of the lateral

canals were filled with cement, less than 10 percent of their total length (Grade 0) and two of the lateral canals were partially filled with cement without the presence of gutta-percha (Grade 1). One of the lateral canals was completely three-dimensionally filled with cement without the presence of gutta-percha (Grade 2).

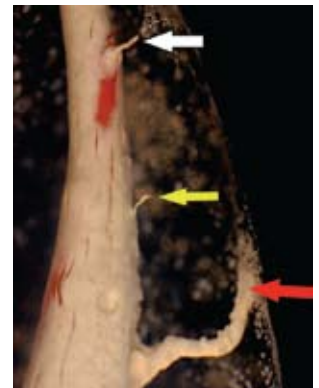


Figure 8: A stereomicroscopic image (5X magnification) of an upper canine. It is clearly visible that there was a large lateral canal (Grade 2) (red arrow), followed by a narrower lateral canal (Grade 0) (yellow arrow) in the midroot area. Also visible on this magnified view is the apical lateral canal (Grade 0) (white arrow).

Figure 8 (5X magnification) depicts stereomicroscopic images of an upper canine that was obturated with gutta-percha and EndoREZ cement. Note the presence of a large lateral canal in the midroot area, completely filled with EndoREZ cement (Grade 2) (red arrow), followed by a narrower lateral canal (yellow arrow) where the cement filled less than 10 percent of the total length of the canal (Grade 0). Also visible on this image is the apical lateral canal (yellow arrow), filled to less than 10 percent of its total length with cement (Grade 0).

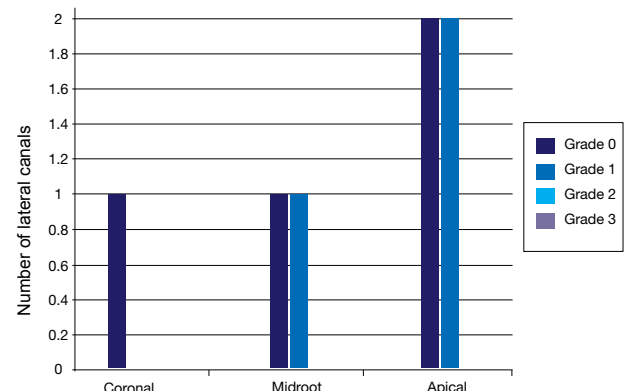


Figure 9: Number of lateral canals obturated with System B in the coronal, midroot and apical aspects of the root canals.

Group C: System B/Obtura Technique (Figure 9)

Four lateral canals were observed in the apical aspects of the obturated root canals in this group. Two of the lateral canals were filled with cement to less than 10 percent of their total length (Grade 0) and two of the lateral canals were partially filled with cement (Grade 1) without the presence of gutta-percha.

In the midroot aspects of the obturated root canals in this group two lateral canals were observed. One of the lateral canals was filled with cement to less than 10 percent of its total length (Grade 0), while the other one was partially filled with cement without the presence of gutta-percha (Grade 1).

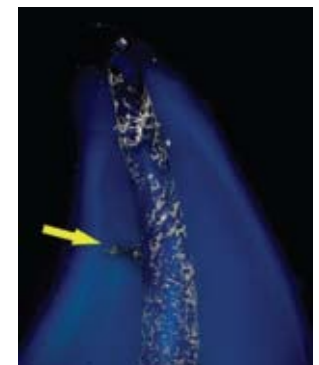


Figure 10: A stereomicroscopic image (2.5X magnification) of the root of an upper canine that was obturated with the System B/Obtura technique. Note the presence of a midroot lateral canal (yellow arrow).

Figure 10 (2.5X magnification) demonstrates a stereomicroscopic image of the root canal

Dental Warehouse

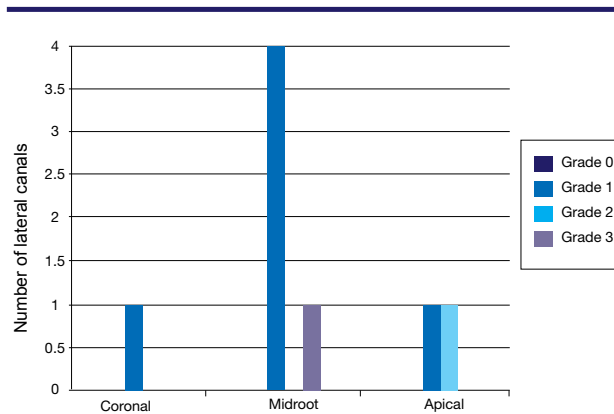


Figure 11: Number of lateral canals obturated with Thermafil in the coronal, midroot and apical aspects of the root canals.

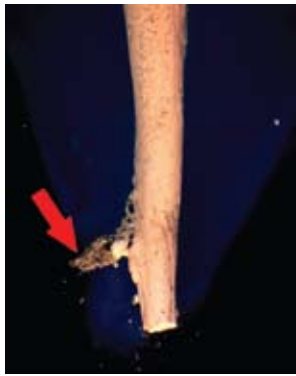

Figure 12: A stereomicroscopic image (2.5X magnification) of the root canal of a lower canine. Note the presence of an apical lateral canal that was completely filled with cement and gutta-percha to less than 50 percent of the total canal length (Grade 2) (red arrow).

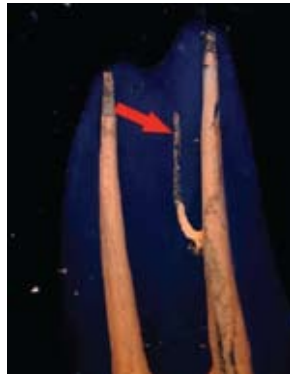

Figure 13: A stereomicroscopic image (2.5X magnification) of the buccal and palatal roots of an upper premolar that was obturated with Thermafil technique. Note the presence of a midroot lateral canal that was completely filled with cement and gutta-percha to less than 50 percent of the total canal length (Grade 2) (red arrow).

of an upper canine that was obturated with the System B/Obtura technique. Note the presence of cement in a midroot lateral canal (Grade 0) (yellow arrow).

In this group, there was also evidence of one lateral canal in the buccal root of an upper premolar that was filled with cement to less than 10 percent of the total length (Grade 0) in the coronal aspect of the obturated root canal.

Group D: Thermafil Technique (Figure 11)

In this group, two lateral canals were observed in the apical aspect of the obturated root canals. One of the lateral canals was filled with cement to less than 10 percent of its total length (Grade 1) while the other one was partially filled with cement (Figure 12) and gutta-percha to approximately 20 percent of the canal length (Grade 2) (red arrow).

Five lateral canals were observed in the midroot aspects of the obturated root canals in this group. Four of the lateral canals were partially filled with cement without the presence of gutta-percha (Grade 1) and one of the lateral canals was completely filled with cement (Figure 13) and partially filled with gutta-percha (Grade 1) (red arrow), to less than 50 percent of the total canal length.

Only one lateral canal was observed in the coronal aspects of the specimens in this group. The lateral canal was filled with cement to less than 10 percent of the total canal length (Grade 1).

The specimens that were obturated with the Thermafil tech-

nique demonstrated the greatest number of filled lateral canals. However, there were no statistically significant ($p < 0.05$) differences between the Thermafil technique and all the other obturation techniques.

DISCUSSION

The potential pathogenicity of unfilled lateral canals was demonstrated in a number of studies¹¹ due to the fact that healing of periradicular lesions occurred after lateral canals were successfully filled. It was also shown that there is no correlation between unfilled lateral canals and inflammation of the periodontal ligament.²⁰ However, a recent study indicated that when obturation materials are forced into lateral canals of vital cases, the obturation material can cause tissue damage and consequent inflammation.¹⁰

Many studies have compared different obturation techniques and their ability to fill lateral canals.^{21,22} However, to date no study could be found in the literature reporting on the incidence of lateral canals filled by Hybrid Root SEAL or EndoREZ root canal cements.

The modified tooth-clearing technique as used in this study was performed by using a weak acid solution and sodium as a buffering agent. According to Venturi *et al.*, the additional step of immersing the specimens in acetic acid improves the quality of the dentine matrix due to its capabilities of fixing organic components.¹⁹ A disadvantage of using a weak acid for this technique was that it took more time for specimen preparation. The advantage of using this technique was that a high level of transparency was achieved, clearly demonstrating the morphology of the root canal systems.

All four obturation techniques in this study caused filling of lateral canals with sealer, gutta-percha or a combination of both. The stereomicroscope that was used in this study allowed the examiners to visualise very small lateral canals in some of the specimens.

The specimens that were obturated with Thermafil demonstrated the greatest number of filled lateral canals, followed by Hybrid Root SEAL, System B and then EndoREZ. It is important to note that there was no statistically significant difference ($p < 0.05$) between the number of lateral canals filled by Thermafil compared with all the other groups.

In the Thermafil group most of the filled lateral canals were present in the midroot area. The majority of the lateral canals in this group were filled with cement to less than 10 percent of their total length (Grade 1). One of the Thermafil specimens demonstrated a lateral canal that was partially filled with gutta-percha up to 20 percent of the total canal length (Grade 2). Clark and El Deeb demonstrated that the heated gutta-percha around the plastic obturator has the potential to fill lateral and accessory canals.²² However, Pathomovich and Edmunds found that with the Thermafil technique only the sealer penetrated into accessory canals without any evidence of gutta-percha.²³

The lateral canals that were filled with Hybrid Root SEAL were either partially filled with cement without the presence of gutta-percha (Grade 1) or completely filled with ce-

ment without the presence of gutta-percha (Grade 2). In this group most of the lateral canals that were filled were present in the apical aspect of the root canals.

Specimens in the EndoREZ group demonstrated a high percentage of lateral canals that were filled with cement to less than 10 percent of the total canal length (Grade 0). The remaining canals were partially filled (Grade 1) or completely filled (Grade 2) with cement without the presence of gutta-percha. In this group there were more or less an equal number of lateral canals in the midroot and apical aspects of the root canals.

The results that were obtained from the Hybrid Root SEAL and EndoREZ groups are to be expected from these techniques since they are both single cone techniques, meaning that only the root canal cement has the potential to penetrate into the lateral canals.

In the System B group most of the lateral canals that were filled were present in the apical aspects of the root canals. Most of the lateral canals in this group were partially filled with cement without gutta-percha (Grade 1). Buchanan reported that the continuous wave of condensation can fill lateral and accessory canals.²⁴ The results of the present study indicated that most of the lateral canals were only filled with cement and not with gutta-percha.

The clinical relevance of the results of this *in vitro* study must be viewed with caution because the results cannot be extrapolated directly to the clinical scene. A selection of different teeth was used in each group of this study in order to obtain a more representative sample size. However, a major clinical variable in this study was the extent of anatomical differences that exist between the different teeth as well as the presence or absence of lateral canals. Further clinical studies are needed to determine whether these materials and obturation techniques will have an influence on the final success of endodontic therapy.

CONCLUSIONS

- Lateral canals that were filled with Hybrid Root SEAL were either partially filled with cement without the presence of gutta-percha or completely filled with cement without the presence of gutta-percha, mostly in the apical aspect of the root canals.
- EndoREZ demonstrated a high percentage of lateral canals that were filled with cement to less than 10 percent of the total canal length. There were more or less an equal number of lateral canals in the midroot and apical aspects of the root canals.
- Most of the lateral canals filled with System B were present in the apical aspects of the root canals and were partially filled with cement without gutta-percha.
- The Thermafil technique demonstrated the greatest number of filled lateral canals. However, there was no statistically significant difference between the Thermafil technique and all the other obturation techniques ($p < 0.05$).

1. Schilder H. Filling root canals in three dimensions. *Dent Clin North Am.* 1967; 11: 723–46.
2. Schilder H. Cleaning and shaping the root canal. *Dent Clin North Am.* 1974; 18: 269–96.
3. Schilder H. Canal debridement and disinfection. In: Cohen S, Burns RC, eds. *Pathways of the pulp.* 2nd ed. St Louis: CV Mosby; 1976; 111: 33–7.
4. Rubach WC, Mitchell DF. Periodontal disease, accessory canals and pulp pathosis. *J Periodontol* 1965; 36: 34 – 8.
5. Stallard RE. Periodontic-endodontic relationships. *Oral Surg Oral Med Oral Pathol.* 1972; 34: 314 –26.
6. Harrington GW. The perio-endo question: differential diagnosis. *Dent Clin North Am.* 1979; 23: 673–90.
7. Barthel CR, Zimmer S, Trope M. Relationship of radiologic and histologic signs of inflammation in human root-filled teeth. *J Endod.* 2004; 30: 75–9.
8. Seltzer S, Bender IB, Smith J, Freedman I, Nazimov H. Endodontic failures-an analysis based on clinical, roentgenographic, and histologic findings. I. *Oral Surg Oral Med Oral Pathol.* 1967; 23: 500 –16.
9. Weine FS. The enigma of the lateral canal. *Dent Clin North Am.* 1984; 28: 833–52.
10. Ricucci D, Siqueira J. Fate of the tissue in lateral canals and apical ramifications in response to pathologic conditions and treatment. *J Endod.* 2010; 36: 1-15.
11. Venturi M, Di Lenarda R, Prati C, Breschi L. An *in vitro* model to investigate filling of lateral canals. *J Endod.* 2005; 31: 887 –91.
12. Schilder H. Filling root canals in three dimensions. *Dent Clin North Am.* 1967;11: 723–44.
13. Wu MK, Kastáková A and Wesselink PR. Quality of cold and warm gutta-percha fillings in oval canals in mandibular premolars. *Int Endod J.* 2001; 34: 485-91.
14. Brothman P. A comparative study of vertical and lateral compaction of gutta-percha. *J Endod.* 1980; 7: 27–30.
15. Musikant BL (2002) Knowing the Research Makes All the Difference [www document]. URL: <http://www.endomail.com/articles/blm20knowingresearch.html>
16. Wolcott J, Himel VT, Powell W and Penney J. Effect of two obturation techniques on the filling of lateral canals and the main canal. *J Endod.* 1997; 23: 632-5.
17. Kytridou V, Gutmann JL and Nunn MH. Adaptation and sealability of two contemporary obturation techniques in the absence of the dentinal smear layer. *Int Endodon J.* 1999; 32: 464-74.
18. Van der Vyver PJ, van der Merwe C, Botha FS, de Wet FA. *In vitro* evaluation of root canals obturated with four different techniques: Part 1: Radiographic evaluation. *SADJ.* 2012; 67: 114-9.
19. Venturi M, Prati C, Capelli G, Falconi M and Breschi L. A preliminary analysis of the morphology of lateral canals after root canal filling using a tooth-clearing technique. *Int Endod J.* 2003; 36: 54-63.
20. Barthel CR, Zimmer S and Trope M. Relationship of radiologic and histologic signs of inflammation in human root-filled teeth. *J Endod.* 2004; 30: 75-9.
21. Himmel VT and Cain CW. An evaluation of the number of condenser insertions needed with warm lateral condensation of gutta-percha. *J Endodon.* 1993; 19: 79-81.
22. Clark DS and El Deeb ME. Apical sealing ability of metal versus plastic carrier Thermafil obturators. *J Endodon.* 1993; 19: 4-9.
23. Pathomovich M and Edmunds DH. The sealing ability of Thermafil obturators assessed by four different microleakage techniques. *Int Endodon J.* 1996; 29: 327-34.
24. Buchanan LS (1994) *The Art of Endodontics: Laboratory Course Manual.* Dental Education Laboratories, Santa Barbara, CA.

Declaration: No conflict of interest declared

References