

In vitro evaluation of root canals obturated with four different techniques

Part 1: Radiographic Evaluation

SADJ April 2012, Vol 67 no 3 p114 - p119

C van der Merwe¹, PJ van der Vyver², FS Botha³, FA de Wet⁴

Correspondence author

Prof PJ van der Vyver: P.O. Box 2609, Cresta, 2118. Tel: 011 781 1020, Cell: 082 4104 293, E-mail: peetv@iafrica.com

INTRODUCTION

Various endodontic materials have been advocated for obturation of the radicular space. Biologically acceptable semi-solid or solid materials are used in conjunction with root canal sealers to establish an effective fluid-tight seal of the root canal system.¹

Many techniques have also been advocated to achieve an adequate three-dimensional root canal seal. Over the years, considerable controversy has existed over competing preferences for the lateral condensation² or vertical condensation techniques.³ However, because it is physically impossible to condense purely laterally or vertically, the true difference between the two techniques depends on whether "cold compaction" or "warm compaction" is used.³

The cold lateral condensation technique is a method commonly used for root canal obturation, but there are disadvantages, the major being: (1) inability to fill canal irregularities⁴ or lateral canals;⁵ and (2) risk of root fracture due to the considerable lateral force that is exerted by the spreader.⁶

With the single cone technique, which involves cold compaction, a gutta-percha cone, preferably contoured to match the taper of the prepared root, is placed with various types of sealers.⁷

The continuous wave of obturation technique is a variation of warm vertical compaction.⁸ This process employs a heat source, the System B unit (Analytic, Technology, Redmond) and tapered stainless steel pluggers. The heat-activated plugger is used to pack the gutta-percha down the root canal, up to 3-5mm from working length. Thereafter, the canal is back-filled using the Obtura II (Spartan, Fenton, USA), a special gun that heats gutta-percha to a recommended 180°C.

The carrier based gutta-percha obturation technique was derived from an original idea of Dr. W.B. Johnson.⁹ The obturator comprises a plastic carrier covered with gutta-percha.¹⁰ The material is an alpha-phase gutta-percha with a fusion heat of 56° C.¹¹ The pre-selected obturator is heated in a ThermaPrep Plus Oven (Dentsply-Tulsa Dental, Tulsa, OK, USA) and slowly introduced into the canal until it reaches its final position.

The objective of this *in vitro* study was to evaluate four different root canal obturation techniques in respect of the quality of root canal obturation as revealed radiographically.

MATERIALS AND METHODS

Non-carious, human teeth recently extracted for periodontal or orthodontic reasons were collected from various dental clinics. Ethical and safety guidelines for the handling of human teeth and laboratory research were strictly followed. All collected teeth were examined by visual inspection under 3.5X magnification using a Dental Operating Microscope (MC-M3101, DF Vasconcellos, Brasil, Av Indianopolis, Sao Paulo, Brazil) and any that showed evidence of resorption, fractures or open apices (larger than 0.3mm were discarded). Only those with roots having narrow canals with no sharp curves were included in this study. Ninety-six teeth were selected.

Access cavities were prepared using a Ti-Max Ti95L 1:5 friction-grip handpiece (NSK, Nakanishi Inc., Kanuma, Japan), with size 023 round diamond burs (Dentsply/Maillefer Instruments, Baillagues, Switzerland). The finishing of the access cavities was done with size 023 round steel burs (Dentsply/Maillefer Instruments - SA, Baillagues, Switzerland) and a Ti-Max Ti25L 1:1 contra-angle handpiece (NSK, Nakanishi Inc., Kanuma, Japan).

All the root canals were prepared by one operator under 3.5X to 16X magnification (MC-M3101, DF Vasconcellos).

Working length was determined by passing a 08 K-file (Dentsply Maillefer) carefully along the canal, until the tip of the file was visible at the apical foramen. This length was recorded and 1mm subtracted to provide the operator with a working length for each root canal. Apical patency was established by using C+ Files (Dentsply/Maillefer) size 08, 10 and 15, with a reciprocating handpiece (NSK TiMax Ti35L 10:1) operating at 40 000 RPM using constant distilled water irrigation. A glide path was established with a 20K file (Dentsply / Maillefer) to working length.

Root canal preparation was done using RaCe nickel titanium rotary files (FKG Dentaire, La Chaux-de-Fonds, Switzerland) mounted in a 16:1 gear reduction handpiece driven by an

electric motor (Micro-Mega, Besancon, France), under constant irrigation with TopClear Solution (Dental Discounts CC, Paulshof, Sandton, South Africa), which is a mixture of 0.2 percent cetremide and 17 percent EDTA. The TopClear Solution was alternated with Chlor-XTRA (Vista Dental Products, 2200 Northwestern Avenue, Racine, WI, USA), a six percent sodium hypochlorite solution (NaOCl). The files were used according to manufacturer's instructions by opening canal orifices to size 40 (10 percent taper) and the apical region of each canal was prepared to a size 30 (six percent taper).

Finally, the dentinal smear layer was removed from all prepared root canals by leaving TopClear Solution (Dental Discounts CC), in the prepared root canals for two minutes before rinsing for five minutes with Chlor-XTRA (Vista Dental). The irrigation solutions were delivered in a disposable syringe with a Navitip needle (Ultradent Products Inc.).

The prepared teeth were randomly and equally divided into four groups (n = 40 canals). Each group contained prepared root canals of the following teeth:

- two maxillary first molars (four canals each);
- six maxillary premolars (two canals each);
- two maxillary canines (one canal each);
- two maxillary central incisors (one canal each);
- two mandibular molars (three canals each);
- six mandibular premolars (one canal each);
- two mandibular canines (one canal each); and
- two mandibular central incisors (one canal each).

In two of the groups that were to be obturated with resin-based sealers, the canals were finally rinsed with TopClear Solution (Dental Discounts CC) for 30 seconds because oxygen-generating solutions, like NaOCl, can inhibit the setting process of some resin cements.

All canals were dried by using several six percent tapered Paper Points (Dentsply/Maillefer) and the four groups were obturated using the following techniques:

- **Group A:** single cone technique with gutta-percha and Hybrid Root SEAL cement (Hybrid Root SEAL technique)

A single gutta-percha point with a taper of six percent (Dentsply Maillefer) was used as a master cone, in conjunction with Hybrid Root SEAL root canal cement (J. Morita, Europe GmbH, Dietzenbach, Germany). The cement was applied to the entire length of the canals using a lentulo spiral, the master cone placed, seared off with System B (Analytic Technology, Redmond, Washington, USA) at the coronal orifice and compacted with a Schilder plugger (Dentsply/Maillefer).

- **Group B:** single cone technique with gutta-percha and EndoREZ Cement (EndoREZ technique)

A single EndoREZ gutta-percha point (Ultradent Inc.) with a taper of six percent was used as a master cone, in conjunction with EndoREZ root canal sealer/filler (Ultradent Products Inc.). By using the TwoSpense syringe (Ultradent Products Inc.) with the Ultra-Mixer tip (Ultradent Products Inc.), the Skini syringe (Ultradent Products Inc.) was filled with the mixed base and catalyst. A Navitip (Ultradent Products Inc.) was fitted to the Skini syringe and

inserted into the canal to within 2-3mm short of working length. The Navitip was withdrawn slowly while sealer was delivered to the canal until the canal orifice was reached. The master cone was subsequently placed and seated to working length. A size 25 accessory cone was dipped in EndoREZ Accelerator (Ultradent Products Inc.) and inserted next to the master cone into the canal as far as possible. The cones were seared off with System B (Analytic Richmond, Washington, USA) and compacted with a Schilder plugger (Dentsply/Maillefer).

- **Group C:** continuous wave of obturation with gutta-percha and Pulp Canal Sealer (System B/Obtura technique)

A single gutta-percha point with a taper of six percent (Dentsply Maillefer) was used as a master cone, Pulp Canal Sealer (Kerr Co., Romulus, Michigan, USA) as root canal cement and System B Heat Source (Analytic Technology, Redmond, Washington, USA) to perform the continuous wave of condensation. Canals were back-filled with gutta-percha heated to 180°C in the Obtura II unit (Obtura Corporation, Fenton, Missouri, USA).

The master cone was cut back to 0.5mm short of working length to ensure that the cone would bind to the canal wall in its terminal 1mm. The continuous wave electric heat plugger was selected with a taper matching the master cone taper. The plugger was inserted into the canal and it was confirmed that the binding point was within 4mm of the working length. The stop was then adjusted to that reference point.

The master cone was buttered with Pulp Canal Sealer and slowly placed in the prepared root canal. The System B Heat Source (Analytic Technology, Redmond) set on 180°C, was used to sear off the master cone at the orifice with the tip of the continuous wave plugger. The softened gutta-percha was then compacted with a Schilder plugger (Dentsply/Maillefer). The cold continuous wave plugger was placed against the gutta-percha, the System B handpiece switch activated and the plugger gently pushed downwards until it was 3-4mm shy of its binding point. With the switch released, apical pressure was maintained firmly on the plugger for 10 seconds. The handpiece switch was then activated for one second, the continuous wave plugger rotated and retracted to remove the coronal excess of gutta-percha. The apical gutta-percha seal was compacted with a small Schilder plugger (Dentsply/Maillefer) to create a flat surface that would avoid the formation of a void when backfilling. With the downpack completed, the Obtura II Gun and needle (Obtura Corporation) were allowed to heat to 180°C. A 23-gauge needle was inserted into the canal until it touched the apical seal. A waiting period of five seconds was observed before pulling the trigger of the Obtura II Gun (Obtura Corporation,) to inject the heated gutta-percha into the backfill space. The gutta-percha was compacted at the canal orifices with a Schilder plugger (Dentsply/Maillefer).

- **Group D:** Thermafil obturators with Pulp Canal Sealer (Thermafil technique)

The canals were verified with size 30 nickel titanium verifier (Dentsply/Maillefer). Pulp canal sealer (Kerr Co.) was placed in the canals, adapting it to the walls and eliminating the excess with a paper point. Size 30 Ther-

Table 1: Mean, standard deviation and coefficient of variance of the radiographic evaluation of Hybrid Root SEAL, EndoREZ, System B/ Obtura and Thermafil techniques in the coronal aspects of the root canals.

	Hybrid Root SEAL	EndoREZ	System B	Thermafil
Mean	1.4000	1.2500	1.0500	1.1000
Standard deviation	0.6806	0.4443	0.2236	0.3078
Coefficient of variance	48.611	35.541	21.296	27.981

Table 2: Significance of difference between the mean values (Table 1) of the radiographic evaluation of Hybrid Root Seal, EndoREZ, System B/Obtura and Thermafil techniques in the coronal aspects of the root canals.

	EndoREZ	System B	Thermafil
Hybrid Root SEAL	p>0,05	p<0,05	p>0,05
EndoREZ		p>0,05	p>0,05
System B			p>0,05

Table 3: Mean, standard deviation and coefficient of variance of the radiographic evaluation of Hybrid Root Seal, EndoREZ, System B/ Obtura and Thermafil techniques in the apical aspects of the root canals.

	Hybrid Root SEAL	EndoREZ	System B	Thermafil
Mean	1.4500	1.0000	1.0500	1.0000
Standard deviation	0.6863	0.0000	0.2236	0.0000
Coefficient of variance	47.333	0.0000	21.296	0.0000

Table 4: Significance of difference between the mean values (Table 3) of the radiographic evaluation of Hybrid Root SEAL, EndoREZ, System B/Obtura and Thermafil techniques in the apical aspects of the root canals.

	EndoREZ	System B	Thermafil
Hybrid Root SEAL	p<0,05	p<0,05	p<0,05
EndoREZ		p>0,05	p>0,05
System B			p>0,05

mafil obturators (Dentsply/Maillefer) were heated in the ThermaPrep Plus oven (Dentsply/Maillefer). The heated obturators were introduced into the canals, using small clockwise/counter-clockwise movements until they reached their final positions. While light pressure was kept on the obturators, the coronal soft gutta-percha was compacted with a Schilder plugger (Dentsply/Maillefer). After 8-10 seconds the obturators were sectioned with a Thermancut bur (Dentsply/Maillefer) using light pressure.

After root canal obturation, all the access openings were cleaned with 90% alcohol and sealed with Miracle Mix (GC Corporation, Hasunuma-Cho, Itabashi-Ku, Tokyo, Japan). Specimens were stored at 37°C at 100 percent humidity for 48 hours to ensure complete setting of the root canal cements.

Digital radiographs were taken of each obturated tooth from bucco-lingual and mesio-distal directions to assess the quality of the root canal obturation, using a Trophy RVG sensor (Trophy Radiologie S.A., Croissy-Beaubourg, France).

The quality of obturation was determined separately for the coronal and apical halves of each canal and was rated and scored according to the following radiographic appearances:¹²

1. Well-condensed root canal filling material that obturated the entire prepared canal, well adapted to the root canal wall with only a few minor areas of relative radiolucency (less than 0.25mm in diameter) scored 1;
2. Imperfectly-condensed root filling material with irregularities of less than 1mm in diameter scored 2;
3. Inadequately-condensed root canal filling material with irregularities of less than 2mm diameter scored 3;
4. Poorly-condensed root canal filling material with irregularities of more than 2mm diameter scored 4;

All the data was collected, tabulated and statistically analysed using the Mann-Whitney U test.

RESULTS

The results of the radiographic evaluation of the coronal parts are summarised in Figure 1 and the results of the radiographic evaluation of the apical parts are summarised in Figure 2 for the four different groups tested. The means,

standard deviations and coefficients of variance of these data are presented in Tables 1 to 4.

Group A: Hybrid Root SEAL technique

In the coronal aspects of the root canals in this group, most of the specimens demonstrated well-condensed root fillings with no areas of radiolucency (Score 1) (Figure 1).

However, four obturated root canals in this group showed imperfectly condensed root fillings in the coronal aspect, with irregularities of less than 1mm in diameter (Score 2). Two canals presented with inadequately-condensed root canal fillings, with irregularities of less than 2mm (Score 3) (Figure 1).

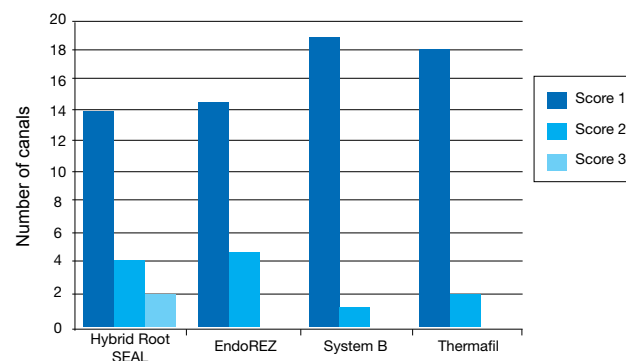


Figure 1: Radiographic evaluation of Hybrid Root SEAL, EndoREZ, System B/Obtura and Thermafil techniques in the coronal aspects of the root canals.

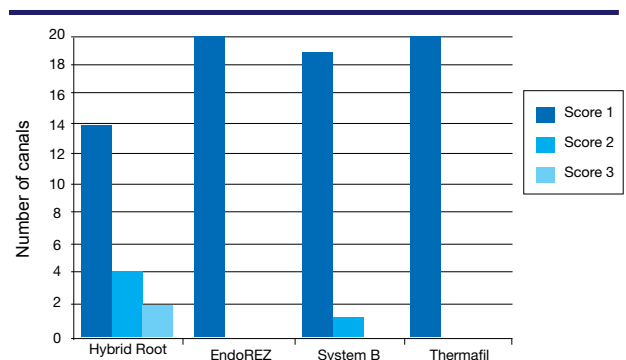


Figure 2: Radiographic evaluation of Hybrid Root SEAL, EndoREZ, System B/Obtura and Thermafil techniques in the apical aspects of the root canals.

The same specimens also demonstrated inadequately condensed root canal fillings in the apical parts of these root canals (Figure 2).

Figure 3 shows a Hybrid Root SEAL technique specimen (upper premolar) that illustrated irregularities of less than 1mm (Score 2) in the coronal aspect of the buccal canal (arrow right) and in the apical aspect of the palatal canal (arrow left).

The specimens that were obturated with Hybrid Root SEAL technique demonstrated a statistically-significant ($p < 0.05$) higher number of radiographic obturation defects in the coronal aspect of the root canals compared with the result achieved using System B/Obtura and Thermafil techniques. There was no significant difference between the means of the data of the Hybrid Root SEAL and EndoREZ techniques ($p > 0.05$).

In the apical aspect there was also a higher number of radiographic obturation defects between the root canal fillings of Hybrid Root SEAL technique compared with all the other techniques (statistically significant at $p < 0.05$).

Group B: EndoREZ technique

Most of the canals in this group demonstrated well-condensed root fillings with no areas of radiolucency (Score 1) in the coronal aspects of the canals. Five of the canals in this group, however, showed imperfectly-condensed root fillings in this region of the root canals (Score 2) (Figure 1).

Figure 4 depicts an EndoREZ technique specimen (upper premolar) that illustrated irregularities of less than 1mm (Score 2) in the coronal aspects of the buccal and palatal canals (arrow).

All the root canals demonstrated well-condensed root fillings in the apical regions (Score 1) (Figure 4).

Group C: System B/Obtura technique

Most of the canals in this group demonstrated well-condensed root fillings with no areas of radiolucency (Score 1) in the coronal as well as the apical aspects of the root canals (Figure 1).

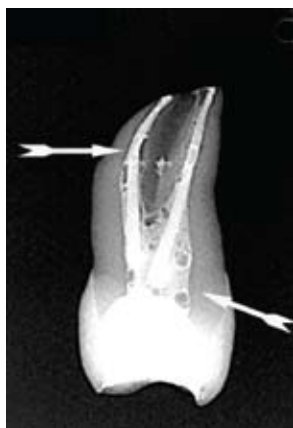

Figure 3: A Hybrid Root SEAL technique specimen (upper premolar) that illustrated irregularities of less than 1mm (Score 2) in the coronal aspect of the buccal canal (arrow right) and the apical aspect (arrow left) of the palatal canal.

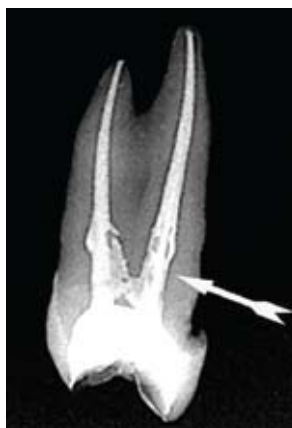

Figure 4: An EndoREZ technique specimen (upper premolar) that illustrates irregularities of less than 1mm (Score 2) in the coronal aspects (arrow) of the buccal and palatal canals. In the apical parts of the canals there were no irregularities and the material was well condensed.

There was evidence of only one imperfect root filling (Score 2) in the coronal aspect of a lower canine (arrow), and one in the apical aspect of a buccal canal of an upper premolar (arrow) (Figure 5), amongst all the other root canals in this group.

The specimens that were obturated using System B/Obtura technique demonstrated the lowest number of radiographic obturation defects in the coronal aspects of the root canals compared with all the other techniques. However, there was only a statistically significant difference between the means of the data of System B/Obtura and Hybrid Root SEAL techniques ($p < 0.05$).

Group D: Thermafil technique

All the root canals in this group showed well-condensed root fillings in the apical aspects (Figure 2) of the obturated root canals. An example of a Thermafil technique specimen (lower first molar) that was well condensed with no areas of radiolucency in the mesial and distal root canals (Score 1) is depicted in Figure 6.

Whilst nearly all the canals in this group demonstrated well-condensed root fillings with no areas of radiolucency (Score 1) in the coronal aspects of the root canals, two specimens did demonstrate imperfections in this area (Figure 7).

The specimens that were obturated with Thermafil and EndoREZ techniques demonstrated the lowest number of radiographic obturation defects in the apical aspects of the root canals compared with all the other groups. However, there was only a statistically significant difference between the means of the data of these two techniques and that of the Hybrid Root SEAL technique ($p < 0.05$).

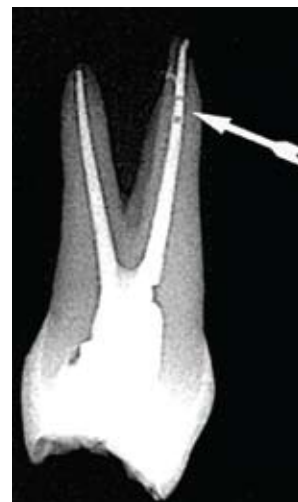

Figure 5: System B/Obtura technique specimen with an imperfect root filling (Score 2) in the apical aspect (arrow) of the buccal canal of a maxillary premolar.

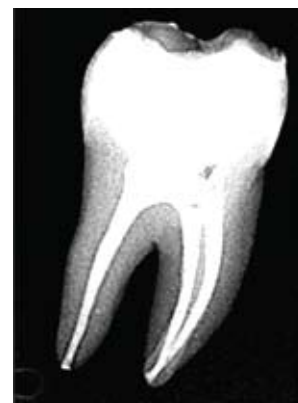

Figure 6: An example of a Thermafil technique specimen (lower first molar) that was well condensed with no areas of radiolucency in the mesial and distal root canals (Score 1).

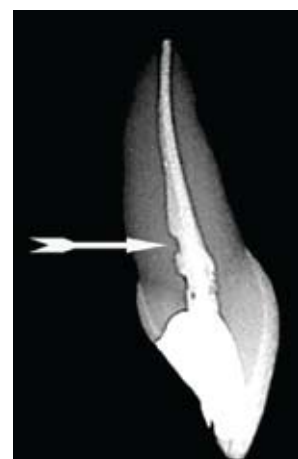

Figure 7: A Thermafil technique specimen (upper central) that illustrates irregularities of less than 1mm (Score 2) in the coronal aspect (arrow) of the root canal. No irregularities were evident in the apical aspect of the root canal (Score 1).

DISCUSSION

The objective of this *in vitro* study was to evaluate four different root canal obturation techniques in respect of the quality of root canal obturation as revealed radiographically. The importance of radiographic criteria and their consistent application cannot be over-emphasised in the evaluation of root canal treatment.¹³ Radiographically there should be the appearance of a dense, three-dimensional filling, which extends as close as possible to the cemento-dental junction, according to the clinical criteria published in the Quality Assurance Guidelines by the American Association of Endodontics.¹⁴

In the radiographic evaluation of the obturation quality in the present study, Hybrid Root SEAL produced the poorest results, coronally and apically. Many voids were observed in the obturations and these irregularities are most probably directly related to the difficulty of placement of Hybrid Root SEAL in the prepared canals. This is contrary to the findings made by Beli *et al.*¹⁵

In the coronal aspects of the root canals, System B group gave the best results. This can be explained as being due to the fact that backfilling of the root canals was done with Obtura II thermoplasticised injectable technique after the initial downpack was completed with System B. The gutta-percha delivered by the Obtura II unit resulted in a solid mass that was well adapted to canal walls. This finding is in agreement with research done by Weller *et al.*¹⁶ wherein the efficacies of Thermafil obturators, Obtura II thermoplasticised injectable technique and the lateral condensation technique in obturating a standard root canal were compared. In that study, the Obtura II thermoplasticised injectable technique demonstrated the best adaptation to the prepared root canal, followed by Thermafil and finally by the lateral condensation technique.¹⁵ In the present study Thermafil also produced the second-best results concerning adaptation in the coronal aspects of the root canals.

The EndoREZ and Thermafil groups resulted in the best obturation quality in the apical aspects of the root canals. In a clinical follow-up study, Zmener and Pameijer¹⁷ showed that 92 out of 120 teeth obturated with EndoREZ were rated to have remained adequately filled five years later.

The excellent obturation quality obtained by the Thermafil specimens in the apical aspects of the root canals can be attributed to the fact that the plastic core of the obturator compressed the alpha-phase gutta-percha and cement into a homogeneous mass. Characteristics of alpha-phase gutta-percha also include elevated radiopacity and excellent viscosity and flow⁹ that could have contributed to the results obtained in the present study.

Analysis of the radiographic evaluation of the obturation quality of the coronal aspects in the present study demonstrated a statistically significant difference between the means of the data of System B and Hybrid Root SEAL ($p < 0.05$). In the apical aspects there was a statistically significant difference ($p < 0.05$) between the data with reference to Hybrid Root SEAL and that from all the other groups.

CONCLUSIONS

- The Hybrid Root SEAL technique demonstrated a statistically-significant higher number of radiographically

defined defects in the filled coronal aspects of the root canals when compared with those seen with the System B/Obtura and Thermafil techniques ($p < 0.05$).

- There was no statistically significant difference between the radiographically defined defects in the coronal aspects of the obturated root canals between the Hybrid Root SEAL and EndoREZ techniques ($p > 0.05$).
- The Hybrid Root SEAL technique demonstrated a statistically higher number of radiographically defined defects in the apical aspects of the root canals compared with all the other obturation techniques (significant at $p < 0.05$).

Author information

1. **C van der Merwe:** Department of Odontology, School of Dentistry, University of Pretoria, Pretoria, South Africa.
2. **PJ van der Vyver:** Department of Odontology, School of Dentistry, University of Pretoria, Pretoria, South Africa.
3. **FS Botha:** Phytomedicine Programme, Department of Para-clinical Sciences, Faculty of Veterinary Sciences, University of Pretoria, South Africa.
4. **FA de Wet:** Department of Odontology, School of Dentistry, University of Pretoria, Pretoria, South Africa.

Declaration: No conflict of interest declared

References

1. Musikant BL (2002) Knowing the Research Makes All the Difference [www document]. URL: <http://www.endomail.com/articles/blm20/knownresearch/html>.
2. Frank AL, Simon JHS, Abou-Rass M, Glick DH (1983). Clinical and Surgical Endodontics: Concepts in Practice. JB Lippincott, Philadelphia.
3. Schilder H (1978). Advanced course in Endodontics. Boston University, School of Graduate Dentistry, Boston, MA.
4. Collins J, Walker MP, Kullid J, Lee C. A comparison of three gutta-percha obturation techniques to replicate canal irregularities. J Endod 2006; (32): 762-5.
5. Reader CM, Himel VT, Germain LP, Hoen MM. Effect of three obturation techniques on the filling of lateral canals and the main canal. J Endod 1993; (19): 404-8.
6. Gimlin DR, Parr CH, Aguirre-Ramirez G. A comparison of stresses produced during lateral and vertical condensation using engineering models. J Endod 1986; (12): 235-41.
7. Gordon MP, Love RM, Chandler NP. An evaluation of .06 tapered gutta-percha cones for filling of .06 taper prepared curved root canals. Int Endod J 2005; (38): 87-96.
8. Buchanan LS. Continuous wave of condensation technique. Endod Prac 1998; (1): 7-10.
9. Johnson WB. A new gutta-percha technique. J Endod 1978; (4): 184-8.
10. Cantatore G. Thermafil versus SystemB. Endodontic Practice 2001; (4): 30-9.
11. Malagnino V, Cantatore G, Lupol I. Analyse chimique quantitative. Point de fusion and temps de plasticization des differentes branches de gutta-percha. Rev Fr Endod 1994; (6): 136-40.
12. Kersten HW, Fransman R and Thoden van Velzen SK. Thermo-mechanical compaction of gutta-percha I. A comparison of several compaction procedures. Int Endod J 1986; (19): 125-33.
13. Gutmann JL, Saunders WP, Saunders EM, Nguyen L. An assessment of the plastic Thermafil obturation technique: Part 1 – Radiographic evaluation of adaptation and placement. Int Endod J 1993; 26: 173-8.
14. Quality Assurance Guidelines (1987) Chicago: American Association of Endodontics, 1-27.
15. Belli S, Ozcan E, Derinbay O, Eldeniz Au. A comparative evaluation of sealing ability of a new, self-etching, dual-curable sealer: Hybrid Root SEAL (MetaSEAL). Oral Surg Oral Med Oral Pathol Oral Radiol Endod 2008; (106): 45-52.
16. Weller RN, Kimbrough WF, Anderson RW. A comparison of thermoplastic obturation techniques: adaptation to the canal walls. J Endod 1977; (23): 703-6.
17. Zmener O, Pameijer CH. Clinical and radiographic evaluation of a resin-based root canal sealer. Am J Dent 2004; (17): 19-22.