

Comparative biomechanics of two non-invasive mandibular fracture repair techniques in dogs

By

Adriaan Mynhardt Kitshoff BVSc (Hons.)

**Section Small Animal Surgery
Department of Companion Animal Clinical Studies
Faculty of Veterinary Science
Onderstepoort
University of Pretoria
South Africa**

Thesis submitted to the Faculty of Veterinary Science, University of Pretoria in partial
fulfillment of the requirements for the degree of

MASTER OF SCIENCE

in

Veterinary Science

Dr. G Steenkamp (Promoter)

Maxillofacial Surgery and Dentistry Clinic, Section Small Animal Surgery, Department Companion
Animal Clinical Studies, Faculty of Veterinary Science, University of Pretoria, Private Bag x04,
Onderstepoort, South Africa, 0110

Email: gerhard.steenkamp@up.ac.za

1 ACKNOWLEDGEMENTS

My warmest gratitude goes to Dr. G Steenkamp for his constant enthusiasm, kind words, inspiration and motivation. Thank you for all your input during the study design, writing of the thesis and articles. Without your help this project would not have been possible.

To Prof. Dr. H de Rooster, my clinical supervisor and mentor. You have been a constant source of inspiration to me. Your professional advise and constructive critique in writing the thesis and articles have been invaluable.

To Dr. S Ferreira. I am greatly appreciative for your patience, time and constant explanations.

To Prof. D Burger. Thank you for all your support and advice during the project design.

To my wife Liani and my parents, I am eternally grateful for everything that you mean to me each day. Thanks you for taking this journey with me. Without your constant motivation and selfless support this would not have been possible.

2 DECLARATION

I, Adriaan M. Kitshoff, hereby declare that the research presented in this dissertation, was conceived and executed by myself, under guidance from my supervisor.

Neither the substance, nor any part of the dissertation has been submitted in the past, or is to be submitted for a degree at the University of Pretoria or any other University.

This dissertation is presented as partial fulfilment of the requirements for the degree Master of Science in Veterinary Science.

Signature:  _____

Adriaan M. Kitshoff

Date: 22 November 2012

TABLE OF CONTENTS

1	AKNOWLEDGEMENTS.....	II
2	DECLARATION	III
3	LIST OF FIGURES.....	6
4	LIST OF TABLES.....	9
5	LIST OF SYMBOLS AND ABBREVIATIONS.....	10
6	LITERATURE REVIEW	11
6.1	BONE AND FRACTURE PATHOLOGY	11
6.2	BONE HEALING	12
6.3	FORCES ACTING ON THE MANDIBLE	14
6.4	BIOMECHANICAL TESTING.....	15
6.5	COLLECTING AND STORAGE OF BONE SPECIMENS FOR BIOMECHANICAL TESTING	20
6.6	ANATOMICAL CONSIDERATIONS	21
6.7	AETIOLOGY, SIGNALMENT AND CLASSIFICATION OF MANDIBULAR FRACTURES.....	24
6.8	MANDIBULAR FRACTURE REPAIR TECHNIQUES.....	26
7	INTRODUCTION.....	30
7.1	AIMS OF THE STUDY	31
7.2	HYPOTHESIS	31
8	MATERIALS AND METHODS.....	32
8.1	RETROSPECTIVE STUDY ON MANDIBULAR FRACTURES.....	32
8.2	THE COMPARATIVE BIOMECHANICS OF THE REINFORCED INTERDENTAL CROSSOVER AND THE STOUT LOOP COMPOSITE SPLINTS FOR MANDIBULAR FRACTURE REPAIR IN DOGS ..	34
8.2.1	<i>Specimen collection and storage.....</i>	<i>34</i>
8.2.2	<i>Specimen preparation</i>	<i>35</i>
8.2.2.1	Reinforced interdental composite splint (RIC).....	37
8.2.2.2	Reinforced interdental Stout loop composite splint (RIS).....	39
8.2.3	<i>Biomechanical testing</i>	<i>40</i>
8.3	STATISTICAL ANALYSIS.....	44
9	RESULTS.....	45
9.1	RETROSPECTIVE STUDY OF MANDIBULAR FRACTURES	45
9.2	REINFORCED INTERDENTAL CROSSOVER COMPOSITE SPLINT AS A NON-INVASIVE MANDIBULAR FRACTURE REPAIR TECHNIQUE	49

9.3	COMPARATIVE BIOMECHANICAL STUDY	50
10	DISCUSSION	53
11	CONCLUSION.....	61
12	ADDENDUM.....	62
12.1	ADDENDUM 1: PERMISSION FOR EUTHANASIA, STUDY AND RESEARCH PURPOSES	62
12.1.1	<i>Patient 1</i>	62
12.1.2	<i>Patient 2</i>	63
12.1.3	<i>Patient 3</i>	64
12.1.4	<i>Patient 4</i>	65
12.1.5	<i>Patient 5</i>	66
12.1.6	<i>Patient 6</i>	67
12.2	ADDENDUM 2: MANDIBULAR RADIOGRAPHS.....	68
12.2.1	<i>Patient 1</i>	68
12.2.2	<i>Patient 2</i>	68
12.2.3	<i>Patient 3</i>	69
12.2.4	<i>Patient 4</i>	69
12.2.5	<i>Patient 5</i>	70
12.2.6	<i>Patient 6</i>	70
12.3	ADDENDUM 3: FORCE-DISPLACEMENT CURVES.....	71
12.3.1	<i>Patient 1</i>	71
12.3.2	<i>Patient 2</i>	72
12.3.3	<i>Patient 3</i>	73
12.3.4	<i>Patient 4</i>	74
12.3.5	<i>Patient 5</i>	75
12.3.6	<i>Patient 6</i>	76
13	SUMMARY	77
14	PAPERS PUBLISHED FROM THIS DISSERTATION	78
15	REFERENCES.....	79

3 LIST OF FIGURES

FIGURE 6-1: SCHEMATIC ILLUSTRATING A 4-POINT BENDING TEST WHERE TWO PAIRED FORCES ARE APPLIED IN OPPOSITE DIRECTIONS. 15

FIGURE 6-2: SCHEMATIC ILLUSTRATING THE 3-POINT BENDING TEST WHERE ONE UNPAIRED FORCE AND ONE PAIRED FORCE IS APPLIED IN OPPOSITE DIRECTIONS. 16

FIGURE 6-3: SCHEMATIC ILLUSTRATING A CANTILEVER BENDING TEST. THE SPECIMEN IS FIXED TO THE ONE END (ASTERISK) AND A LOAD AT THE OPPOSITE END. 16

FIGURE 6-4: TYPICAL LOAD-DEFORMATION CURVE DURING CANTILEVER BENDING 17

FIGURE 6-5: CAUDOROSTRAL VIEW OF THE ROSTRAL PART OF THE MANDIBLE AFTER OSTEOTOMY BETWEEN THE FIRST MOLAR AND FOURTH PREMOLAR. THE MANDIBULAR CANAL (DASHED CIRCLE), THE CAUDAL TOOTH ROOT OF THE FOURTH MANDIBULAR PREMOLAR (BLUE ARROWS) AND THE MANDIBULAR ARTERY (BLACK ARROW) ARE VISIBLE..... 22

FIGURE 6-6: REPRESENTATION OF A CANINE MANDIBLE INDICATING THE COURSE OF THE INFERIOR ALVEOLAR NERVE (YELLOW) AND THE MANDIBULAR ALVEOLAR ARTERY (RED) IN THE MANDIBULAR CANAL. 23

FIGURE 8-1: LATERAL RADIOGRAPH DEPICTING THE ANATOMICAL ZONES. 1. INCISIVE REGION, 2. CANINE REGION, 3. PREMOLAR REGION, 4. MOLAR REGION, 5. RAMUS REGION, 6. CONDYLAR REGION. 32

FIGURE 8-2 A,B: SPECIALLY DESIGNED MOULD VIEWED FROM THE SIDE (A) AND FROM THE TOP (B) THE CONDYLAR , THE CORONOID AND THE ANGULAR PROCESSES OF THE MANDIBLE WILL BE MOULDED INTO A POLYMETHYL METHACRYLATE BLOCK AFTER POSITIONING IT IN THE CRYPT BETWEEN THE TWO VERTICAL UPRIGHTS (BLACK ARROW). 35

FIGURE 8-3 A,B: THE CAUDAL SEGMENT OF THE MANDIBLE WAS FIXED IN A POLYMETHYL METHACRYLATE BLOCK (*) AND POSITIONED IN A METAL JIG. THE POSITION OF THE MANDIBLE IN THE POLYMETHYL METHACRYLATE WAS SUCH THAT THE TEETH FORMED A 90-DEGREE ANGLE WITH THE HORIZONTAL PLANE (A) AND 15 DEGREES TOWARDS THE MEDIAL PLANE (B). NOTE THAT IN BOTH PHOTOGRAPHS THE TEETH ARE COVERED IN 37% PHOSPHORIC ACID (BLUE COLOUR). THE BLACK ARROW INDICATES THE LOCATION AND DIRECTION WERE THE FORCE WAS APPLIED DURING TESTING. 36

FIGURE 8-4: PREPARED AND FIXED MANDIBLE SHOWING THE AREAS WHERE THE COMPOMER HAS BEEN APPLIED TO CREATE SMALL “BUTTONS” TO PREVENT THE WIRE FROM

SLIPPING IN A DORSAL DIRECTION. NOTE THAT INITIALLY THE OSTEOTOMY WAS ONLY MADE THROUGH THE DORSAL TWO THIRDS OF THE MANDIBULAR BODY. ... 38

FIGURE 8-5: REINFORCED INTERDENTAL CROSSOVER TECHNIQUE BEFORE THE APPLICATION OF THE BIS-ACRYLIC COMPOSITE. NOTE THE SMALL “BUTTONS” OF COMPOMER JUST DORSAL TO THE INTERDENTAL WIRE (BLACK ARROWS). THE OSTEOTOMY (WHITE ARROW) HAS NOT BEEN COMPLETED YET..... 38

FIGURE 8-6: INTERDENTAL STOUT LOOP WIRE PATTERN BEFORE THE APPLICATION OF THE BIS-ACRYLIC COMPOSITE. THE OSTEOTOMY (WHITE ARROW) HAS NOT BEEN COMPLETED YET. NOTE THE FROSTED WHITE APPEARANCE OF THE TEETH POST ACID ETCHING..... 39

FIGURE 8-7: A CUSTOM MADE JIG THAT WILL BE USED TO SECURE THE PMMA BLOCKS OF THE IMBEDDED MANDIBLE TO THE SINGLE COLUMN TESTING MACHINE VIEWED FROM THE SIDE (A) AND FROM THE FRONT (B). THE PMMA BLOCK IS INSERTED INTO THE SQUARE TUBING AND FIXED LIGHTLY WITH THE TWO BOLTS. 40

FIGURE 8-8: SINGLE COLUMN TESTING MACHINE, TO WHICH THE CUSTOM MADE JIG WAS ATTACHED. 41

FIGURE 8-9: THE BUCCAL ASPECT OF THE RIGHT MANDIBLE AFTER APPLICATION OF THE BIS-ACRYLIC COMPOSITE ON THE LINGUAL AND THE BUCCAL ASPECT OF THE TEETH. THE BIS-ACRYLIC IS APPLIED IN SUCH A WAY TO COMPLETELY COVER THE EXPOSED INTERDENTAL WIRE WITH AS LITTLE AS POSSIBLE ON THE BUCCAL ASPECT OF THE FIRST MOLAR. 42

FIGURE 9-1: THE AGE DISTRIBUTION OF THE 109 PATIENTS PRESENTED TO THE DMSC. AGE DISTRIBUTIONS EXTRACTED FROM *UMPHLET ET AL. (1990)* AND *LOPES ET AL. (2005)* ARE PROVIDED. 45

FIGURE 9-2: MOST COMMONLY PRESENTED BREEDS WITH MANDIBULAR FRACTURES COMPARED TO POPULATION PRESENTED TO OVAH DURING THE SAME TIME PERIOD..... 46

FIGURE 9-3: FRACTURE AETIOLOGY OF THE 109 DOGS PRESENTED TO THE DMSC. (RTA= ROAD TRAFFIC ACCIDENT) 47

FIGURE 9-4: A COMPARATIVE PRESENTATION OF FRACTURE FREQUENCIES IN THE VARIOUS ANATOMICAL LOCATIONS OF THE MANDIBLE. 47

FIGURE 9-5: THE INCIDENCE OF OPEN OR CLOSED FRACTURES BASED ON THE ANATOMICAL LOCATIONS INVOLVED..... 48

FIGURE 9-6: REGIONAL DISTRIBUTION OF THE 124 TEETH IN THE FRACTURE LINE OF 109 DOGS WITH 135 MANDIBULAR FRACTURES..... 48

FIGURE 9-7 A,B: PICTURES INDICATING THE PATTERNS OF FAILURE, EITHER BIS-ACRYLIC COMPOSITE BREAKAGE (A) OR LIFTING OF THE ENAMEL SURFACE OF THE TOOTH (B). ALTHOUGH NOT VISIBLE IN THIS PHOTOGRAPH THE IMBEDDED INTERDENTAL WIRE WAS STILL INTACT. ROSTRAL IS TO THE RIGHT. 51

FIGURE 10-1: PHOTOGRAPH SHOWING THE LINGUAL ASPECT OF THE MANDIBLE DURING TESTING. NOTE SLIGHT BUCCAL ROTATION OF THE ROSTRAL SEGMENT CHARACTERISED BY THE INCREASE VISIBILITY OF THE CAUDAL SEGMENTS LINGUAL CORTEX (BLACK ARROW)..... 57

4 LIST OF TABLES

TABLE 8-1: FRACTURE CLASSIFICATION USED TO CLASSIFY MANDIBULAR FRACTURES.....	33
TABLE 9-1: PATIENT AND BIOMECHANICAL TESTING DATA. (RIS= REINFORCED INTERDENTAL STOUT LOOP COMPOSITE SPLINT, RIC= REINFORCED INTERDENTAL CROSSOVER COMPOSITE SPLINT, S= SECONDS, CCR= CHEMICAL CURE COMPOSITE RESIN, G=GRAM, N = NEWTONS, N/MM= NEWTON PER MILLIMETER, MM= MILLIMETER, N.MM= NEWTON MILLIMETER).....	52

5 LIST OF SYMBOLS AND ABBREVIATIONS

σ	Stress
BAC	Bis-acrylic composite
d	Distance
DMSC	Dentistry and Maxillofacial Surgery Clinic
F	Force
G	Gauge
L	Length of the bone
M	Torque/moment
N	Newton
NaCl	Sodium chloride
OVAH	Onderstepoort Veterinary Academic Hospital
PMMA	Polymethyl methacrylate
RIC	Reinforced interdental crossover composite splint
RIS	Reinforced interdental Stout loop composite splint
RTA	Road traffic accident

6 LITERATURE REVIEW

6.1 Bone and fracture pathology

A bone's ability to absorb forces is an inherent characteristic of the bone itself and changes depending on the bone's dimensions, location, species, age, sex and whether or not bone pathology is present (1-3). Inorganic structural materials provide compression strength and are responsible for the stiffness whereas organic components determine the tension properties (1). Fractures occur when the force (F) exceeds the ultimate strength of the bone and results in a complete or incomplete break in its continuity (1, 3, 4). If the speed at which the F is applied increases, the bone becomes stronger. This characteristic is referred to as viscoelasticity (3). Bone is classified as an anisotropic material which means that it is stronger when loaded longitudinally compared to transverse loading due to the osteonal and lamellar orientation (3). The fracture morphology can vary due to F related factors (magnitude, direction, rate, aetiology and contact area) and due to patient related factors (presence of disease, position during F application and motion) (1, 4, 5). These factors will determine whether the forces that lead to the fracture are compressive, tension, bending or rotational or a combination of these (4). Fractures can further be classified depending on whether pre-existing pathologies are present (1, 4). When disease leads to structural changes in the bone the extent of trauma needed for a fracture to occur is less than in healthy bone. Such fractures are known as pathological fractures (1, 4).

Direct trauma is the most common cause of fractures and occurs when F is applied directly to the bone (4). As mentioned earlier factors related to the applied force and the patient could change the fracture morphology. Fractures can further be classified based on the anatomical location, whether the fracture is simple or comminuted, open or closed and according to the length and direction of the fracture line (6). The classification of the fracture, the forces acting on the fracture, the ability to completely reconstruct the fracture and concurrent musculoskeletal injuries can affect the method selected for surgical correction (6).

6.2 Bone healing

Although bone can heal without surgical intervention the function of the bone can be influenced, either primarily or secondarily, if anatomical reduction is not achieved (3). The most important factors determining the way that fractures heal are the rigidity of the fracture repair device, the fracture morphology, the accuracy of fracture reduction, and the strain that occurs at the fracture ends (3, 7). Bone healing ideally requires an inter-fragmentary strain of less than 2%. Strain between two fracture ends is a change in the dimension of the fracture gap per unit of length of that gap. For the same amount of movement, a smaller fracture gap will thus have a higher inter-fragmentary strain when compared to a larger fracture gap (3, 7). During fracture healing the excessive inter-fragmentary strain can be decreased by either the formation of callus, contraction of muscles or by bone resorption at the fracture gaps (3, 7).

If a fracture is surgically corrected with an inter-fragmentary strain of less than 2% and an inter-fragmentary gap of less than 1 mm, primary bone healing occurs. During this process of healing cutting cones cross the fracture gap to form new lamellar bone oriented longitudinally to the diaphysis (3). Rigid fracture fixation is a prerequisite for primary bone healing. In unstable fractures or unstable fracture fixations secondary bone healing occurs and is recognised by the formation of callus during healing (7). The process starts with the formation of a fracture hematoma and the initiation of an inflammatory response. The inflammatory phase usually last for 3-4 days (3). Fractures result in the disruption of the medullary blood supply and the formation of a fracture hematoma. This hematoma is important in secondary bone healing as it precedes the repair phase of bone healing (7). The hematoma causes the release of vascular endothelial growth factor that stimulates angiogenesis. Together with these growth factors, platelets in the region of the hematoma release platelet derived growth factor and transforming growth factor- β 1, which further stimulate the production of new bone (7). Macrophages in the region of the fracture assist in the removal of necrotic bone. The formation of new capillaries, fibroblast and the influx on mononuclear cells results in the formation of granulation tissue (7). Granulation tissue can extend to twice its original size before rupturing which is ideal during this phase of healing as the inter-fragmentary strain remains high (7). Mesenchymal cells will now differentiate into chondrocytes and osteoblast for the formation of cartilage and bone respectively. The

signal to determine the formation of either chondrocytes or osteoblast is regulated by transforming growth factor- β 1 and bone morphogenetic protein (7). Mineralization of this soft callus then starts and proceeds from the ends of the fractures to the centre of the fracture site. The callus is now known as a hard callus. The fibrocartilage situated in the callus can undergo either endochondral or intramembranous bone formation depending on the amount of mechanical stability present (7). Following this phase of the bone healing the bone undergoes remodelling during which it undergoes morphological adaptations to regain its strength and function (7).

Primary bone healing can be divided into either contact healing, where fracture gap is less than 0.01 mm and gap healing, in which the fracture gap is between 0.08 and 1 mm (7). In both of these scenarios the prerequisite for primary bone healing is an inter-fragmentary strain of less than 2%, and thus rigid fixation is required. In primary bone healing the initial phases of bone healing is skipped and lamellar bone formation and Haversian remodelling occurs from the beginning (7). When a fracture gap of between 0.01 mm and 1 mm exists the fracture gap fill up with lamellar bone. By the third week Haversian remodelling starts during which osteons start crossing the fracture gap (7). In contact healing no inter-fragmentary lamellar bone formation occurs and osteons cross the fracture directly cross (3).

The ideal fracture fixation method should allow for fast uncomplicated healing with rapid return to function, with the function equivalent to the prefracture state. Semi-rigid fracture fixation techniques result in secondary healing and a decrease in the time till radiographic healing (8). Although no study exists in veterinary medicine comparing the time radiographic union using rigid and semi-rigid fixation methods for mandibular fractures, other factors (see anatomic considerations) might influence the selection of implants.

6.3 Forces acting on the mandible

Contraction of the temporal, masseter and medial pterygoid muscles, during eating or biting, will result in a dorsal displacement of the mandibular body due to caudal movement of the coronoid process (9). Contraction of the digastricus muscle on the other hand will result in ventral movement of the mandibular body, thus opening of the mouth (9, 10). The digastricus muscle originates on the paracondylar process of the occiput and inserts over a distance of approximately 2.5 cm on the ventromedial border of the of mandible. The insertion extends up to the level of the canine tooth (10). Bending forces (dorsoventral direction) due to the contraction of the masticatory muscles are the primary forces acting on the mandibular body during mastication and biting (9, 11). Lateral bending, compressive and torsional (due to the scissor bite/dental interlock) forces are negligible (9).

During closure of the mouth the alveolar margin is under tension whereas the ventral aspect of the mandible is under compression (9, 12-14). Implants offer more resistance to bending if placed on the tension surface of a bone and thus the preferred site of placement of implants is on the alveolar margin (13).

During biting extreme forces can be generated (147 N to 946 N at the level of the canines) (15). The high forces, limitations on the type and size of implants (due to decreased bone stock) and all the abovementioned factors may complicate mandibular fracture repair and healing and can explain the high complication rate reported (34%) (16).

It is the researchers opinion that the forces acting on the mandible are import to consider when selecting a method for biomechanical testing. A testing method that closely mimics the scenario post fracture fixation should be selected.

6.4 Biomechanical testing

Mechanical testing of bone can be done in compression, torsion, tension, bending or a combination of these (17). Bending tests evaluate the strength of a bone when bent about its long axis (17). Different methods of bending tests exist and include four point, three point and cantilever bending tests (17). Four point bending tests involve the application of “force couples” which is the application of paired forces parallel to each other in opposite directions (Figure 6.1). Fractures that occur as a result of the forces applied during this test, will occur at the weakest point of the bone (17).

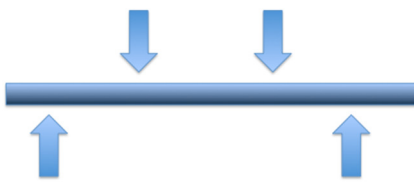


Figure 6-1: Schematic illustrating a 4-point bending test where two paired forces are applied in opposite directions.

In the three point bending test three forces act on the bone, with the resultant fracture at the area where the central F is applied (17) (Figure 6.2). Cantilever bending test on the other hand involves the rigid fixation of a bone specimen on the one end and the application of a F on the opposite end (Figure 6.3). It is the researcher’s opinion that cantilever testing reflects the normal forces acting on the mandibular body during biting, chewing and eating more closely compared to other biomechanical testing methods.

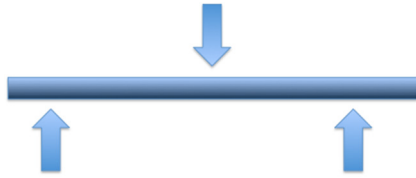

Figure 6-2: Schematic illustrating the 3-point bending test where one unpaired force and one paired force is applied in opposite directions.



Figure 6-3: Schematic illustrating a cantilever bending test. The specimen is fixed to the one end (asterisk) and a load at the opposite end.

Bending forces are commonly referred to as moments. The moment (M) is the turning effect produced by the applied force applied a distance away from a fixed point. The moment during cantilever testing is a product of the force and the distance from the point of fixation to the point where the force is applied (18). The M ranges from zero at the point where the F is applied to the maximum at the area where the bone is fixed or at the location of the osteotomy (17). During cantilever testing a load transducer mounted to a single linear actuator is used and is mostly under control of a servovalve (servohydraulic unit) (19). During testing the actuator rod moves down and places the specimen under compression (19). Controller units are used to control the rate of displacement during constant loading (19).

Before testing the samples need to be fixed with a “potting” agent especially when the samples have an irregular shape. “Potting” of the sample will allow for adequate fixation during testing and prevent movement when the F is applied (19). Polymethyl methacrylate (PMMA) is a good choice as “potting” agent as it allows ample time for positioning during the time that it takes to harden (8-10 minutes) (19). When dry, PMMA has a compression strength of 55 megapascal and volumetric

expansion of 0.12% which will result in insignificant biomechanical alterations during testing (19). Multiple factors like the conformation of the osteotomy, distance of osteotomy to the area where the F is applied, width of the bone at the osteotomy, loading rate, testing preparation and storage of the specimens can alter biomechanical properties of bones (20-25). Ideally, testing should be done under controlled environmental conditions consisting of a temperature of 24°C with a relative humidity of 40–90% (26).

Force-displacement curves of materials are used to help define and calculate the mechanical properties of that material (Figure 6.4) (27, 28). In biomechanical studies, the direction of the F determines the direction of displacement/deformation and can easily be read off the x-axis of the force-displacement curve (Figure 6.4). Changes in the displacement/deformation of the bone are measured by the displacement of the actuator (18). Care should be taken when directly correlating the force with displacements, as decrease stability of specimen fixation and the mechanical properties of the “potting” material used for fixation to the testing system can influence the displacement (29).

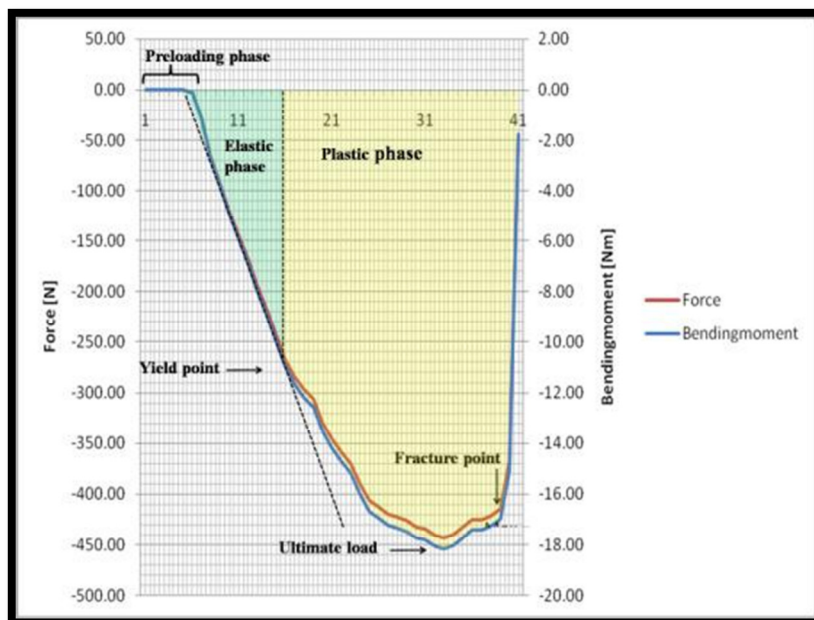


Figure 6-4: Typical load-deformation curve during cantilever bending

The applied F that results in an external effect (change of velocity) or an internal effect which is a change in the shape (deformation) of the body (18). Forces

have magnitude, direction and a point of application (18). The unit for F is Newton, where one Newton equals the F needed to accelerate 1 kg at 1 m/sec² (18).

The equation for F is mass multiplied by acceleration.

$$F = M \times A$$

Commonly in the initial part of the force displacement curve a horizontal line can be appreciated. During this phase displacement occurs with no force recordings. This phase is known as the preloading phase of the force displacement curve and is defined as the period until the load transducer (attached to the actuator) starts to engage the specimen (18) (Figure 6.4).

As a load is applied to the construct placed in the testing machine the construct will start to deform. If the load is removed and the construct returns to its original shape it is known as elastic deformation. As the load increases a point is reached where the material starts to deform plastically. This implies that even after the removal of the force the material would be permanently deformed (18). The point where the elastic behaviour of a material changes to the plastic behaviour is known as the yield point, from where the force-displacement curve has a shallower incline (18).

Stress (σ) is related to inherent characteristics of the bone/implant, for instance the microscopic architecture of bone, and defines the resistance that the bone/implant provides against the F that is acting on it (18). The stress might differ depending on the microscopic architecture of bone. Stress is equal to the amount of F applied per unit of surface area over which the F acts if the specimen is placed in either compression or tension and is measured in either N/m² or Pascal (18, 30). The ultimate strength/stress is defined as the maximum amount of F that a material can withstand and is characterised by the peak of the stress-strain curve (18). Ultimate stress (stress at construct failure) during bending is calculated with the formula: (31)

$$\sigma = M_y/I$$

In this formula M_y = the y moment and I = second moment of area. To calculate stress and ultimate stress the precise surface area over which the F act should be known (18).

The ultimate force, which is the load at which failure occurs, is equivalent to the ultimate stress on the force-displacement curve. The unit for ultimate force is N (18).

The amount of change in dimension (ΔL) per unit area of length of the bone (L) is termed strain (\mathcal{E}) and is equal to deformation (change in dimension) of the bone in the direction in which the F is applied (18). Strain can also be termed normalised displacement and due to the strain being the ratio between two lengths it has no units (18, 28, 30). Strain is negative when the bone is compressed and positive if the bone is placed under tension (18). The ultimate strain (\mathcal{E}_{ult}) is the strain calculated at the time of fracture/failure (18).

$$\mathcal{E} = \Delta L / L$$

The M occurs when an off axis F is applied a distance away from the point of rotation of that object. The outcome of the applied M is the internal effect resulting in strain (18). The M is represented by the F multiplied by the distance (d) from the centre of rotation of the object to the point of application of that F . The unit for M is Nm.

$$M = F \times d$$

The stiffness of a material on the other hand is the resistance that the body offers to deformation (18, 32). Stiffness is the ratio between the F that is applied to a body within the elastic phase of the force-displacement curve divided by the displacement (d) in the corresponding phase of the curve (18).

$$S = F/d$$

The elastic modulus (E) of a material is defined as the ratio between the stress and the strain values in the linear region (elastic phase) of the stress-strain curve. The elastic modulus of biological tissues cannot be calculated because they do not have a true linear phase due to the non-linear characteristics of the fluid in them and hence do not obey Hooke's law (18). Hooke's law states that the F needed to extend/compress a spring by a certain amount is proportional to that amount (18).

6.5 Collecting and storage of bone specimens for biomechanical testing

In the post mortem period tissues in the body undergo different rates of decomposition of which skeletal structures and the heart are some of the last to decompose (33). Decomposition involves two processes, namely putrefaction and autolysis (34). Putrefaction involves bacteria and fermentation whereas autolysis is the breakdown of tissue due to chemical processes related to intra cellular enzymes (34). A magnitude of factors like species, general health status, presence of gastrointestinal contents, cause of death, body temperature at death, environmental conditions and position in the post mortem period determine the rate of progression of post mortem decomposition (33). This is an important consideration in the use of post-mortem specimens as autolysis and putrefaction occurs within hours of collection and may affect the biomechanical properties of bone (27).

Bone harvesting post mortem should be done with great care since small cuts may inadvertently be created into the bony surface (35). These small cuts can act as points of stress concentration during subsequent mechanical testing (35), while on the other hand, incorrect handling can also lead to falsely improved mechanical properties. Another factor to consider is that tissues, even bone, will easily dehydrate during harvesting and testing if no special measures are taken. Drying of bone will also increase the modulus of elasticity and increase the tensile strength (21).

It has been established that bone can be stored at -20°C without any significant alterations in the biomechanical properties, as long as the surface hydration of the bone specimens is maintained by wrapping it in 0.9 % saline soaked swabs (36-39). It is not known whether all the collagenase and protease activity in the bone stops during freezing but previous studies have shown that freezing bony specimens for a period of 8 months does not significantly change the mechanical properties (38). More extended periods of storage of canine bones have not been studied.

It is advisable that specimens are thawed in 0.9% saline at room temperature for at least 3 hours prior to mechanical testing (26). Collagenases and proteases in the bone can be reactivated during thawing, therefore, biomechanical testing should commence immediately after the thawing cycle has been completed (26).

6.6 Anatomical considerations

The unique anatomy of the mandibles commonly challenges surgeons during fracture fixation (40). Anatomically, mandibles differ considerably from long bones. The alveolar canal is located in the ventral third of the mandibular body and contains the inferior alveolar nerve, the mandibular alveolar artery and the mandibular alveolar vein (Figure 6.5 and 6.6) (41, 42). The mandibular alveolar artery provides the main blood supply to the teeth and the alveolar bone (41-43). Fracture of the mandible will mostly result in severance of the mandibular alveolar artery (42). The vascular support to the fracture fragments from the surrounding soft tissues (muscular attachment and periosteum) is thus of paramount importance in the post fracture period (42, 44). Surgical techniques that aim for precise anatomical reduction requires extensive stripping of the soft tissue off the bone to allow access to the fracture fragments and to the mandibular body for fixation, which can significantly affect the fracture prognosis (14). Multiple large foraminae are present in the mandible. These foraminae are located on the rostralateral (mental foraminae) and caudomedial aspects (mandibular foramen) of the mandibular body and can complicate the placement of fixation systems (14, 41). Screw placement in these foramina can result in the inadequate/loss of cortical fixation. Additionally teeth possess varying sizes, shapes, length and number of roots (depending on their location) that occupy the mandibular body and incisive bone (41). These tooth roots can extend ventromedially for 45-70% of the mandibular body and thus limit the safe corridors for fixation system placement in the mandible (42). The anatomical characteristics of the mandible limit the options for implant placement by a novice surgeon (16, 48).

Further complicating the management of mandibular fractures is the fact that the majority of these fractures (85%) of the mandibular fractures involves the alveolus of a tooth (16). In pathological fractures where peri-apical lesions are present and in loose teeth as a result of the trauma; teeth need to be removed at the expense of fracture stability (40).

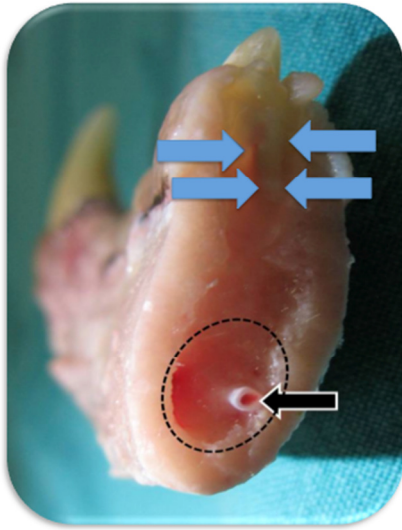


Figure 6-5: Caudorostral view of the rostral part of the mandible after osteotomy between the first molar and fourth premolar. The mandibular canal (dashed circle), the caudal tooth root of the fourth mandibular premolar (blue arrows) and the mandibular artery (black arrow) are visible.

Accurate anatomical reduction is of great importance to prevent postoperative malocclusion as malalignment of 2-3 mm caudally can result in a failure of rostral closure by up to 1 cm (45). Malocclusion can lead to serious consequences like patient discomfort, temporo-mandibular joint arthritis and arthrosis, oral mucosal damage, fistulation, and difficulty in eating (46). The abnormal bite can also predispose the animals to tartar build up and subsequent periodontal disease (46).

Post operatively patients can experience exposure of bone plates if the plates are placed to far dorsal on the mandibular body due to the limited soft tissue coverage (46).

For the same reasons the majority of cases (72%) of mandibular fracture are open (9, 16, 47).

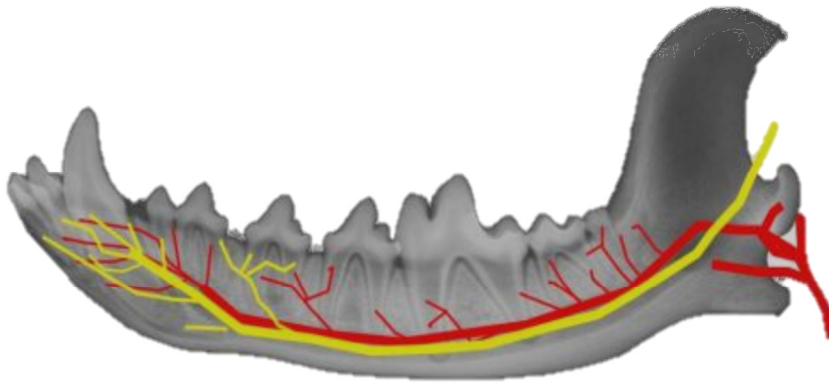


Figure 6-6: Representation of a canine mandible indicating the course of the inferior alveolar nerve (yellow) and the mandibular alveolar artery (red) in the mandibular canal.

6.7 Aetiology, signalment and classification of mandibular fractures

Mandibular fractures occur in 1.5-6% of all patients that present with fractures and occur mainly as a result of road traffic accidents (RTA), fall from heights, projectile injuries, unknown trauma and dogfights (16, 49-51). Dogfights and RTA are the most common causes of mandibular fractures accounting for between 19.1–43% and 12–52% of cases respectively (16, 51). Pathological mandibular fractures usually occur in older small breed dogs as they have more severe periodontal disease that can lead to alveolar bone resorption, tooth loss and root pathology (52). The most severe periodontitis and periapical pathology is found in the mandibular molar region (53). In elderly toy breeds, considerable osteoporosis usually precedes fractures through an infected alveolus (13). This can lead to tooth loss and tooth root pathology, potentially predisposing dogs to mandibular fractures in this region even with minor trauma. The mandibular first molars of small breed dogs, compared to large breeds, are larger relative to the height of the mandible (their roots extend ventral to the mandibular canal) (52, 53). Due to the conical shape of their tooth roots, disruption of the proximal 5 mm attachment support potentially causes disruption of 44.6% of its attachment area (54).

Nearly half of the patients that present with traumatic mandibular fractures are dogs less than 12 months of age (16, 51). Young male dogs are overrepresented and this has been attributed to inexperience and roaming (16, 51). Male dogs are more aggressive and territorial, which can lead to scenarios more conducive to mandible fractures, contributing to the higher incidence in males (60-66%) when compared to females (16, 51).

Mandibular fracture were described in the symphyseal region in 15-22%, the incisive region in 5%, the canine region in 9%, the premolar region in 17-31%, the molar region in 18-47%, the ramus region in 5-17%, and the condylar region in 5% of the cases presented in two large studies (16, 51). The variations in percentages between the two studies may be the result of regional breed differences. Anatomical location and conformation of mandibular fractures can play an important role in the selection of treatment methods. In humans, these factors have been shown to aid in prognostication associated with the outcomes of surgery (42, 55). Although previous retrospective

studies of oral fractures in dogs exist, none describes the fracture morphology in detail (16, 51).

Fracture morphology depends on the aetiology as well as patient factors but also depends on the characteristics of the applied F, such as direction, the speed at which it is applied, the amount and nature as well as the spatial relation of the bone to the force. In humans, anatomical characteristics like the strength of anatomical regions of the bone, the size and shape of the bone and muscle attachments is known to influence the morphology of mandibular fractures (5).

6.8 Mandibular fracture repair techniques

Mandibular fractures can be treated by conventional osteosynthesis techniques, minimally invasive or by non-invasive methods (40). The mechanical properties of the fixation devices plays an integral role in the eventual outcome (6). Fixation devices should be able to support the load across the fracture line until the bone has regained sufficient strength (6). The extent to which the implant supports the bone can differ ranging from absolute stabilisation to biological stabilisation. With absolute stabilisation the inter-fragmentary strain is less than 2% and with a limited inter-fragmentary gap <1 mm primary bone healing results and thus no callus formation e.g. fracture compression with plate fixation. Biological stabilisation on the other hand allows for a less rigid fixation, a larger inter-fragmentary strain and thus callus formation (7). Examples of fixation methods that allows for biological stabilisation include external skeletal fixators. The amount of callus that forms depends on the inter-fragmentary strain. Larger strain equals greater amount of callus formation (7). Interdental splints can also be considered as a type of external skeletal fixator. The choice of fracture fixation method will depend on the fracture type and site (fracture classification), the patient age and size, the disease status, the quality of bone and the expected postoperative patient activity and owner compliance (6, 9, 13, 42, 55, 56). The most common conventional surgical techniques for mandibular fracture repair in small animal include interosseus wires, external skeletal fixation and plate osteosynthesis (12, 57-61). The techniques differ considerably but should ideally aim to achieve: fragment stabilisation, dental occlusion by precise anatomical reduction, early return to function, avoidance of excessive perifractural soft tissue elevation/disruption, removal of diseased teeth in the fracture line and prevention of tooth root damage during placement of fixation devices (42, 46, 62). Unfortunately, except for fragment stabilisation, conventional mandibular osteosynthesis procedures do not always meet all these requirements (56). Implants placed too dorsal on the mandibular body will result in tooth root damage or plate exposure by erosion through the oral mucosa. In addition, inadequately contoured plates can result in displacement of the fracture fragments with resultant occlusion problems.

The high incidence of iatrogenic trauma has lead to the selection of non-invasive repair techniques by some in an attempt to provide fracture stabilisation while avoiding

the disadvantages inherent to conventional fracture fixation techniques (42, 56). Interdental composite splint and interdental wiring are examples of non-invasive surgical techniques (56). By using such techniques surgeons can greatly decrease the surgical time, retain occlusion, save costs and attain a more rapid return to function (42, 56). Non-invasive techniques also limit the damage to the structures in the mandibular canal and tooth roots (42, 56).

Interdental wiring is an established non-invasive intraoral fixation technique used to treat simple mandibular and maxillary fractures where the dentition and eruption patterns are normal (56). Interdental wiring involves the application of a wire in loop fashion around the crowns of intact teeth rostral and caudal to the fracture line (13, 14). A variety of interdental wiring techniques (almost always used in combination with intraoral splints) have been described in companion animal patients and includes the Erich arch bar, Stout loop, Ivy loop and Risdon wiring (9, 20, 63).

The most commonly used technique, the interdental Stout loop technique, relies on the incorporation of at least two teeth rostral and two teeth caudal to the fracture line (14). During its application a wire is passed through the most caudal diastema and the one end of the wire is then drawn rostrally along the buccal aspect of the teeth to be included. The other end is kept longer and is passed from the lingual aspect through each interdental space of the pair of teeth adjacent to the fracture site, dorsal to the wire on the buccal aspect and then passed back via the same route ventral to the wire. The loops formed in the diastema on the buccal aspect are twisted to tighten them. The two free ends are twisted close to the gingival margin and cut (45, 64) (Figure 8.6). Dorsal slippage is inevitable in most small animals due to the conical shape of the teeth (base of the crown being the largest diameter) (9). Subgingival wire placement of the wire has also been recommended to prevent the dorsal slippage (14, 56). This results in postoperative gingivitis and patient discomfort due to soft tissue impingement (56). Others have advocated notching the crowns using a dental burr to overcome the anatomical hurdle, where the trough created with the burr will prevent the wire from slipping (14, 45). Notching is not recommended as it can lead to calculus and plaque accumulation in the postoperative period which predisposes patients to periodontal pathology (9).

The disruption of the gingiva, the gross interference with the periodontium and the technical difficulties in their application, however, puts in question the use of these non-invasive techniques' clinical use in small animal surgery. Other non-invasive techniques without these potential disadvantages are sought.

Interdental splinting is a non-invasive intraoral technique in which a resin is used to stabilise mandibular fractures (56). Prior to application of the composite, the teeth are polished using flour pumice and acid etched on both lingual and buccal aspect using 37% phosphoric acid (55). After 20 seconds the entire etched surface is rinsed with water and air-dried (55). The composite is then applied to the teeth of the mandible including at least two teeth rostral and two teeth caudal to the fracture (56). The material can be placed on both the lingual and buccal aspects of the premolar teeth but in the region of the 4th maxillary premolar and first mandibular molar the splint should be transitioned to the lingual aspect as not to interfere with the normal "scissor bite" (56).

Bis-acrylic composites are the current materials of choice for interdental splinting as they provide additional patient benefits when compared to the methacrylate based acrylics (56, 65, 66). The low exothermic temperature reaction (35.6°C) results in no concerns for pulpal damage as with methacrylate products (65). The composite is conveniently mixed during extrusion with no noxious monomer fumes (56, 66). Furthermore these products are less porous and require no polishing after application and therefore the increasing the efficiency of plaque removal resulting in improved gingival health (66). Overall patient comfort is improved (66).

Potential complications of interdental wire and interdental splinting techniques include slippage of the wire (that can lead to bone resorption), infection, wire breakage, non-union, malocclusion, interference of the wire with dental occlusion, laceration of oral soft tissue, acrylic breakage, gingivitis and oral ulceration (14, 46, 67). Other disadvantages are damage to periodontal tissue and teeth during placement, after placement and at removal (14, 68).

Notwithstanding the drawbacks of the current non-invasive techniques the advantages of using these methods outweigh their potential disadvantages. These techniques are cost effective, preserve the tooth roots and neurovascular structures,

decrease surgical time and postoperative return to function and they are biomechanically more sound techniques since the fixation device is placed on the tension side of the mandible (14, 42, 56, 69). By combining interdental wiring and interdental splinting (also called reinforcing of the composite splint) the construct will provide superior strength in bending, compared to any of the techniques alone (20, 56). One biomechanical study has been performed on canine mandibles to evaluate the bending strength of various interdental fixation techniques (20). It was concluded that the ultimate strengths of the interdental fixations decreased in order from Erich arch bar with acrylic, Stout loop with acrylic, Acrylic alone, Stout loop interdental wire to Erich arch bar (20).

7 INTRODUCTION

There are few studies that have looked at the incidence of mandibular fractures in dogs (16, 51), and no information exist the most commonly encountered fracture conformations. Biomechanical testing data on mandibular fracture fixation methods in small animals are lacknig.

Many techniques used to correct mandibular fractures in dogs rely on the bone for the placement of fixation devices (11, 12). This can potentially result in damage to the tooth root and neurovascular structures in the mandibular canal (56).

Interdental splinting techniques are difficult to place in dogs because of the large interdental space and the absence of a supragingival “neck” when compared to humans. Technique modifications are therefore needed that have similar mechanical properties but are adapted to the canine anatomy.

The study will consist of two parts. Data collected from the initial part of this study will be used to select cadavers for mandible collection. These mandibles will be used in the second part of the study to describe a novel reinforced interdental composite splinting technique, the reinforced interdental crossover composite splint (RIC). This novel technique will then be comapred biomechanically to a existing technique, the reinforced interdental Stout loop composite splint (RIS)

7.1 Aims of the study

The aims of the current study are to describe the morphology of fractures and signalment of patients presented with mandibular fractures to a referral practice in South Africa. The data collected will be used to create a fracture model using the most commonly encountered fracture morphology and location. This model will be used to compare the biomechanical properties of a novel, non-invasive mandibular fracture repair technique for dogs, the reinforced interdental crossover composite splint (RIC) to an existing technique, the reinforced interdental Stout loop composite splint (RIS).

7.2 Hypothesis

The null-hypothesis is that there is no biomechanical difference when comparing the reinforced interdental crossover composite splint to the reinforced interdental Stout loop composite splint

8 MATERIALS AND METHODS

8.1 Retrospective study on mandibular fractures

The case records and radiographs of dogs with mandibular fractures that were presented to the Dentistry and Maxillofacial Surgery Clinic (DMSC), Onderstepoort Veterinary Academic Hospital (OVAH), South Africa between January 2001 and December 2009 were reviewed retrospectively.

Data recorded from the patient files included sex (entire or neutered), age (months), weight and breed. Information recorded in the patient files was used to determine whether the fractures were open or closed. Aetiological factors were classified as dog fights, RTA, unknown, pathologic or other. All pre-operative radiographs were evaluated by the researcher and the data recorded from the radiographic re-evaluation included the anatomical location (Figure 8.1), fracture conformation, unilateral or bilateral involvement, tooth roots in the fracture line, displacement, fracture stability and radiographic evidence of pre-existing pathology (Table 8.1). Patients with incomplete patient records were excluded from the study.

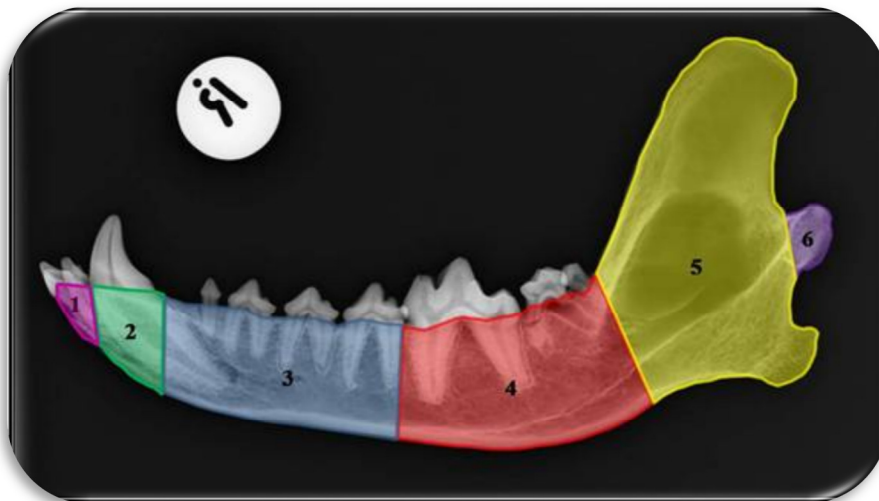


Figure 8-1: Lateral radiograph depicting the anatomical zones. 1. Incisive region, 2. Canine region, 3. Premolar region, 4. Molar region, 5. Ramus region, 6. Condylar region.

Table 8-1: Fracture classification used to classify mandibular fractures.

Classification	Description
Location	
<i>Symphyseal region</i>	Separation of the <i>synchondrosis intermandibularis</i> .
<i>Incisive region</i>	Fracture involving the <i>pars incisiva</i> of the mandible lateral (distal) to the <i>synchondrosis intermandibularis</i> and rostral to the periodontal space of the canine tooth on the <i>margo dorsalis</i> .
<i>Canine region</i>	Fracture originating in the periodontal space of the canine tooth.
<i>Premolar region</i>	Fracture originating from periodontal space of the first premolar tooth on the <i>margo dorsalis</i> and distal to, but not including the periodontal space of the first molar.
<i>Molar region</i>	Fracture originating from the rostral aspect of the periodontal space of the first molar extending along the <i>margo dorsalis</i> of the mandible to an area that includes the periodontal space of the third molar on its distal aspect.
<i>Ramus region (coronoid and angular process)</i>	Fractures involving the <i>ramus mandibulae</i> extending from an area distal to the periodontal space of the third molar but not including it and excluding the <i>processus condylaris</i> .
<i>Condylar region</i>	Fractures involving the <i>processus condylaris</i> of the mandible.
Fracture type*	
<i>Transverse</i>	Fracture line perpendicular to the long axis of the bone (47).
<i>Oblique</i>	Fracture at an angle to the long axis of the bone. Oblique fractures can be sub classified as long- (fracture length more than about twice the width of the bone) and short (fracture length less than twice the width of the bone) oblique (47).
<i>Comminuted</i>	Fracture in which there are several fragments and the fracture lines communicate (47).
*Fractures in the ramus region and condylar region are classified based on the fracture line direction in relation to the mandibular body. The length of the fracture line is based on the dorsoventral mandibular body width just rostral to the mesial root of the first mandibular molar.	
Fracture distribution	
<i>Unilateral</i>	Fracture(s) involving a single mandible or with multiple unilateral mandibular fractures.
<i>Bilateral</i>	Fracture involving both mandibles, or a single unilateral mandibular fractures in combination with symphyseal separation.
Open or closed fractures	
Open	Clinical history revealed whether these fractures were open i.e. one in which there is a skin or mucosal wound over the fracture location (47, 55).
Closed	Clinical history revealed whether these fractures were closed i.e. one in which there is no skin or mucosal wound over the fracture location (47, 55).
Involvement of tooth roots	
<i>Yes</i>	Fracture extending through the periodontal space of tooth/teeth.
<i>No</i>	Fracture not extending through the periodontal space of tooth/teeth.
Fracture stability	
<i>Relatively stable</i>	Fracture where the fracture line runs in a rostroventral direction (55).
<i>Relatively unstable</i>	Fracture where the fracture line runs in a caudoventral direction (55). This groups also includes comminuted and transverse fractures.
Displaced fractures	
<i>Yes</i>	There is a change in the axis, step off or no contact along the fracture lines (70).
<i>No</i>	There is no change in the axis or step formation between the fracture lines (70).
Pathological fractures	
	The fracture occurred as a result of minimal or no traumatic force and the dental radiographs showed the presence of alveolar bone lysis, osteopenia, osteomyelitis or neoplasia.

8.2 The comparative biomechanics of the reinforced interdental crossover and the Stout loop composite splints for mandibular fracture repair in dogs

A case controlled observational study was performed on the mandibles of 6 small breed dogs (<10 kg) between 6 and 12 months of age. All dogs were euthanised for reasons unrelated to this study. The Animal Use and Care Committee of the University of Pretoria approved the study (V024/11) and owners gave written consent for study and research purposes (Addendum 1).

8.2.1 Specimen collection and storage

The mandibles were harvested within 12 hours of euthanasia. Initially they were inspected visually for any crown and eruption pattern abnormalities (including the presence of deciduous teeth). If the history of the patients indicated that they were euthanised due to suspected or confirmed infectious diseases, the mandibles were harvested in the pathology building, OVAH. After disarticulation the mandibles were radiographed to evaluate for and ensure the absence of fractures, bone pathology and tooth root abnormalities. Radiographs were performed using a fixed rotating anode x-ray machine (Polymath 50, Siemens AG, Erlangen, Germany) with a focal spot to film distance of 115 cm (without a grid). The x-ray machine was set to a kilo voltage peak (KVp) of 45 and milli-ampere seconds (mAs) of 5. The mandibles were positioned for a lateromedial radiograph. The images were acquired using computed radiography (Fujifilm, Tokyo, Japan) and the images were enhanced for optimal quality (Addendum 2). All the mandibles were stripped of all soft tissue except for the gingiva. During preparation the mandibles were frequently irrigated with 0.9% NaCl (Freeflex saline 0.9%, Fresenius Kabi, Gauteng, South Africa) to prevent desiccation. Before storage all the teeth were scaled using an ultrasonic scaler (Woodpecker UDS-K, Hongtaiyand Dental Instruments Co. Ltd., China). Each pair of mandibles was randomly assigned to one of two groups (group A and B) by the flip of a coin, wrapped in a 0.9 % saline soaked swab and vacuum-sealed in a plastic bag. The bags were permanently marked with the patient details, group number; and stored at -20°C until testing (39).

On the day of mechanical testing the mandibles were thawed and rehydrated by submersion in 0.9% NaCl for 5 hours at room temperature. During preparation and testing the mandibles were constantly irrigated with 0.9% NaCl to prevent desiccation.

8.2.2 Specimen preparation

A moulding block welded from 2.5 cm square tubing metal was used to imbed the caudal segment (condylar, coronoid and angular processes) of each mandible in a 2.5 cm x 2.5 cm x 9 cm block of polymethyl methacrylate (PMMA) (Polymethyl methacrylate, Melodont Dental Laboratory, Springs, South Africa) (Figure 8.2). The condylar process of each was placed in contact with the floor of the mould, which was filled with PMMA to ensure the distance from the region between the 3rd incisor and the canine to the surface of the PMMA was equal for both mandibles in a pair. The mandibles were aligned during curing of the PMMA with the alveolar surface positioned at 90 degrees in relation to the horizontal plane and 15 degrees lingual in relation to the vertical (Figure 8.3 a, b) using wooden templates.




Figure 8-2 a,b: Specially designed mould viewed from the side (a) and from the top (b) The condylar , the coronoid and the angular processes of the mandible will be moulded into a polymethyl methacrylate block after positioning it in the crypt between the two vertical uprights (black arrow).




Figure 8-3 a,b: The caudal segment of the mandible was fixed in a polymethyl methacrylate block (*) and positioned in a metal jig. The position of the mandible in the polymethyl methacrylate was such that the teeth formed a 90-degree angle with the horizontal plane (a) and 15 degrees towards the medial plane (b). Note that in both photographs the teeth are covered in 37% phosphoric acid (blue colour). The black arrow indicates the location and direction where the force was applied during testing.

In every bone a partial osteotomy was created in the diastema between the 4th premolar and the 1st molar using an electric drill (Dremel, Robert Bosch Tool Corporation, Illinois, USA) and a diamond disc (24 mm diameter and 0.35 mm thick) (Dental diamond cutting disc, Ritodental, China). The osteotomies were made perpendicular to the long axis of the mandibular body and extended from the alveolar margin ventrally for two thirds of the dorsoventral height.

The RIC was applied to the right mandible whereas the RIS was performed on the left mandible in all patients belonging to group A. The opposite was true for the patients in group B.

Prior to application of the interdental wires the teeth were polished using flour pumice and acid etched on both lingual and buccal aspect using 37% phosphoric acid (Best-Etch, Vista dental products, USA). After 20 seconds the entire etched surface was rinsed with water and air-dried. The principle researcher conducted all procedures; he did not have previous experience in interdental wiring nor splinting techniques. Touching of the etched surfaces was avoided prevent contamination of the etched surface (68).

8.2.2.1 Reinforced interdental composite splint (RIC)

For all the mandibular fractures undergoing the RIC, a primer and bonding agent (Prime and Bond, Dentsply Int. Inc., USA) was applied on the buccal aspect (close to the gingival margin) of all teeth from the canine to the 1st molar (excluding the 1st premolar) using a micro brush. The sites of bonding agent application corresponded to the proposed locations of the compomer “buttons” on the buccal aspect of the teeth. The bonding agent was light cured using a curing light (LA 500 Blue Light, Apoza, Enterprise Co. Ltd., Taipei, Taiwan) for 10 seconds. A “button” (approximately 1.5 mm x 3 mm) of compomer (Dyract, Dentsply Int. Inc., USA) was placed onto the bonding agent and light cured for 40 seconds. The function of these “buttons” was to prevent dorsal slippage of the interdental wire (Figure 8.4). A 25-gauge stainless steel wire was placed through the diastemas of the 1st and 2nd mandibular molar so that the free ends of the wire extended rostral beyond the mandibular incisor teeth. The wire was then advanced rostral on the lingual and buccal aspect (ventral to the “buttons”), crossing in the diastemas between subsequent teeth (excluding the 1st premolar) (Figure 8.5). The free ends of the wire were twisted on the lingual aspect (close to the gingival margin) of the canine until the wire was tight (without causing collapse of the osteotomy gap). The ends of the wire were then cut leaving 3 to 4 turns and bent flat against the gingival margin.

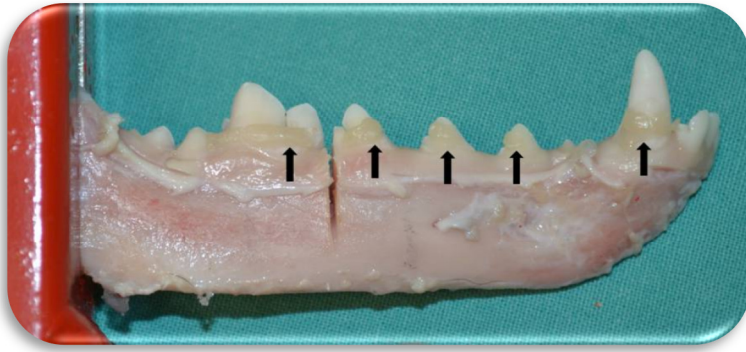


Figure 8-4: Prepared and fixed mandible showing the areas where the compomer has been applied to create small “buttons” to prevent the wire from slipping in a dorsal direction. Note that initially the osteotomy was only made through the dorsal two thirds of the mandibular body.

The BAC (Protemp 4, 3M ESPE dental, Seefeld, Germany) was applied on the lingual and buccal aspects of the teeth from the 1st molar to canine. Only a small amount, just to cover the wire, was applied to the buccal aspect of the 1st molar and the canine teeth. The BAC canister was weighed just before and immediately after application and the amount of acrylic used was recorded.

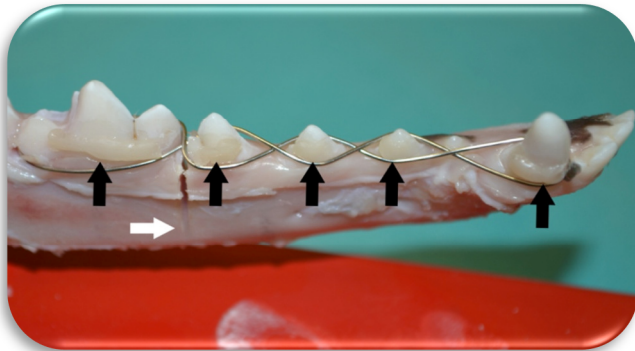


Figure 8-5: Reinforced interdental crossover technique before the application of the bis-acrylic composite. Note the small “buttons” of compomer just dorsal to the interdental wire (black arrows). The osteotomy (white arrow) has not been completed yet.

After curing application of the BAC for 5 minutes, the osteotomy was completed (ventral third) and the mandible was submersed in a 0.9% NaCl solution until testing. The time from the start of each technique until the end of the BAC application was recorded for each mandible.

8.2.2.2 Reinforced interdental Stout loop composite splint (RIS)

The technique for application of the RIS has been described previously (45, 64). In short, a 20 G hypodermic needle was used to assist the passage of a 25 G wire subgingivally in the diastema between the 1st and 2nd molar. One end of the wire was placed along the buccal aspect of the teeth from the 1st molar to the 3rd incisor. The other end was left longer and passed from the lingual aspect through the diastema of the 4th premolar and the 1st molar dorsal the wire on the buccal aspect. It was then passed back via the same route ventral to the wire (always subgingivally using a 20 G hypodermic needle). The loop formed in the diastema on the buccal aspect was twisted clockwise to tighten it (without causing collapse of the osteotomy gap) (Figure 8.6).

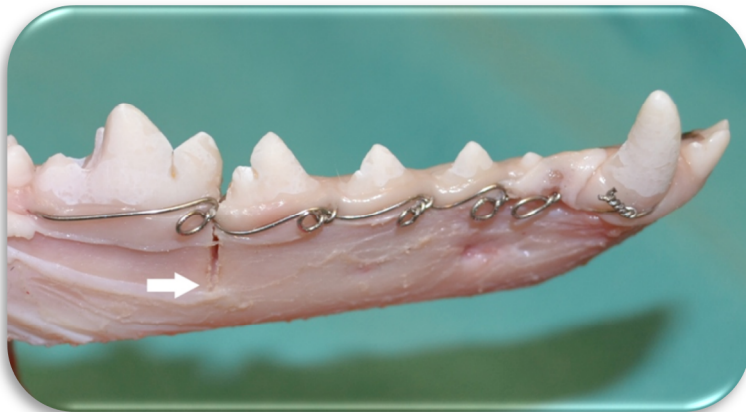


Figure 8-6: Interdental Stout loop wire pattern before the application of the bis-acrylic composite. The osteotomy (white arrow) has not been completed yet. Note the frosted white appearance of the teeth post acid etching.

These steps were repeated for each interdental space and ended off by twisting the two free ends on the lingual aspect of the canine (close to the gingival margin). The ends of the wire were cut leaving 3 to 4 twists and bent flat against the gingival margin.

The application of the bis-acrylic composite (BAC) was identical to the RIC.

8.2.3 Biomechanical testing

A custom made jig (Figure 8.7) fixed the PMMA block to a single column testing machine (Schenck PM 250, Schenck Ltd., Warwick, UK) (Figure 8.8). A S-shaped load transducer (error +/- 0.03% of total load) was mounted to a linear actuator rod under control of a servovalve (servohydraulic unit). During testing the actuator rod (with the load transducer attached to it) moved downward and exerted a cantilever bending force with the aid of an indenter to the region between the canine and the 3rd incisor (Figure 8.9). The indenter was custom made from a 12 mm diameter round bar with a 40 degree bevelled and blunted tip. A dorsoventrally directed force was applied at a rate of 2 mm/min based on a previous study (60). A controller unit (K7500 Servocontroller, Zwick/Roell, Hauptsitz, Germany) was used to control the displacement during constant loading.




Figure 8-7: A custom made jig that will be used to secure the PMMA blocks of the imbedded mandible to the single column testing machine viewed from the side (a) and from the front (b). The PMMA block is inserted into the square tubing and fixed lightly with the two bolts.




Figure 8-8: Single column testing machine, to which the custom made jig was attached.



Figure 8-9: The buccal aspect of the right mandible after application of the bis-acrylic composite on the lingual and the buccal aspect of the teeth. The bis-acrylic is applied in such a way to completely cover the exposed interdental wire with as little as possible on the buccal aspect of the first molar.

The resistance of the construct to the force was measured in Newton (N) using a load transducer. Ventral displacement of the rostral segment (between the canine and the 3rd incisor) was calculated as the displacement of the actuator during testing. Data were recorded at a frequency of 10 Hertz using commercial software (Matlab R2012a, Mathworks, Natick, Massachusetts, USA) and exported into a spreadsheet program (Excel 2010, Microsoft, Redmond, Washington, United States) for further processing.

All mandibles were tested until failure. The failure point was defined as the point when the interdental wire or the composite fractured or whenever the composite detached from the tooth surface. Force-displacement curves were constructed for each mandible and the ultimate force (N at the point of failure), stiffness of the construct (N per meter of displacement, measured in the linear portion of the force-displacement curve), total displacement (total mm of displacement from start until failure) and total energy absorbed during testing of the mandible (area under the curve) were calculated. The total energy absorbed by the construct was calculated by the sum of the areas by using the trapezoidal rule of numerical integration.

During cantilever loading in a gap model, a low-stiffness phase can be recognized on the initial part of the force-deformation curve. The initial phase was included in the calculation of the ultimate force, total displacement and the total energy absorbed.

8.3 Statistical analysis

For evaluation of the data for the retrospective study, categorical data was evaluated using Pearson's Chi-square test and continuous data using the paired t-test. The age groups in that study were compared to studies done by *Umphlet et al.* (1990) and *Lopes et al.* (2005) by calculating the coefficient of determination (R^2). Breeds presented to the DMSC for mandibular fractures were compared to the entire patient population for the same time periods. Test statistics were performed to evaluate whether certain breeds were presented more than expected. All calculations were done using commercial spreadsheets (Excel 2010, Redmond, Washington, United States).

For evaluation of the data for the biomechanical study, the Akaike information criterion corrected for finite small samples sizes was used to compare models of time of application for the techniques, to combinations of patient signalment, weight, and clinician experience (with subsequent applications). The Wilcoxon signed rank test was used to analyse the differences between the RIC and the RIS group of paired data (time of application, composite weight, ultimate force, S, total displacement and total F absorbed). The influence of the composite weight on the ultimate force, S and total F absorbed was tested using the Pearson correlation test. Values between -0.8 and -1 and +0.8 and +1 were considered strong negative and positive correlations respectively. Mann-Whitney U test was used to determine whether there were statistical significant differences in the ultimate force and the stiffness between the failure patterns. A p value < 0.05 was considered significant

9 RESULTS

9.1 Retrospective study of mandibular fractures

The case records of 119 dogs presented between January 2001 and December 2009 were identified and reviewed. Due to incomplete records 10 patients were excluded. A total of 135 mandibular fractures were present in the 109 dogs included in this study.

Fifty-seven percent of the dogs were under the age of twelve months at the time of fracture management (Figure 9.1). In this age group, males (n=32) and females (n=29) were almost equally represented. ($\chi^2=0.067$, $p=0.80$). In the patients older than twelve months, a male: female ratio of 1.9:1 was observed although the sex differences were not statistically significant ($\chi^2=3.000$, $p=0.08$). In this group of patients, 69% of the males and 6.25% of the females were entire. The age distribution in the current study compares more closely to the findings of the study done by *Umphlet et al.* (1990) ($R^2=0.92$) than to the one done by *Lopes et al.* (2005) ($R^2=0.34$).

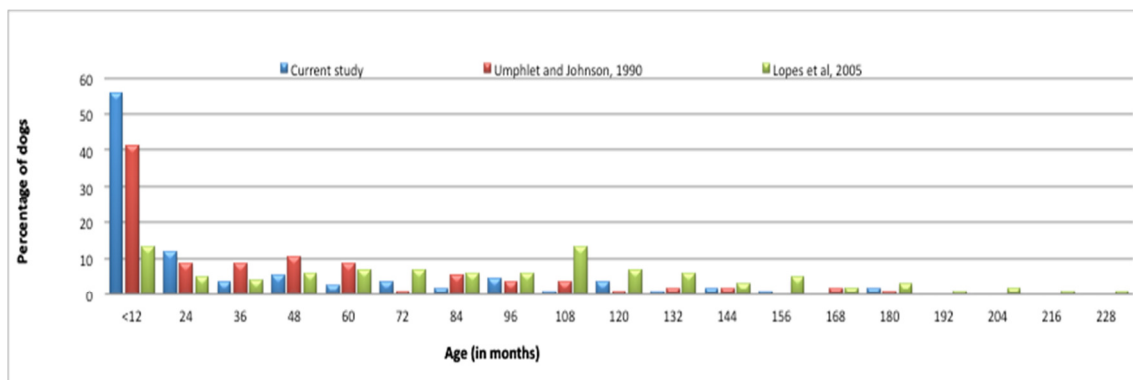


Figure 9-1: The age distribution of the 109 patients presented to the DMSC. Age distributions extracted from *Umphlet et al.* (1990) and *Lopes et al.* (2005) are provided.

A high incidence of mandibular fractures was noted in small breed dogs (77/109; 70.6%). The mean body weight of patients in this study was 6.46 kg (SD \pm 5.4 kg) and the median 5.2 kg. Of the total dog population that was presented to the OVAH during the same period, 1023/2321 (44.1%) were small breeds. The five breeds that had the highest incidence of mandibular fracture were: Yorkshire terriers (16%),

Dachshunds (14%), Jack Russell Terriers (11%), Maltese (10%) and Pekingese (6%). These breeds made up 15%, 24%, 11%, 21% and 2% respectively of the total patient population presented to the OVAH (Figure 9.2). Test statistics revealed that only Pekingese dogs were presented more than expected ($p=0.001$).

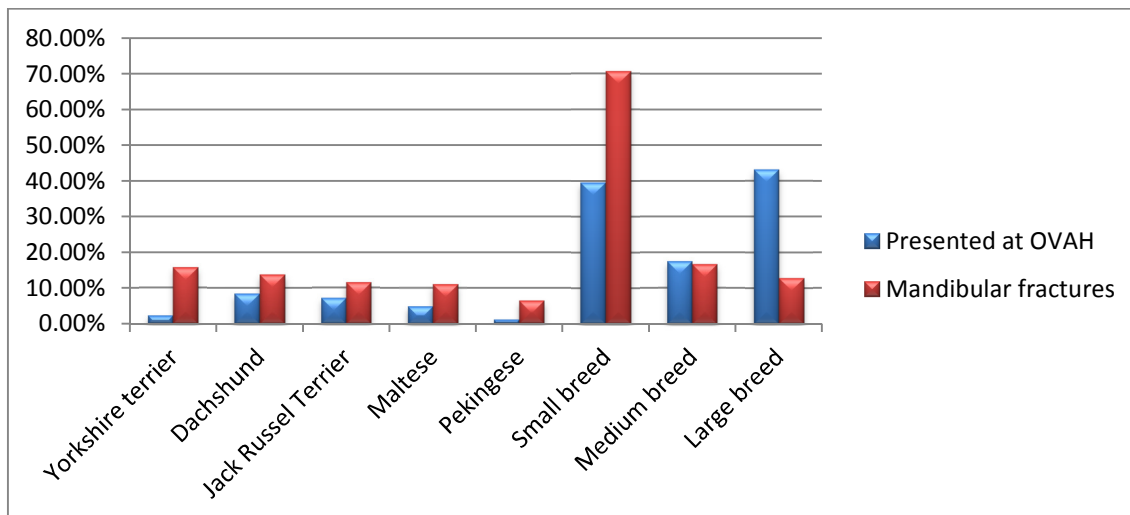


Figure 9-2: Most commonly presented breeds with mandibular fractures compared to population presented to OVAH during the same time period.

Large breed dogs older than 8 months of age only made up 6% of the study population. Dog fights were the most common aetiology (68/109) of mandibular fractures in this study (Figure 9.3). The patients with aetiologies that did not fit into any of the groups were classified as “other”. In this group, mandibular fractures due to gunshot ($n=3$), pig bite ($n=1$), kick from a horse ($n=1$), hit with a metal pole ($n=1$), run over by a wheelbarrow ($n=1$), and chewing on a hard object in the absence of pathology ($n=1$), were included. Only one mandibular fracture was caused iatrogenically during extraction of teeth. This fracture was subsequently classified as pathologic due to the radiographic presence of alveolar bone lysis. Pathologic fractures also occurred in three other dogs.

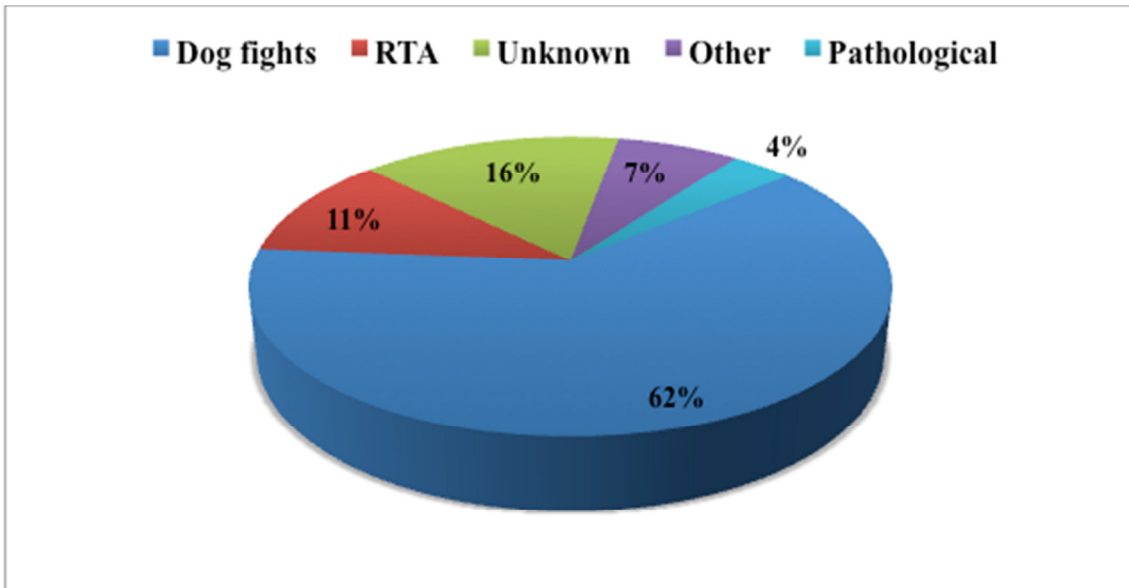


Figure 9-3: Fracture aetiology of the 109 dogs presented to the DMSC. (RTA= Road traffic accident)

The incidence of mandibular fractures was highest in the molar region (Figure 9.4). Anatomical distribution of mandibular fractures were similar to that noted in two other studies (16, 51).

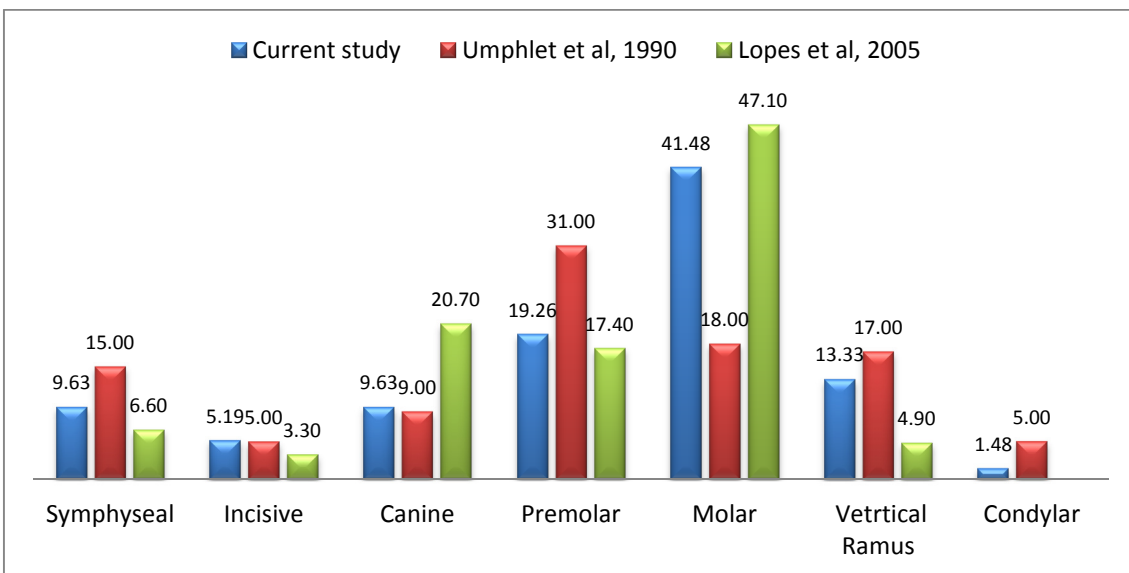


Figure 9-4: A comparative presentation of fracture frequencies in the various anatomical locations of the mandible.

Of the 135 fractures, 104 were open (Figure 9.5). There was a high incidence of open fractures in the dentate portion of the mandible (87/104). The fracture type was

transverse in 73, short oblique in 48, oblique in 1, comminuted in 11 and incomplete in 2 of the cases. The fractures were relatively unstable in 116/135 and displaced in 112/135. Almost three quarters of the fractures extended through the alveolus of one or more teeth. A total of 124 teeth were involved in the fracture line with the first molar predominating (Figure 9.6).

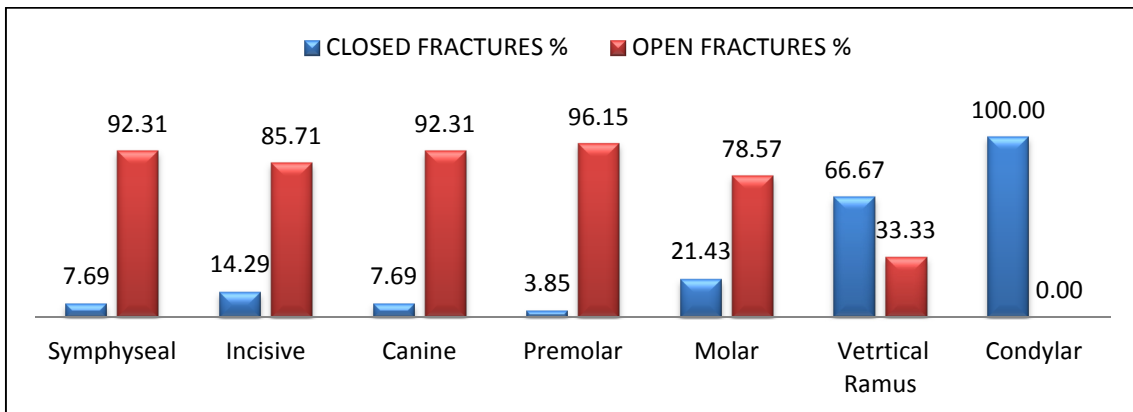


Figure 9-5: The incidence of open or closed fractures based on the anatomical locations involved.

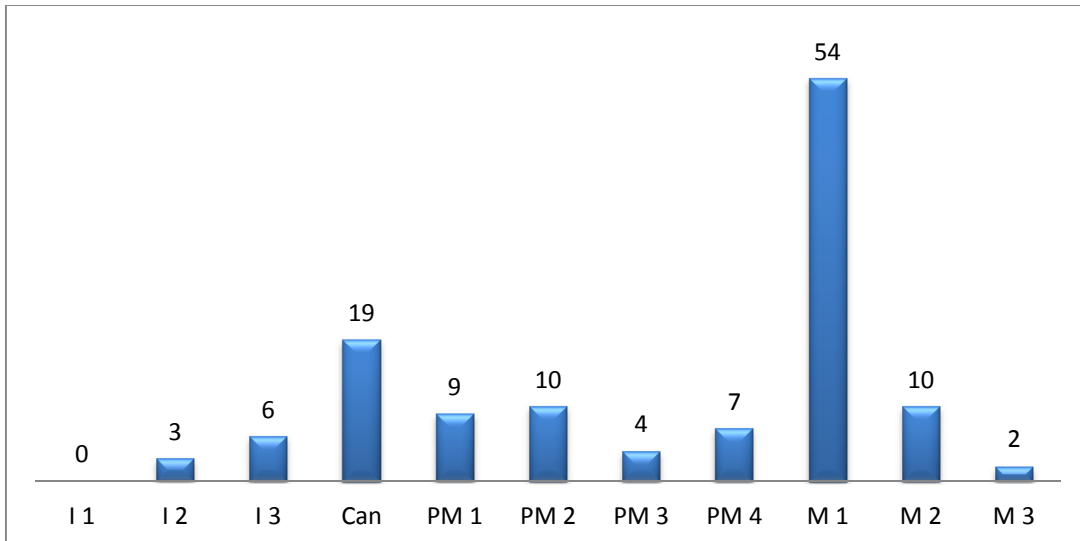


Figure 9-6: Regional distribution of the 124 teeth in the fracture line of 109 dogs with 135 mandibular fractures.

In small breed dogs, fractures of the molar, premolar and symphyseal regions predominated compared to large breed dogs where fractures of the ramus, incisive,

canine region and condylar process were more common (Chi-square test, $X^2=23.73$, $p=0.02$).

Contingency tables also showed that aetiology was associated with fracture type (Chi-square test, $X^2=30.27$, $p=0.02$) and anatomical location (Chi square test, $X^2=36.36$, $p=0.05$). Higher than expected incidences of short oblique fractures in the canine and premolar regions, incomplete fractures of the ramus region and transverse fractures of the condylar process were noted when the fractures occurred as a result of RTA.

Multiple mandibular fractures were present in 24 (22%) of the patients. The multiple fractures included fractures involving both mandibles ($n=14$), multiple fractures with non-communicating fracture lines of one mandible ($n=3$) and mandibular fractures together with symphyseal separation ($n=7$). Two thirds of these patients were presented after a dogfight.

9.2 Reinforced interdental crossover composite splint as a non-invasive mandibular fracture repair technique

Subjectively the RIC was the easier to apply and the techniques used in preparation of the buttons were easy to master. The RIS caused extensive soft tissue disruption and damage during the subgingival application of the interdental wire. Application and tensioning of the interdental crossover wire in this osteotomy model was also convenient.

9.3 Comparative biomechanical study

The breeds included in the study were Jack Russell terrier (n=2), crossbreed (n=2), Dachshund (n=1) and Maltese (n=1). Males and females were equally represented, and the mean weight was 5.68 kg (± 0.87). The Akaike information criterion indicated, that gaining experience in either technique, was the only factor that explained the variance in times between subsequent applications ($p=0.01$) of RIC or RIS were not significantly different ($p=0.97$).

All the implants failed by fracturing of the composite over the fracture site (n=8) or by lifting off the enamel surface at the 1st molar (n=4) without breakage of the interdental wire (Figure 9.7). When comparing the failure pattern between the two groups, 1/6 of the RIC and 3/6 of the RIC group failed by the composite lifting of the enamel surface of the first mandibular molar. No significant differences were noted when the ultimate force and stiffness were compared between these two failure pattern groups ($p=0.80$ and $p=1.00$). With both of these failure patterns the interdental wires were still in the position that they were surgically placed. No fracture or detachment of the “buttons” could be observed. No visual signs of 1st molar fracture or avulsion was noticed during the study.

Macroscopically, breakage or lifting off the enamel surface was first noticed on the lingual aspect preceding either breakage or lifting off the buccal aspect in all mandibles. Preceding the failure, a small amount of buccal rotation of the rostral segment together with dorsal opening of the osteotomy site was noted

The ultimate force and stiffness (S) were the only two variables that were significantly different between the two techniques (both $p=0.03$). The mean ultimate force was 80.50 N (± 40.29) and 58.70 N (± 41.75), whereas the mean S was 16.19 N/mm (± 4.38) and 9.91 N/mm (± 4.03) for the RIC and RIS respectively.

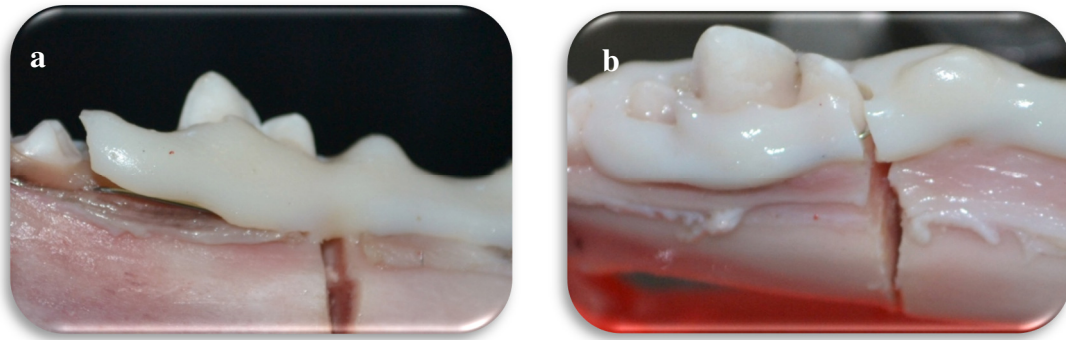


Figure 9-7 a,b: Pictures indicating the patterns of failure, either bis-acrylic composite breakage (a) or lifting of the enamel surface of the tooth (b). Although not visible in this photograph the imbedded interdental wire was still intact. Rostral is to the right.

The amount of BAC used during application of the reinforced splints was not statistically different between the two techniques ($p=0.66$). For both the RIC and RIS there were no correlation between the amount of BAC and the ultimate force (-0.02 and +0.14), stiffness (-0.06 and -0.07) or the total energy absorbed (+0.05 and +0.18).

Table 9-1: Patient and biomechanical testing data. (RIS= Reinforced Interdental Stout loop composite splint, RIC= Reinforced Interdental Crossover composite splint, s= seconds, CCR= Chemical cure Composite Resin, g=gram, N= Newtons, N/mm= Newton per millimeter, mm= millimeter, N.mm= Newton millimeter)

Sample number	Technique	Time (s)	CCR (g)	Ultimate force (N)	Stiffness (N/mm)	Total displacement (mm)	Total energy absorbed (N.mm)
1R	RIS	1083	3,20	46,27	11,01	4,95	82,86
2L	RIS	1171	3,80	35,34	9,68	4,15	58,23
3L*	RIS	976	3,90	135,79	11,05	13,98	869,22
4L	RIS	733	4,00	72,90	15,85	5,69	176,35
5R	RIS	700	3,90	18,11	3,51	5,42	61,80
6L	RIS	735	4,10	43,79	8,36	5,69	119,64
Mean ± Standard deviation		899,67 ± 203,87	3,82 ± 0,32	58,70 ± 41,75	9,91 ± 4,03	6,64 ± 3,64	228,02 ± 317,20
Sample number	Technique	Time (s)	CCR (g)	Ultimate force (N)	Stiffness (N/mm)	Total displacement (mm)	Total energy absorbed (N.mm)
1L	RIC	1050,00	3,50	83,72	18,81	5,01	174,00
2R	RIC	926,00	3,60	55,41	18,25	3,41	78,12
3R*	RIC	929,00	3,80	139,67	17,91	8,09	629,69
4R*	RIC	888,00	3,90	118,95	16,46	7,89	448,17
5L	RIC	806,00	3,80	27,56	7,40	3,81	44,74
6R	RIC	759,00	4,20	57,69	18,32	3,14	91,46
Mean ± Standard deviation		893,00 ± 102,55	3,80 ± 0,24	80,50 ± 42,29	16,19 ± 4,38	5,23 ± 2,24	244,36 ± 239,10

10 DISCUSSION

Previous studies found that mandibular fractures account for 1.6 to 6% of all fractures in dogs that were presented to veterinary hospitals (49, 50). In published studies main aetiologies for mandibular fractures include RTA, falls from height, projectile injuries, unknown trauma and dog fights (16, 50, 51). In this study dog fights were more frequently the cause of mandibular fractures (62%) than has been previously reported (19%–43%) (16, 51).

During dog fights, the head and neck are frequently targeted areas (71). The relative sizes of the victim and the attacker play a significant role in the severity of bite wounds (71). As the size of the animal increases so does its biting force (72). The width of the gape also increases as the size of the dog increases which makes it impossible for small breed dogs to fit the muzzle of a larger breed in their mouth to apply the biting forces. Large breed dogs like Boerboels (Bullmastif like breed) and multi-dog households (especially mixed large and small breed) in the Onderstepoort area are factors that might explain the higher incidence in this study. It is the authors' opinion that owners in the Onderstepoort region prefer to keep larger guard dogs on their properties together with smaller pets. Small breed dogs less than 12 months of age were the most common size and age group affected (Figure 9.1). As dogs mature the bone mineral content, and thus its density, increases (73). Therefore, young dogs may be overrepresented as they have a relatively low bone density predisposing the bone to failure (74). In addition to this younger dogs still need to find their place in the social hierarchy and are frequently “reprimanded” by older dogs.

Pekingese dogs were presented more than was expected in this study. It is uncertain whether their particular brachycephalic like anatomy, behaviour or personality predisposes them to mandibular fractures. Further studies would be needed to clarify this.

Of the patients older than 12 months, uncastrated male dogs were overrepresented (69%). When compared to castrated males, uncastrated male dogs are involved in more incidents of aggression and roam more frequently (75, 76). Roaming will increase the frequency of contact with other dogs and with motor vehicles.

Considering the fact that the incidence of RTA was low in this study other factors like castration later in life might contribute to this finding. Dogs are generally castrated at 3-6 months of age. A large amount of dogs in this age group might also skew the results falsely increasing the amount of non-castrated dogs.

On evaluation of pre-operative radiographs, only a few patients (4) had lysis of the alveolar bone. In the mandible, pathological fractures occur most frequently in the area of the first molar as most of the cases of severe periodontitis and peri-apical pathology are found in this region (53). This was also seen in the present study where all the pathological fractures involved the mandibular first molar. In published reports small breed dogs have more severe periodontal disease (53). Periodontal tissue detachment (5 mm from the furcation apically) potentially causes disruption of 44.6% of the attachment area of the first mandibular molar (54) and may lead to tooth loss and tooth root pathology, potentially predisposing dogs to mandibular fractures, even if subjected to minor trauma. The molar region was also the most commonly involved region for fractures without any pre-existing pathology. Pathology in this region can potentially further weaken an area that is already mechanically inferior. One patient with periodontal disease experienced a mandibular fracture during tooth extraction prior to referral. Identifying periodontal disease on pre-extraction radiographs might have prevented this fracture by being more careful during the extractions.

The roots of the mandibular first molars of small breed dogs are larger in length relative to the height of the mandible and their roots extend ventral to the mandibular canal when compared with larger breeds of dogs (52, 53). This ratio can act as stress risers, potentially explaining the high incidence of molar region fractures in this study. The stress rider is likely due to the differences in the stiffness between tissues like the alveolar bone, cementum and the periodontal ligament may contribute.

Of all the fractures that occur in the molar region, the first mandibular molar was involved in nearly all the cases (53/56). Fractures through the alveolus of the first mandibular molar might also be related to early periodontitis that results in weakening of the alveolus and periodontal ligament. This weakening might be the result of periodontal ligament destruction that is not radiographically visible or appreciated on clinical examination.

The nature of the applied F may have had an influence on the type and location of the fractures in our study as biting wounds can be associated with compressive but also torsional forces. The low incidence of mandibular fractures through the condylar process was a finding that was similar to another study (16). Research has shown differences in the indentation modulus of the condyles in young and adult dogs (77). It is unknown whether this difference, due to ageing, is clinically relevant. During mastication, the shearing action of the carnassial teeth in dogs requires a mild amount of transverse movement of the condyles (78). This minimal movement in the joint and the protective effect of the masticatory muscles might be enough to absorb the forces and thus decrease the incidence of fractures of the condyles. Due to the low number of condylar fractures no significant conclusion could be drawn from the fracture types seen in this region. It is the researchers opinion that due to the shape of the condyle in dogs it offers more resistance to bending in a dorsal plane than the mandibular body, which might also contribute to the lower incidence of condylar region fractures.

The presence of teeth influences the fracture line direction as the fracture line will follow the route of least resistance, resulting in fractures along the tooth roots (14). Likewise the *synchondrosis intermandibularis* is the weakest area in the symphyseal region as it is composed of fibrocartilage (9). In this study separation of the *synchondrosis intermandibularis* was classified as transverse fractures through the symphyseal region. The incidence of transverse fractures through the symphyseal region was high in this study.

The protective and supporting effect of the caudal masticatory muscles probably resulted in the high incidence of incomplete, closed and non-displaced fractures in the ramus region.

Mandibular fractures in the dentate portion of the mandible were mostly open. Only a thin layer of gingiva covers these regions of the mandible orally and displacement of the fracture fragments and the fragments sharp edges will easily disrupt the gingiva.

After identifying the most commonly presented fracture morphology, a simple transverse fracture was mimicked in canine cadavers by creating a transverse osteotomy

just rostral to the 1st mandibular molar that was then corrected by interdental reinforced composite splints. Mandibular fractures can be treated by conventional osteosynthesis or by non-invasive techniques (11). Several surgical procedures have been described for the management of mandibular fractures, including interdental wiring, inter-fragmentary wires, external skeletal fixators and plating (12, 20, 56-59, 63, 67, 79, 80). Due to the anatomical differences between long bones and mandibles, additional factors need to be considered whenever surgery (and in particular conventional osteosynthesis) is planned (9, 14, 55, 56). An important consideration is the presence of the alveolar canal in the ventral third of the mandibular body. It contains the inferior alveolar nerve, the mandibular alveolar artery and the mandibular alveolar vein (41, 42). The mandibular artery provides the main blood supply to the teeth and contributes significantly to the vascular supply to the alveolar bone.

Severance of this artery during trauma makes the bone fragments largely reliant on the surrounding soft tissue for their blood supply until the blood supply is re-established as is seen during long bone fractures (41-43). Additionally, multiple foramina are present in the mandible. These foraminae are located on the rostrolateral (mental foramina) and the caudomedial aspect (mandibular foramen) of the mandibular body and should, like the alveolar canal, be avoided during implant placement (14, 41).

The principle of interdental splinting was introduced many decades ago to overcome the limitations of the other means of fracture stabilisation of the canine mandible (81). Currently, an uncertainty still exists in the number of teeth that should be incorporated when applying an interdental wire and/or composite in canine mandibular fracture repair. In the literature one can find the recommendation to include at least two teeth rostral and two teeth caudal to the fracture site (56). To the authors' knowledge, however, there are no studies substantiating this recommendation or whether the number varies according to the anatomical location of the mandibular fracture. For this study the researchers chose to include only one single tooth caudal to the fracture site. The mandibular 1st molar has two roots and a relatively extensive surface area of attachment compared to the premolars and incisors. The teeth rostral to the 1st molar have a conical shape and for this reason the authors elected to include all the teeth up to the base of the canine which is around which the wire could be anchored.

Although not specifically evaluated in this study, the 1st molar did not show any visual signs of avulsion or fracture at the time of failure of the composite in any of the tested mandibles. Unfortunately no post testing radiographs were taken to assess the integrity of the tooth roots and alveoli.

During testing a small amount of buccal rotation of the rostral segment together with dorsal opening of the osteotomy site was noted (Figure 10.1). Lifting of the acrylic off the enamel surface of the teeth on the lingual aspect preceded fracture of the composite or lifting off the buccal aspect. The breakage or lifting off the lingual aspect was not clearly presented on the force-displacement curve. This displacement was a direct result of the anatomical shape of the mandible, the absence of the contralateral mandible, the position during testing and the location of the applied F in these samples. The authors feel that this resulted in more tension on the lingual aspect what could explain the observed failure pattern. It is difficult to judge to which extent rotation of the rostral fragment will occur during loading of a stabilised mandibular fracture in a clinical situation.

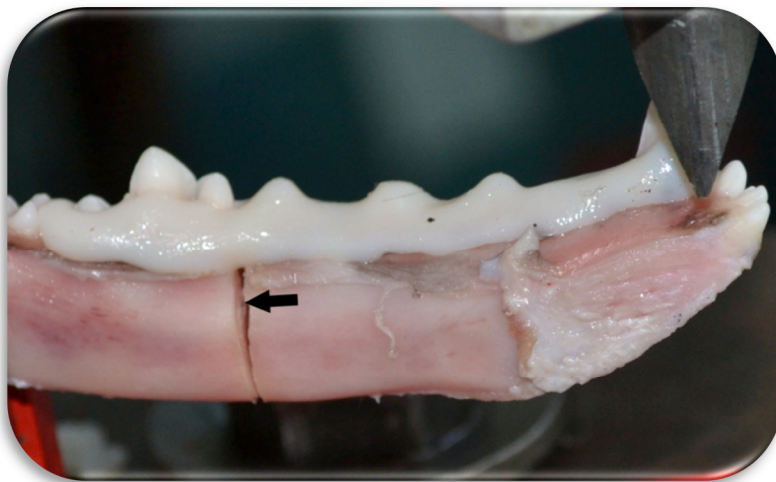


Figure 10-1: Photograph showing the lingual aspect of the mandible during testing. Note slight buccal rotation of the rostral segment characterised by the increase visibility of the caudal segments lingual cortex (black arrow).

The time for application was not different between the RIC and the RIS. Although a lot of time was consumed by constructing the “buttons” in the RIC group, this time loss

was compensated by the relatively easy application of the interdental wire for the RIC as compared to the more elaborate wire application for the RIS. The strict case selection criteria resulted in the sampling of mandibles that were roughly equal in size creating an almost homogenous population of mandibles and thus the time for application was not affected by the weight of the donors. Throughout this study the experience increased and the time of application decreased for both techniques. In this experimental setting, however, the artificially prepared fracture was standardised for all mandibles. The surgeon in practice, to the contrary, will face different fracture conformations and often these will be accompanied by other dental pathologies that make the application of the splinting techniques more challenging.

On average the ultimate force for the specimens tested was almost 40% more in the RIC when compared to the RIS. When applying the RIC, compomer buttons were bonded to the enamel surface of the teeth. Although the bonding agent does not seem to enhance the bonding of the chemical cure composite resin to the enamel surface (68), the presence of “buttons” attached onto the bonding agent could interdigitate with the composite, potentially creating a stronger bond. When comparing the failure pattern between the two groups, 3/6 of the RIS and 1/6 of the RIC group failed by the composite lifting of the enamel surface of the first mandibular molar. Although differences occurred in failure no differences were noted when the stiffness and ultimate force of these two groups were compared. The presence of the buttons might have caused a decrease in the incidence of RIC failing by composite lifting off the enamel surface of the tooth due to an increased bonding strength. Acrylics do not adhere well to metal but they do conform to and interdigitate with the wire twists (45). The subgingival course of the RIS could result in less of the “tensioned” wire incorporated in the reinforced composite splint, resulting in lesser load to be shared by the interdental wire during the initial phases of testing. Although the difference was small, these same reasons could also explain why the RIC was stiffer during testing. The stiffer the material the more F it will absorb and the less it will displace (27).

Biomechanically, bis-acrylic compounds are classified as brittle materials because they have no well-defined yield point that indicates the transition between the elastic and plastic phases of the material (82, 83). There is in fact a distinct fracture

point that coincides with the ultimate force (82, 83). On evaluation of the results, three sets of data i.e. 3L, 3R and 4R showed a high of displacement, ultimate force and total energy absorbed, when compared to the other datasets. Considering the brittle nature of the BAC the displacement in these samples seems excessive. It is uncertain whether failure of the construct occurred before the point, which was identified as the ultimate force, although no indication of such failure was visible on evaluation of the force displacement curves.

The individual mandibles had no support from the contralateral mandible during testing, dissimilar to the clinical situation. A wide range of ultimate forces was encountered for both treatment groups, although the dogs were more or less of the same age and body weight. The differences in the anatomy between breeds and individuals can explain this variance. Factors like the moment arm and the dorsoventral height of the mandibular body at the fracture location can affect the way that the specimen responds to the force applied to the rostral mandible (3). Neither of these factors correlated with the ultimate force for the RIC or RIS (data not shown)

The amount of BAC used during application did not affect any of the variables and did not differ between the two techniques. An attempt was made to only lightly cover the wire. In clinical cases excessive BAC is burred away especially on the buccal aspect of the 1st molar as it might interfere with the 4th maxillary premolar upon closure of the mouth (56). The author feels that application of the composite on the buccal aspect of the 1st molar is necessary. This will make the postoperative care more efficient as it decreases the entrapment of food on foreign material like hair between the wire and the teeth. Further studies are warranted to identify whether local removal of BAC at the buccal side has an effect on the biomechanical properties of the interdental composite splints tested in this study.

The buccal aspect was selected for the compomer “buttons” (RIC) because it was thought to allow an easier application in clinical patients. As mentioned earlier for the BAC, however, a buccal “button” can potentially interfere with the 4th maxillary premolar during closure of the mouth. Due to the rotation of the rostral fragment during loading, the interdental wire is presumably under more tension on the lingual aspect of the 1st molar than on the buccal side. This can result in a greater tendency to displace

dorsally and might contribute to failure of the BAC. Although it is uncertain to which extent rotation occurs in clinical cases, there are arguments to prefer one compomer button on the lingual aspect of the 1st molar and another on the buccal aspect of the 4th premolar in the RIC. “Buttons” in these positions will probably provide more resistance against dorsal slippage of the wire during loading, besides the clinical advantage of not interfering with full closure of the mouth.

During preparation of the model, a small gap was created between the cortices of the rostral and caudal segments. This resulted in phase on the force displacement curve that represents the time taken for soft tissue displacement by the indenter and time until the ventral cortices of the two opposing segments made contact. Although the ventral aspects of the cortices made contact early during the loading process, it is uncertain whether this gap might affect the performance of the reinforced interdental composite splints during loading or during cyclic loading as is expected in clinical patients. To clarify this and to assess whether the placement of “buttons” on the lingual and buccal aspect of the teeth has an effect on the parameters tested in this study, further biomechanical studies would be necessary.

11 CONCLUSION

Screening of this patient population did inspire the selection a model for recreating the most commonly occurring fracture in dog presented to a referral practice in South Africa. Small breed dogs and dogs less than 8 months of age predominated (102/109). Dog fights were the most common aetiology in this study (68/109). The molar region was the most commonly affected region (56/135). Evaluation of the radiographs revealed that transverse (73/135), relatively unstable (116/135) and displaced (112/135) fractures were the most common. The majority of fractures involved teeth in the fracture line (100/135), with the first molar frequently involved (54/135). The majority of fractures were open (104/135).

The null hypothesis was rejected because there was evidence that in experimentally fractured mandibles of young adult dogs there is evidence that the RIC is biomechanically superior to the RIS. Further *in vitro* and *in vivo* studies should be conducted to assess whether RIC is a good alternative for clinical cases as the established procedures for mandibular fracture fixation in small animals.

- 1 12 ADDENDUM
- 2 12.1 Addendum 1: Permission for euthanasia, study and research purposes
- 3 12.1.1 Patient 1

**UNIVERSITY OF PRETORIA
FACULTY OF VETERINARY SCIENCE
ONDERSTEPSPOORT VETERINARY ACADEMIC HOSPITAL**

TRANSFER FORM N^o 28933

From Clinic: OP To: Tropical Diseases
 Pathology
 Other

STICKER OR
Patient: Banner Date: 17/10/19
Patient Number: Owner Address: n-9 la Catura
Species: Canine Alberius str 243
Breed: Jack Russel Sex: M Age: 1yr la Montagne
Owner: Jacques Pieterse Owner Tel: 082 381 2860
Owner number:

Specimen: Carcass
History: Anaemic weight loss vomiting collapsed
No money to Rx euthanized suspected Parvo

Examination required:

Diagnostic Pathology	Tropical Diseases
<input checked="" type="checkbox"/> PM Small animal	<input type="checkbox"/> Bacteriology - Aerobic <input type="checkbox"/> Anaerobic <input type="checkbox"/>
<input type="checkbox"/> PM Large animal	<input type="checkbox"/> Antibigram
<input type="checkbox"/> PM Insurance Case	<input type="checkbox"/> Fungal Culture
<input type="checkbox"/> Histopath Biopsy	<input type="checkbox"/> Virus Isolation
<input type="checkbox"/> IFA	<input type="checkbox"/> EM
<input type="checkbox"/> IMP first section	<input type="checkbox"/> FIV/FIP
<input type="checkbox"/> IMP additional section	<input type="checkbox"/> FIV Antigen
<input type="checkbox"/> HE stained sections	<input type="checkbox"/> FeLV
<input type="checkbox"/> Special stains	<input type="checkbox"/> IgM IgG antibodies
	<input type="checkbox"/> Mycoplasma Culture

Other (please specify):

Fees levied: R Fund case: Yes No

Clinician signature: L. Anon Print: L. Anon

Clinician contact tel no: Clinician pager no:

Preliminary/Final result: Reference No
Date: Signed:

100 UNIVERSITEIT VAN PRETORIA
UNIVERSITY OF PRETORIA
YUNIBESITHI YA PRETORIA

PERMISSION FOR EUTHANASIA/POST MORTEM/DISPOSAL OF REMAINS

Euthanasia N^o 3465

Owner: Jacques Pieterse ID Number: 515120504080
Name of animal: Banner Male/Female: Male
Species: Canine Breed: Raschund
Age: 1 year Colour: Brown
Brief reason for euthanasia: anaemia weight loss vomiting collapsed
suspected Parvo No money to Rx euthanized

Post Mortem (all costs include VAT)
A post mortem examination may provide essential scientific information plus serve as a valuable training opportunity for students.

Dog/cat	Yes	No	R 108.00
Horse	Yes	No	R 180.00
Foal	Yes	No	R 130.00
Horse (for insurance purposes)	Yes	No	R1 300.00
Permission granted for student training	<input checked="" type="checkbox"/>	No	No charge
No post mortem allowed	Yes	No	

Disposal (all prices include VAT)

Dogs/cats/small exotics

Communal burial	<input checked="" type="checkbox"/>	No	R 40.00
Communal incineration (Enviroclin)	Yes	No	R 200.00
Individual incineration (return of ashes by Enviroclin)	Yes	No	R 935.00
Removal of body by client	Yes	No	No charge

Horses/ponies/donkeys/foals

Communal burial	Yes	No	R 68.00
Individual incineration (Faculty premises)	Yes	No	R 12.70 per kg
Return of ashes in small wooden casket	Yes	No	R 168.00
Return of ashes in a ± 60 litre receptacle	Yes	No	No charge

Please note:
Incineration may be mandatory if post mortem findings indicate the presence of a potentially contagious disease
Ashes will be returned by Enviroclin within approximately 14 days, and will be available for your collection for a period of 90 days. Thereafter uncollected ashes will be disposed of.

Client signature: Jacques Pieterse Date: 17/10/2019
Clinician's name/signature: L. Anon
Students' name/signature: Melina Joans H. Joans

FOR OFFICE USE ONLY

Clinic:
Contact Person: Ext:
Patient name:
Patient number:

OR PLACE STICKER HERE

5 12.1.3 Patient 3

**UNIVERSITY OF PRETORIA
FACULTY OF VETERINARY SCIENCE
ONDERSTEPSPOORT VETERINARY ACADEMIC HOSPITAL**

TRANSFER FORM N° 26721

From Clinic: CP To: Tropical Diseases
 Pathology
 Other

STICKER OR Patient: Sheepcase Date: 21/10/10

Patient Number: _____ Owner Address: _____
Species: Cat
Breed: Scottish Fold Sex: ♂ Age: 1/2
Owner: _____ Contact Tel: _____

Examination required:

Diagnostic Pathology	Tropical Diseases
<input type="checkbox"/> PM Small animal	<input type="checkbox"/> Bacteriology - Aerobic <input type="checkbox"/> Anaerobic <input type="checkbox"/>
<input type="checkbox"/> PM Large animal	<input type="checkbox"/> Antibiogram
<input checked="" type="checkbox"/> PM Insurance Case	<input type="checkbox"/> Fungal Culture
<input type="checkbox"/> Histopath Biopsy	<input type="checkbox"/> Virus Isolation
<input type="checkbox"/> IFA	<input type="checkbox"/> EM
<input type="checkbox"/> IWP first section	<input type="checkbox"/> FIV/FIP
<input type="checkbox"/> IWP additional section	<input type="checkbox"/> FIV Antigen
<input type="checkbox"/> HE stained sections	<input type="checkbox"/> FeLV
<input type="checkbox"/> Special stains	<input type="checkbox"/> IVDG antibodies
	<input type="checkbox"/> Microscopic Culture

Other special stains: _____
 Post mortem: Yes No
 Signature: _____
 Date: 21/10/10 Signed: _____

100 UNIVERSITEIT VAN PRETORIA
UNIVERSITY OF PRETORIA
YUNIBESITHI YA PRETORIA

PERMISSION FOR BIRTHANALISA/POST MORTEM/EXAMINAL OF SPECIMENS
N° 4419

Owner: Sheepcase ID Number: _____
 Name of animal: Sheepcase Species: Cat
 Breed: Scottish Fold Age: 1/2
 Date of return for examination: 21/10/10 Reason for examination: Insurance claim

Post Mortem (all costs include VAT)
 A post mortem examination may provide essential scientific information plus serve as a valuable training opportunity for students.

Dog/cat	<input type="checkbox"/> Yes <input type="checkbox"/> No	
Horse	<input type="checkbox"/> Yes <input type="checkbox"/> No	
Foal	<input type="checkbox"/> Yes <input type="checkbox"/> No	
Horse (for insurance purposes)	<input type="checkbox"/> Yes <input type="checkbox"/> No	No charge
Permission granted for student training	<input type="checkbox"/> Yes <input type="checkbox"/> No	
No post mortem allowed	<input type="checkbox"/> Yes <input type="checkbox"/> No	

Disposal (all prices include VAT)

Deep pit/soil sealer	<input type="checkbox"/> Yes <input type="checkbox"/> No	
Communal burial	<input type="checkbox"/> Yes <input type="checkbox"/> No	
Communal incineration (Eurodrin)	<input type="checkbox"/> Yes <input type="checkbox"/> No	
Individual incineration (return of ashes by Eurodrin)	<input type="checkbox"/> Yes <input type="checkbox"/> No	No charge
Return of body to owner	<input type="checkbox"/> Yes <input type="checkbox"/> No	
Return of body to owner (Eurodrin)	<input type="checkbox"/> Yes <input type="checkbox"/> No	
Return of body to owner (Eurodrin)	<input type="checkbox"/> Yes <input type="checkbox"/> No	
Return of body to owner (Eurodrin)	<input type="checkbox"/> Yes <input type="checkbox"/> No	
Return of body to owner (Eurodrin)	<input type="checkbox"/> Yes <input type="checkbox"/> No	

Signature: _____ Date: 21/10/10

OR PLACE STICKER HERE

6 12.1.4 Patient 4

**UNIVERSITY OF PRETORIA
FACULTY OF VETERINARY SCIENCE
ONDERSTEPOORT VETERINARY ACADEMIC HOSPITAL**

TRANSFER FORM N^o 29502

From Clinic: OP To: Tropical Diseases
 Pathology
 Other

STICKER OR Patient: Surgery Date: 06/05/2011
Patient Number: 240634 Owner Address: _____
Species: Cat Breed: Siamese Sex: _____ Age: 7 months
Owner: Zebillon Owner Tel: _____
Owner number: _____

Specimen: Sweas
History: Very bad condition - multiple skin lesions in axilla

Examination required:
Diagnostic Pathology PM Small animal
 PM Large animal
 PM Insurance Case
 Histopath Biopsy
 IFA
 IMP first section
 IMP additional section
 HE stained sections
 Special stains

Tropical Diseases
 Bacteriology - Aerobic Anaerobic
 Antibigram
 Fungal Culture
 Virus Isolation
 EM
 FIV/FIP
 FIV Antigen
 FeLV
 IgM IgG antibodies
 Mycoplasma Culture

Required Optional
Requested by Clinician

Other (please specify): _____
Fees levied: R _____ Fund case: Yes No
Clinician signature: _____ Print: _____
Clinician contact tel no: _____ Clinician pager no: _____
Preliminary/Final result: _____ Reference No _____
Date: _____ Signed: _____

100
UNIVERSITEIT VAN PRETORIA
UNIVERSITY OF PRETORIA
YUNIBESITHI YA PRETORIA

PERMISSION FOR EUTHANASIA/POST MORTEM/DISPOSAL OF REMAINS
N^o 5330

Euthanasia
Owner: ZEBILLON ID Number: 6608075933089
Name of animal: Cat Male/Female: Female
Species: Siamese Breed: Siamese
Age: 7 months Colour: _____
Brief reason for euthanasia: No money TREATMENT

Post Mortem (all costs include VAT)
A post mortem examination may provide essential scientific information plus serve as a valuable training opportunity for students.

Dog/cat	Yes	No	
Horse	Yes	No	
Foal	Yes	No	
Horse (for insurance purposes)	Yes	No	
Permission granted for student training	<input checked="" type="checkbox"/>	No	No charge
No post mortem allowed	Yes	No	

Disposal (all prices include VAT)
Dogs/cats/small exotics
Communal burial Yes No
Communal incineration (Envirocin) Yes No
Individual incineration (Return of ashes by Envirocin) Yes No
Removal of body by client Yes No No charge

Horses/ponies/donkeys/foals
Communal burial Yes No
Individual incineration (Faculty premises) Yes No
Return of ashes in small wooden casket Yes No
Return of ashes in a ± 60 litre receptacle Yes No No charge

Please note:
Incineration may be mandatory if post mortem findings indicate the presence of a potentially contagious disease. Ashes will be returned by Envirocin within approximately 14 days, and will be available for your collection for a period of 90 days. Thereafter uncollected ashes will be disposed of.

Client signature: _____ Date: 06/05/2011
Clinician's name/signature: _____
Students' name/signature: _____

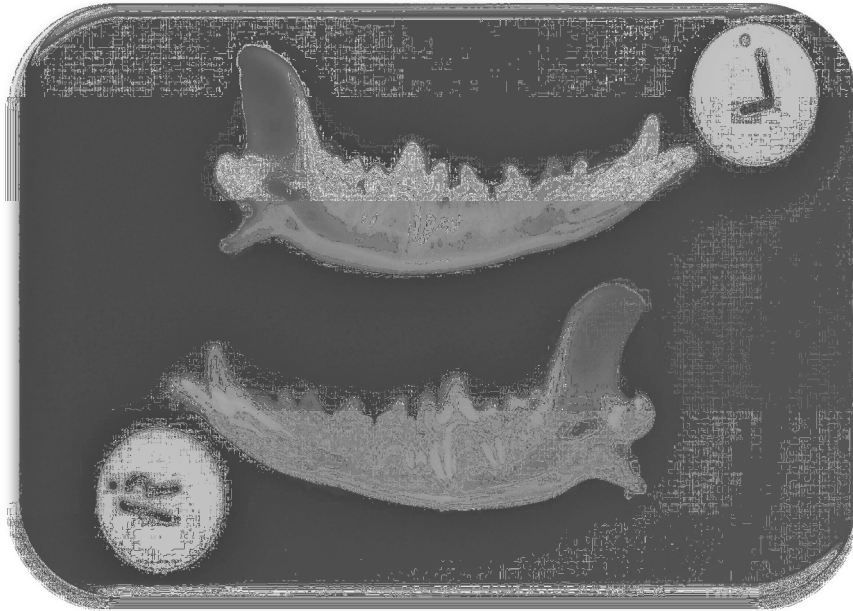
FOR OFFICE USE ONLY

Clinic: _____
Contact Person: _____ Ext: _____
Patient name: _____
Patient number: _____

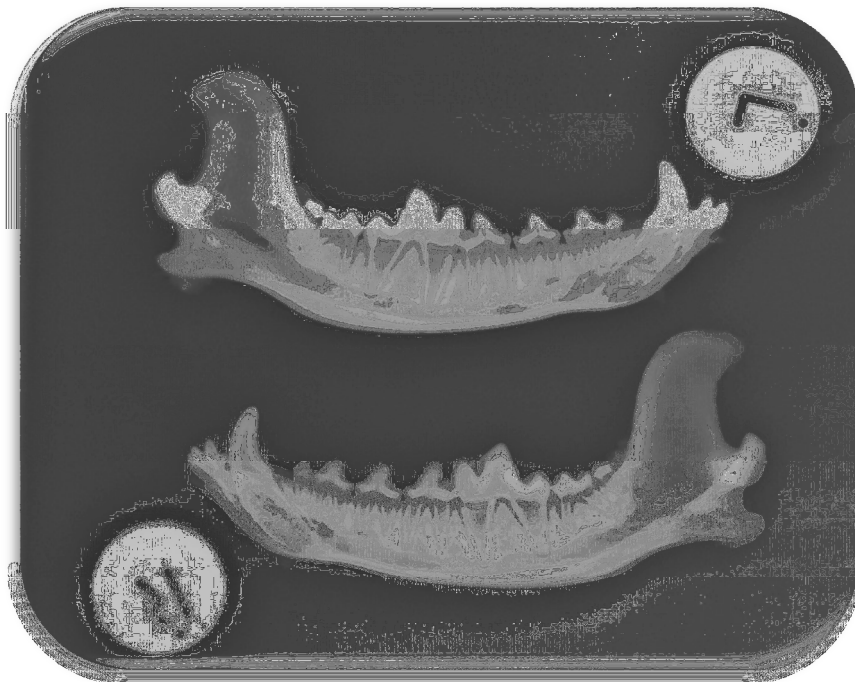OR PLACE STICKER HERE

12.2 Addendum 2: Mandibular radiographs

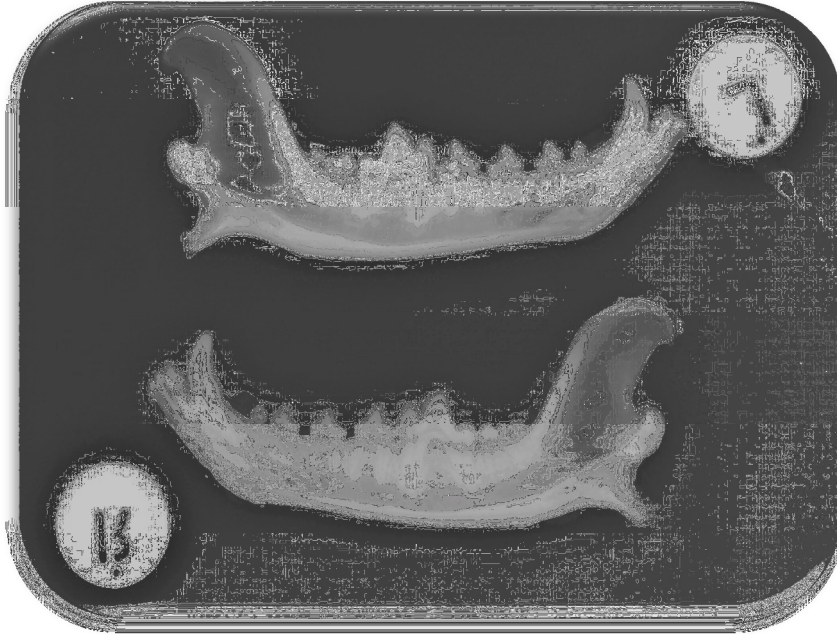
12.2.1 Patient 1



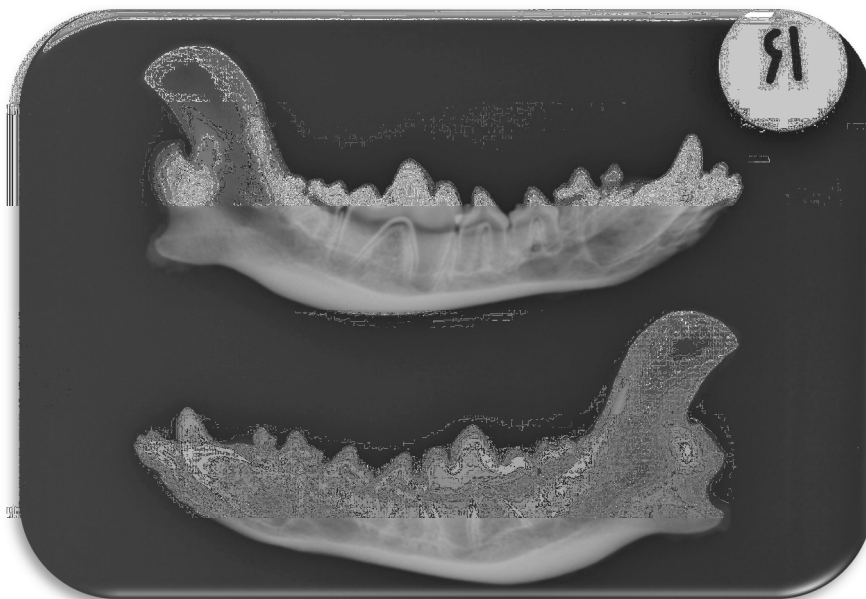
12.2.2 Patient 2



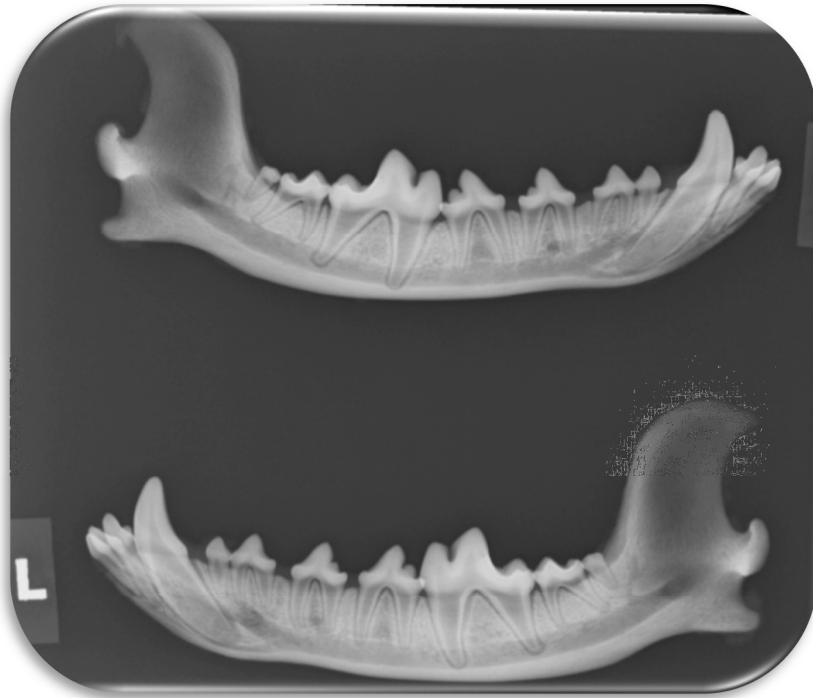
12.2.3 Patient 3



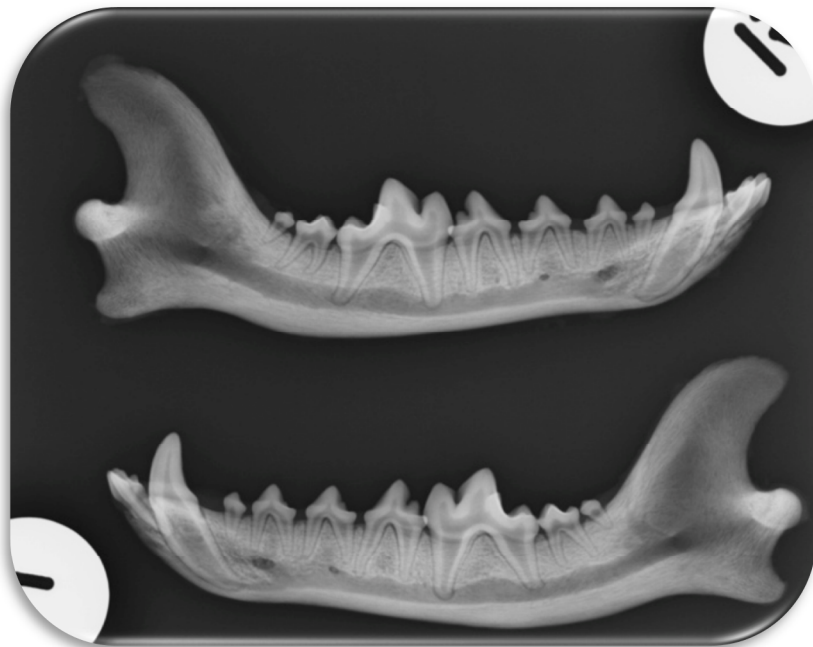12.2.4 Patient 4



12.2.5 Patient 5

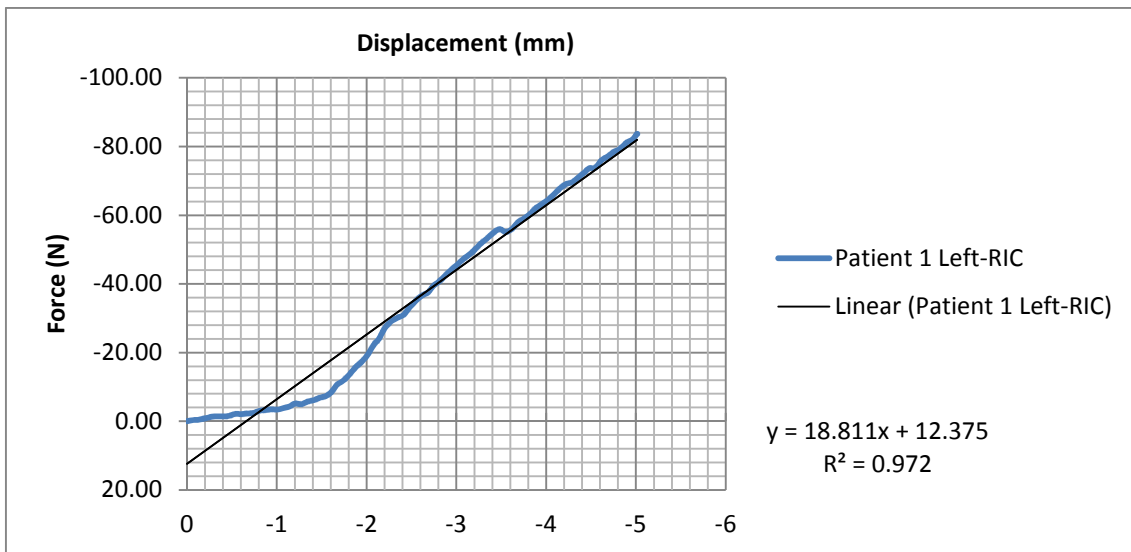
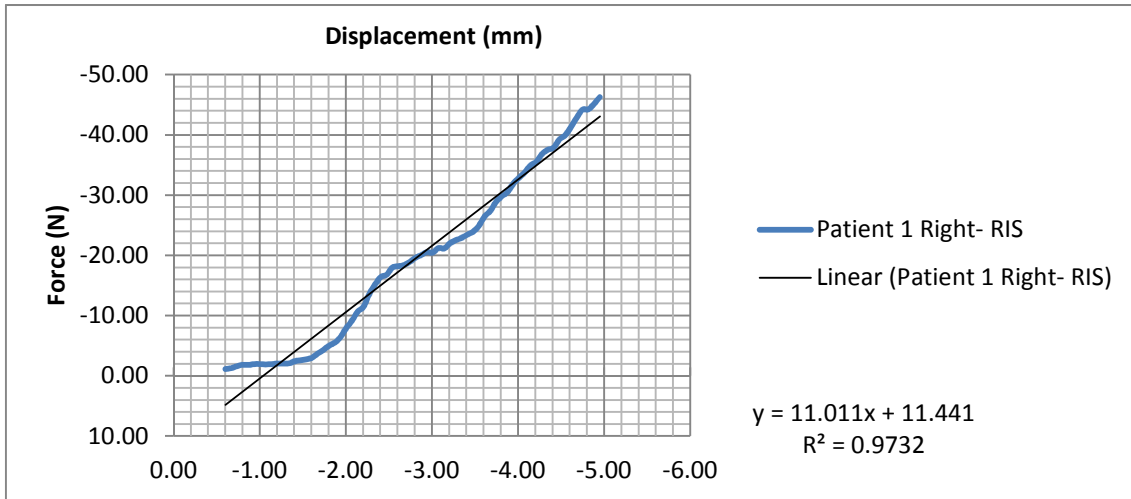


12.2.6 Patient 6

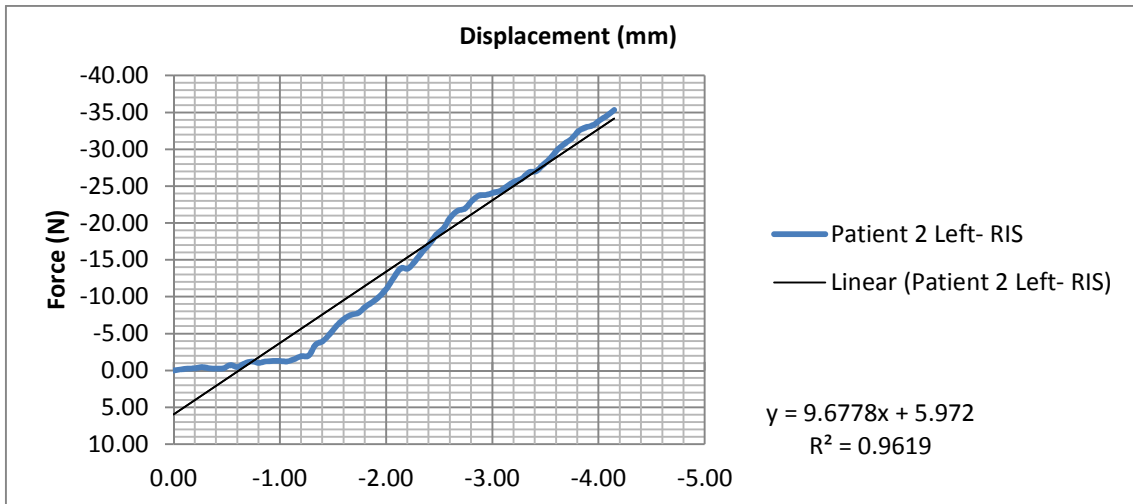
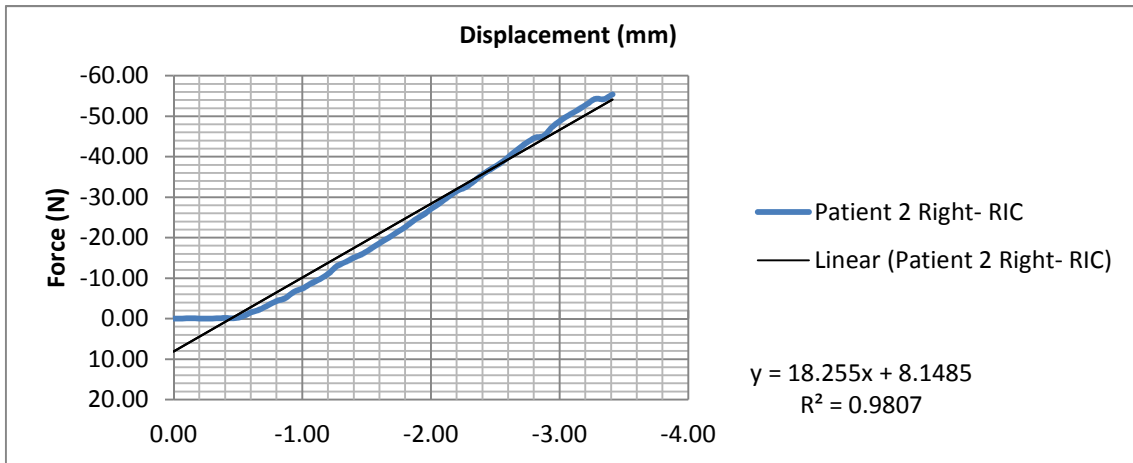


12.3 Addendum 3: Force-displacement curves

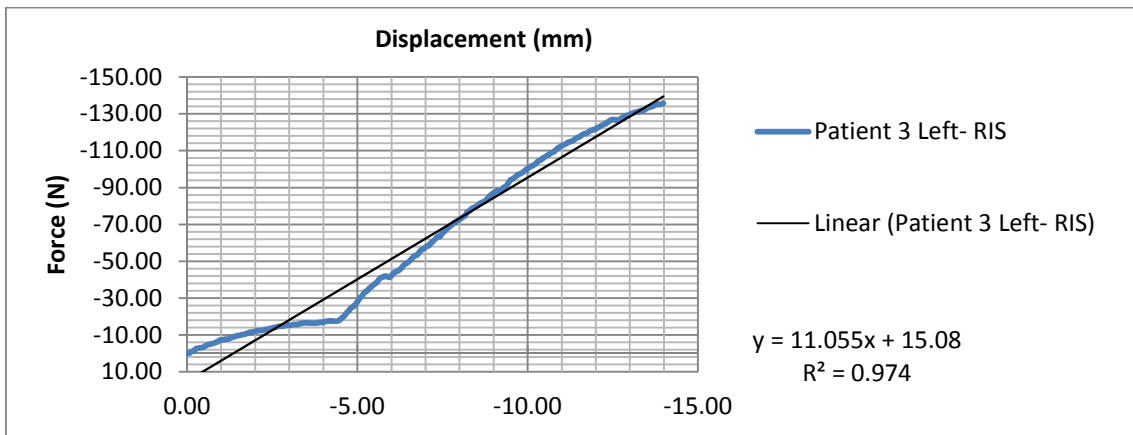
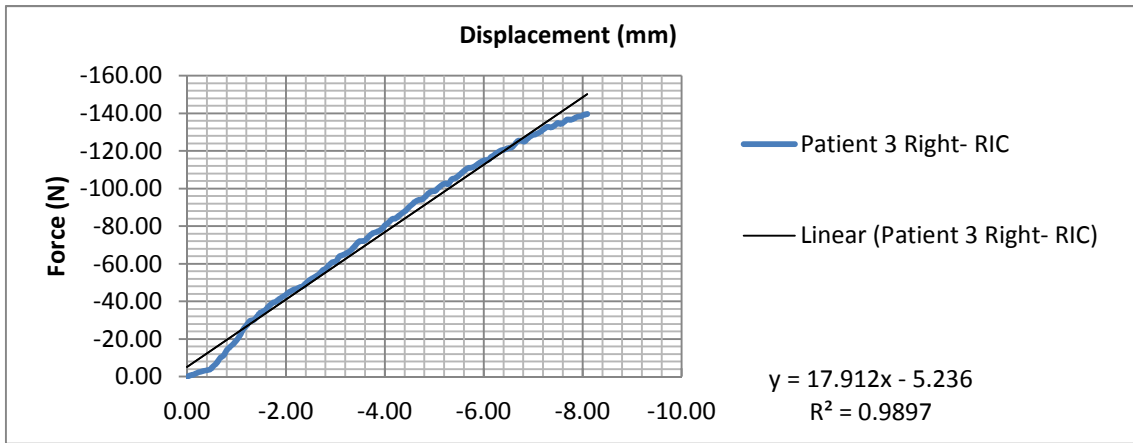
12.3.1 Patient 1



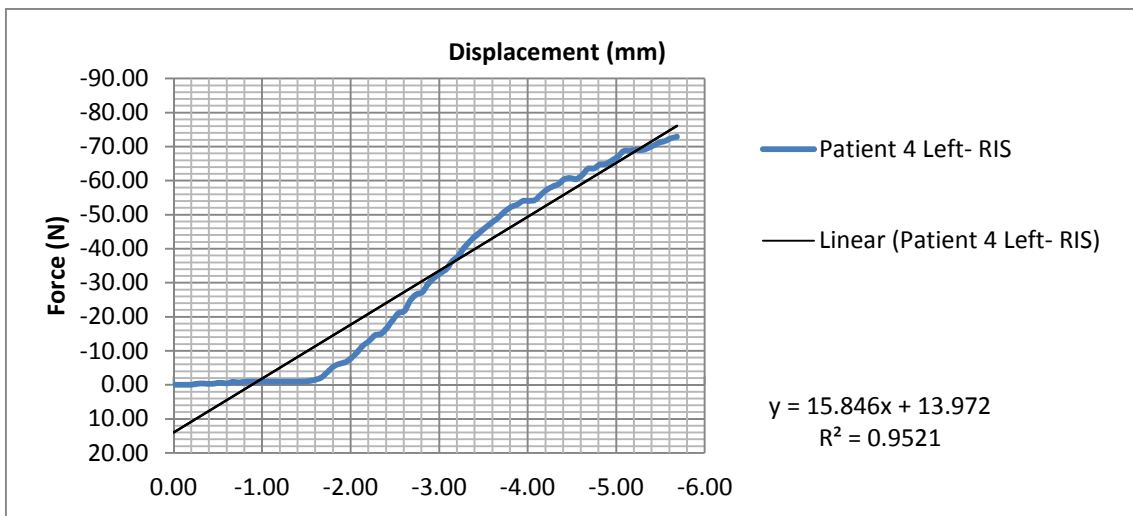
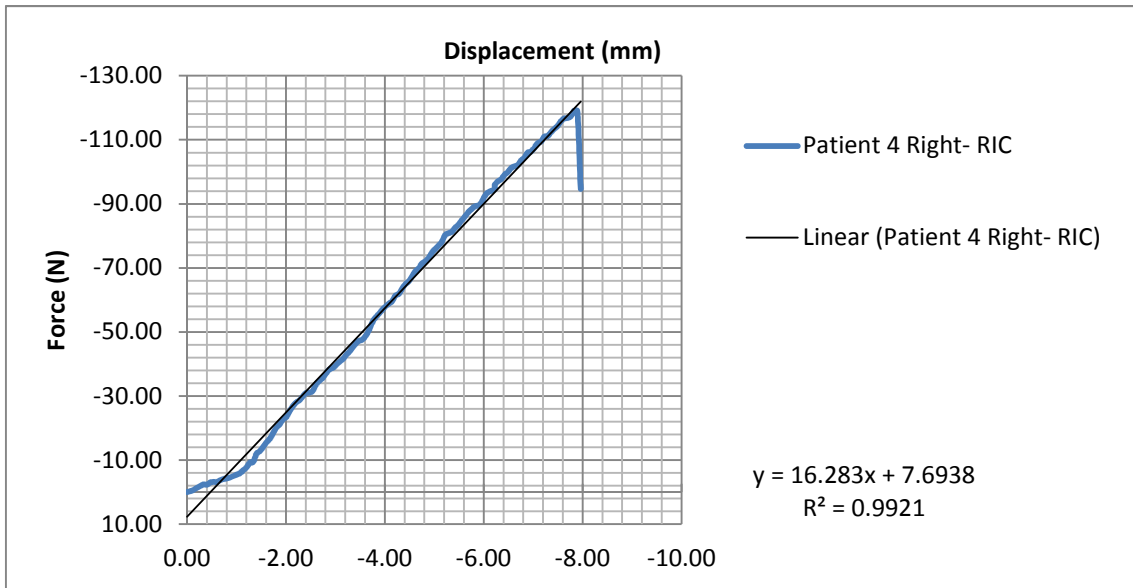
12.3.2 Patient 2



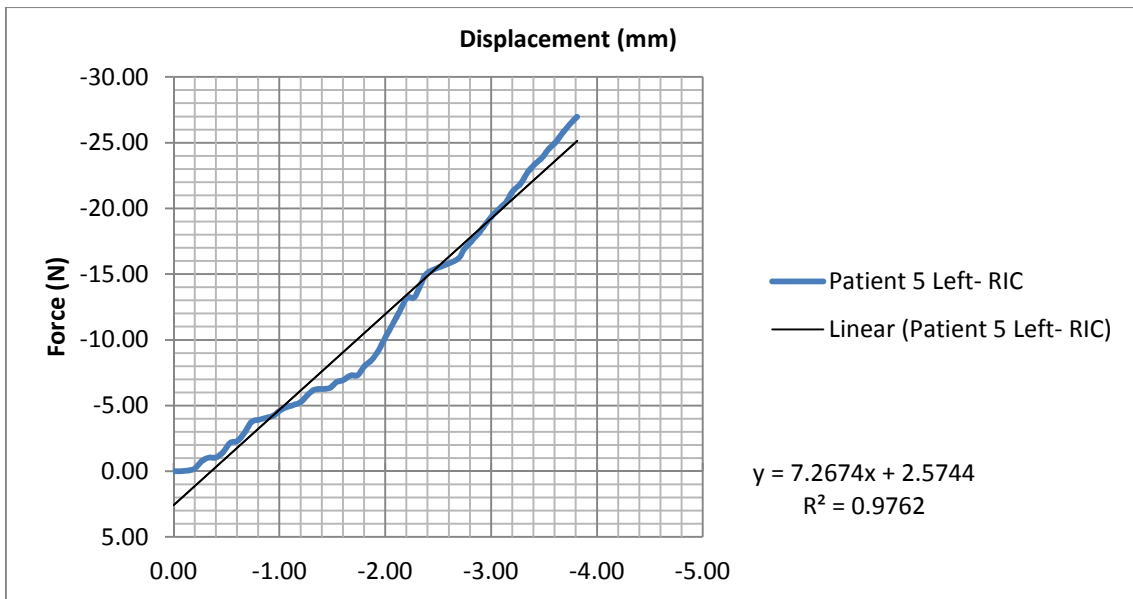
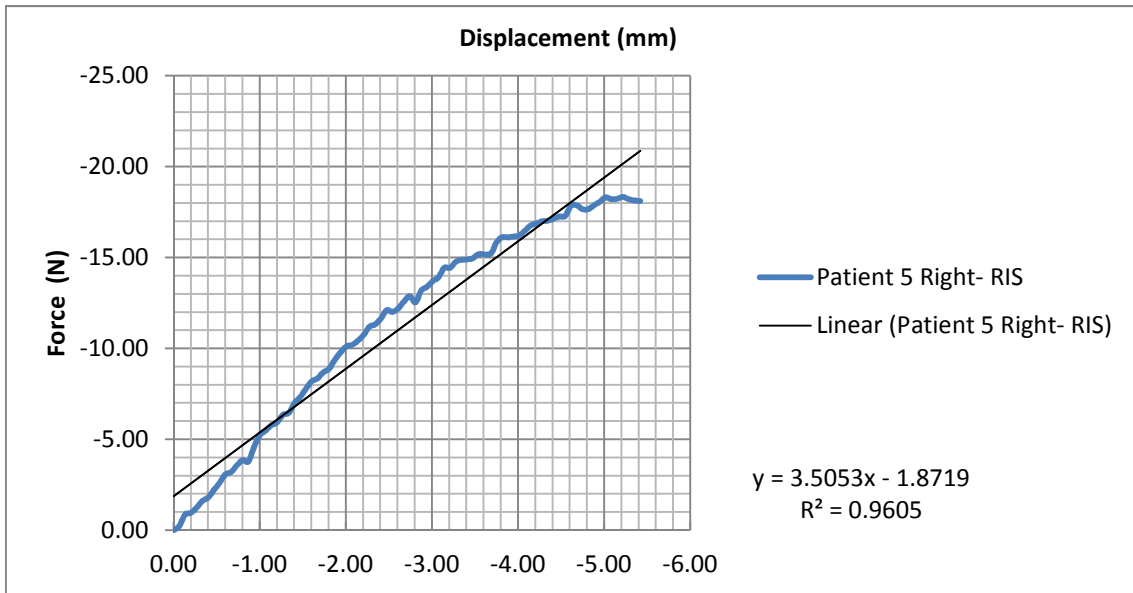
12.3.3 Patient 3



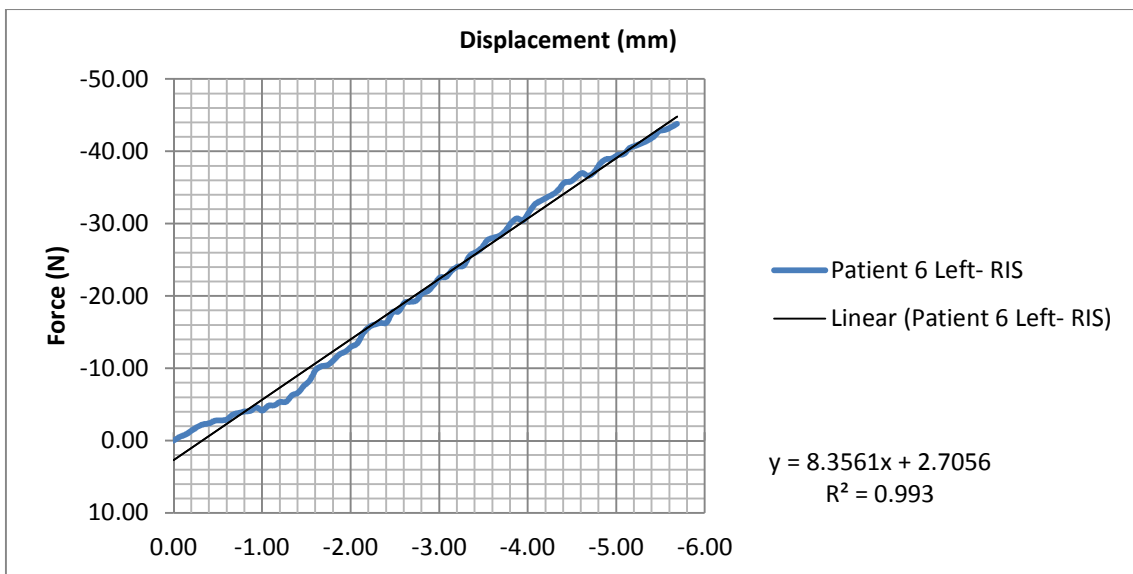
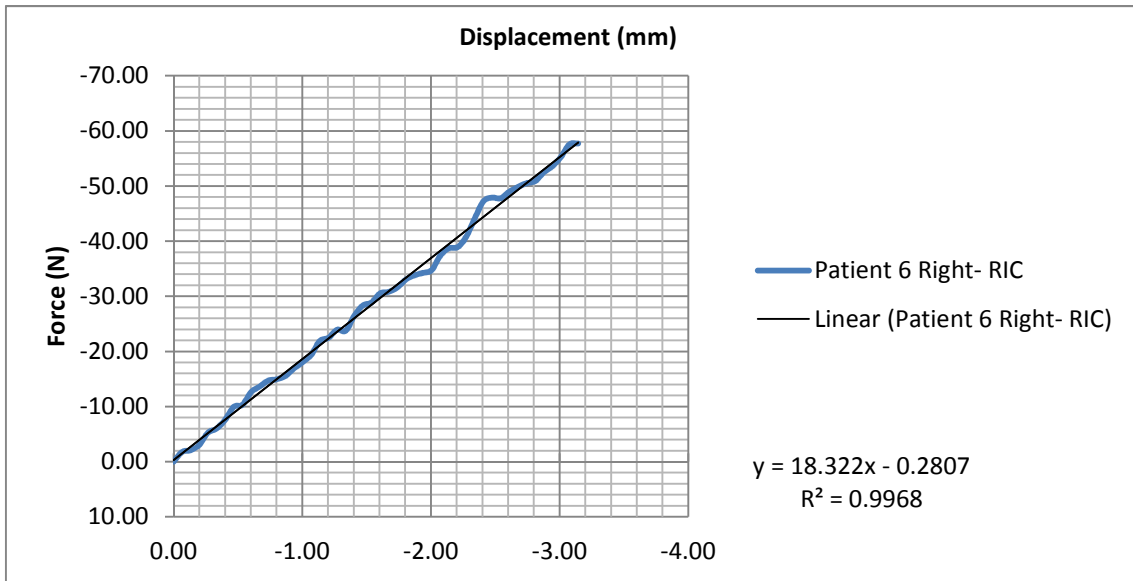
12.3.4 Patient 4



12.3.5 Patient 5



12.3.6 Patient 6



13 SUMMARY

Objective

To determine patient factors and fracture morphology of dogs presented with mandibular fractures to a small animal referral centre in South Africa. The information gathered in this study was used for donor selection and osteotomy morphology for a biomechanical study to compare two reinforced interdental composite splinting techniques.

A new reinforced interdental composite splinting technique, the reinforced interdental crossover composite splint (RIC) will be described in detail. The RIC will be tested biomechanically under controlled conditions and compared with the established reinforced interdental Stout loop composite splint (RIS).

Materials and Methods

Patient data on age, sex, breed and aetiology of dogs with mandibular fractures were recorded. The fractures were classified according to the anatomical location, displacement, fracture type, fracture line direction, periodontal pathology and whether there were teeth in the fracture line or not by evaluation of pre-operative radiographs. Clinical observations indicated whether these fractures were open or closed.

Six pairs of mandibles of young adult small breed dogs, euthanised for reasons unrelated to the study, were then evaluated. Osteotomies were created in a standardised fashion between the 4th premolar and 1st molar and fixed with either RIC or RIS. Both composite splint constructs were tested biomechanically (by applying a cantilever bending F) using a single column testing machine at a rate of 2 mm/min.

Results

In total, 109 dogs with 135 mandibular fractures were included in the study. Small breed dogs and dogs less than 8 months of age predominated (102/109). Dog fights were the most common aetiology in this study (68/109). The molar region was the

most commonly affected region (56/135). Evaluation of the radiographs revealed that transverse (73/135), relatively unstable (116/135) and displaced (112/135) fractures were the most common. The majority of fractures involved teeth in the fracture line (100/135), with the first molar frequently involved (54/135). The majority of fractures were open (104/135).

No statistically significant difference was found between the time of application between the RIC and the RIS. All the implants failed by fracturing of the composite over the area of the fracture or by acrylic lifting on the lingual aspect of the 1st molar. The mean ultimate force was 80.50 N (± 40.29) and 58.70 N (± 41.75), whereas the mean S was 16.19 N/mm (± 4.38) and 9.91 N/mm (± 4.03) for the RIC and RIS respectively (both $p=0.03$). There was no statistical difference between the amounts of displacement in both treatment groups or between the energy absorbed by the two techniques.

Conclusion

Screening of this patient population inspired the selecting a model for recreating the most commonly occurring fracture in dog presented to a referral practice in South Africa. In experimentally fractured mandibles of young adult dogs there is evidence that the RIC is biomechanically superior to the RIS.

14 PAPERS PUBLISHED FROM THIS DISSERTATION

- Kitshoff AM, de Rooster H, Ferreira SM, Steenkamp G. A retrospective study of 109 dogs with mandibular fractures. *Vet Comp Orthop Traumatol* 2013; 26: 1-5.
- Kitshoff AM, de Rooster H, Burger D, Ferreira SM, Steenkamp G. The comparative biomechanics of the reinforced interdental crossover and the Stout loop composite splints for mandibular fracture repair in dogs. *Vet Comp Orthop In Press*.

15 REFERENCES

1. Doblaré M, García JM, Gómez MJ. Modelling bone tissue fracture and healing: a review. *Engineering Fracture Mechanics*. 2004;71(13-14):1809-40.
2. Vashishth D. Small animal bone biomechanics. *Bone*. 2008;43(5):794-7.
3. Cross AR. Fracture biology and biomechanics. In: Tobias KM, Johnston SA, editors. *Veterinary Surgery: Small Animal*. 1. St. Louis, Missouri: Elsevier Saunders; 2011. p. 565-71.
4. Piermattei DL, Flo GL, DeCamp CE, Brinker WO. Fractures: Classification, diagnosis, and treatment. In: Piermattei DL, Flo GL, DeCamp CE, Brinker WO, editors. *Brinker, Piermattei, and Flo's handbook of small animal orthopedics and fracture repair*. 4th ed. St. Louis, Mo.: Elsevier Saunders; 2006. p. 25-159.
5. Copcu E, Sisman N, Oztan Y. Trauma and Fracture of the Mandible. *European Journal of Trauma*. 2004;30(2):110-5.
6. Houlton JEF, Dunning. Perioperative patient management. In: Johnson AL, Houlton JEF, Vannini RAL, editors. *AO principles of fracture management in the dog and cat*. Davos Platz, Switzerland; 2005. p. 1-25.
7. Griffon D. Fracture healing. In: Johnson AL, Houlton JEF, Vannini R, editors. *AO principles of fracture management in the dog and cat*. Davos Platz, Switzerland; 2005. p. 72-97.
8. Heitemeyer U, Kemper F, Hierholzer G, Haines J. Severely comminuted femoral shaft fractures: treatment by bridging-plate osteosynthesis. *Arch Orthop Trauma Surg*. 1987;106(5):327-30.
9. Verstraete F. Maxillofacial fractures. In: Slatter DH, editor. *Textbook of small animal surgery*. 2. 3rd ed. Philadelphia, PA: Saunders; 2003. p. 2190-207.
10. Hermanson JW, Evans HE. The muscular system. In: Miller ME, Evans HE, editors. *Miller's anatomy of the dog*. 3rd ed. Philadelphia: Saunders; 1993. p. 258-384.
11. Boudrieau R. Fractures of the mandible. In: Johnson AL, Houlton JEF, Vannini R, editors. *AO principles of fracture management in the dog and cat*. Davos Platz, Switzerland: AO Publications; 2005. p. 99-115.

12. Boudrieau RJ. Mandibular and maxillofacial fractures. In: Tobias KM, Johnston SA, editors. *Veterinary Surgery: Small Animal*. 1. 1 ed. St. Louis, Missouri: Elsevier, Saunders; 2012. p. 1054-77.
13. Piermattei DL, Flo GL, DeCamp CE, Brinker WO. Fractures and luxations of the mandible and maxilla. In: Piermattei DL, Flo GL, DeCamp CE, Brinker WO, editors. *Brinker, Piermattei, and Flo's handbook of small animal orthopedics and fracture repair*. 4th ed. St. Louis, Mo.: Elsevier Saunders; 2006. p. 717-36.
14. Scott H. The skull and mandible. In: Coughlan AR, Miller A, editors. *BSAVA manual of small animal fracture repair and management*. Cheltenham: British Small Animal Veterinary Association; 1998. p. 115-29.
15. Ellis JL, Thomason JJ, Kebraab E, France J. Calibration of estimated biting forces in domestic canids: comparison of post-mortem and in vivo measurements. *J Anat*. 2008;212(6):769-80.
16. Umphlet RC, Johnson AL. Mandibular fractures in the dog. A retrospective study of 157 cases. *Vet Surg*. 1990;19(4):272-5.
17. An YH, Barfield WR, Knets I. Methods of Evaluation for Bone Dimensions, Densities, Contents, Morphology, and Structures. In: An YH, Draughn RA, editors. *Mechanical Testing of Bone and the Bone-Implant Interface*. Danvers, USA: CRC Press; 1999. p. 103-18.
18. An YH, Barfield WR, Knets I. Basic Concepts of Mechanical Property Measurement and Bone Biomechanics. In: An YH, Draughn RA, editors. *Mechanical Testing of Bone and the Bone-Implant Interface*. Danvers, USA: CRC Press; 1999. p. 23-40.
19. Benson CV, An YH. Basic Facilities and Instruments for Mechanical Testing of Bone. In: An YH, Draughn RA, editors. *Mechanical Testing of Bone and the Bone-Implant Interface*. Danvers, USA: CRC Press; 1999. p. 87-102.
20. Kern DA, Smith MM, Grant JW, Rockhill AD. Evaluation of bending strength of five interdental fixation apparatuses applied to canine mandibles. *Am J Vet Res*. 1993;54(7):1177-82.
21. Currey JD. The effects of drying and re-wetting on some mechanical properties of cortical bone. *J Biomech*. 1988;21(5):439-41.

22. Currey JD, Brear K, Zioupos P, Reilly GC. Effect of formaldehyde fixation on some mechanical properties of bovine bone. *Biomaterials*. 1995;16(16):1267-71.
23. Evans GP, Behiri JC, Vaughan LC, Bonfield W. The response of equine cortical bone to loading at strain rates experienced in vivo by the galloping horse. *Equine Vet J*. 1992;24(2):125-8.
24. Naoki S. Viscoelastic Properties of Bone and Testing Methods. In: An YH, Draughn RA, editors. *Mechanical Testing of Bone and the Bone-Implant Interface*. Danvers, USA: CRC Press; 1999. p. 329-48.
25. Kang JS, Kim NH. The biomechanical properties of deep freezing and freeze drying bones and their biomechanical changes after in-vivo allograft. *Yonsei Med J*. 1995;36(4):332-5.
26. Brodie M, Yuehuei A, Richard F. Factors Affecting the Strength of the Bone-Implant Interface. In: An YH, Draughn RA, editors. *Mechanical Testing of Bone and the Bone-Implant Interface*. Danvers, USA: CRC Press; 1999. p. 439-62.
27. An YH. Mechanical Properties of Bone. In: An YH, Draughn RA, editors. *Mechanical Testing of Bone and the Bone-Implant Interface*. Danvers, USA: CRC Press; 1999. p. 41-63.
28. Sharir A, Barak MM, Shahar R. Whole bone mechanics and mechanical testing. *Vet J*. 2008;177(1):8-17.
29. An YH, Benson CV. General Considerations of Mechanical Testing. In: An YH, Draughn RA, editors. *Mechanical Testing of Bone and the Bone-Implant Interface*. Danvers, USA: CRC Press; 1999. p. 119-32.
30. Cordey J, Gautier E. Strain gauges used in the mechanical testing of bones Part I: Theoretical and technical aspects. *Injury*. 1999;30(0):1-13.
31. Lopez MJ, Markel MD. Bending Tests of Bone. In: An YH, Draughn RA, editors. *Mechanical Testing of Bone and the Bone-Implant Interface*. Danvers, USA: CRC Press; 1999. p. 207-18
32. Radasch RM. Biomechanics of bone and fractures. *Vet Clin N Am Small*. 1999;29(5):1045-82.
33. Cooper JE, Cooper ME. Pathology and post mortem examination. In: Cooper JE, Cooper ME, editors. *Introduction to veterinary and comparative forensic medicine*. Oxford ; Ames, Iowa: Blackwell Pub.; 2007. p. 168-224.

34. Merck M. Time of death. In: Veterinary forensics: animal cruelty investigations. 1st ed. Ames, Iowa: Blackwell Pub.; 2007. p. 241-63.
35. Zioupos P, Smith CW, An YH. Factors Affecting Mechanical Properties of Bone. In: An YH, Draughn RA, editors. Mechanical Testing of Bone and the Bone-Implant Interface. Danvers, USA: CRC Press; 1999. p. 65-86.
36. Sedlin ED. A rheologic model for cortical bone. A study of the physical properties of human femoral samples. *Acta Orthop Scand Suppl.* 1965;Suppl 83:1-77.
37. Pelker RR, Friedlaender GE, Markham TC, Panjabi MM, Moen CJ. Effects of freezing and freeze-drying on the biomechanical properties of rat bone. *J Orthop Res.* 1984;1(4):405-11.
38. Panjabi MM, Krag M, Summers D, Videman T. Biomechanical time-tolerance of fresh cadaveric human spine specimens. *J Orthop Res.* 1985;3(3):292-300.
39. Roe SC, Pijanowski GJ, Johnson AL. Biomechanical properties of canine cortical bone allografts: effects of preparation and storage. *Am J Vet Res.* 1988;49(6):873-7.
40. Boudrieau R, Verstraete F. Principles of maxillofacial trauma repair. In: Verstraete FJM, Lommer MJ, Bezuidenhout AJ, editors. Oral and maxillofacial surgery in dogs and cats. Edinburgh: Saunders/Elsevier; 2012. p. 233-42.
41. Evans HE. The skeleton. In: Miller ME, Evans HE, editors. Miller's anatomy of the dog. 3rd ed. Philadelphia: Saunders; 1993. p. 122-218.
42. Glyde M, Lidbetter D. Management of fractures of the mandible in small animals. In *Practice.* 2003 (25):570-85.
43. Evans H. The heart and arteries. In: Miller ME, Evans HE, editors. Miller's anatomy of the dog. 3rd ed. Philadelphia: Saunders; 1993. p. 586-681.
44. Roush JK, Wilson JW. Healing of mandibular body osteotomies after plate and intramedullary pin fixation. *Vet Surg.* 1989;18(3):190-6.
45. Weigel JP. Trauma to oral structures. In: Harvey CE, editor. *J Vet Dent.* Philadelphia: W B Saunders; 1985. p. 140-55.
46. Manfra Marretta S. Maxillofacial fracture complications. In: Verstraete FJM, Lommer MJ, Bezuidenhout AJ, editors. Oral and maxillofacial surgery in dogs and cats. Edinburgh: Saunders/Elsevier; 2012. p. 333-41.

47. McAllister H, Tobin E. Long bones- fractures. In: Barr F, Kirberger R, editors. BSAVA manual of canine and feline musculoskeletal imaging. Gloucester, UK: British Small Animal Veterinary Association; 2006. p. 32-70.
48. Wang Z, Li Y, Deng F, Song J, Zhao Z. A quantitative anatomical study on posterior mandibular interradicular safe zones for miniscrew implantation in the beagle. *Ann Anat.* 2008;190(3):252-7.
49. Phillips IR. A survey of bone fractures in the dog and cat. *J Small Anim Pract.* 1979;20(11):661-74.
50. Wong WT. A survey of fractures in the dog and cat in Malaysia. *Vet Rec.* 1984;115(11):273-4.
51. Lopes FM, Gioso MA, Ferro DG, Leon-Roman MA, Venturini MA, Correa HL. Oral fractures in dogs of Brazil- a retrospective study. *J Vet Dent.* 2005;22(2):86-90.
52. Gioso MA, Shofer F, Barros PS, Harvey CE. Mandible and mandibular first molar tooth measurements in dogs: relationship of radiographic height to body weight. *J Vet Dent.* 2001;18(2):65-8.
53. Erikson T. Physical orodental conditions. In: Tutt C, Deepprose J, Crossley DA, editors. BSAVA manual of canine and feline dentistry. 3rd ed. Quedgeley: British Small Animal Veterinary Association; 2007. p. 148-59.
54. Smith MM, Massoudi LM. Potential attachment area of the first mandibular molar in dogs. *Am J Vet Res.* 1992;53(2):258-61.
55. Verstraete FJM. Maxillofacial fractures. In: Holmstrom SE, Frost P, Eisner ER, editors. *Veterinary Dental Techniques for the Small Animal Practitioner.* 3rd ed. Philadelphia: W.B. Saunders; 2004. p. 559-600.
56. Smith M, Legendre L. Maxillofacial fracture repair using non-invasive techniques. In: Verstraete FJM, Lommer MJ, Bezuidenhout AJ, editors. *Oral and maxillofacial surgery in dogs and cats.* Edinburgh: Saunders/Elsevier; 2012. p. 275-84.
57. Boudrieau R. Maxillofacial fracture repair using miniplates and screws. In: Verstraete FJM, Lommer MJ, Bezuidenhout AJ, editors. *Oral and maxillofacial surgery in dogs and cats.* Edinburgh: Saunders/Elsevier; 2012. p. 293-308.

58. Boudrieau R. Maxillofacial fracture repair using intraosseous wires. In: Verstraete FJM, Lommer MJ, Bezuidenhout AJ, editors. Oral and maxillofacial surgery in dogs and cats. Edinburgh: Saunders/Elsevier; 2012. p. 289-92.
59. Tsugawa A, Verstraete F. Maxillofacial fracture repair using external skeletal fixation. In: Verstraete FJM, Lommer MJ, Bezuidenhout AJ, editors. Oral and maxillofacial surgery in dogs and cats. Edinburgh: Saunders/Elsevier; 2012. p. 309-19.
60. Cook WT, Smith MM, Markel MD, Grant JW. Influence of an interdental full pin on stability of an acrylic external fixator for rostral mandibular fractures in dogs. *Am J Vet Res.* 2001;62(4):576-80.
61. Bilgili H, Kurum B. Treatment of fractures of the mandible and maxilla by mini titanium plate fixation systems in dogs and cats. *Aust Vet J.* 2003;81(11):671-3.
62. Manfra Marretta S, Schrader SC, Matthiesen DT. Problems associated with the management and treatment of jaw fractures. *Probl Vet Med.* 1990;2(1):220-47.
63. Kern DA, Smith MM, Stevenson S, Moon ML, Saunders GK, Irby MH, et al. Evaluation of three fixation techniques for repair of mandibular fractures in dogs. *J Am Vet Med Assoc.* 1995 ;206(12):1883-90.
64. Holmstrom SE, Frost P, Eisner ER. *Veterinary Dental Techniques for the Small Animal Practitioner. Maxillofacial fractures.* Philadelphia: W.B. Saunders; 2004. p. 559-600.
65. Lieu C, Nguyen TM, Payant L. In vitro comparison of peak polymerization temperatures of 5 provisional restoration resins. *J Can Dent Assoc.* 2001;67(1):36-9.
66. Kurtzman GM, Strassler HE. Provisional fixed restorations. *Dental Economics.* 2006;3:1-12.
67. Muir P, Gengler WR. Interdental acrylic stabilisation of canine tooth root and mandibular fractures in a dog. *Vet Rec.* 1999;145(2):43-5.
68. Hoffer M, Manfra Marretta S, Kurath P, Johnson A, Griffon D, Schaeffer D, et al. Evaluation of composite resin materials for maxillomandibular fixation in cats for treatment of jaw fractures and temporomandibular joint luxations. *Vet Surg.* 2011;40(3):357-68.
69. Marretta SM. Maxillofacial surgery. *Vet Clin N Am Small.* 1998;28(5):1285-96.

70. Buitrago-Téllez CH, Audigé L, Strong B, Gawelin P, Hirsch J, Ehrenfeld M, et al. A comprehensive classification of mandibular fractures: a preliminary agreement validation study. *Int J Oral Maxillofac Surg.* 2008;37(12):1080-8.
71. Shamir MH, Leisner S, Klement E, Gonen E, Johnston DE. Dog bite wounds in dogs and cats: a retrospective study of 196 cases. *J Vet Med A.* 2002;49(2):107-12.
72. Ellis JL, Thomason J, Kebreab E, Zubair K, France J. Cranial dimensions and forces of biting in the domestic dog. *J Anat.* 2009;214(3):362-73.
73. Lorinson K, Loebcke S, Skalicky M, Grampp S, Lorinson D. Signalment differences in bone mineral content and bone mineral density in canine appendicular bones. A cadaveric study. *Vet Comp Orthop Traumatol.* 2008;21(2):147-51.
74. Pietrzak W, Sarver D, Kohn D. Fatigue Testing of Bioabsorbable Screws in a Synthetic Bone Substrate. In: An YH, Draughn RA, editors. *Mechanical Testing of Bone and the Bone-Implant Interface* 1999. p. 581-91
75. Hopkins SG, Schubert TA, Hart BL. Castration of adult male dogs: effects on roaming, aggression, urine marking, and mounting. *J Am Vet Med Assoc.* 1976;168(12):1108-10.
76. Overall KL, Love M. Dog bites to humans--demography, epidemiology, injury, and risk. *J Am Vet Med Assoc.* 2001;218(12):1923-34.
77. Huja SS, Rummel AM, Beck FM. Changes in mechanical properties of bone within the mandibular condyle with age. *J Morphol.* 2008;269(2):138-43.
78. Vollmerhaus B, Roos H. The transverse movement of the temporo-mandibular joint (translation movement) of the dog, also with reference to dysplasia of this joint in the dachshund. *Anat Histol Embryol.* 1996;25(3):145-9.
79. Hall BP, Wiggs RB. Acrylic splint and circumferential mandibular wire for mandibular fracture repair in a dog. *J Vet Dent.* 2005;22(3):170-5.
80. Legendre L. Maxillofacial Fracture Repairs. *Vet Clin N Am Small.* 2005;35(4):985-1008.
81. Norsworthy GD N, DC M. Mandibular fracture repair using an acrylic splint. *Canine Practice.* 1977;4:36-7.

82. Keller T, Liebschner M. Tensile and Compression Testing of Bone. In: An YH, Draughn RA, editors. *Mechanical Testing of Bone and the Bone-Implant Interface*. New York, Washington, USA: CRC Press; 1999. p. 175-205.
83. Burns DR, Beck DA, Nelson SK. A review of selected dental literature on contemporary provisional fixed prosthodontic treatment: Report of the Committee on Research in Fixed Prosthodontics of the Academy of Fixed Prosthodontics. *J Prosthet Dent*. 2003;90(5):474-97.