

Static Stabilisers of the Glenohumeral Joint in the Dog – an *in vitro* study.

Michael Gray

Department of Companion Animal Clinical Studies
Onderstepoort, Faculty of Veterinary Science,
University of Pretoria

A dissertation presented to the Faculty of Veterinary Science
of the University of Pretoria in partial fulfilment
of the requirements for the degree of
M.Med.Vet. (chir.) (small animals)

2004

PROMOTOR: NGJ Maritz

Professor, Department of Orthopaedics

Faculty of Health Sciences

University of Pretoria

CO-PROMOTOR: NE Lambrechts

Associate Professor, Department of Companion Animal Clinical Studies

Onderstepoort, Faculty of Veterinary Science

University of Pretoria

For Charnelle, who has made great sacrifices so that I could become a student again.

Contents

Acknowledgements	5
Introduction/Justification	6
List of Tables	7
List of Figures	8
Abstract	9
Terms and Definitions	10
Chapter 1: Literature Review	11
Chapter 2: Materials and Methods:	17
2.1: Model system and justification of the model.....	17
2.2: Experimental design.....	17
2.3: Experimental procedures.....	19
2.4: Analytical procedures.....	24
Chapter 3: Results:	28
3.1: Specimens.....	28
3.2: Palpation study.....	28
3.3: Biomechanical study.....	30
3.4: Anatomical dissection study.....	37
3.4: Microscopic study.....	49
Chapter 4: Discussion:	52
4.1: Palpation study.....	53
4.2: Biomechanical study.....	54
4.3: Anatomical dissection study.....	64
4.4: Microscopic study.....	68
Chapter 5: Conclusion	69
List of References	72
Appendix	A1-A10

Acknowledgements

I extend my sincerest thanks and gratitude to Prof. Nic Lambrechts who has been my mentor and motivator, not only for this project but throughout my post-graduate studies. His enthusiasm, sense of humour, and thought-provoking questioning of accepted norms have taught me a great deal about how to approach my work and life.

I am indebted to Prof. NGJ Maritz who agreed to promote this research, despite veterinary orthopaedics being slightly out of his field of expertise (human orthopaedics). A vast amount of work has been published on the biomechanics of the human shoulder, and his experience and perspective have provided invaluable insights.

Statistics are a clinical post-graduate student's worst nightmare. I am very grateful to friend and colleague Dr Kenneth Joubert for his expertise, endless calculations, and patient explanations.

I would like to thank Dr PG Rösch for his contribution and ideas, Prof. John Soley for his valued input and histological descriptions, as well as Prof. Piet Stadler and Prof. Andy Leisewitz for providing a kick-start to this project. Thanks are also due to Dr Ian Millward for proof-reading this document.

Special thanks are due to my two laboratory assistants, Nikki Mentz and Nezelle de Jager, who spent many hours and days accurately recording over 4000 data points. This work would also not have been possible without the co-operation and assistance of Dr M Van Staden and staff at the Pretoria SPCA.

Finally, I would like to thank all the clinical staff at the Onderspepoort Veterinary Academic Hospital who have shown an interest and contributed ideas that have enabled me to complete this project.

Introduction/Justification

Much of the published literature on the glenohumeral joint (GHJ) in the dog centres around treatment of luxation, a condition that is rarely encountered. With the increased availability of advanced diagnostic techniques such as arthroscopy, magnetic resonance imaging, and computed tomography, interest in the GHJ has been renewed and a number of previously unrecognised conditions have been described. The pathogenesis of many of these conditions remains speculative and there have been few reports describing or evaluating treatment options. One reason for this may be that very little work has been published describing the normal structure and biomechanical function of the GHJ. Such gaps in our knowledge also make it difficult to develop or evaluate new repair techniques. For example, a number of techniques have been described for the repair of traumatic luxation. Most of these are variations on surgical procedures performed on humans more than 50 years ago, but they still dominate current veterinary texts. In human medicine numerous biomechanical, physiological and clinical trials have been carried out subsequently, leading to new approaches and techniques. Although the results of human trials can give us some insight and a direction to follow with our research, to attempt to extrapolate the results from these studies to dogs may be inappropriate. The human and dog glenohumeral joints differ in many fundamental ways, including function, range of motion, orientation of the bony components, and even the bones that contribute to the joint's function and stability.

The purpose of the present study is to describe in some detail, the anatomical/structural components contributing to static stability of the canine GHJ and quantify the degree of translation/rotation they allow by means of a biomechanical trial. This information will add to the current body of knowledge and assist us in making more accurate hypotheses regarding the pathogenesis of GHJ pathological conditions. It will also provide us with an ideal for re-establishing normal physiologic and biomechanical function when developing surgical repair techniques. In addition, the results of the abovementioned biomechanical trial were compared to a clinical assessment of GHJ stability, to establish the reliability of the latter.

List of Tables

Palpation study

Table 3-1	Maximum flexion and extension in degrees.....	29
------------------	---	----

Biomechanical study

Table 3-2	Measured laxity in intact and vented joints (150°).....	30
------------------	---	----

Table 3-3	Measured laxity in intact and vented joints (135°).....	31
------------------	---	----

Table 3-4	Measured laxity in intact and vented joints (90°).....	31
------------------	--	----

Table 3-5	Maximum flexion in degrees.....	32
------------------	---------------------------------	----

Table 3-6	Maximum extension in degrees.....	32
------------------	-----------------------------------	----

Table 3.7	Summary of results for intact joints.....	33
------------------	---	----

List of Figures

Materials and methods

Figure 2-1.	Jig used for biomechanical study.....	26
Figure 2-2.	Cranio-caudal force.....	27
Figure 2-3.	Medial/lateral force.....	27
Figure 2-4.	Internal/external rotation.....	27
Figure 2-5.	Abduction/adduction	27

Results

Biomechanical study

Figure 3-1.	Comparison between intact and vented joints.....	32
Figure 3-2.	Translation/rotation of intact and vented joints.....	34
Figure 3-3.	Correlation between palpation study and biomechanical study.....	36

Anatomical dissection study

Figure 3-4.	Lateral glenohumeral ligament (GHL).....	39
Figure 3-5.	Medial glenohumeral ligament (GHL).....	40
Figure 3-6.	Glenoid labrum.....	41
Figure 3-7.	Maximum extension.....	43
Figure 3-8.	Constraint of cranial and caudal translation.....	44
Figure 3-9.	Constraint of medial and lateral translation.....	47
Figure 3-10.	Maximum adduction and abduction.....	48

Abstract

To investigate the structural/anatomical components of the static stabilisers of the canine glenohumeral joint (GHJ).

The GHJ of 22 complete cadaver specimens (44 limbs) were manipulated to estimate laxity at joint angles of 150°, 135° and 90° (palpation study). Following the removal of the peri-articular muscles, laxity was measured in 32 of these limbs after applying a 15N force to the scapula in a variety of directions whilst the humerus was fixed to a jig. This was repeated for the abovementioned angles in intact joints and after venting and flushing to eliminate the limited joint volume and adhesion/cohesion (LJV/AC) mechanisms (biomechanical study). Results of the palpation and biomechanical studies were compared. Anatomical dissections were also performed to better describe the structures constituting the static GHJ stabilisers.

The palpation study revealed a marked variation between joints although there was a tendency for progressive laxity as the joint was flexed. This finding was supported by the biomechanical study which also demonstrated no significant difference between intact and vented joints except in a cranio-caudal direction at 135° and 90°, and in a medial/lateral direction at 135°. Static stabilisers contributed to the stability of the GHJ in extension but permitted an ever-increasing range of motion as the joint was flexed. The results of the palpation study did not correlate well with the objective measurements of the biomechanical study.

Manipulation is unlikely to be a reliable method for determining subtle joint laxity in the GHJ. The static stabilisers do not appear to play a significant role in providing joint constraint during normal range of motion (except in extension). Diagnoses of pathological laxity attributable to dysfunction of the static stabilisers should be made with caution and surgical treatments should take cognisance of the abovementioned biomechanical features. Anatomical structures providing constraint to joint mobility are described.

Terms and definitions

There is some inconsistency in the veterinary literature with regard to the use of terms that describe glenohumeral joint (GHJ) pathology. For example, GHJ *instability* has been used to imply complete luxation in some studies, and subluxation in others. For the purposes of this study, the following definitions will apply:

Translation: The movement of one joint surface relative to the other in a horizontal or vertical plane, when the one joint surface is fixed and a force is applied to the other.

Luxation: Complete separation of the humeral head from the glenoid cavity such that the articulating surfaces are no longer in contact.

Subluxation: Reduction in contact between articulating surfaces that is greater than the normal physiologic range of motion, but not to the point of complete separation.

Instability: Instability incorporates both GHJ luxation and GHJ subluxation but implies that the luxation or subluxation is pathological and results in clinical symptoms and further joint damage.

Laxity: Laxity refers to “slackness or looseness” of the joint. It may be physiologic or pathologic. In this study, the term is used to describe the magnitude of translation or rotation of the joint surfaces relative to one another when a force is applied.

Primary stabiliser: A joint structure or mechanism that places a constraint on motion before any other. Such a stabiliser may be functional in one or many directions.

Secondary stabiliser: A joint structure or mechanism that only places a constraint on motion once the primary stabilisers have been overcome.

Note: In the human literature, the term “glenohumeral instability” has been used to differentiate patients that are *symptomatic* as a result of *inappropriate* joint laxity from those who are not (Matsen 1998). A supple athlete, for example, may have lax joints, but no symptoms. His or her joints would not be considered unstable. For a diagnosis of shoulder instability in people, the presence of pain, apprehension related to normal manoeuvres, crepitation, and lack of resistance to translation will all be evaluated and taken into consideration. In addition, diagnostic imaging techniques may be required.

Chapter 1

Literature Review

The glenohumeral joint (GHJ) is classified as spheroidal and consists of a ball (humeral head) and socket (glenoid cavity of the scapula), similar to the hip joint. The shallow glenoid cavity and large difference in surface area between it and the humeral head, combined with a voluminous joint capsule, allow for a wide range of movement: In the dog, extension to flexion - 120 degrees; abduction to adduction - 90°; internal to external rotation - 90° (Evans 1993, Newton 1985). The primary motion, however, is extension and flexion (Evans 1993). The glenoid labrum may deepen the glenoid cavity somewhat and slightly improve congruity, but the joint has been shown to be slightly incongruent (Bardet 1998, Evans 1993, Maierl 2002).

Despite its conformation, mobility, and freedom from bony constraints, the GHJ forms a very stable articulation that rarely luxates (Puglisi 1986, Vasseur 1982). The structures responsible for this joint stability have been divided into two categories:

1. Static stabilisers: These do not actively respond to changes in joint position. They comprise the glenohumeral ligaments (GHL) (medial and lateral) and the joint capsule (JC). These structures blend into each other to form an integral unit, the GHL/JC complex.
2. Dynamic stabilisers: These comprise the peri-articular muscles that bridge the joint and are thought to act by contracting or relaxing in response to changes in joint position and by causing the concavity-compression effect (Karduna 1996, Matsen 1998, Puglisi 1986, Talcott 2003). The latter term implies that a spheroid body compressed against a curved surface will require significantly more force to induce translational movement than the same body compressed against a flat surface (Bardet 2002, Karduna 1996, Matsen 1991, Matsen 1998).

The muscles include: *M. infraspinatus*, *M. supraspinatus*, *M. subscapularis*, *M. teres minor* and, to a lesser extent, the *M. biceps brachii*, *M. triceps brachii caput longum*, *M. deltoideus*, *M. Teres major* and *M. coracobrachialis*) (Craig 1980, Matsen 1998, Puglisi 1986, Talcott 2003). In humans, it has been shown that there is no activity in the dynamic stabilisers at rest (Itoi 1993, Matsen 1991).

There is probably a degree of interaction between these two stabilising mechanisms. The tendinous insertions of the *M. subscapularis*, *M. infraspinatus*, and *M. supraspinatus* blend with the joint capsule and may play a role in static stabilisation (Bardet 1998, Bardet 2002b, Evans 1993, Matsen 1991, Matsen 1998, Puglisi 1986). On the other hand, tensioning of the static stabilisers by these muscles may incorporate them into the dynamic stabilisation of the joint. The GHL/JC complex also has sensory nerve endings that link to the reflex arc which results in muscular proprioceptive responses (Matsen 1998).

The difference in size between the two articular surfaces probably also reduces the likelihood of luxation (i.e. the small glenoid surface must be displaced a great distance before it loses contact with the large humeral articular surface).

Two additional intra-articular forces have been identified as playing a significant role in GHJ stability in humans and can also be classified as static stabilisers (Bardet 1998, Matsen 1991, Matsen 1998). They have been termed the “limited joint volume” (LJV) and “adhesion-cohesion” (AC) mechanisms and relate to the joint space and unique physiology of synovial fluid. Synovial fluid is essentially a dialysate of plasma, excluding larger protein molecules. These are prevented from entering the joint by the filtering effect of the hyaluronic acid molecular structures adjacent to and within the synovial interstitium. Smaller protein molecules can enter the joint, but at a slow rate. Hyaluronic acid is produced by the synovial lining cells and added to the dialysate. Synovial fluid plays a role in joint nutrition and lubrication (Sledge 1993, Vernon-Roberts 1986). The joint space is essentially a potential space containing a small amount of synovial fluid (0.7-1ml in a medium sized dog) that forms a thin lining between the articular surfaces (Simkin 1984). In humans, and probably in dogs, a small negative pressure within the joint maintains this limited volume of fluid.

A negative intra-articular pressure is maintained because the joint fluid has a lower colloidal osmotic pressure than plasma. This is brought about by the selective protein filtration mentioned above, coupled with an effective and non-selective drainage of the joint by lymphatics located within the synovium (Levick 1983, Matsen 1991). Although this negative pressure will contribute little directly to joint stability, it contributes to the formation of the LJV and AC mechanisms (Matsen 1998):

1. In humans, when tractional forces are applied across the intact joint, the glenoid labrum will be pulled inwards to seal the margins of the articulating surfaces (Habermeyer 1992). Displacement forces will create a vacuum that will resist efforts to separate the cartilage surfaces further (Matsen 1998). The resistive force of a vacuum is very strong, as was demonstrated by Von Guericke in 1645 with the use of Magdeburg spheres: Two 4 inch spheres were placed together and the air within sucked out to create a vacuum. They required a distraction force of 1500N to separate them from each other, due to the atmospheric pressure exerted from the outside. In joints, this effect is termed the “LJV” mechanism (Gibb 1991, Matsen 1998). This phenomenon may be compromised where the joint capsule is excessively compliant and itself gets drawn into the joint to displace joint fluid (sulcus effect), where capsular tears break the seal, and where joint effusions increase the total joint volume beyond physiologic norms (Matsen 1991, Matsen 1998).
2. Attempts to separate joint surfaces that are lined by a film of synovial fluid will also be resisted by molecular forces of attraction (Matsen 1998). Joint cartilage is “wetable” – fluids adhere to it and resists separation from it (Matsen 1998). This is termed “adhesion” and is the same phenomenon that results in a concave meniscus when water is poured into a glass container – the water molecules on the periphery of the water column adhere to the glass. In addition, fluid molecules display attractive forces between themselves. Whereas molecules within a fluid are attracted to each other from all sides, neutralising the net force, those on the surface are only attracted from below, creating a surface tension. Any attempt to increase the surface area (such as distraction of the joint) will be resisted by this inherent force. This is termed “cohesion” (Matsen 1998). The combined forces are termed the “adhesion/cohesion (AC)” mechanism. The AC mechanism would be diminished by pathologic factors that separate or cause

changes in the “wettability” of the joint surfaces, the nature of the joint fluid, and the conformity of the joint contact surfaces (Bardet 1998, Matsen 1998).

The LJV and AC mechanisms have rarely been mentioned in the veterinary literature and the freedom of movement allowed by the GHL/JC complex has not been separated from that which is allowed by these mechanisms. The magnitude or relevance of the forces resulting from the LJV/AC mechanisms have not been quantified in dogs, but they have been shown to be substantial in humans (Gibb 1991, Habermeyer 1992).

There are also few reports in the literature evaluating the relative function of the ligaments, tendons, and other mechanisms in glenohumeral joint stabilisation in the dog, and most form part of wider studies evaluating the treatment of shoulder luxation (Craig 1980, Puglisi 1986, Stobie 1995, Vasseur 1983a, Vasseur 1983b). In the past, it has been hypothesised that the peri-articular muscles provided primary stabilisation to the GHJ. Vasseur, however, showed that in dogs, transection of any individual peri-articular muscle attachment resulted in very little static laxity (Stobie 1995). In that study it was not stated whether joints were vented to exclude the effects of LJV and AC. Only the changes in pre- and post-sectioning angles of maximum internal rotation, external rotation, abduction and adduction with the limb in full extension were measured, and these were reported in subjective terms (slight/moderate/marked). Changes in translational mobility were not evaluated. There was no evaluation of joints with all peri-articular muscle attachments severed, so the specific constraints imposed on joint mobility solely by the GHL/JC complex was not evaluated. It did appear, however, that the medial and lateral canine GHL/JC complexes provide an important restraint to excessive joint mobility in extension. Transection of these structures (in addition to the peri-articular muscles) was required for luxation to occur.

In the absence of more detailed biomechanical trials, it has been tempting to conclude from the abovementioned study that the GHL/JC complex provides the primary restraint to joint motion, and at extremes of articulation this is possibly true.

However, it should be borne in mind that where ligaments are considered to be the primary stabilizers of a joint (e.g. the stifle), one or more must always be under tension and they must provide constraint before any other structure or mechanism. They are not performing any function when all are relaxed (Matsen 1991, Matsen 1998). In humans, the entire GHL/JC complex is lax and ineffectual throughout most of the joint's range of motion, only coming under tension at the limits of its range (Matsen 1991, Matsen 1998). It is possible that the same applies to the canine GHJ. If this is true then other restraining mechanisms may also play an important role in GHJ stability before the GHJ/JC complex becomes functional. The issue of which factors provide primary stabilisation through the normal range of motion in the canine GHJ and their relationship to each other remains undefined.

In a further study by Vasseur, evaluating a method of repair for glenohumeral luxation, the medial joint capsule, medial glenohumeral ligament and *M. subscapularis* tendon, or the lateral joint capsule, lateral glenohumeral ligament and *M. infraspinatus* tendon, were transected in a group of 5 live dogs. It is interesting to note that the animals on which no surgical repair was performed were clinically sound within 14 days (Vasseur 1983b). It would appear, therefore, that various combinations of the stabilising tendons and ligaments can be transected (theoretically making luxation possible) without significant loss of joint stability or function. This suggests that there may be other, as yet undefined, mechanisms still functioning that keep the joint relatively stable during the 2 week healing process, although it is possible that the study period was not long enough to identify longer term effects.

It is clear that, due to the paucity of basic research, the normal function and biomechanics of the canine GHJ are still relatively poorly understood. On the other hand, the increasing availability to veterinarians of advanced diagnostic imaging methods (e.g. computed tomography and magnetic resonance imaging) and other diagnostic modalities (e.g. arthroscopy), has made more accurate diagnosis of GHJ pathology and the description of previously unidentified conditions possible.

For example, conditions such as mineralisation of the supraspinatus tendon (Bardet 1998, Kriegleder 1995), tears in the medial and lateral glenohumeral ligaments (Bardet 1998, Mitchell 2000), infraspinatus bursal ossification (McKee 2002) and incomplete ossification of the caudal glenoid (Oliveri 2000) have only been described recently. With the continued development and routine utilization of advanced diagnostic techniques, it is quite possible that more conditions will be identified.

Until we better understand the normal function and limitations of the structures involved with the GHJ, the clinical relevance and effect on joint biomechanics of many of these newly described conditions will remain uncertain. For example, it has been suggested that instability is the most common cause of GHJ pain in the dog (Bardet 1998). Yet what exactly constitutes GHJ instability has never been defined clinically or experimentally. There are references in the literature to the use of joint manipulation as a clinical tool to assist in identifying glenohumeral joint instability. One study referred to the diagnosis of shoulder luxation specifically and described general manipulations (flexion, extension, abduction, adduction, rotation) while paying special attention to the spatial relationship between the acromion process of the scapula and the major tubercle of the humerus (Puglisi 1986). Another study referred to joint laxity in a more general sense (Bardet 1998): A technique for clinical evaluation of laxity was described (grasping the distal scapula and proximal humerus laterally and medially), and comparison with the contralateral normal joint was suggested. No specific findings were reported.

Directly extrapolating knowledge from human anatomy and biomechanical studies to describe the relative functions of the stabilising structures of the canine GHJ may be inappropriate, as the two species' shoulders differ markedly in anatomy and function (Bechtol 1980).

Thus, the purpose of the present study was to elucidate the relative contribution of the LJV/AC mechanisms and GHJ/JC complex in providing a constraint to joint mobility by means of a biomechanical study and to compare these results to clinical palpation (palpation study) findings. This information will serve as a reference for pathologic comparison and will have relevance for further experimental studies and the approach to clinical cases.

Chapter 2

Materials and Methods

2.1. Model system and justification of the model

This study was approved by the University of Pretoria's Animal Use and Care Committee and the Research Committee. The trial made use of cadaver specimens. Performing a similar trial on live animals would have been difficult to perform, costly, and ethically questionable since good information could be gained from a cadaver study. There are many examples in the literature in which cadaver specimens have been used to evaluate joint function (Bigliani, 1996, Cain 1987, Ferrari 1990, Halder 2001, Itoi 1993, Karduna 1997, Lazarus 1996, Maierl 2002, Matsen 1991, Ovesen 1986, Pagnani 1996, Vasseur 1982). All animals were strays and were euthanased because it was not possible to find the original owners or new homes for adoption within the period prescribed by the SPCA (i.e. euthanased for reasons unrelated to this study).

2.2. Experimental Design

2.2.1. Type

An *in vitro* work-bench study. Scapula and humerus, including the glenohumeral joint with joint capsule, glenohumeral ligaments and the proximal $\frac{1}{3}$ of the biceps muscle were harvested from dogs that had been recently euthanased. Each specimen served as its own control.

2.2.2. Selection

Both thoracic limbs were used from 22 dogs (44 limbs) for the palpation part of the trial (see 1.2.1). Of these, 16 dogs (32 limbs) were used for the biomechanical part of the trial (see 1.2.2-1.2.15). Where results between the two parts were compared, only those specimens used in both were included.

The following selection/elimination criteria applied:

- Skeletal maturity
- Weight: 25-35kg
- No obvious emaciation or excessive obesity (subjective evaluation)
- No obvious chronic disease
- No obvious neoplasia
- No radiographic evidence of GHJ pathology.
- No physical evidence of lesions/defects of the glenoid or humeral head
- No obvious trauma involving the thoracic limbs
- No amputees
- No evidence of appendicular chondrodysplasia (eg bulldog, basset)
- No dogs that were obviously elderly

2.2.3. Observations

The following was recorded for every animal used in the study:

1. Breed
2. Sex
3. Body weight
4. Source (e.g. SPCA)
5. Approximation of age (there were no accurate records available)

The following was recorded for every limb used in the study:

1. Donor identification (numbered tags)
2. Date of collection
3. Storage time
4. Limb identification (left/right)
5. The measured cranio-caudal length of the distal scapula from a radiograph: 5mm proximal to the distal edge of the supra- and infraglenoid tubercles.

2.3. Experimental procedures

The study was divided into three parts: A “clinical” palpation study, a biomechanical study performed on a custom-made jig, and an anatomical dissection study.

2.3.1. Palpation study

Dogs were euthanased by intravenous barbiturate overdose.

The primary author performed an evaluation of the following parameters immediately following death:

- Using a goniometer: Angles of maximum flexion and maximum extension. Angles were measured using the lateral epicondyle and major tubercle of the humerus as reference points to determine the orientation of the humerus, and the scapula spine to determine the orientation of the scapula.
- Subjective evaluation: Cranial translation (drawer movement), caudal translation (drawer movement), medial translation, lateral translation.

Cranial and caudal translation was evaluated by grasping the supraglenoid tubercle and caudal aspect of the scapula neck (behind the *m. deltoideus pars acromialis*) between the thumb and forefinger of one hand with the rest of the fingers resting on the cranial margin of the scapula. In well-muscled dogs this was not possible but it was possible to fix the scapula by grasping the cranial and caudal aspect of the acromion process of the scapula instead. With the other hand, the major tubercle of the humerus was grasped cranially and caudally (or the neck of the humerus caudally) between the forefinger and thumb with the rest of the fingers resting on the major tubercular crest. Force was then applied to the proximal humerus in a cranial or caudal direction to evaluate the translation. The magnitude of the force was very much the same as would be applied in evaluating the integrity of cruciate ligaments in the stifle joint.

Medial and lateral translation was evaluated by grasping the scapula with the forefinger positioned on the medial aspect of the supraglenoid tubercle and the thumb on the acromion process.

The acromion process was grasped (as above) where it was otherwise not possible to fix the scapula as described above. The proximal humerus was grasped over the major and minor tubercles below the insertion of the *m. pectoralis profundus* between the forefinger and thumb.

Translation was evaluated at a joint angles of 150° (or full extension if this was less than 150°), 135°, and 90° and was classified and recorded as either:

- No or minimal translation (subjectively $\pm 0-2\text{mm}$)
- Moderate, easily palpable translation (subjectively $>2\text{mm}$)

2.3.2. Biomechanical study

2.3.2.1. Limbs were amputated by transecting the surrounding skin and the muscles of the pectoral girdle: *m. trapezius*, *m. omotransversarius*, *m. brachiocephalicus*, *m. rhomboideus*, *m. pectorales superficiales et profundus*, *m. latissimus dorsi*. Bodies were disposed of by the SPCA according to their current policy.

2.3.2.2. Harvested limbs were placed in sealed, labelled bags and transported in a cool-box with ice packs to the Onderstepoort Veterinary Academic Hospital (OVAH) for further processing.

2.3.2.3. Limbs were radiographed as follows: One extended mediolateral view and 1 extended caudocranial view of the glenohumeral joint. Any specimens showing radiographic evidence of bone or joint pathology were discarded. Caudal humeral head or glenoid osteophytes of up to 2mm were accepted for inclusion in this study (1 case).

2.3.2.4. Specimens were tagged, wrapped in Ringer's lactate^a moistened tissue paper, and placed in sealed bags before being frozen (-20°C), until the biomechanical part of the trial was performed. Specimen storage time ranged from 2 to 75 (mean 60) days.

^a Intramed Ringer's lactate, Frazemius Kabi, South Africa

On the day of the trial, limbs were thawed within the sealed bags in a water bath at room temperature (approximately 22°C). Specimens were kept moist by spraying them with Ringer's lactate at regular intervals for the duration of the trial.

- 2.3.2.5. Holes were drilled in the humerus to fix it firmly, by means of nuts and bolts, to a plate on a custom-made steel jig that allowed rotational adjustment in a vertical plane only (Fig. 2-1). A hole was drilled through the scapula in the middle of the dorsal margin, 5mm from the edge. The scapula was suspended by means of a dacron line running through a hole in a horizontal suspension beam, across the top of the jig, and onto a hanging tensioning lead sinker. Lining up its dorsal margin with the suspension plate ensured correct orientation of the scapula. Orientation was confirmed by lining up a plumb line with 2 widely spaced marks made on the scapular spine and cranial margin. The humerus was rotated to create a joint angle of 150°, 135° or 90°. A hole was drilled horizontally across the supraglenoid tubercle from medial to lateral, 5mm from the cranial edge of the bone just proximal to the attachment of the glenohumeral joint capsule. Another hole was drilled caudally through the infraglenoid tubercle in a similar manner. Five mm diameter steel rings were fastened to the cranial aspect of the supraglenoid tubercle and caudal aspect of the infraglenoid tubercle by passing a dacron line through the holes and tying. These provided attachment points for the tensioning lines. Mid-sagittal marks were made on the supraglenoid and infraglenoid tubercles and the middle of the medial and lateral aspects of the scapula neck, to serve as reference points for subsequent displacement measurements. The calliper was rested on the sliding frame and aligned with perpendicular reference lines inscribed on the frame to ensure geometrically accurate readings were made relative to the bone. The scapula was maintained in vertical orientation (if displaced by application of the weights) by moving the suspending cord as required, and applying further weights to the dorsal tensioning line if needed to maintain its vertical orientation. Cranial and caudal translation of the scapula was calculated by subtracting the initial, pre-tensioning bone/sliding frame distance from that measured after application of the force. A similar procedure was carried out for medial and lateral translational determinations (Fig. 2-3).

Medial and lateral scapular attachments were created by connecting the cranial and caudal steel rings by means of a fishing swivel and running a single line to the medial and lateral pulley systems. In this case, the tensioning lines were passed through pulleys situated under the sliding frame, on the lateral or medial sides of the bone.

- 2.3.2.6. For cranial and caudal translational measurements (Fig. 2-2), a dacron line was attached to the cranial and caudal steel rings, and threaded around pulleys attached cranially and caudally to the underside of a lockable, horizontal frame that was able to slide up and down along the vertical limbs of the jig. The horizontal orientation of the line was ensured using an “in-line” spirit level and lead sinker for cord tensioning. A 15N force was applied after detaching the sinker, by attaching a 1.5kg weight to the tensioning lines. Translational distances were measured between the cranial or caudal scapular marks and the inner edge of the sliding frame using a vernier calliper^a.
- 2.3.2.7. For rotational measurements (Fig. 2-4), lines were passed from both the cranial and caudal steel rings through either the lateral and medial pulleys, respectively. Horizontal forces of 7.5N were simultaneously applied to each line, resulting in an average pure moment of 0.23Nm (standard deviation due to differences in glenoid length and angle of rotation: 0.04Nm). The rotational angle of the scapula (dorsal margin) relative to the longitudinal axis of the jig (suspension beam) was measured with a goniometer^a. By reversing the scapular attachment of the 2 cords, a rotational force was applied in the opposite direction. In this way, the maximum internal and external rotational angles were measured.
- 2.3.2.8. For the angles of adduction and abduction (Fig. 2-5), lines were passed from cranial and caudal holes drilled 5mm from the cranial and caudal angles of the scapula, respectively to join and run through medial or lateral pulleys. A horizontal force of 15N (approximately 2.2 Nm) was applied. The rotational angle of the cranial edge of the scapula relative to a plumb line was measured with a goniometer^a.

^a Vernier calliper, Omni-tech, calibrated to 0.02mm

^a Baseline diagnostic and measuring instruments

After the scapula was detached from the suspension beam, a 1.5kg weight was then suspended from the line attached to the dorsal margin of the scapula to create a ventrally directed tensioning force. The angle of maximum flexion was measured. This created a moment of approximately 2 Nm. The same force (creating a moment of approximately 2.2Nm) was then applied by means of a pulley on the jig in a cranial direction and the angle of maximum extension measured. In similar manner, abduction and adduction angles were measured by application of a laterally or medially directed force. The order at which angle the testing was conducted (90°, 135°, 150°) was alternated in successive specimens to reduce the possible effect of tissue fatigue on measured results. All translational measurements were repeated 3 times and the average of the measurements was recorded and used for statistical calculations. The weight(s) were removed and the scapula returned to a neutral position with respect to the humeral head between measurements.

- 2.3.2.9. Joint fluid was aspirated from the joint and the viscosity was evaluated subjectively by placing a drop between 2 fingers and separating them. The distance between the fingers was measured at the point where the strand broke. The joint was then vented by inserting two 18-gauge needles that remained *in situ*. The joint was rinsed with 20-40ml Ringer's lactate, and the remaining fluid was aspirated. Tests were repeated as described in 2.3.2.5-2.3.2.8.
- 2.3.2.10. The resting position of the glenoid cavity in relation to the humeral head was quite variable, especially at joint angles of 135° and 90° and after venting. To eliminate the resultant variation in measurements, cranial and caudal translations were combined and are presented as a total cranial-caudal translation. The same was done for medial and lateral translation, and for internal and external rotation. The difference in the translation or rotation between vented and intact joints was calculated by subtracting the latter from the former.

2.3.3. Anatomical dissection study

All joints were dissected while attached to the jig with one of the abovementioned forces applied (dynamic study) to determine which structures were responsible for limiting translation and rotation. Specimens were then removed from the jig and further dissected to examine the joint structures more fully (static study). Notes and digital photographs were made of these subjective investigations.

2.3.4. Microscopic study

The lateral and medial components of the capsule of the shoulder joint of four limbs from two further dogs^a were carefully freed from the scapula and humerus and immersion fixed in 10% neutral buffered formalin for 48 hours. The limbs of these dogs had previously been dissected to expose the joint capsule after which they were stored in 10% neutral buffered formalin until sampling for histology. The tissue samples were trimmed of excess material and routinely processed for light microscopy. During embedding, the samples were oriented to provide transverse sections of the wall of the joint capsule. Paraffin sections were stained with haematoxylin and eosin and examined by light microscopy.

2.4 Analytical procedures

All data was entered onto a spreadsheet^a. Statistical analysis was performed using commercial software^b. Statistical significance was set at $p < 0.05$. Left and right leg data were combined for statistical analysis as there was no statistical difference between left and right limbs. A pair wise t-test was used to compare intact to vented joints at the same angles of extension.

^a These specimens were sourced from a further two dogs that fitted the criteria for inclusion in the study, but were not used for other aspects of the study.

^a Excel, Microsoft Corporation, GET CITY, USA

^b SigmaStat version 2.03, SPSS, Chicago

The results of the palpation and biomechanical studies and differences in translation or rotation of intact and vented joints at different joint angles were all compared using the One Way Analysis of Variance (ANOVA) test.

Pearson product-moment correlation was used to determine a correlation between palpated variables and measured variables. Measured variables were analysed as raw data or, for comparison with the palpation study, indexed using the same system as indicated in the palpation part of the study, i.e. 1 = < 2mm movement or a 2 = > 2mm movement.

Means and standard deviations were calculated for the three measurements from each translational parameter to evaluate for repeatability.

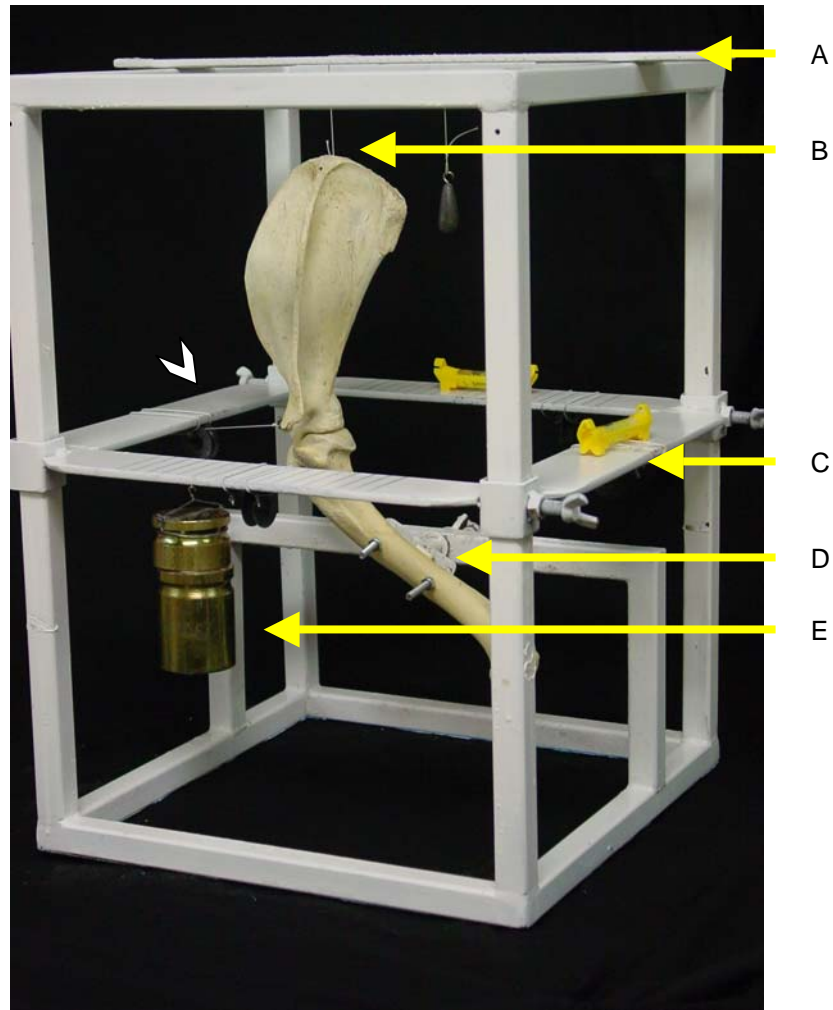


Figure 2-1: Steel Jig: A: Scapula suspension beam; B: Scapula suspended in vertical orientation; C: Horizontal sliding frame with calibrations and spirit levels; D: Adjustable plate for fixing specimen at desired joint angle; E: Weight at the end of the tensioning line; Arrow head: Position of pulley (not visualised) mounted just below sliding frame.

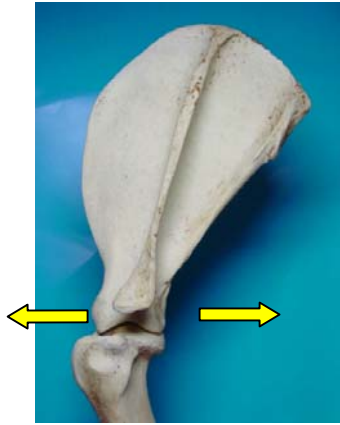


Figure 2-2. Direction of Cranio-caudal force

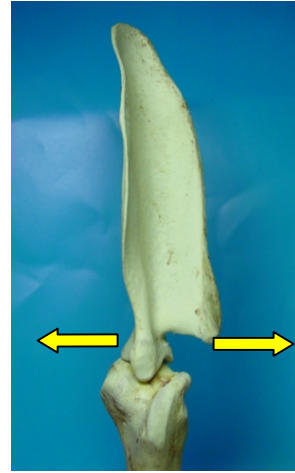


Figure 2-3. Direction of Medial/lateral force




Figure 2-4. Direction of internal (left arrow) and external (right arrow) rotation



Figure 2-5. Direction of abduction (right arrow) and adduction (left arrow)

Chapter Three

Results

3.1. Specimens

A total of 44 limbs were collected from 22 dogs. One pair (specimen 16) was excluded from the study due to radiographic evidence of osteoarthritis (a large enthesophyte within the *m. biceps brachii* tendon of origin). All other limbs were used for the palpation and anatomical dissection parts of the study. A table listing donor signalment and specimen storage time can be found in the Appendix (Table A1). Breeds that were represented included: 14 crossbreeds, 4 German shepherds, 2 boerboels (mastiff-type breed) and 1 dalmation. There were 8 males and 13 females. The mean (estimated) age was 4.8 yrs (range 2-8). Mean body weight was 29.9kg (range 2-8). Mean storage time was 60 days (range 2-75). Three further sets (specimens 3, 4, 8) were excluded from the biomechanical part of the study, due to inadvertent venting of the joint capsule during dissection or preparation. An additional two sets were also excluded due to errors in methodology (specimens 18, 19). Thus the data from a total of 16 dogs (32 limbs) were included in the biomechanical part of the study. Breeds represented in the biomechanical study included: 11 crossbreeds, 2 German shepherds, 2 boerboels, and 1 dalmation. There were 7 males and 9 females. Age was estimated in all cases and ranged from 2 years to 8 years, with a mean of 4.8 years. Body weights ranged from 25kg to 34.6kg, with a mean of 29.9kg (yes, same mean as above!). Specimen storage time ranged from 2 to 75 days, with a mean of 60 days.

3.2. Palpation study

Since it was not possible to determine the exact extent of translation, estimates reported here as <2mm should be regarded, in practical terms, as “no translation or minimal translation” and estimates of >2mm should be regarded as “easily palpable translation.”

In medium and well-muscled dogs it was more difficult than in lean dogs to isolate the scapula neck, minor tubercle, or acromion process, and maintain a grip that enabled manipulation. This may have made estimates of translation even less accurate. At a joint angle of 90°, it was difficult to grip the proximal humerus (due to horizontal orientation) to evaluate cranio-caudal translation. Results of the goniometric measurement of maximum flexion and extension angles are presented in Table 3-1. A definite “stop” or limit to extension was noted. Measurement of the angle of maximum flexion was somewhat more subjective as the end-point for maximum flexion was dependent on the force applied. There was, however, a point at which the resistance to flexion increased sharply. This was the angle that was recorded.

	Mean	Range	SD ^a
Maximum flexion	53	43-63	5.2
Maximum extension	155	140-165	5.3

Table 3-1. Maximum flexion and extension in degrees.

Results of the subjective evaluation of cranial, caudal, lateral, and medial translation are listed in the Appendix (Table A2). It was not possible to elicit palpable translation in any direction in any specimen with the limb extended (150°). As the limb was flexed, it was possible to elicit translational movement in all joints. There was, however, some variation in the way in which this occurred. Translation became readily palpable (>2mm) at a joint angle of 135° in 55% (23/42) of the dogs for cranial translation, 29% (12/42) for caudal translation, 5% (2/42) for lateral translation, and 21% (9/42) for medial translation. Translation was readily palpable (>2mm) at a joint angle of 90° in 95% (40/42) of the dogs for cranial translation, 38% (16/42) for caudal translation, 14% (6/42) for lateral translation, and 36% (15/42) for medial translation.

Where translational movement was evident, there was not a definite stop as is described in the stifle joint with intact cruciate ligaments. A definite stop was found when performing the same manipulations on the specimens after removal of all muscles (except the proximal $\frac{1}{3}$ of the *m. biceps brachii*).

^a SD: Standard Deviation

3.3. Biomechanical study

3.3.1. Subjective joint fluid viscosity evaluation

All samples formed vertical synovial fluid strand of greater than 10cm.

3.3.2. Biomechanical study

The full data results of the biomechanical study are listed in the Appendix (Tables A3-A10). Results are summarised in Tables 3-2 to 3-4. Negative values indicate that the translation/rotation was greater in the intact than the vented joints.

150° Extension

	Mean	SD [°]	Highest	Lowest
Cranio-caudal translation – intact*	3.5	2.1	9.2	-0.5
Cranio-caudal translation – vented*	4.2	2.0	5.3	-1
Difference: intact vs vented*	0.7	1.7	3.5	-2.1
Medial/lateral translation – intact*	6.0	1.3	8.2	0.4
Medial/lateral translation – vented*	7.3	3.3	14	0.4
Difference: intact vs vented*	1.3	2.4	6.7	-2.4
External/internal rotation – intact [#]	34	2.6	11	2
External/internal rotation – vented [#]	34	6.1	51	22
Difference: internal rotation [#]	1	5.5	13	-11
Abduction – intact [#]	23.9	6.5	37	12
Abduction – vented [#]	25.7	6.1	38	15
Difference: intact vs vented [#]	2.3	6.5	17	-12
Adduction – intact [#]	25.4	6.4	38	14
Adduction – vented [#]	26.8	6.3	38	12
Difference: intact vs vented [#]	2.2	5.7	16	-10

Table 3-2. Measured laxity in intact and vented joints. Differences between intact and vented joints are also listed. *Distance in mm, [#]Rotation in degrees, [°]Standard deviation

There was no significant difference between intact and vented joints for any of the variables tested at a joint angle of 150°.

135° Extension

	Mean	SD	Highest	Lowest
Cranio-caudal translation - intact	8.8	2.3	12.9	2.3
Cranio-caudal translation - vented	13.1	1.9	16.2	9.8
Difference: intact vs vented	4.9	3.0	12.3	0.3
Medial/lateral translation – intact	12.5	3.0	18.2	6.5
Medial/lateral translation - vented	14.6	2.3	18.7	10.5
Difference: intact vs vented	2.1	2.6	8.2	-2
Internal/external rotation - intact	58.1	10	73	41
Internal/external rotation - vented	60.4	8.8	78	40
Difference: intact vs vented	2.3	6.5	17	-8
Abduction - intact	34.9	8.6	54	20
Abduction - vented	37.3	6.2	58	27
Difference: intact vs vented	2	5.2	15	-11
Adduction - intact	37.3	7.8	54	20
Adduction - vented	37.8	7.6	52	18
Difference: intact vs vented	1	6.2	9	-12

Table 3-3. Measured laxity in intact and vented joints. Differences between intact and vented joints are also listed.

*Distance in mm, #Rotation in degrees, SD – Standard deviation

There was a significant difference ($p=0.002$) between intact and vented joints at 135° extension for medial/lateral translation (Fig. 3-1). This difference was, on average quite small (2.1mm). There was also a significant difference ($p<0.001$) between intact and vented joints for cranio-caudal translation at this angle (Fig. 3-1). None of the other variables showed a significant difference between intact and vented joints.

90° Extension

	Mean	SD	Highest	Lowest
Cranio-caudal translation – intact	12.6	3.2	17.8	7.0
Cranio-caudal translation - vented	18.4	3.6	26.8	12.0
Difference: intact vs vented	5.8	4.0	16.4	-1.0
Medial/lateral translation – intact	16.8	2.6	21.1	10.7
Medial/lateral translation - vented	17.7	2.8	22.5	12.3
Difference: intact vs vented	0.8	2.1	5.1	-2.7
Internal/external rotation - intact	78.7	7.6	90	58
Internal/external rotation - vented	79.8	7.8	94	55
Difference: intact vs vented	0.6	7.0	16	-15
Abduction - intact	42.4	6.0	52	27
Abduction - vented	44.7	7.7	62	29
Difference: intact vs vented	2	5.3	14	-7
Adduction - intact	51.9	7.8	63	35
Adduction - vented	53.7	7.5	68	34
Difference: intact vs vented	2	4.0	10	-6

Table 3-4. Measured laxity in intact and vented joints. Differences between intact and vented joints are also listed. *Distance in mm, #Rotation in degrees, SD – Standard deviation

There was a significant difference ($p < 0.001$) between intact and vented joints at 90° extension for cranio-caudal translation (Fig. 3-1). None of the other variables showed a significant difference between intact and vented joints at this angle.

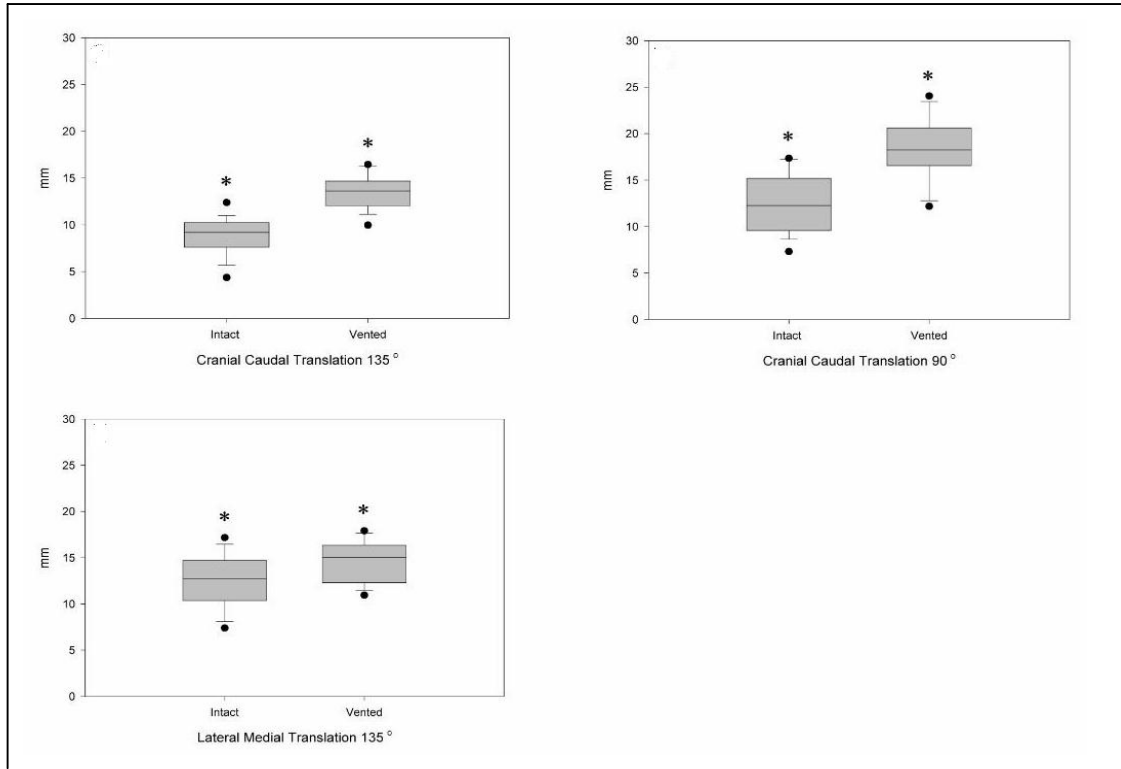


Figure 3-1. Comparison between intact and vented joints where differences were statistically significant. (* Indicates a statistical difference; ● = outliers; bars = 95th percentile; boxes = standard deviation).

Maximum flexion/extension

	Mean	SD	Highest	Lowest
Maximum flexion – intact	33.7	5.7	45	24
Maximum flexion – vented	34.2	5.5	47	25
Difference: intact vs vented	0.3	3.6	10	-6

Table 3-5. Maximum flexion in degrees

	Mean	SD	Highest	Lowest
Maximum extension – intact	155.4	5.5	165	145
Maximum extension – vented	155.3	4.4	164	147
Difference: intact vs vented	0	3.2	7	-5

Table 3-6. Maximum extension in degrees

There was no significant difference between intact and vented joints for maximum flexion and maximum extension.

Comparative values

Both intact and vented joints showed a significant and progressive increase in translation/rotation as the joint was flexed. This was true for all variables (Table 3-7 and Fig. 3-2).

A wide variation in translation/rotation was exhibited between joints (Table 3-7).

	Mean	Range	SD
150°			
Cranio-caudal*	3.5	0-9.2	2.1
Medial/lateral*	6.0	1.6-11.4	2.6
Internal/external [#]	34	2-11	2.6
Abduction [#]	23.9	12-37	6.5
Adduction [#]	25.4	14-38	6.4
135°			
Cranio-caudal*	8.8	2.3-12.9	2.3
Medial/lateral*	12.5	6.5-18.2	3.0
Internal/external [#]	58.1	41-73	10
Abduction [#]	34.9	20-54	8.6
Adduction [#]	37.3	20-54	7.8
90°			
Cranio-caudal*	12.6	7-17.8	3.2
Medial/lateral*	16.8	10.7-21.1	2.6
Internal/external [#]	78.7	58-90	7.6
Abduction [#]	42.4	27-52	6
Adduction [#]	51.9	35-63	7.8

Table 3-7. Summary of results for intact joints.

*Translation in mm, [#]Rotation in degrees

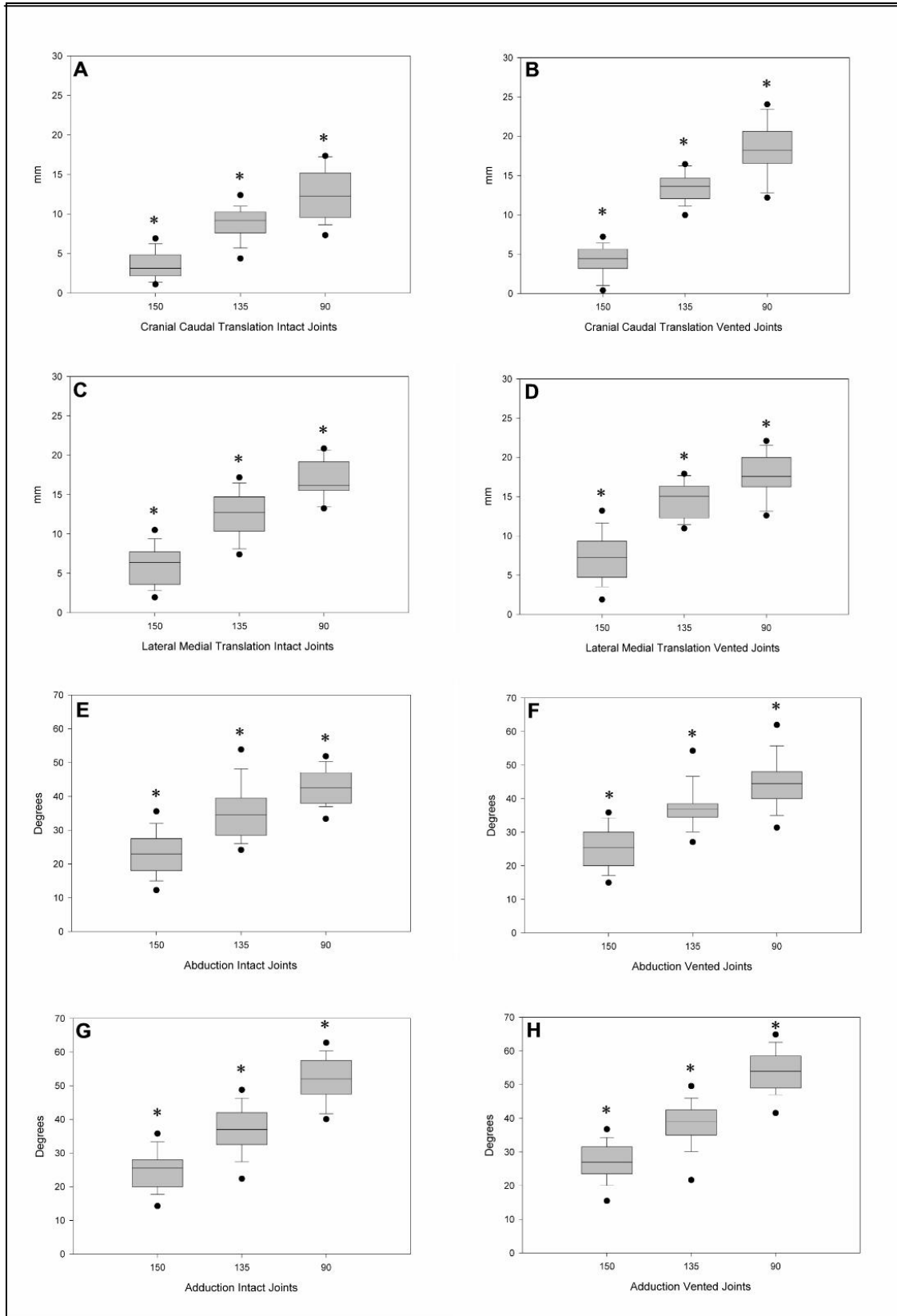


Figure 3-2. Translation/rotation of intact and vented joints. Note the progressive increase in laxity with decreasing joint angle (* Indicates a statistical difference; ● = outliers; bars = 95th percentile; boxes = standard deviation).

In a comparison of translation elicited during palpation with that measured in the biomechanical study, none of the parameters displayed a reliable correlation (Fig. 3-3). For example, at 150°, only 43% (55/128) measurements correlated. It should be noted, however, that the average for all translations at this angle was 2.4mm, which is very close to the cut off point between categories in the translation study. At joint angles of 135° and 90°, palpation under-estimated the translation in all of the 32% (41/128) of cases that did not correlate.

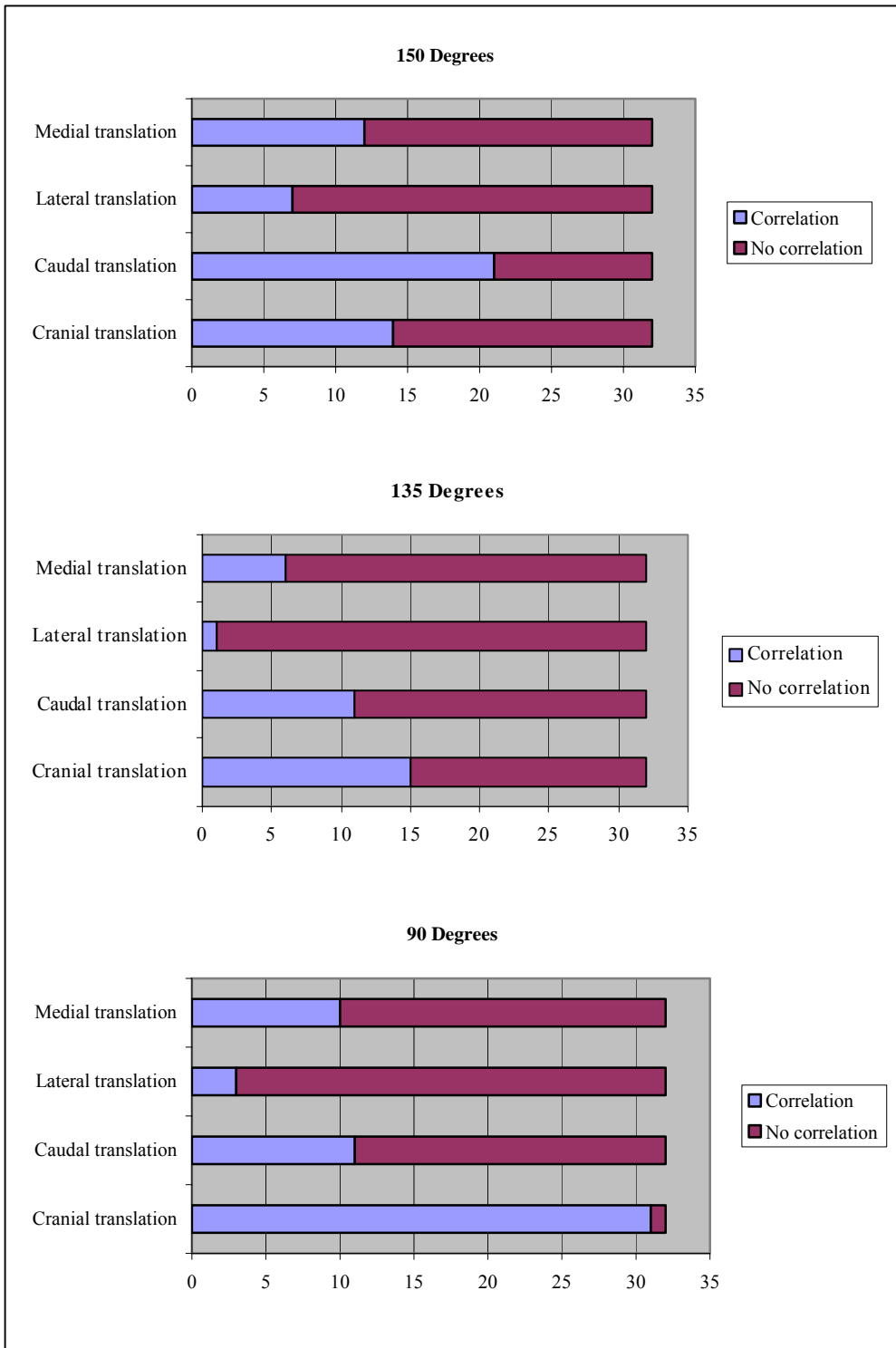


Figure 3-3. Correlation between palpation study and biomechanical study. Light shaded areas represent the number of cases where the palpation and biomechanical studies agreed (i.e. > or < 2mm translation). X-axis – total number of cases.

3.4. Anatomical dissection study

3.4.1. Static study

Previously described anatomical features of the GHJ were observed (Evans 1993), including the voluminous nature of the joint capsule (especially the caudal pouch), the subscapular and bicipital synovial pouches, and medial and lateral GHLs. The following additional features were noted:

Lateral glenohumeral ligament

The lateral GHL consisted of 2 bands (Fig. 3-4). This was consistent in all specimens examined in this study. Together they formed an inverted U shape. The combined origin formed a broad band just caudal to the origin of the *m. biceps brachii* muscle on the supraglenoid tubercle of the scapula and extended laterally to include the cranio-lateral glenoid rim. One band ran in a caudo-ventral direction (caudal band) and the other ran in a cranio-ventral direction (cranial band). The caudal band was 8.5mm wide and the cranial band 5mm wide in the one specimen on which it was measured. The caudal band inserted on the humeral neck in the region of the caudo-medial aspect of the major tubercle. It had fibres that extended over the caudal aspect of the major tubercle to insert on the proximal tricipital line. The cranial band ran parallel and cranio-lateral to the tendon of origin of the *m. biceps brachii* and implanted along the medial aspect of the cranial extremity of the major tubercle within the intertubercular groove.

Medial glenohumeral ligament and medial joint capsule

The medial glenohumeral ligament consisted of a cranial and caudal band (as has been described in the literature (Bardet 1998, Craig 1980, Evans 1993, Puglisi 1986) originating on the medial glenoid rim and converging to implant on the minor tubercle and thus form a Y-shaped ligament (Fig. 3-5a, b). The caudal band originated on the caudo-medial aspect of the glenoid rim just cranial to the infraglenoid tubercle and appeared as a thickening of the joint capsule.

The cranial band originated medial to the origin of the *m. biceps brachii* along the craniomedial aspect of the glenoid rim. Proximally it ran medial to the joint capsule, forming a structure that was quite distinct from, and only loosely attached to, the overlying joint capsule (Fig.3-5d). Distally it merged with the joint capsule and caudal band to form a common insertion on the caudal aspect of the minor tubercle. The medial joint capsule originated on the scapula neck about 5-6mm proximal to the glenoid rim (and cranial band of the medial GHL). Medial to the tendon of origin of the *m. biceps brachii*, the joint capsule formed a narrow fold that appeared to be ligamentous and was situated craniomedial to the tendon of origin of the *m. subscapularis* (Fig. 3-5b, c). This ligamentous structure took origin from the craniomedial glenoid rim on the ventral aspect of the coracoid process (blending with the origin of the cranial band of the medial GHL) or from the medial GHL itself. It inserted on the medial aspect of the minor tubercle of the humerus within the inter-tubercular groove. On dissection, it did not appear to be a thickened fibrous band like the glenohumeral ligaments, but simply a fold of joint capsule, giving the impression of a ligamentous band. A clear fibrous band was, however, identified in this region on three of the four further specimens (from two dogs) that were evaluated histologically (see microscopic study below).

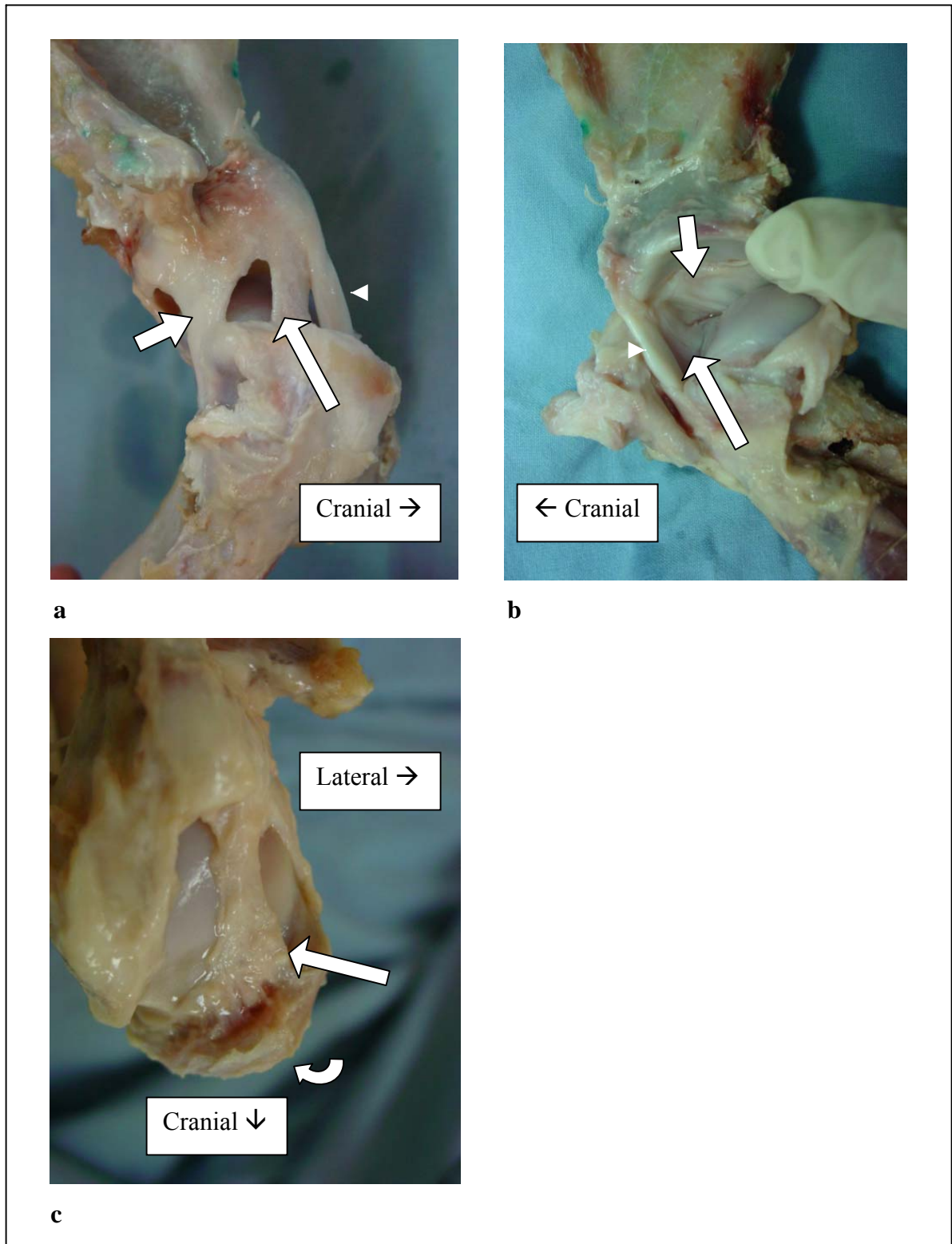


Figure 3-4. Lateral GHL: Medial (a) and lateral (b) views showing cranial and caudal bands.

Dorsal view, *m. biceps brachii* removed (c) showing broad insertion on medial aspect of major tubercle. Caudal band, short arrow; cranial band, long arrow; tendon of origin *m. biceps brachii*, arrowhead; major tubercle of humerus, curved arrow.

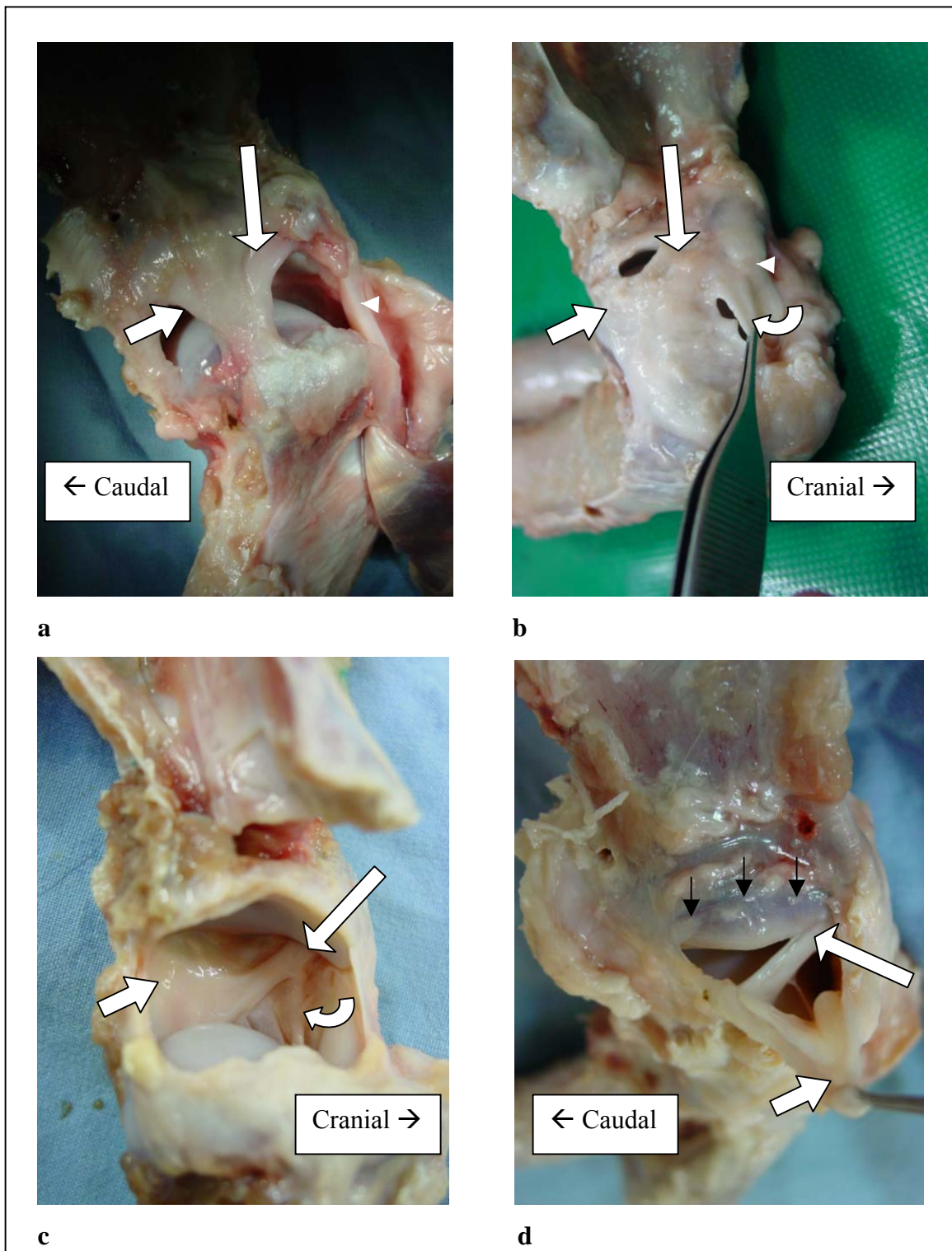


Figure 3-5 (a-c). Medial GHL: Medial view (a, b) and lateral view (c). Cranial band, long white arrow; caudal band, short white arrow; coracohumeral ligament, curved arrow; black arrows, glenoid labrum.

Figure 3-5 (d). Medial glenoid rim. Black arrows indicate line of medial joint capsule origin. The joint capsule is retracted ventrally (short white arrow) Note that the cranial band of the medial GHL (long white arrow) is an independent structure with an insertion distal to the joint capsule.

Glenoid cavity and labrum

A glenoid labrum was noted as a distinct thickened fibrous band in three specimens. It was situated on the caudal and lateral glenoid rim joining the bone and joint capsule (Fig. 3-6). It was up to 3mm in height.

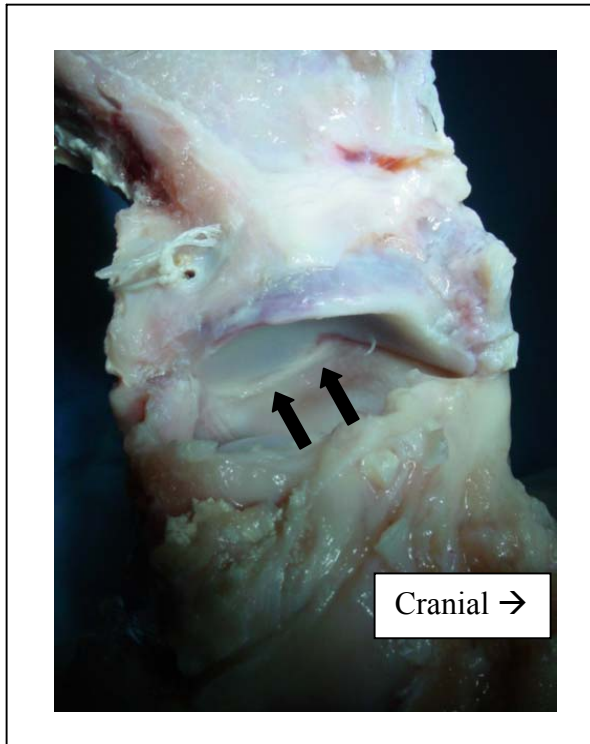


Figure 3-6. Glenoid labrum on lateral rim of glenoid cavity (looking through the joint). Labrum, arrows.

3.4.2. Dynamic study

Maximum extension

A narrow area of the caudal joint capsule (approximately 10-15mm wide) provided the main restraint against hyperextension

(Fig. 3-7a, c). If this area was severed, the caudal joint space widened as the scapula tilted forwards (Fig. 3-7b, d). Neither band of the lateral or medial GHL was fully taut at maximum joint extension. The caudal band of the medial GHL acted as a secondary restraint, only becoming fully taut once the caudal joint capsule had been transected.

At maximum extension, the supraglenoid tubercle and *m. biceps brachii* tendon of origin were compressed into the intertubercular groove (under the transverse humeral ligament). This may contribute to the stability of the joint in this position. However, transecting the transverse humeral ligament did not appear to significantly diminish joint stability.

Maximum flexion

The cranial joint capsule, which included the cranial band of the lateral GHL and the capsular fold running between the coracoid process and minor tubercle, provided restraint against excessive flexion.

Cranial translation^a

The cranial band of the medial GHL, caudal band of the lateral GHL, and the caudal joint capsule provide primary capsular restraint to excessive cranial translation of the scapula relative to the humeral head (Fig. 3-8a, b).

Caudal translation^a

Caudal translation of the scapula relative to the humeral head was restrained by both the caudal band of the medial GHL and the caudal part of the caudal band of the lateral GHL (Fig. 3-8c). The caudal aspect of the joint capsule was also under tension at maximum caudal translation, but isolated sectioning (with the medial and lateral GHLs intact) of this area allowed only 1-2mm of additional translation.

The cranial band of the medial GHL, the cranial $\frac{2}{3}$ of the caudal band of the lateral GHL, and the cranial part of the lateral GHL were in a relaxed state.

^a Translational evaluations were carried out at a joint angle of 135°

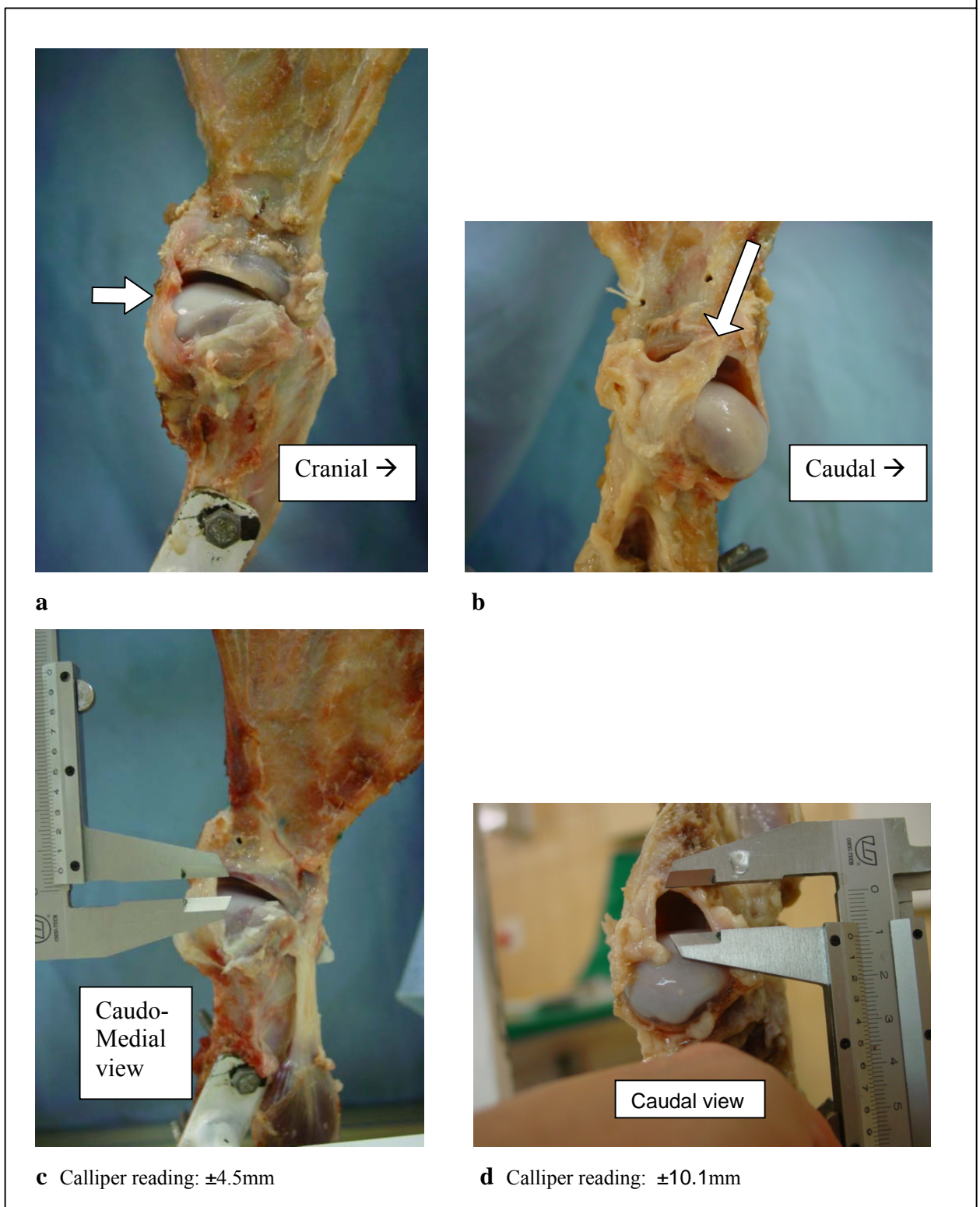


Figure 3-7(a, c). Maximum extension: constraint provided by caudal joint capsule and compression of supraglenoid tubercle of scapula in the intertubercular groove of the humerus. Caudal joint capsule, short arrow; Caudal band of medial GHL, long arrow.

Figure 3-7 (b, d). Intact medial and lateral GHL with caudal joint capsule resected. Note increase in joint divergence compared with a and c.

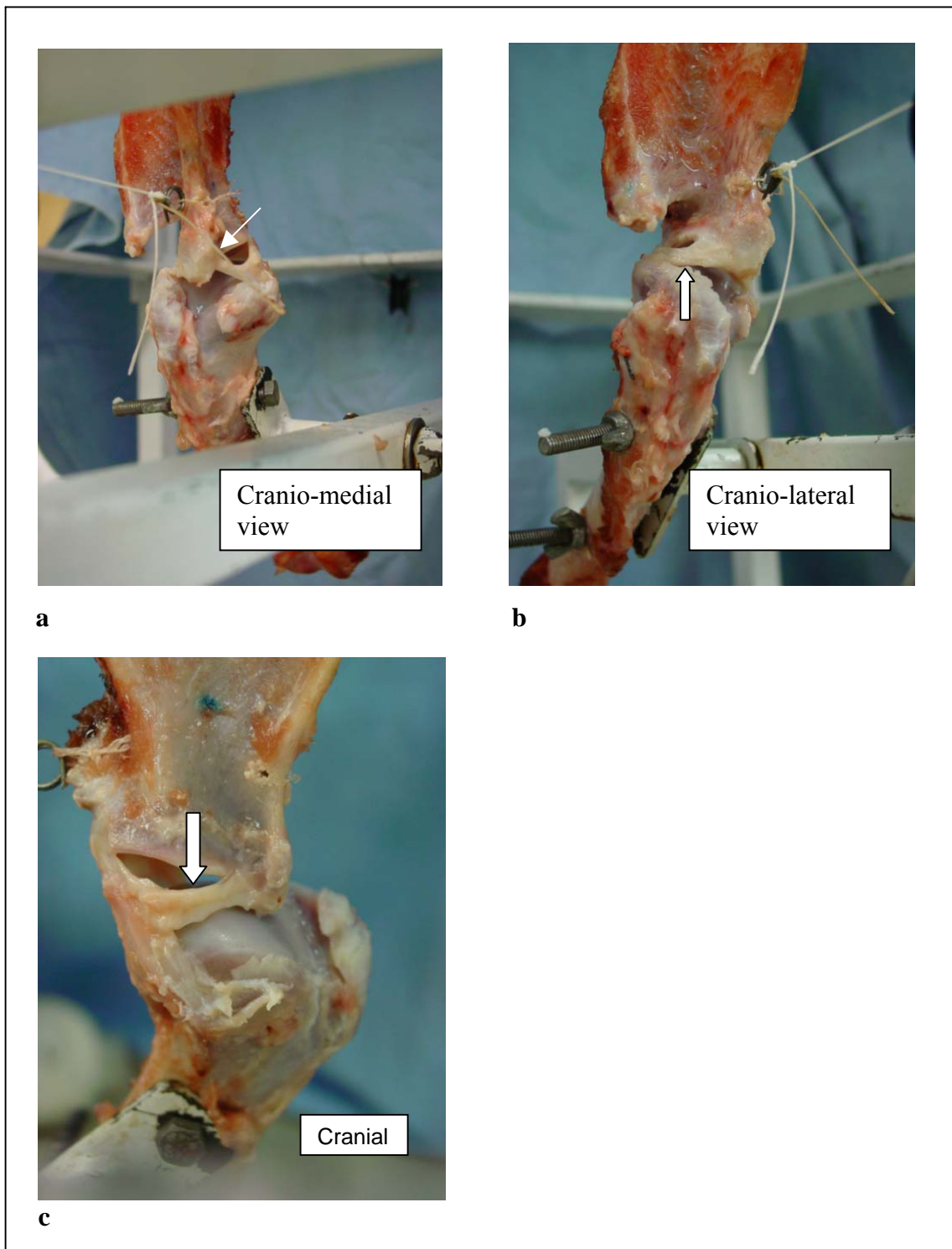


Figure 3-8a, b. Constraint of cranial translation viewed from a cranio-medial (a) and cranio-lateral (b) direction.

Note the tension on the cranial band of the medial GHL and the caudal band of the lateral GHL (arrows). The cranial band of the lateral GHL has been removed in b.

Figure 3-8c.

Constraint of caudal translation of the scapula (medial view). Note how the supraglenoid tubercle of the scapula rides up on the humeral head. The cranial band of the medial GHL is not under tension (arrow).

Medial translation^a

The entire lateral joint capsule extending to its most caudal aspect, including the caudal band of the lateral GHL, restrained medial translation of the scapula relative to the humeral head (Fig. 3-9a, b). There was no tension on the medial joint capsule, medial GHL, or biceps tendon.

Lateral translation^a

The cranial and caudal bands of the medial GHL provided restraint to lateral translation of the scapula relative to the humeral head (Fig. 3-9c). The caudal part of the joint capsule was also under tension. The medial joint capsule was not under any tension (see the separate origins of the cranial band of the medial GHL and medial joint capsule above). The lateral joint capsule, lateral GHL and biceps tendon also appeared to play no role in the primary restraint of lateral translation.

Note: Transection of either the medial or lateral GHL (at 135° joint angle) resulted in subluxation with approximately 50% displacement of the articular surfaces. If the medial or lateral GHL were transected along with the ipsilateral joint capsule, extending past the caudal aspect of the joint, then dislocation was possible by rotation of the scapula around the remaining intact GHL and surrounding joint capsule.

Internal rotation^a

The caudal band of the lateral GHL restricted internal rotation of the scapula relative to the humeral head. The caudal joint capsule was also under some tension and was twisted.

External rotation^a

The cranial band of the medial GHL restricted external rotation of the scapula relative to the humerus. The major tubercle of the humerus and broad fibrous insertion of the supraspinatus muscle also provide some restraint to external rotation. The caudal aspect of the joint capsule was twisted in a medial direction.

^a Translational and rotational evaluations were carried out at a joint angle of 135°

Adduction^a

During adduction of the scapula, the caudal band of the lateral GHL and joint capsule directly caudal to it provided restraint (Fig. 3-10a). The caudal joint capsule was not tensed.

Abduction^a

Both bands of the medial GHL, as well as the medial joint capsule provided restraint to excessive abduction (Fig. 3-10b). No other structures were under tension.

^a Translational and rotational evaluations were carried out at a joint angle of 135°

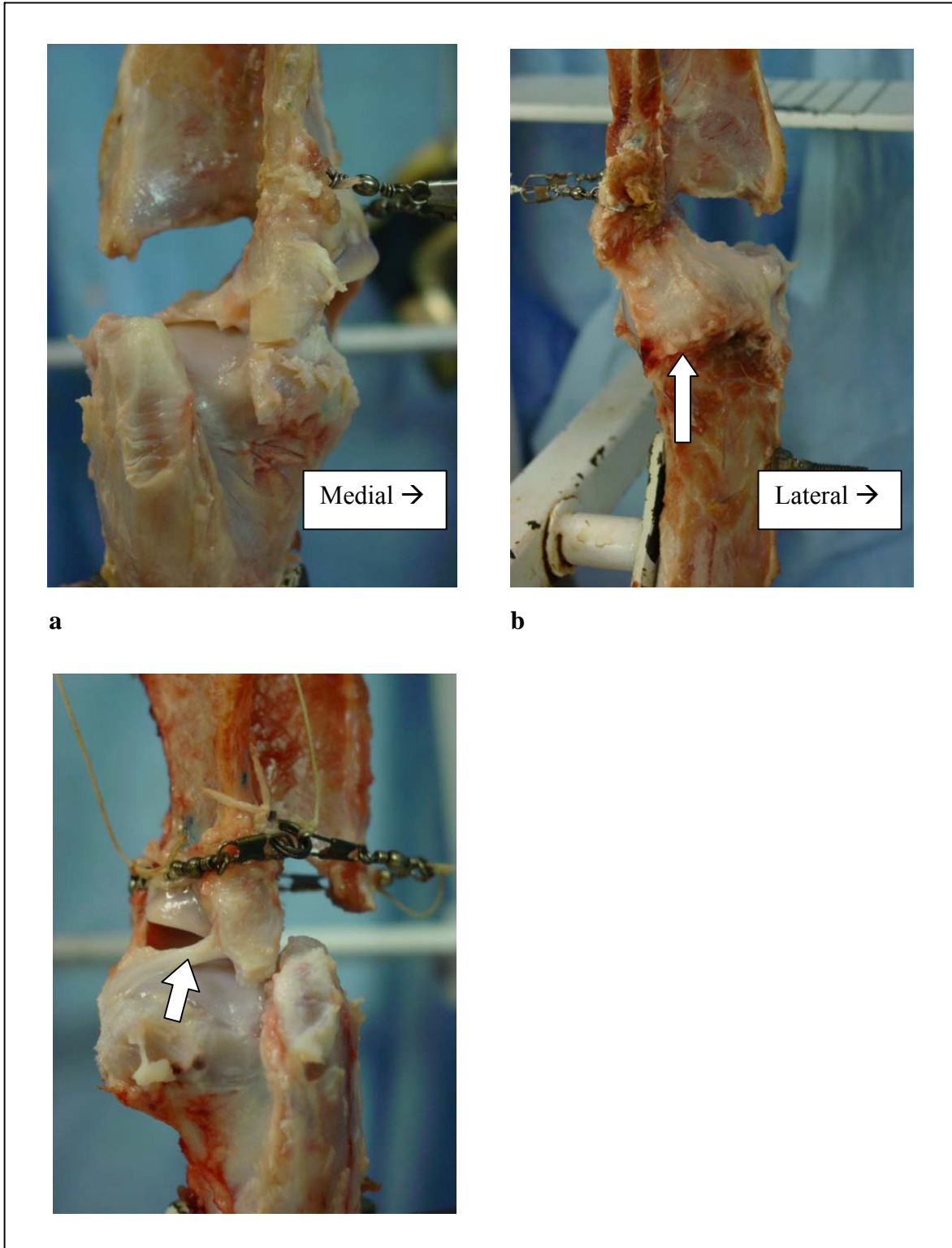


Figure 3-9a, b. Constraint of medial translation. Cranial (a) and caudal (b) views. Insertion of caudal joint capsule, arrow.

Figure 3-9c. Constraint of lateral translation. Cranial band of medial GHL, arrow.

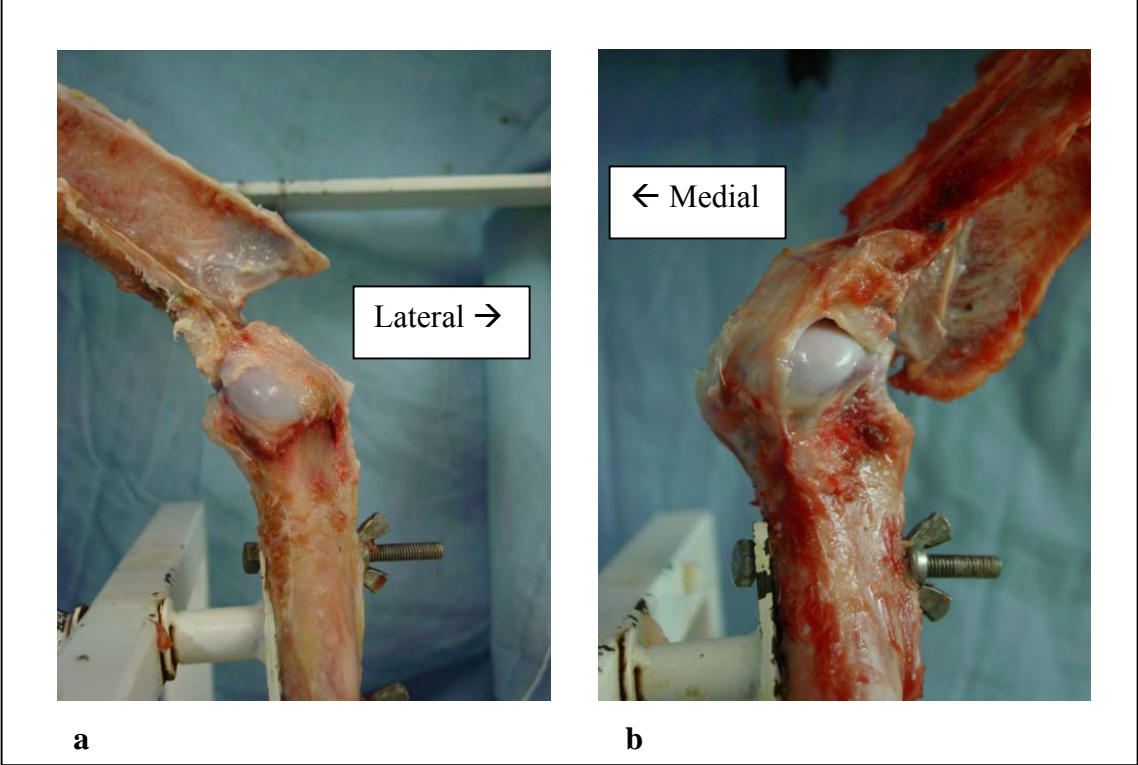


Figure 3-10. Maximum adduction (a) and abduction (b). Caudal views.

3.5. Microscopic study^a

Lateral joint capsule and glenohumeral ligament

The segment of joint capsule lying between the two bands of the lateral GHJ identified macroscopically revealed the typical components common to joint capsules. Immediately bordering the joint cavity was a zone of connective tissue elements of variable width forming the synovial membrane (synovium). The free surface of this membrane was characterised by a discontinuous layer of cells ranging from one to four cells deep. The nuclei of the cells were round to ovoid in shape although elongated forms were also observed. The elongated nuclei exhibited a denser karyoplasm than the rounder forms. Lying between the cells were bundles of collagen fibres and an extensive capillary network intimately associated with the surface of the joint cavity. The deeper part of the synovium was composed of scattered collagen fibres and fat cells in varying proportions, between which lay numerous blood vessels. Arterioles and venules were positioned close to the layer of surface cells at regular intervals. Beneath the synovium was a relatively thin layer of fibrous connective tissue which constituted the outer fibrous membrane. This membrane was composed of numerous loosely arranged sheets of collagen fibres. Typically elongated, condensed fibroblast nuclei were associated with the periphery of the collagen bundles. Larger blood vessels were located within the fibrous membrane or lay adjacent to it. The fibrous membrane was backed by loose connective tissue/adipose tissue containing small muscular arteries and veins. Synovial folds and villi were conspicuous in this part of the joint capsule. The folds were large, blunt projections of the synovium which exhibited the typical features outlined above. The villi were relatively long, slender structures composed essentially of the cellular surface layer of the synovium, although they sometimes also contained fat cells. These structures were seen to branch and were extremely rich in capillaries.

The cranial and caudal bands forming the lateral GHJ were readily discernable by light microscopy and were characterised by morphological changes to both the inner synovial membrane and outer fibrous membrane.

^a This histologic description of the medial and lateral joint structures was written by Prof. John Soley, Department of Anatomy and Physiology, Faculty of Veterinary Science, University of Pretoria.

In the region of the ligamentous bands the fibrous membrane was observed to have thickened up to five-fold. In addition, the layers of fibrous tissue appeared more compact with less intervening spaces. A large part of the membrane exhibited typical cross-sectional features of regular dense connective tissue. A notable feature was the presence of large numbers of fibroblast nuclei. In the broader and thicker caudal band, the connective tissue closest to the joint cavity was arranged in the form of fibro-cartilage blocks or sheets along part of its surface. In such regions scattered chondrocytes with round vesicular nuclei were located within lacunae. Blood vessels were absent in the fibro-cartilage units, the closest vasculature being observed between elements of the adjacent regular dense connective tissue. The narrower cranial band, in contrast, was composed almost entirely of regular dense connective tissue, with only occasional, small pockets of fibro-cartilage being observed. In comparison, the cranial band was far better vascularised than the caudal band.

In the caudal band the typical synovium described above was observed to have thinned considerably, leaving only the superficial cellular layer with its capillary network intact. At the transitional zone between the normal joint capsule and the caudal band, the cellular layer formed a distinct vascular membrane which soon petered out in the vicinity of the fibro-cartilage component. Here, the surface of the joint capsule displayed a thin layer of dense material continuous with the fibro-cartilage, embedded in which were dense, elongated nuclei. In regions of the band free of fibro-cartilage, the vascular membrane was again apparent. In the cranial band the synovium was more substantial although not as well developed as in the non-ligamentous parts of the joint capsule. The cellular layer of the synovium (vascular membrane) was almost continuous except in restricted areas occupied by fibro-cartilage. In places, arterioles and venules were also encountered adjacent to the cellular surface layer.

Medial glenohumeral ligament

A substantial part of the medial wall of the joint capsule was characterised macroscopically by a distinct thickening which protruded appreciably into the joint cavity forming the medial glenohumeral ligament. Obvious cranial and caudal bands could be distinguished and in the cranial band a deep split traversed the band dorso-ventrally.

Transverse sections of the wall of the joint capsule revealed a combination of histological features similar to those seen in the lateral wall of the capsule. Those parts of the capsule adjacent to the ligament displayed a typical synovial membrane supported by an outer fibrous membrane. The histological features of these components was similar to that described for the lateral glenohumeral ligament except that the fibrous membrane appeared thicker in parts, particularly towards the more cranial aspect of the medial wall of the joint capsule. Slender villi and blunt projections (synovial folds) were also common in this area.

In the vicinity of the medial ligament the synovial membrane displayed variable features. Along much of its length only the superficial cellular layer was visible which was restricted to a thin band of cells devoid of vascular elements. This cellular layer was interrupted by occasional, circumscribed, units of fibrocartilage with typical chondrocytes in lacunae. Short segments of vascular synovial membrane were randomly interposed between the two regions described above. Only in these areas was the cellular component of the synovial membrane supported by loosely arranged fibrous connective tissue bundles and numerous intervening fat cells. In areas displaying an avascular cellular synovium and units of fibrocartilage, the fibrous membrane of the joint capsule lay close beneath the surface of the joint capsule. The fibrous membrane was characterised by closely packed cords of regular dense fibrous connective tissue which displayed a paucity of blood vessels. When present, blood vessels lay in localised, more loosely arranged, deposits of fibrous connective tissue.

Chapter Four

Discussion

In the past, diagnosis of shoulder pathology was essentially limited to those conditions that could be identified clinically or where bony changes could be demonstrated on survey radiographs eg. tumours, osteochondritis dissecans, fracture, traumatic luxation, contracture of the tendon of insertion of the *m. infraspinatus* (Bennett 1979, Campbell 1968). Recently, there has been a dramatic increase in the number of new diagnostic techniques that have become available to veterinarians, including magnetic resonance imaging, computed tomography, ultrasonography, scintigraphy and arthroscopy. We are now able to identify subtle bone and soft tissue lesions with a great deal of precision and reliability. As a result of this and a renewed interest in the GHJ^a of the dog, a number of pathologic conditions have only been described relatively recently. These include tears to the medial and lateral GHJs^b (Bardet 1998, Mitchell 2000); mineralisation of the tendon of origin of the *m. supraspinatus* (Flo 1990, Kriegleder 1995, Laitinen 2000); inflammation, tears, and enthesophytes in the tendon of origin of the *m. biceps brachii* (Rivers 1992); incomplete ossification of the caudal aspect of the glenoid (Oliveri 2000); and “joint instability” as a clinical syndrome (Bardet 1998). Unfortunately, we are still largely in the dark with regard to the pathogenesis of these conditions, their clinical significance, and how best to treat them. There are many probable reasons for this lack of knowledge. The fact that most of these conditions have an insidious onset and are not related to an identifiable traumatic event makes early investigation and identification of the primary lesion impossible. These conditions have also not been reproduced in an experimental setting. There is also a surprising paucity of information regarding the normal biomechanical function of the GHJ of the dog to serve as a basis for pathologic comparison. The result has been that authors have extrapolated information from human studies. This may be inappropriate. It takes no more than a casual glance to identify large differences in the function, shape and biomechanics of the GHJ between these two species.

^a Glenohumeral joint

^b Glenohumeral ligament

The objectives of the present study were:

- To investigate and describe the mechanisms that contribute to static stability in the normal GHJ of the dog by means of a biomechanical study and anatomical dissections.
- To determine the degree of laxity present in the normal GHJ.
- To determine whether the extent of laxity could be reliably determined in normal dogs by means of clinical palpation/manipulation.

4.1. Palpation study

Except in cases demonstrating gross displacement, clinical examination of the GHJ usually offers few diagnostic clues other than isolating the source of the pain to the shoulder region. For example, despite the advances in diagnostic imaging techniques cited above, reliable methods to accurately determine and evaluate GHJ laxity or instability continue to elude us. Use of stress radiographic techniques have not gained widespread acceptance (Puglisi 1988). Clinical manipulations have been described to evaluate laxity in the GHJ, but neither the accuracy nor interpretation of these tests have been critically appraised and reported (Bardet 1998).

The palpation part of the present study, performed on fresh cadavers, described the normal findings that can be expected on palpation of the GHJ in medium to large breed anaesthetised dogs. The accuracy of palpation of the healthy joint was determined by comparing these findings with the objective findings of the biomechanical study. A simple allocation into 2 categories (<2mm or >2mm) was chosen, as subjective evaluation of the magnitude of translation became impossible with increased distances due to a lack of visual landmarks.

The finding that a definite “stop” was not evident at the extremes of translation in the palpation study, but was present in the specimens after muscles had been removed suggests that surrounding muscle mass may play a role in contributing to joint stability in a passive manner at the limits of translational movement. Vasseur reported that the major cuff muscles surrounding the joint (*m. infraspinatus*, *m. supraspinatus*, *m. biceps brachii*, *m. teres minor*) played little role in this respect (Vasseur 1982).

That study was, however, carried out with the limb in full extension which may have influenced results (see “locking mechanism” in biomechanical study). The results of the present study show that an abrupt “stop” to translation cannot be used as a criterion for evaluating the integrity of the static GHJ restraints as has been described in evaluation of the stifle joint.

A recent study confirmed the reliability of goniometric measurements in determining maximum and minimum GHJ angles in labrador retrievers (max=165°, min=53°) (Jaegger 2002). The average maximum angle of extension (155°) and maximum angle of flexion (53°) measured in the present study correlate fairly well with that report.

At 150°, very little or no translation was elicited in any direction. As the joint angle decreased, despite marked variation, there was an overall tendency toward increasing palpable laxity. This was also found in the biomechanical study (reported below). The proposed functional significance of this characteristic is that, at an extended or near extended joint angle (140-150+°), the static stabilisers provide a greater degree of joint constraint as the limb makes ground contact, bears weight, and exerts propulsive forces. The increased laxity in flexion may allow greater joint mobility when performing specific tasks, such as fighting, copulating, catching prey or eating.

Measurements of maximum abduction and adduction were initially planned for this part of the study, but were abandoned due to difficulty in accurately establishing the plane of the scapula at all angles.

4.2. Biomechanical study

The biomechanical study was designed to investigate the normal constraints provided by the static stabilising mechanisms (GHL/JC^a complex and LJV/AC^b mechanisms), and evaluate their relative importance by comparing measurements between intact and vented joints when a fixed force or moment was applied at various angles of extension.

^a Glenohumeral ligament / joint capsule

^b Limited joint volume / adhesion/cohesion

In human studies, venting and irrigation has been employed to eliminate the LJV/AC mechanisms (Gibb 1991, Kumar 1985, Matsen 1998).

The average maximum joint angle was identical (155°) to that measured in the palpation study. This shows that maximum extension is limited by the static stabilisers of the joint. The average minimum joint angle was markedly less than that measured in the palpation study (33.7° versus 53°). This was seen to be due to bunching of the muscle mass caudal to the GHJ that restricted further flexion of the palpation study limb.

Locking mechanism

Translation and rotation variables were significantly less at a joint angle of 150° than at other angles. This was due to the “locking mechanism” created by tension on the caudal joint capsule and compression of the supraglenoid tubercle and tendon of origin of the *m. biceps brachii* within the intertubercular groove of the humerus (resulting in a concavity compression effect). This locking mechanism provided primary restraint and limited all other movement. At 135° and 90° degrees extension, as the glenoid cavity translated caudally relative to the humeral head, the caudal joint capsule became lax and the constraining effect of the intertubercular groove disappeared. This released the locking mechanism and allowed progressively greater translational and rotational movements in both intact and vented joints. The increase in laxity occurred in an almost linear fashion.

Relationship of the GHJ/JC complex to the LJV/AC mechanisms

To evaluate the relative constraints provided by the GHJ/JC complex and the LJV/AC mechanisms, intact and vented joints were compared for differences in translation and rotation when a force or moment was applied to them. For the AC mechanism to be neutralised in the intact joint, the bonds between individual synovial fluid molecules and between the synovial fluid molecules and the joint cartilage must be broken. In human studies, venting the joint neutralised the LJV/AC mechanisms. Irrigation of the joint flushed out the viscous synovial fluid. In human texts, the AC mechanism is not considered to provide a strong adhesive force and so probably makes up a minor component of the combined LJV/AC mechanisms {Matsen shouler 1998}.

For the LJV effect to be overcome, the joint volume would have to be increased. Increasing the volume of a sealed joint would require considerably greater force as evidenced by the force required to separate Magdeberg spheres (see literature review).

There was no statistically significant difference between intact and vented joints for most variables measured in the present study. The exceptions were cranio-caudal translation at 90° and 135° and medial/lateral translation at 135°. It would appear, therefore, that the LJV/AC mechanisms did not contribute significantly to the constraint of joint motion for all other variables measured. It may, however, perform a shock absorbing function by limiting the rate of translation or rotation (somewhat like a hydraulic door stay).

The abovementioned exceptions suggest that the LJV/AC mechanisms were not neutralised in this trial. It is also possible that at lower forces the difference in translation between intact and vented joints may have been significant in other directions. In fact this is quite likely as, subjectively, the intact joint is less lax than the vented joint on application of small forces, especially with regard to traction, which was not measured in the present study. This would have to be substantiated in subsequent studies. It should be noted that where differences in translation/rotation between intact and vented joints were not statistically different, they were also not statistically similar ($p > 0.05$). It is possible, therefore, that a type two error resulted where differences were too small to achieve statistical significance. This mechanism may, therefore, still have a minor role to play when minimal forces are acting on the joint, such as when the dog is at rest.

To explain the lack of difference between intact and vented joints for most variables in this study, the author proposes the following: The combination of the lax GHJ/JC complex and volume of synovial fluid present in the canine GHJ will allow a wide range of motion without altering total joint volume (and thus engaging the LJV effect), leaving only the weak AC part of the mechanism to be overcome. During translation or rotation, the joint capsule adheres to any exposed articular surface of the humeral head that is not covered by the glenoid cavity and moves into gaps that may develop between the joint surfaces (sulcus effect) (Matsen 1991). Synovial fluid is redistributed from compressed areas to those that are distracted. These features enable considerable range of motion without changing the overall joint volume.

The result is that the GHL/JC complex provides restraint before the LJV mechanism is activated, for movement in most directions. The magnitude of the AC mechanism may be limited by the fact that the joint surfaces are actually incongruent with more contact at the cranial and caudal edges of the glenoid cavity than centrally, at a standing angle (Maierl 2002). The AC mechanism is dependant on congruity to create a thin film and exert its adhesive effect.

The above explanation would not apply to cranio-caudal translation at 90° and 135° extension where a significant difference was noted between intact and vented joints. As we have seen, laxity of the GHL/JC complex allows considerable translation at these angles (Average: 8.8mm and 12.6mm respectively). The relatively deep cup formed by the glenoid cavity in a cranio-caudal direction means that the joint surfaces have to separate some distance (with only one contact point – the supraglenoid tubercle or caudal glenoid rim on the humeral head) to allow translation. The joint space would have to widen quite dramatically and thereby increase the joint volume, engaging the LJV/AC mechanism.

The significant difference between intact and vented joints for medial/lateral translation at 135° is more difficult to explain. The glenoid cavity is remarkably shallow in this direction (1-2mm depth) and translation should not require much joint distraction. In addition, with further flexion (a joint angle of 90°), no significant difference in translation was evident for this parameter. A possible explanation, supported by subjective observations during the anatomical part of this study, is that the cranio-lateral aspect of the glenoid is forced to ride up onto the caudal aspect of major tubercle (and in the live dog - the tendon of insertion of the *m. supraspinatus*) when lateral force is applied, leading to divergence of the joint surfaces. This separation of the joint surfaces would activate the LJV/AC mechanism.

A clinical consequence of the above findings (and the subjective impression that the LJV/AC mechanism provides significant constraint when small forces are applied to the joint) is that joint effusion or tearing of the joint capsule could increase passive cranio-caudal joint laxity. This may further complicate interpretation of subjective clinical palpation findings.

Comparison to human studies

Biomechanical studies performed on human cadavers have found a significant difference in translation and rotation between vented and unvented shoulders (Gibb 1991, Kumar 1985). In the study by Gibb, anterior (cranial), posterior (caudal), and inferior (ventral) translation were evaluated. A significant difference was found between vented and unvented joints for these 3 parameters. Anterior/posterior translation in the human would very roughly translate into medial/lateral translation in a dog at a joint angle of 90°. The differences between these limited human studies and the present one could relate to a relatively greater amount of synovial fluid in the canine GHJ. Both humans and dogs have, on average just less than 1ml of synovial fluid in this joint, despite the marked discrepancies in size (Matsen 1991, Simkin 1984). Added to this, humans may have relatively more abundant joint capsule (required for the greater range of motion) that is collapsed on itself most of the time due to the small amount of synovial fluid. Another possible factor is the presence in humans of a significant glenoid labrum. This could help to seal the joint surfaces when they are compressed and provide an added “suction cup” effect. This effect will enhance the LJV/AC mechanisms by reducing the effective joint volume to that space between the two cartilage contact surfaces. The canine labrum is very poorly developed and not even macroscopically present in many specimens.

The vented human joint can translate up to 45 mm in an anterior-posterior plane and some people have so much redundant joint capsule that they can luxate the joint voluntarily without any pathology (Matsen 1998). Dogs have a relatively tighter GHJ/JC complex that decreases the chance of the LJV/AC mechanisms making a significant contribution to stability. It was noted that the joint capsule of the dog is not collapsed in a neutral position but pouches out with fluid that has been forced out of the joint space. Another possible reason for the different findings between human studies and the present one is that the dog may have a more pliable joint capsule that is easily deformed and moves in between distracted joint surfaces (sulcus effect). The author’s observations during the course of the present study would support this. Such flexibility in the capsule would be considered abnormal in humans. The study by Gibb used specimens from people who were between 57 and 87 years of age which may have also been a reason that joint capsules were less pliable.

Laxity versus instability

The wide inter-specimen disparity between measured variables for the present study is probably due to differences in size of specimen, significant individual variations in the quantity of joint fluid within the joint, and differences in the relative laxity of the GHL/JC complex. This makes quantification of “normal” parameters for joint laxity impossible. Attempting to quantify subtle increases in joint laxity may not be worth pursuing since even if a reliable method were found, one would still not know what the clinical significance was.

In human medicine, a distinction is made between GHJ laxity and GHJ instability. GHJ *laxity* could be pathologic or physiologic. It is quite variable between individuals. For example, the palpable laxity of a supple gymnast will be far greater than a middle-aged non-athletic businessman of the same size and weight (Matsen 1998). GHJ *instability* is a sub-category of laxity that is pathologic and has been defined as “an inability to keep the humeral head centered in the glenoid cavity during normal range of motion” (Matsen 1998). Diagnosing luxation is relatively simple. Distinguishing a more subtle instability from laxity is less dependant on quantitative differences in translation/rotation than whether the laxity is uncomfortable for the patient, or compromises joint function (Matsen 1991, Lazarus 1996). Such symptoms would suggest that the stabilizers of the shoulder as a whole (dynamic and static) are not keeping the humeral head centered in the glenoid cavity. Interestingly, Matsen found that there was no difference in laxity between a study of normal joints and one of clinically unstable joints requiring surgery. He, therefore, suggests that examination under anaesthesia and the observation of GHJ laxity during surgery cannot be used to confirm of a diagnosis.

Instability in the GHJ of people is broadly divided into 2 major categories. The first is the so-called “TUBS^a” syndrome that is the result of a traumatic injury with tearing of the glenoid labrum along with the attachment of the anterior inferior GHL complex. This leads to unidirectional anterior instability and is traditionally surgically repaired. In dogs, this is similar to tearing the medial GHL as described in dogs by Bardet (Bardet 1998). These lesions have been reported to cause GHJ “instability” in dogs (Bardet 1998).

^a “TUBS” denotes: **T**raumatic, **u**nilateral, **B**ankart lesion, requires surgery

Whether actual instability (inability to maintain the humeral head centred in the glenoid cavity) results from GHJ/JC complex lesions has not been objectively documented in dogs. Current methods of diagnosing instability (history, clinical examination, arthroscopy) as a cause of lameness require validation. The findings of the current study, as well as findings in other studies would suggest that isolated torn medial (or lateral) GHJs should simply go on to heal without incident or intervention (Vasseur 1983b). Yet, in some cases they clearly do not heal spontaneously, as evidenced by GHJ tears visualised arthroscopically following chronic thoracic limb lameness (Bardet 1998, Mitchell 2000). It has been theorised that the reason for this apparent paradox is that these injuries become chronic as a result of ongoing high load repetitive microtrauma that prevents healing. The basis for this theory is the typical lack of a known traumatic incident, with a rather tenuous citation of human studies where it has been found that athletes involved in field sports (where they throw things a lot) tend to suffer this type of injury. Since the GHJ of the dog essentially behaves in a ginglymous (hinge joint) fashion (Bardet 1998, Evans 1993, Kinzel 1976), it is unlikely that a dog would be attempting to abduct the limb in excess of 34° (average abduction permitted by the GHJ/JC complex) or rotate it in excess of 60-80° (average range of internal/external rotation permitted by GHJ/JC complex) on a regular basis during normal daily activity. The GHJ/JC complex should be well protected during joint loading by the dynamic stabilisers. The theory that instability results from repetitive microtrauma is further brought into question by the fact that the vast majority of reported cases only suffer instability on one side. Yet the dog is not known to have a dominant side. In one study, only 1/46 dogs was diagnosed with instability in both limbs (Bardet 1998). In the same study, 64% of the dogs diagnosed with joint instability had minimal or no radiographic osteoarthritis even though most had a history of chronic lameness ranging from 2 months to several years (50% had an erosion of the medial glenoid rim identified arthroscopically) (Bardet 1998, Bardet 2002a). One would, perhaps, have expected more evidence of osteoarthritis from a persistent instability.

The author proposes two separate theories to attempt to explain this apparent paradox:

1. A pathologic instability is responsible for ongoing trauma to the GHJ. In this case, the cuff muscles (dynamic stabilisers) are not functioning as they should (protecting the GHJ/JC complex). This could be due to lack of proprioceptive feedback from the damaged GHJ/JC complex or primary muscle pathology.

Alternatively, excessive forces and moments acting about the joint due to conformational or gait characteristics could overwhelm the dynamic stabilisers (similar to Slocum's theory regarding rupture of the cranial cruciate ligament in the stifle (Slocum 1983, Slocum 1984, Slocum 1993). Whatever the cause, inefficient muscle support could place excessive stress on the joint and supporting structures (static stabilisers) during normal motion.

2. Traumatic tearing of the GHL may not lead to ongoing functional instability of the joint, hence little or no evidence of osteoarthritis. In this case, other unknown factors (e.g. an auto-immune reaction to exposed collagen) could result in continued joint pain, further ligamentous degeneration, and failure to heal. Elevated levels of Type 1 and Type 2 collagen antibodies are commonly found in cruciate deficient and other osteoarthritic joints (de Rooster 2000).

In humans, the second major category of GHJ instability is the so-called "AMBRII"^a syndrome where the patient is born with or develops a more general laxity of the joint that results in excessive anterior and posterior translation. These are usually treated conservatively with techniques designed to build up the stabilizing contribution of the cuff muscles. This may be similar to congenital instability in dogs – an instability that could ultimately lead to luxation. Dogs, however, will often have malformed joints in addition to the instability. These cases are usually only presented after complete luxation, which may occur at any age.

It should be borne in mind that pathologic conditions of the human GHJ may have completely different pathogeneses to those in the dog because of the substantial differences in structure and function.

Comparison of palpation and biomechanical studies

The comparison of translation elicited on palpation to that measured in the biomechanical study showed a poor correlation in most cases. This may be due to a number of factors: The confounding effect of intervening muscle mass (especially in medium and well muscled specimens); difficulty in categorising translations close to 2mm due to the intervening muscle mass and lack of visual landmarks; differences between the two studies in the direction of

^a "AMBRII" denotes: **A**traumatic, **m**ultidirectional with **b**ilateral findings **r**esponsive to rehab or surgery – **i**nferior capsular shift or rotator **i**nterval closed.

tension applied; variation in the joint angle during palpation; or the passive effect that muscles may have in providing stability.

The findings of the present study apply only to healthy joints, but the author suggests that the results of the above comparison should be borne in mind if making use of “drawer” type^a translational manipulations as a diagnostic tool to evaluate GHJ stability. Bardet described the technique on which the present study was based (Bardet 1998). He did not report specific findings, but suggested that it was possible to identify abnormal laxity by comparison with the contra-lateral limb. One obvious limitation to this approach is that bilateral pathology may be present and missed. The results of the present study suggest that it is very difficult to clinically quantify subtle differences in translational distance with the methods described. This may limit the value of comparison with the contra-lateral limb. This finding is similar to another report where palpable laxity could not be elicited in dogs that had torn the lateral GHL (Mitchell 2000). When attempting a comparison of limbs, it is important to ensure that both limbs are evaluated at the same joint angle.

Limitations of the biomechanical study

Unfortunately, almost nothing is known about the magnitude of forces that act around the GHJ (or any other joint) in the dog, including the forces that make up the LJV or AC mechanisms. A limitation of this part of the study is that it was assumed that the LJV/AC mechanisms could withstand the arbitrarily designated force of 15N (or moment of approximately 0.23Nm) applied and, if they couldn't, then they didn't make a significant contribution to joint stability during loading. A comparison with forces used in similar human studies shows that the LJV/AC mechanisms should be able to withstand considerably more than 15N. One human study showed that the AC/LJV mechanisms provided a mean stabilising force of 146N and two other studies have showed significant differences between intact and vented joints at 40N and 50N respectively (Gibb 1991, Matsen 1998). The force at which the LJV and AC mechanisms are overcome also remain undetermined.

^a A “drawer” test has been described, and is commonly used, to determine the integrity of the cruciate ligaments of the stifle joint. The distal femur is grasped with one hand and the proximal tibia with the other. Cranial and caudal movement of the tibia relative to the femur is assessed by applying a force to the proximal tibia (Vasseur 2003).

Further studies in the dog, using progressively changing forces would provide more detailed information about the magnitude of the forces active in the AC/LJV mechanisms.

A manual testing technique was used, which could be subject to user error. All translational measurements were repeated three times and good repeatability was shown, however. Standard deviations varied but were very small: 0.04 to 0.18mm (Table A10).

A pure moment was applied to the distal scapula for internal and external rotational measurements. The unit of measurement of a moment is Newton-meters (Nm) and is defined by the formula: $Moment (Nm) = F \times d \cos \alpha$, where F = force in Newtons, d = length of the lever arm in meters, and α = the angle of the force in degrees relative to the perpendicular of d. The moment varied slightly between specimens. This was due to small differences in the length of the lever arm (distance between the cranial and caudal rings on the scapula) and variations in the angle of rotation. Variations were very small (standard deviation: 0.04Nm) and are reported (Table A9). They are unlikely to have had any material influence on results. A moment was also applied to the dorsal scapula for measurement of abduction, adduction, maximum flexion, and maximum extension. The length of the lever arm for these parameters (length of the scapula) was not measured at the trial and radiographs were collimated to the GHJ, making subsequent measurement impossible. This distance could have varied significantly. The moment applied to intact and vented joints of the same specimen would have been similar, making comparisons valid, but cognisance should be taken of this flaw in the study design when interpreting the results of inter-specimen comparisons (e.g. average abduction or adduction).

A concern raised with regard to the design of this study was that freezing, storage, and thawing of specimens might change the viscosity of the synovial fluid and material properties of the soft tissue, thereby affecting results. Due to a lack of sufficient quantity, objective measurements were not carried out to determine synovial fluid viscosity, but subjective evaluation indicated that the viscosity of the fluid was not significantly impaired during freezing, storage or thawing. The author does not know of any studies evaluating the effect of freezing on the biomechanical characteristics of soft tissues.

4.3. Anatomical dissection study

The reader is referred to chapter three for a detailed description of the joint structures and their contribution to constraint of joint motion. To the best of the author's knowledge, a detailed description of the specific functions of each component of the static constraints to joint motion has not been previously published. Most of the joint structures have been identified and reported in the literature. The findings reported in the present study largely corroborate those descriptions.

A number of issues warrant further discussion:

Glenohumeral ligament/joint capsule complex

The GHL/JC complex appears to be a more complex structure than previously described (Evans). The lateral GHL has been described as a single band running from the rim of the glenoid cavity to the caudal part of the major tubercle of the humerus (Bardet 1998, Craig 1980, Evans 1993). Dissections in this study confirmed the presence of the lateral GHL within the lateral JC. However, the lateral GHL consistently comprised a combination of separate cranial and caudal bands that blended into one broad structure proximally to give the ligament an inverted-U shape. The cranial band ran lateral and slightly caudal to the tendon of origin of the *m. biceps brachii* and inserted on the medial aspect of the major tubercle. It was significantly smaller than the caudal band. This cranial band of the lateral GHL has not, to the author's knowledge, been previously described. Its function is uncertain, as it only came under tension in this study at maximum joint flexion after muscles had been removed. Maximum flexion is probably seldom achieved in the live animal due to the restrictive effects of the muscle mass caudal to the GHJ.

The Y-shaped medial GHL has been described and is easily identified during arthroscopic procedures (Bardet 1998, Craig 1980). The fact that the cranial band runs medial to the joint capsule and is only loosely attached to it should, perhaps, be highlighted. Also of interest is that the cranial band of the medial GHL and the cranial medial joint capsule arise from different origins. This supports Bardet's finding (Bardet 1998). The medial joint capsule originates on the scapula neck about 5-6mm proximal to the glenoid rim whereas the cranial band of the medial GHL inserts on the glenoid rim itself.

To the authors' knowledge, the narrow fold of joint capsule identified craniomedial to the tendon of origin of the *m. subscapularis* in some specimens has not been previously described. It takes origin from the craniomedial glenoid rim on the ventral aspect of the coracoid process (blending with the origin of the cranial band of the medial GHL) or from the medial GHL itself. It inserts on the medial aspect of the minor tubercle of the humerus within the inter-tubercular groove. It appears ligamentous due to its folded orientation. When straightened out, there appears to be no obvious difference in the thickness between this band and the surrounding joint capsule. However, in three of the four specimens (two dogs) examined histologically, a clear fibrous band was visualised in this area running within the joint capsule. A similar fold in the joint capsule has been described in the human shoulder, and termed the coracohumeral ligament (Cooper 1993, Ferrari 1990). For clarity and simplicity, and despite the fact that it is not a true ligament, the author proposes that the same term be adopted for this structure in the canine GHJ. In humans, the coracohumeral ligament plays a role in restraining external rotation of the humerus, preventing excessive distraction, and maintaining the biceps tendon in the intertubercular groove. The same may be true in dogs. Its function is, however, uncertain as it was only noted to come under tension on maximal flexion of the dissected joint in the present study.

The caudal aspect of the glenohumeral joint capsule plays a greater role in providing restraint to joint mobility than has been ascribed to it. Despite the fact that it appears quite thin, it provides the first restraint against hyper-extension. It also plays a role in restricting rotational movements, cranial and caudal translation, and medial and lateral translation. The caudal aspect of the joint capsule could come under tension on a regular basis in the live animal. This may explain why osteophytes are most commonly identified at the caudal aspect of the humeral head (Barthez 1993, Kinzel 1976, Vasseur 1983b). Regular tension in this area may also play a role in the development of incomplete ossification of the caudal aspect of the glenoid cavity (Oliveri 2000).

This study confirmed the important role that the medial and lateral GHL play in providing a final restraint to excessive rotational and translational movements (Craig 1980, Puglisi 1986, Vasseur 1982).

It was also found that the tendon of origin of the *m. biceps brachii* does not come under tension with any of the manipulations carried out, supporting the theory that it plays little or no role in providing static stability (Vasseur 1982). Other studies have claimed that this tendon plays an important role in providing cranial joint stability (Craig 1980) and that a tendon repair should be attempted in cases of shoulder luxation where it has been torn (Bennett 1979, Craig 1980). It may play a significant back-up role in providing joint stability by its cranial tethering effect as a dynamic stabiliser in otherwise compromised joints.

Primary stability

The issue of which structure/s provide primary stability to the joint has been discussed in the literature (Bardet 1998, Craig 1980, Puglisi 1986, Vasseur 1982). The normal extent of joint translation in the live dog during normal daily activity is not known. However, it is difficult to imagine that translations of the magnitude recorded in the present study in intact joints is tolerated, or that they could occur on a regular basis without significant damage to the joint surface. An interesting human study showed that it is not possible to rotate the shoulder joint by muscle contraction to the extent that the GHJ/JC would allow (Karduna 1996). The author believes this to be true in dogs as well. In other words, it is very unlikely that a dog would be able to voluntarily rotate its GHJ to the same degree measured for the static stabilisers in the present study. The present study shows that the static stabilisers allow a considerable degree of translation and rotation. An *in vivo* biomechanical trial evaluating joint motion in a single healthy dog showed that internal/external rotation and abduction/adduction varied by no more than 10-15 degrees at a walk and going up stairs (Kinzel 1976). These findings would support the theory that the surrounding “cuff” muscles (dynamic stabilizers) provide restraint to the joint during normal activity (Craig 1980). While the function of the cuff muscles have been mentioned in the literature in this regard, their relative importance has, perhaps, been understated in recent times. In human medicine, it is generally accepted that stability of the joint is provided by the cuff muscles through the normal range of motion with the GHJ/JC complex only providing constraint at extremes of joint motion (Lazarus 1996). The results of the present study suggest that the same holds true in dogs. This has important implications with regard to surgical repair.

Imbricating the joint capsule, as has been suggested in the veterinary literature for repair of joint luxations (Piermattei 1997) or tight prosthetic capsular repairs for the repair of torn GHJ/JC complexes or subscapular ligaments should be performed with caution. Tightening the joint capsule beyond physiologic norms could have an adverse effect on the normal range of joint motion and the proprioceptive feedback mechanism. Prosthetic repair techniques should also take into account the normal increase in laxity with decreasing joint angles.

It may be an over-simplification to attempt to classify stabilising mechanisms in the GHJ as primary or secondary. They probably all play an integrated role, providing components of both categories that vary according to the position of the joint and stresses applied. For example, the GHJ/JC complex may provide primary restraint at hyper-extension, but only play a secondary role by providing constraint at the extremes of motion in other directions. The cuff muscles probably play the most important role during regular activity, with the LJV/AC mechanisms perhaps having a role to play when at rest. The LJV/AC mechanisms could also provide a shock-absorbing effect. In addition, it has been shown in humans that the GHJ/JC complex has proprioceptive nerve endings that initiate reflex, compensatory contractions in the cuff muscles when stimulated by stretching. These cross-over and secondary mechanisms would help explain the fact that any stabilizing structure surrounding the joint can be transected in isolation without having a marked adverse effect on joint function (Vasseur 1983).

The present study has shown that in the normal joint, for the humerus to luxate in a medial or lateral direction (and maintain its alignment with the scapula), both the medial and lateral GHJ/JC must be transected (complete spatial joint derangement). A similar observation has been reported previously (Puglisi 1988). If either the medial or lateral GHJ/JC complex is torn independently, the joint will luxate by rotation around the remaining GHJ/JC complex (hence, taking radiographs with the limb held in alignment will often result in relocation (Puglisi 1986, Puglisi 1988)). A conscious dog with all other peri-articular GHJ structures intact is unlikely to allow luxation by rotation to occur. If isolated GHJ tears do result in luxation by rotation, then it may be adequate to address only the rotational instability when considering surgical repair.

4.4 Microscopic study

The joint capsule of the GHJ in the four limbs (two animals) examined histologically showed a typical and well-described appearance. The presence of a discrete cranial and caudal band to the lateral GHL was confirmed. The larger caudal band showed patches of fibro-cartilage, in addition to the dense connective tissue. A fibrous band running in the region as the described synovial coracohumeral ligament was identified within the joint capsule in three out of four specimens.

Chapter 5

Conclusion

This study has identified a number of features that improve our understanding of the biomechanical function of the canine glenohumeral joint (GHJ).

The locking mechanism of the GHJ has been described where translation and rotation were severely limited at full extension. This was due to tension on the caudal joint capsule and compression of the supraglenoid tubercle and tendon of origin of the *m. biceps brachii* within the intertubercular groove of the humerus. As the glenoid cavity translated caudally relative to the humeral head, the caudal aspect of the joint capsule became lax and the constraining effect of the intertubercular groove disappeared. This released the locking mechanism and allowed progressively greater translational and rotational movements in both intact and vented joints.

An important finding is that the normal GHJ of the dog allows a considerable amount of translation and rotation when flexed. This varies quite widely between individuals (sometimes even between limbs from the same individual) and increases as the joint angle decreases. It is unlikely that this freedom of movement is permitted in the healthy live animal. The static stabilisers are, therefore, unlikely to be tested during normal range of motion in the live dog except in extension. The cuff muscles probably play an important role in providing primary stability to the joint during normal activity. It is, however, likely that the functions of the static and dynamic stabilisers are integrated and functions are shared depending on the position and loading of the joint.

The natural laxity of the static stabilisers of the GHJ should be borne in mind when interpreting biomechanical studies and designing future studies. This characteristic should also be considered when performing or designing examination techniques to determine pathologic joint laxity, or when evaluating or developing new surgical techniques to repair laxity, instability or luxation.

This study has shown that the correlation between clinical palpation and the actual degree of laxity present in normal GHJs is poor. This is probably also true of joints suffering a mild to moderate increase in laxity due to pathology. It has highlighted the need to develop new, more reliable methods to confirm the existence of joint instability so that we can tailor our therapeutic interventions to directly target the source of the animal's discomfort. Two theories have been proposed to explain the phenomenon of chronic medial GHJ injury, which may have application to other chronic shoulder conditions:

1. A pathologic instability is responsible for ongoing trauma to the GHJ as a result of abnormal function of the dynamic stabilisers. This abnormal function could be due to primary muscle disease or the result of deficiencies in joint proprioceptive feedback, or conformational and gait characteristics.
2. An increased laxity of the joint may or may not be present but other unknown factors result in ongoing joint pain and a progression of ligamentous degeneration.

It would appear that the LJV/AC^a mechanisms do not significantly add to the constraint provided by the GHJ/JC^b complex except where the joint capsule is relatively lax (i.e. flexion) **and** where translation would result in a large separation of joint surfaces – cranio-caudal translation (90° and 135°) and medial/lateral translation (135°). The LJV/AC mechanisms may, however, play a role in providing stability at rest or act as a shock absorber.

A comparison between the results of this study and similar human studies showed important differences. These may relate to differences in the relative amount of joint fluid, extent of the glenoid labrum, and redundancy of the joint capsule. Direct extrapolation from human studies to the animal model should be made with caution.

This study has confirmed that the medial and lateral GHJs^c provide static constraint to the GHJ, especially in rotation, abduction and adduction. In addition, the caudal joint capsule has been identified as an important structure in providing constraint to excessive extension, rotation and translation.

^a Limited joint volume and adhesion/cohesion

^b Glenohumeral ligament/joint capsule

^c Glenohumeral ligament

This may explain the fact that GHJ osteophytes are often found in the region of caudal joint capsule insertion. The coracohumeral ligament and the cranial band of the lateral GHL are two intracapsular structures that have been described.

Suggestions for further study

- Repeating the biomechanical tests performed in this study using a more sophisticated apparatus to quantify the effects of the LJV/AC mechanisms. Application of a progressive increase in force and constant measuring of displacement would provide valuable additional information.
- Similar studies, carried out on dogs thought to be suffering from pathologic joint laxity, would provide interesting comparisons.
- If an *in vivo* method to determine the direction and magnitude of forces active across the joint during loading could be devised, these results would also contribute important information.
- To devise a reliable technique to evaluate and determine pathologic joint instability.

List of References

Bardet JF (1998), Diagnosis of shoulder instability in dogs and cats: a retrospective study, *Journal of the American Animal Hospital Association*. 34: 42-54

Bardet JF (2002a), Shoulder diseases in dogs, *Veterinary Medicine* 97: 909-918

Bardet JF (2002b), Shoulder instability and joint pain in dogs and cats. ESVOT/VOS 1st World Orthopaedic Veterinary Congress, Munich, Germany. 40-42

Ref Type: Conference Proceeding

Barthez PY, Morgan JP (1993), Bicipital tenosynovitis in the dog - evaluation with positive contrast arthrography, *Veterinary Radiology & Ultrasound*. 34: 325-330

Bechtol CO (1980), Biomechanics of the shoulder, *Clinical Orthopaedics & Related Research*. 37-41

Bennett D, Campbell JR (1979), Unusual soft tissue orthopaedic problems in the dog, *Journal of Small Animal Practice*. 20: 27-39

Bigliani LU, Kelkar R, Flatow EL, Pollock RG, Mow VC (1996), Glenohumeral stability. Biomechanical properties of passive and active stabilizers. [Review] [79 refs], *Clinical Orthopaedics & Related Research*. 13-30

Cain PR, Mutschler TA, Fu FH, Lee SK (1987), Anterior stability of the glenohumeral joint. A dynamic model, *American Journal of Sports Medicine*. 15: 144-148

Campbell JR (1968), Shoulder lameness in the dog, *Journal of Small Animal Practice*. 9: 189-198

- Cooper DE, O'Brien SJ, Warren RF (1993), Supporting layers of the glenohumeral joint. An anatomic study, *Clinical Orthopaedics & Related Research*. 144-155
- Craig E, Hohn RB, Anderson WD (1980), Surgical stabilization of traumatic medial shoulder dislocation, *Journal of the American Animal Hospital Association*. 16: 93-102
- de Rooster H, Cox E, van Bree H (2000), Prevalence and relevance of antibodies to type-I and -II collagen in synovial fluid of dogs with cranial cruciate ligament damage, *American Journal of Veterinary Research*.61(11):1456-61,
- Evans HE (1993), Arthrology, in *Miller's Anatomy of the Dog*, ed. Evans HE, W.B. Saunders, Philadelphia p 219-257
- Ferrari DA (1990), Capsular ligaments of the shoulder. Anatomical and functional study of the anterior superior capsule, *American Journal of Sports Medicine*. 18: 20-24
- Flo GL, Middleton D (1990), Mineralization of the supraspinatus tendon in dogs, *Journal of the American Veterinary Medical Association*. 197: 95-97
- Gibb TD, Sidles JA, Harryman DT, McQuade KJ, Matsen FA, III (1991), The effect of capsular venting on glenohumeral laxity, *Clinical Orthopaedics & Related Research*. 120-127
- Habermeyer P, Schuller U, Wiedemann E (1992), The intra-articular pressure of the shoulder: an experimental study on the role of the glenoid labrum in stabilizing the joint, *Arthroscopy*. 8: 166-172
- Halder AM, Zhao KD, Odriscoll SW, Morrey BF, An KN (2001), Dynamic contributions to superior shoulder stability, *Journal of Orthopaedic Research*. 19: 206-212
- Itoi E, Motzkin NE, Morrey BF, An KN (1993), Bulk effect of rotator cuff on inferior glenohumeral stability as function of scapular inclination angle: a cadaver study, *Tohoku Journal of Experimental Medicine*. 171: 267-276

Jaegger G, Marcellin-Little D.J., Levine D (2002), Reliability of goniometry in Labrador Retrievers, *American Journal of Veterinary Research*. 979-986

Karduna AR, Williams GR, Williams JL, Iannotti JP (1996), Kinematics of the glenohumeral joint: influences of muscle forces, ligamentous constraints, and articular geometry, *Journal of Orthopaedic Research*. 14: 986-993

Karduna AR, Williams GR, Williams JL, Iannotti JP (1997), Glenohumeral joint translations before and after total shoulder arthroplasty. A study in cadavera, *Journal of Bone & Joint Surgery - American Volume*. 79: 1166-1174

Kinzel GL, Van Sickle DC, Hillberry BM, Hall AS, Jr. (1976), Preliminary study of the in vivo motion in the canine shoulder, *American Journal of Veterinary Research*. 37: 1505-1510

Kriegleder H (1995), Mineralization of the supraspinatus tendon: clinical observations in seven dogs, *Veterinary and Comparative Orthopaedics and Traumatology* 8: 91-97

Kumar VP, Balasubramaniam P (1985), The role of atmospheric pressure in stabilising the shoulder. An experimental study, *Journal of Bone & Joint Surgery - British Volume*. 67: 719-721

Laitinen OM, Flo GL (2000), Mineralization of the supraspinatus tendon in dogs: a long-term follow-up, *Journal of the American Animal Hospital Association*. 36: 262-267

Lazarus MD, Sidles JA, Harryman DT, Matsen FA, III (1996), Effect of a chondral-labral defect on glenoid concavity and glenohumeral stability. A cadaveric model, *Journal of Bone & Joint Surgery - American Volume*. 78: 94-102

Levick JR (1983), Joint pressure-volume studies: their importance, design and interpretation, *Journal of Rheumatology*. 10: 353-357

Maielr J, Eller D, Böttcher P, Hecht S, Matis U, Liebich HG (2002) Biomechanical properties of the canine shoulder joint. ESVOT/VOS 1st World Orthopaedic Veterinary Congress, Munich, Germany. 136

Ref Type: Conference Proceeding

Matsen FA, Harryman DT, Sidles JA (1991), Mechanics of glenohumeral instability, *Clinics in Sports Medicine* 10: 783-788

Matsen FA, Thomas SC, Rockwood CA, Wirth MA (1998), Glenohumeral instability, in *The Shoulder*, ed. Rockwood CAJ and Matsen FA, W.B. Saunders, Philadelphia p 611-689

McKee WM, May C, Macias C (2002) Infraspinatus bursal ossification (IBO) in eight dogs. ESVOT/VOS 1st World Orthopaedic Veterinary Congress, Munich, Germany. 141

Ref Type: Conference Proceeding

Mitchell RA, Innes JF (2000), Lateral glenohumeral ligament rupture in three dogs, *Journal of Small Animal Practice*. 41: 511-514

Newton CD (1985), Normal range of motion in the dog and cat, in *Textbook of Small Animal Orthopaedics*, ed. Newton CD and Nunamaker DM, J.B. Lippincott, Philadelphia p 1101-1106

Oliveri M, Piras A, Vezzoni A, Marcellin-Little D (2000), Incomplete ossification of the caudal aspect of the glenoid in 5 dogs: Arthroscopic diagnosis and treatment., *Veterinary and Comparative Orthopaedics and Traumatology* 13: A8

Ovesen J, Nielsen S (1986), Posterior instability of the shoulder. A cadaver study, *Acta Orthopaedica Scandinavica*. 57: 436-439

Pagnani MJ, Deng XH, Warren RF, Torzilli PA, O'Brien SJ (1996), Role of the long head of the biceps brachii in glenohumeral stability: a biomechanical study in cadavera, *Journal of Shoulder & Elbow Surgery*. 5: 255-262

Piermattei DL, Flo GL (1997), The shoulder joint, in Handbook of Small Animal Orthopaedics and Fracture Repair, W.B. Saunders, Philadelphia p 228-360

Puglisi TA (1986), Canine humeral joint instability - part 1, Compendium of Continuing Education 8: 593-601

Puglisi TA, Tanger CH, Green RW, Mann FA, Mathey WS, Shively MJ (1988), Stress radiography of the canine humeral joint, Journal of the American Animal Hospital Association. 24: 235-240

Rivers B, Wallace L, Johnston GR (1992), Biceps tenosynovitis in the dog: radiographic and sonographic findings, Veterinary and Comparative Orthopaedics and Traumatology 5: 51-57

Simkin PA, Pickerell CC (1984), Interarticular differences in oncotic pressure of canine synovial fluid, Journal of Rheumatology. 11: 14-16

Sledge CB (1993), Biology of the joint, in Textbook of Rheumatology, ed. Kelly WN, Harris ED, and Ruddy S, W.B. Saunders, Philadelphia p 1-16

Slocum B, Devine T (1983), Cranial tibial thrust: a primary force in the canine stifle, Journal of the American Veterinary Medical Association. 183: 456-459

Slocum B, Devine T (1984), Cranial tibial wedge osteotomy: a technique for eliminating cranial tibial thrust in cranial cruciate ligament repair, Journal of the American Veterinary Medical Association. 184: 564-569

Slocum B, Slocum TD (1993), Tibial plateau leveling osteotomy for repair of cranial cruciate ligament rupture in the canine. [Review] [22 refs], Veterinary Clinics of North America - Small Animal Practice. 23: 777-795

Stobie D, Wallace LJ, Lipowitz AJ, King V, Lund EM (1995), Chronic bicipital tenosynovitis in dogs: 29 cases (1985-1992), Journal of the American Veterinary Medical Association. 207: 201-207

Talcott KW, Vasseur PB (2003), Luxation of the scapulohumeral joint, in Textbook of Small Animal Surgery, ed. Slatter DH, W.B. Saunders, Philadelphia p 1897-1904

Vasseur PB (1983a), Clinical results of surgical correction of shoulder luxation in dogs, Journal of the American Veterinary Medical Association. 182: 503-505

Vasseur PB (2003), Stifle joint, in Textbook of Small Animal Surgery, ed. Slatter DH, W.B. Saunders, Philadelphia p 2090-2133

Vasseur PB, Moore D, Brown SA (1982), Stability of the canine shoulder joint: an in vitro analysis, American Journal of Veterinary Research. 43: 352-355

Vasseur PB, Pool RR, Klein K (1983b), Effects of tendon transfer on the canine scapulohumeral joint, American Journal of Veterinary Research. 44: 811-815

Vernon-Roberts B (1986), Synovial fluid and its examination, in Copeman's textbook of the rheumatic diseases, ed. Scott JT, Churchill Livingstone, Edinburgh p 251-259

Wall CR, Taylor R (2002), Arthroscopic biceps brachii tenotomy as a treatment for canine bicipital tenosynovitis, Journal of the American Animal Hospital Association. 38: 169-175