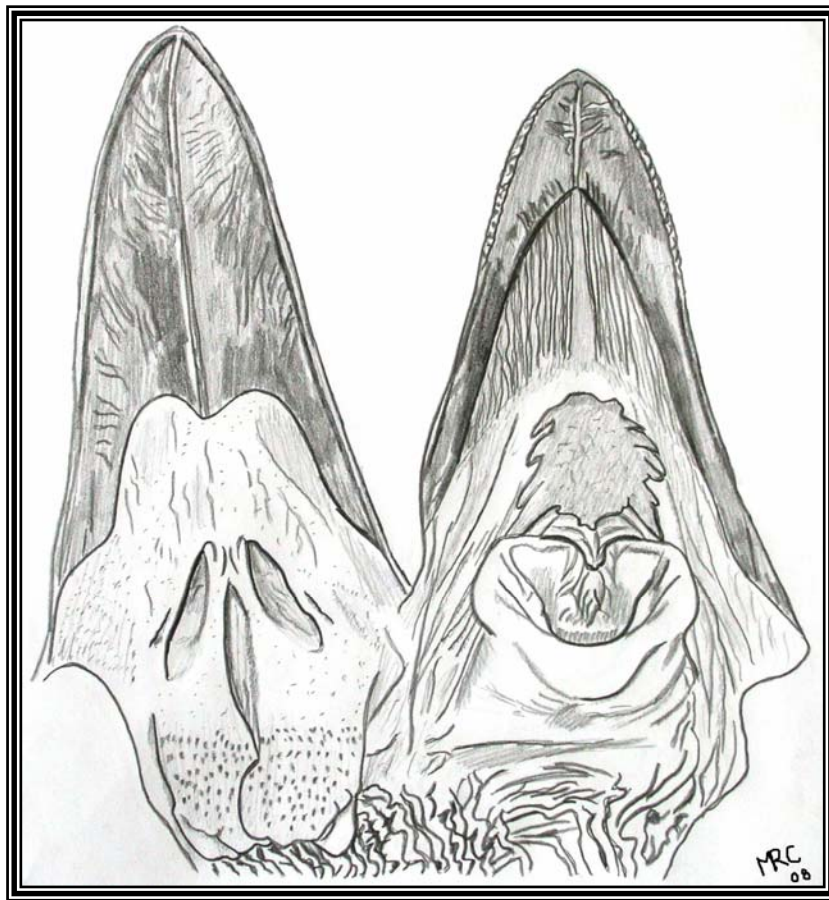




A Gross Anatomical and Histological Study of the Oropharynx and Proximal Oesophagus of the Emu (*Dromaius novaehollandiae*)

by

MARTINA RACHEL CROLE



Submitted in partial fulfilment of the requirements for the degree MSc

**DEPARTMENT OF ANATOMY AND PHYSIOLOGY
FACULTY OF VETERINARY SCIENCE
UNIVERSITY OF PRETORIA
PRETORIA**

2009



Supervisor:

Professor Doctor John Thomson Soley
Department of Anatomy and Physiology
Faculty of Veterinary Science
University of Pretoria
Pretoria

DECLARATION

I declare that the dissertation which I hereby submit for the degree MSc (Veterinary Sciences) at the University of Pretoria is my own work and has not been submitted by me for a degree at another university.



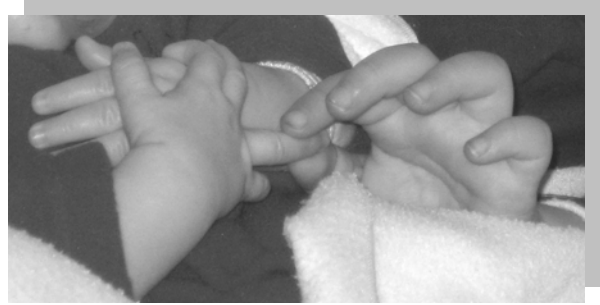

Dedication

To Damién and Jayden van den Berg:
The most endearing brothers I have ever known.

Dear Baby Jay

...It was but a breath of time,
And your smiling, precious soul was amongst us.
...It was but another, brief,
Breath of time,
...and you had left us. Departed.....
Yet, for all the time,
...For every breath that will still fill our lungs,
All who cared so deeply for you,
...Will never forget you, never stop loving you.
And our hearts will be joyously filled;
...Overflowed,
With the memory of you, Jayden,
...Of every second you were with us.
You live on, here, in us, who love you,
.....Forever.



To my dearest little friend



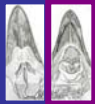



Damién

You have stolen my heart,
Right from the start;
From your intelligence and questions,
To your incontrovertible perceptions.
Your lucid imagination, leaves no room,
for our adult stagnation.
The freedom with which you love
And the freedom, with which
you live, is exceptionally
enlightening and truly inspiring.





CONTENTS

ACKNOWLEDGEMENTS	ii
SUMMARY	iii
 <u>CHAPTER 1:</u> GENERAL INTRODUCTION	1
 <u>CHAPTER 2:</u> GROSS MORPHOLOGY OF THE OROPHARYNGEAL CAVITY AND PROXIMAL OESOPHAGUS	10
 <u>CHAPTER 3:</u> HISTOLOGICAL FEATURES AND SURFACE MORPHOLOGY OF THE OROPHARYNGEAL CAVITY AND PROXIMAL OESOPHAGUS	46
 <u>CHAPTER 4:</u> GROSS MORPHOLOGY OF THE TONGUE	111
 <u>CHAPTER 5:</u> HISTOLOGICAL FEATURES AND SURFACE MORPHOLOGY OF THE TONGUE	134
 <u>CHAPTER 6:</u> GENERAL CONCLUSIONS	171





ACKNOWLEDGEMENTS

My promoter, Prof. John Soley, who guided and taught me so patiently, thoroughly and with all his heart. Thank you for your dedication, you have given me a solid foundation.

The Head of the Department of Anatomy and Physiology, Faculty of Veterinary Science, Prof. Herman Groenewald. Thank you for the trust and belief you show in me and my work. I value your inputs and the freedom with which you allow me to work.

Mr. Peter Duncan for providing the emu heads and for his willingness to secure samples for future work. Joan and Adrian Perry for providing an emu head for SEM. Dr. Catarina Tivane for the initial specimen collection.

Erna Van Wilpe and Lizette du Plessis of the Electron Microscopy Unit, Department of Anatomy and Physiology, for their kind assistance in sample processing, viewing and use of printing facilities. My colleagues and support staff from the Department of Anatomy and Physiology including Martè Smit for technical assistance and preparation of articles and Leon De Villiers and Adam Flink for specimen storage and handling.

Alan Hall, Andre Botha and Chris van der Merwe from the Laboratory for Microscopy and Microanalysis, University of Pretoria, for kindly allowing me use of the SEM's.

Joey Breedt from the Section of Pathology, Faculty of Veterinary Science, for the preparation of histological sections; Charmaine Vermeulen for photography of the gross anatomy specimens; Dr. Kerstin Junker from the Department of Veterinary Tropical Diseases for her assistance in photographing histology slides. Drs. Fritz and Hildegard Huchzermeyer for article translations.

Carole Long, Secretary of the Otanewainuku Kiwi Trust, Avi Holzapfel (leader of the Kiwi Recovery Group) and Susan Cunningham from New Zealand for their assistance in acquiring literature on the kiwi; Peter Johnston from the Liver Transplant Unit and Department of Anatomy, University of Auckland, New Zealand for his information on the cassowary and assistance in the acquisition of literature.

The University of Pretoria for financial support of this project.





SUMMARY

A Gross Anatomical and Histological Study of the Oropharynx and Proximal Oesophagus of the Emu (*Dromaius novaehollandiae*)

by

MARTINA RACHEL CROLE

SUPERVISOR: Professor John T. Soley

DEPARTMENT: Department of Anatomy and Physiology, Faculty of Veterinary Science, University of Pretoria, Private Bag X04, Onderstepoort, 0110, Republic of South Africa.

DEGREE: MSc (Veterinary Sciences)

This study describes the gross anatomical, histological and surface morphological features of the oropharynx and proximal oesophagus of the emu in order to address the scarcity of information on this region in this commercially important bird. Heads obtained from birds at slaughter (and a younger and older bird from emergency farm slaughter) were used for this study and described using basic gross anatomical and histological techniques, supplemented by scanning electron microscopy. The findings of the study were compared with the relevant literature.

The oral and pharyngeal cavities could not be morphologically separated and formed a single cavity. This cavity was dorso-ventrally flattened and clearly divided, both on the floor and the roof, into rostral pigmented and caudal non-pigmented parts. The non-pigmented floor housed the tongue and laryngeal mound which had a wide glottis and no papillae. The choana was triangular-shaped, with a small caudo-lateral fold on either side, and was situated in the non-pigmented part of the roof. Caudal to the choana were two rounded pharyngeal folds with a



pitted ventral surface. A small bilateral projection from the caudo-lateral edge consisted mainly of diffuse lymphoid tissue. The pharyngeal folds contained numerous large simple branched tubular mucus-secreting glands as well as large accumulations of lymphoid tissue.

The pigmented regions of the roof and floor were aglandular and lined by a keratinised stratified squamous epithelium which, particularly in the roof, contained numerous Herbst corpuscles in the underlying connective tissue. SEM revealed the surface to be composed of sheets of desquamating flattened polygonal cells. The non-pigmented regions were glandular and lined by a non-keratinised stratified squamous epithelium. Surface cells displayed a pattern of microplicae or microvilli while individual surface cells were seen to desquamate. The connective tissue housed small, simple tubular and large, simple branched tubular mucus-secreting glands, Herbst corpuscles (only absent from the pharyngeal folds and proximal oesophagus), lymphoid tissue, blood vessels and nerves. The glands of the upper digestive tract were polystomatic and named as follows according to their location: Caudal intermandibular, lingual, crico-arytenoid, oral angular, caudal palatine, pharyngeal and oesophageal. The openings of the glands to the surface were seen on SEM as variably sized holes on the surface, some being obscured by mucus secretions from the underlying glands. Taste receptors were sparse and present only in the caudal non-pigmented oropharyngeal floor, tongue root and proximal oesophagus. Accumulations of lymphoid tissue were identified at the junction between the two regions of the roof, and in the non-pigmented roof, the non-pigmented floor, tongue ventrum, root and frenulum, proximal oesophagus and pharyngeal folds. The consistent dense accumulation of lymphoid tissue in the pharyngeal folds constituted pharyngeal tonsils (*Lymphonoduli pharyngeales*). The lymphoid tissue of the non-pigmented floor was visible macroscopically as round raised nodules. Specific, unnamed larger lymphoid tissue aggregations were located at the junction of the tongue ventrum and frenulum and in the small folds lateral to the choana. Surface morphology, as seen by SEM, revealed a pattern of microridges on the surface cells of the keratinised areas, whereas the surface cells of the non-keratinised areas displayed microplicae, microvilli and cilia. Microvilli and cilia were associated with the gland openings and ducts.

The proximal oesophagus was a cylindrical tube with a longitudinally folded mucosa and displayed the typical tissue layers described in birds. The mucosa was formed by a non-keratinised stratified epithelium which on SEM showed minimal surface desquamation. The *lamina propria* contained numerous simple tubular mucus-secreting glands which sometimes branched and occasional diffuse lymphoid tissue aggregations. The gland openings to the surface





were seen on SEM as small and large dark holes. The *muscularis mucosae* was very prominent and was a longitudinal smooth muscle layer separating the mucosa from the submucosa. The *tunica muscularis* was composed of a thicker inner circular and a thinner outer longitudinal smooth muscle layer surrounded by the outer loose connective tissue forming the *tunica adventitia*.

The emu tongue was divided into a body and a root. The body was triangular, dorso-ventrally flattened, pigmented and displayed caudally directed lingual papillae on both the lateral and caudal margins. The root, a more conspicuous structure in comparison to other ratites, was triangular, with a raised bulbous component folding over the rostral part of the laryngeal fissure. The lingual skeleton was formed by the triangular-shaped *paraglossum* (hyaline cartilage), forming the core of the tongue body, and the rostral projection of the *basihyale*, ventral to the *paraglossum*. Following the general trend in ratites, the emu tongue was greatly reduced in comparison to the bill length and specifically adapted for swallowing during the cranioinertial method of feeding employed by palaeognaths.

The tongue was invested by a non-keratinised stratified squamous epithelium. The glands in the connective tissue formed the bulk of the parenchyma and were composed of both small simple tubular and large simple branched tubular mucus-secreting glands similar to those seen in the oropharynx. The lingual glands were grouped as follows: dorsal and rostro-ventral (large glands), caudo-ventral and radical (large and small glands) and frenular (small glands). The large glands were visible macroscopically as doughnut-shaped structures. Melanocytes were absent from the tongue ventrum and occasionally from the tongue root. Lymphoid tissue was absent from the tongue dorsum. Herbst corpuscles were present in the tongue body and root and generally closely associated with the large mucus-secreting glands. The surface morphology varied in the different regions of the tongue. The dorsal and rostro-ventral tongue body showed individual desquamating cells and large gland openings only, the caudo-lateral ventrum showed less desquamation and both large and small openings. The mid-ventral aspect had an undulating uneven appearance with round raised cells on the surface which were densely packed with microvilli. Very large, large and small openings were present in this region and ciliated cells occurred in the vicinity of gland openings.

This study presented various unique findings regarding the morphology of the emu oropharynx compared to other ratites. Although the sense of taste has been confirmed in many avian species,





this study presented the first evidence of taste in the emu and ratites in general and suggests the possibility of taste being previously overlooked in the other birds studied (ostrich and greater rhea). The tongue root of the emu was clearly defined and is unique in structure and possible function amongst the ratites and other birds. Previously unmentioned functions of the emu tongue revealed by this study include: touch (Herbst corpuscles), taste (taste bud), lubrication and mechanical protection (mucus-secreting glands), immunological (lymphoid tissue) and digestive (swallowing). It was also noted that the various structures and organs of the oropharynx revealed important and often interesting differences between the emu and the other ratites documented. The prominent serrations of the rostral mandibular tomia of the emu also appear to be unique amongst ratites. The presence and wide distribution of Herbst corpuscles within the emu oropharynx and tongue show these areas to be highly sensitive to touch. The caudo-lateral projections of the pharyngeal folds effectively formed pharyngeal tonsils, a feature not apparent in other ratites. Despite the differences noted between the emu and other ratites it was possible to discern a common pattern of structures and features, with their modifications, both within and forming the oropharynx in this group of birds.

