



## Suspected sheep-associated malignant catarrhal fever in a zero-grazed dairy herd in Kenya

C.M. MULEI<sup>1</sup>, P.K. GATHUMBI<sup>2\*</sup> and P.G. MBUTHIA<sup>2</sup>

### ABSTRACT

MULEI, C.M., GATHUMBI, P.K. & MBUTHIA, P.G. 2000. Sheep-associated malignant catarrhal fever in a zero-grazed dairy herd in Kenya. *Onderstepoort Journal of Veterinary Research*, 67:43–47

An outbreak of a disease characterised by very high mortality occurred in a group of nine calves (1B4 months old) in a zero-grazing unit 2–3 weeks after an introduction of an apparently healthy alien sheep into the calf pen. Five of the six calves which contracted the disease died. The main clinical signs observed were marked depression, persistently high body temperature (40.5–41.5 °C), copious mucopurulent nasal and ocular discharges, dyspnoea, bilateral keratoconjunctivitis with corneal opacity, enlargement of the superficial lymph nodes and marked erythema and/or superficial erosions of the buccal mucosae. At necropsy there were lesions in the upper respiratory and digestive tracts, lymph nodes, brain, eyes, liver, kidneys and the urinary bladder. The lesions were histopathologically characterized by fibrinoid vasculitis which was accompanied by lymphocytic infiltration in the parenchyma of the affected tissues. Based on the evidence of contact between the calves and the recently introduced foreign sheep, the characteristic clinical signs and histopathological findings, a diagnosis of sheep-associated malignant catarrhal fever was made.

**Keywords:** Dairy herd, Kenya, sheep-associated malignant catarrhal fever, zero grazed

### INTRODUCTION

Malignant catarrhal fever (MCF) is a fatal lymphoproliferative and degenerative disease of cattle and some wild ruminants (Plowright 1981). It is characterized by fever, depression, profuse nasal and ocular discharges, corneal opacity, generalized lymphadenopathy and occasionally by central nervous system involvement (Plowright, Ferris & Scott 1960; Selman, Wiseman, Murray & Wright 1974; Selman, Wiseman, Wright & Murphy 1978). The disease occurs in two forms, one being due to Alcelaphine herpesvirus-(AHV-1) which is associated with inapparently infected blue (*Connochaetes taurinus*) or

black (*C. gnu*) wildebeest, and the other form thought to be due to an antigenically related virus but associated with inapparently infected sheep (Reid, Pow & Buxton 1989; Schuller, Cerny Leilerer & Silber 1991). The wildebeest-associated form of MCF has been the only one reported in East Africa (Plowright 1965). Although the sheep-associated form of MCF (SA-MCF) is occasionally reported in countries outside Africa, in Africa, it has only been reported in South Africa (Barnard, Van der Lugt & Mushi 1994; Michel & Aspeling 1994). The transmission of the SA-MCF is assumed to be through contact between infected sheep and cattle, although incidents of the disease have been reported where sheep have been separated from affected animals by several hundred metres (Hoffman, Soeripto, Sobironingsir, Campbell & Clarke 1984; Reid *et al.* 1989).

In Kenya, the commonest encountered form of malignant catarrhal fever is the wildebeest-associated form, which is mainly encountered in certain parts of the country such as Narok district where livestock and wildlife often interact.

\* Author to whom correspondence is to be directed

<sup>1</sup> University of Nairobi, Clinical Studies Departments, Faculty of Veterinary Medicine, P.O. Box 29053, Nairobi, Kenya

<sup>2</sup> University of Nairobi, Department of Veterinary Pathology and Microbiology, Faculty of Veterinary Medicine, P.O. Box 29053 Nairobi, Kenya

The present report describes an outbreak of MCF in a zero-grazed dairy herd in Kenya after introduction of a recently acquired apparently healthy adult female red Masai sheep into a pen containing nine calves.

### Case history

Six out of the nine (67%) Friesian calves aged between one and four months fell sick within 2–3 weeks after the introduction of the sheep, acquired from Narok district, into their pen. One of the calves, aged four months, recovered from the clinical disease while the other five (83,3%) died within a period of 5–10 d after the onset of the disease.

The main clinical signs observed were a severe depression, persistently high body temperature (40,5–41,5°C), mucopurulent nasal and ocular discharges, dyspnoea, bilateral corneal opacity, marked enlargement of the superficial lymph nodes and marked erythema of the buccal mucus membrane which was later followed by superficial erosions and salivation. Haematological examination and evaluation of blood and lymph node smears did not reveal any abnormalities or haemoparasites.

Initial treatment with Parvaquone (Clexon®, Coopers, Kenya) and antihistamine (Vetibenzamine®, Ciba Geigy, Kenya) for tentative diagnosis of East Coast fever (ECF) was abandoned when it failed to bring any positive response. At this time the association of the disease with the recently introduced foreign sheep was suspected. This led to immediate slaughter of the sheep even before samples for serology or virology could be taken. Thus a tentative diagnosis of MCF was made based on the clinical signs, results of haematology (negative for ECF) and the epidemiological association of the disease with the recently introduced sheep. Subsequent treatment was aimed at controlling secondary bacterial infection and involved daily intramuscular administration of a preparation containing procaine penicillin, dihydrostreptomycin sulphate (Penstrep®, Norbrook) at the recommended dosage rate during the active stage of the disease.

### Necropsy and Histopathology

Animals that died were subjected to post mortem examination. At necropsy, representative specimen of tissues from body systems were preserved in neutral buffered formalin solution for subsequent histopathological examination and were processed using standard procedures. Tissue sections 4–6 µm in thickness were stained with haematoxylin and eosin.

### Gross lesions

The carcasses were in poor condition and all showed the presence of a mucopurulent nasal discharge. The

main lesions observed were intense congestion of nasal mucosae, fibrinous laryngitis with intense mucosal congestion, and tracheitis and bronchitis that were manifested by diffuse mucosal congestion. The lumen of the trachea and bronchi contained bloody froth. There were mild congestion in the lungs and numerous scattered petechiae and ecchymotic haemorrhages occurred throughout all lobes of both lungs. Mediastinal lymph nodes showed mild congestion and multifocal ecchymotic and petechiae haemorrhages on the cut surface. Myocardium appeared pale and in two calves, this change was accompanied by a diffuse serofibrinous pericarditis with adhesion of the pericardium to the epicardium. The distal part of the oesophagus had numerous, irregular, occasionally linear erosions which were either discrete or coalescent. In all carcasses, there was bilateral mucopurulent keratoconjunctivitis with corneal opacity. Brain oedema which was grossly characterized by the occurrence of cloudy to milky meninges was present in all cases. All lymph nodes were enlarged in every case.

### Histopathology

Lesions were present in several organ systems. In the brain, perivascular aggregations of lymphocytes accompanied by fibrinoid vasculitis (Fig. 1) were observed in the cerebellum, cerebrum and the choroid plexus. Some neurons located within, or adjacent to, the lesions were shrunken, with a condensed eosinophilic cytoplasm, while others had no definable cytoplasmic or nuclear membranes. Many of the neurons located distant from the perivascular lesions showed mild chromatolysis and margination of the nuclei. Astrogliosis occurred in many areas of the central nervous system. Although the ependymal lining was intact in many areas, the periventricular and subependymal regions contained a moderate number of diffusely distributed gitter cells.

There was brain oedema that was characterized by occurrence of spongiosis of the white matter and the presence of numerous gemastocytic astrocytes.

The eyes showed bilateral lymphocytic keratoconjunctivitis which was severe at the marginal borders from the corneal-sclera junction. The corneal epithelium was thick due to epidermalization. There was fibrosis and vascularization of the corneal stroma which also contained lymphocytic cells. Vasculitis was a prominent lesion in the corneal, other lesions observed in the eye were mononuclear choroiditis and uveitis. There was a mild vasculitis and perivascular lymphocytic infiltration in the sheath of the optic nerve.

In the lungs, fibrinoid vasculitis with perivascular lymphocytic aggregations was also a main observation. The peribronchiolar areas including the lamina propria were colonized by lymphocytes. In the kidneys



FIG. 1 Vasculitis is accompanied by perivascular lymphocytic infiltration in the brain of cow with sheep-associated malignant catarrhal fever  
Haematoxylin and eosin, x 40

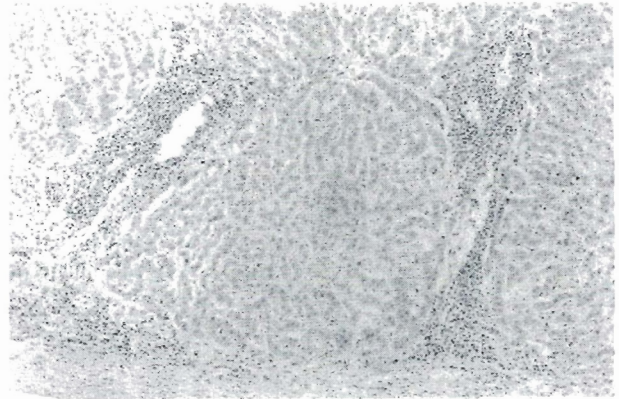


FIG. 3 Lymphocytic infiltration occurs at the portal and perivascular spaces and into the liver capsule  
Haematoxylin and eosin, x 40

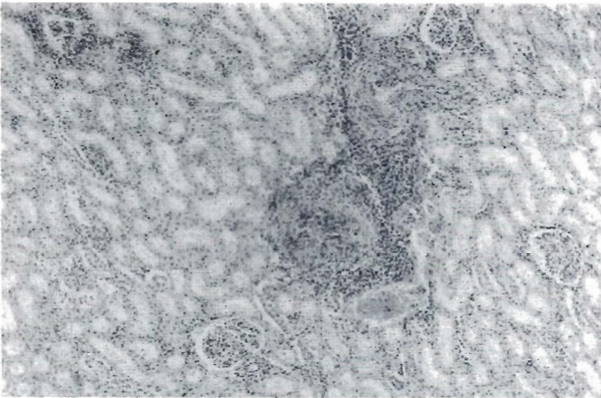


FIG. 2 Kidney shows Lymphocytic infiltration in the perivascular and interstitial spaces  
Haematoxylin and eosin, x 40




FIG. 4 Multifocal to diffuse lymphocytic infiltration into the myocardium is accompanied by focal necrosis and atrophy of the myocardium  
Haematoxylin and eosin, x 40

there were multifocal areas of periglomerular, perivascular and or interstitial lymphocytic infiltration accompanied by vasculitis, and atrophy or degeneration of renal tubular epithelial cells. The interstitial reaction was more pronounced in the areas lying adjacent to the vascular lesions (Fig. 2) The glomerular connective tissue was hypercellular and hyalinized with an increase in mesangial cell population.

There were prominent, multifocal to diffuse lymphocytic infiltrations into the liver. The liver capsule and parenchyma were infiltrated by varying lymphocytic population which tended to be more conspicuous at the portal and perivascular areas (Fig. 3). Subsequently, the hepatic cords were atrophied in many areas. Fibrinoid vasculitis was also a notable lesion in the liver.

The heart showed diffuse or focal areas of lymphocytic infiltration into the myocardium. This was

accompanied by vasculitis and foci of atrophy or necrosis of myofibers (Fig. 4). There was marked lymphoid hyperplasia in the lymphnodes. The cortico-medullary demarcation was not discernible due to the presence of a uniformly dense population of cells in both regions. Germinal centres were prominent and showed cores of fading cell populations that simulated the lymphoid changes associated with exhaustion. Sinus catarrh was prominent in the subcapsular, peritrabecular and medullary sinuses. Lymph node capsules were thickened due to fibrinoid vasculitis and lymphocytic infiltration.

Focal necrosis and erosions or ulcers of varying severity occurred in the oesophagus. These were accompanied by a mononuclear inflammatory process and congestion in the continuous lamina propria and submucosa. Vasculitis of the arterioles was noted as a prominent lesion in the submucosa and in the muscular layer of the oesophagus.

## DISCUSSION

The diagnosis of MCF was based on the epidemiology, i.e. the recent introduction of a sheep into the calf pen, and the typical clinical signs and pathological findings. Histopathological changes, especially the fibrinoid vasculitis which was accompanied by lymphocytic infiltration in the affected tissues are pertinent to the disease. In outbreaks of MCF in Africa, there is either evidence of close contact between cattle and wildebeest or (rarely) sheep (Barnard *et al.* 1994). The nervous lesions of lymphocytic perivascular cuffing and some degree of degeneration of neurons as was observed in these cases are considered to be pathognomonic for MCF (Selman *et al.* 1974; Wandera 1979; Radostits, Blood & Gray 1994). When viral DNA hybridization assay and polymerase chain reaction (PCR) (Blaxter, Pow, Bridgen & Reid 1993; Michel & Aspelung 1994) are not available for confirmation of a diagnosis, this is based on the histopathological findings (Selman *et al.* 1974; Wandera 1979; Radostits *et al.* 1994).

The epidemiological association between the introduction of the sheep from the Narok district, an area known to be endemic for wildebeest-associated MCF, into the calf pen on a farm, that is located in a periurban area where wildebeest do not occur, and the subsequent occurrence of the disease strongly suggests that the sheep was the possible source of the infection. It is possible that both forms of MCF coexist in endemic area such as Narok district, where both reservoir hosts occur together. In the past, wildebeest-associated MCF may have been overdiagnosed in such areas since only PCR based methods can be used to differentiate between the two forms of the disease.

Future research on MCF in Kenya should therefore focus on investigations of the possible coexistence of the two forms of the disease in endemic areas where the reservoir hosts occur together. This is relevant because introduction of sheep inapparently infected with SA-MCF virus into areas where MCF does not normally occur can lead to an outbreak of the disease. If, in such areas, routine laboratory diagnostic procedures or post mortem and histopathological examinations are not done, then such cases could easily be confused with East Coast Fever.

The recovery of one of the sick calves which had manifested typical signs of MCF infection indicates that recovery is possible in some cases of MCF. The mortality rate of MCF is generally considered to be 100% while apparently recovered cases have been thought to represent a diagnostic error (Plowright 1987; Selman 1987). However, cases of persistent MCF confirmed by PCR have been reported (Milne & Reid 1990, Michel & Aspelung 1994). Since the DNA hybridization assay and PCR techniques are more definitive diagnostic techniques, then it can be

said that recovery from clinical MCF may be possible in some cases.

The occurrence of these cases of MCF was unusual since the disease occurred in animals which were closely confined to a farm on which the only way the disease could have been introduced was by way of sheep. Sheep-associated malignant catarrhal fever has not previously been reported in animals in Kenya and its occurrence in the dairy herd is of epidemiological significance in this country where only the wildebeest-associated MCF has been diagnosed to date.

## ACKNOWLEDGEMENT

The authors wish to thank the staff of Histopathology laboratory in the Department of Veterinary Pathology and Microbiology for technical support.

## REFERENCES

- BARNARD, B.J.H., VAN DER LUGT, J.J. & MUSHI, E.Z. 1994. Malignant catarrhal fever, in *Infectious diseases of livestock with special reference to Southern Africa*, 1, edited by J.A.W. Coetzer, G.R. Thomson & R.C. Tustin, Cape Town: Oxford University Press Southern Africa.
- BLAXTER, S.I.F., POW, I., BRIDGEN, A. & REID, H.W. 1993. PCR detection of sheep associated agent of malignant catarrhal fever. *Archives of Virology*, 132:145–159.
- HOFFMAN, D., SOERIPTO, S., SOBIRONINGSIR, S., CAMPBELL, R.S.F. & CLARKE, B.C. 1984. The clinico-pathology of Malignant catarrhal fever syndrome in the Indonesian Swamp buffalo (*Bubalus Bubalis*). *Australian Veterinary Journal*, 61: 108–112.
- MICHEL, A.L. & ASPELING, I.A. 1994. Evidence of persistent malignant catarrhal fever infection in a cow obtained by nuclear acid hybridization. *Journal of South African Veterinary Association*, 65:26–27.
- MILNE, E.M. & REID, H.W. 1990. Recovery of a cow from malignant catarrhal fever. *Veterinary Records*, 126:640–641.
- PLOWRIGHT, W. 1965. Malignant catarrhal fever. Behaviour of the virus in free living population of Blue wildebeest. *Research in Veterinary Science*, 6:56–58.
- PLOWRIGHT, W., FERRIS, R.D. & SCOTT, G.R. 1960. Blue Wildebeest and aetiological agent of malignant catarrhal fever. *Nature*, 188:1167–1169.
- PLOWRIGHT, W. 1981. Herpesvirus of wild ungulates, including malignant catarrhal fever, in *Infectious diseases of wild mammals*, 1, edited by J.W. Davis, L.H. Karstad & D.O. Traaner, Ames: Iowa state University Press.
- PLOWRIGHT, W. 1986. Malignant Catarrhal fever. *Revue Scientifique et Technique. Office International des Epizooties*, 5:897–918.
- RADOSTITS, O.M., BLOOD, D.C. & GAY, C.C. 1994. *Veterinary Medicine, a textbook of the diseases of cattle, sheep, pigs, goats and horses* (8th ed). London: Bailliere Tindall.
- REID, H.W., POW, I. & BUXTON, D. 1989. Antibody to alcelaphine herpesvirus-1 (AHV-1) in hamster experimentally infected with AHV-1 and sheep-associated agent of malignant catarrhal fever, *Research in Veterinary Science*, 47:383–386.

- SCHULLER, W., CERNY LEILERER, S. & SILBER, R. 1991. Evidence of malignant catarrhal fever is caused by a herpesvirus, *Journal of Veterinary Medicine B*, 37:442–447.
- SELMAN, I.E., WISEMAN, A., MURRAY, M. & WRIGHT, N.G. 1974. A clinico-pathological study of bovine malignant catarrhal fever in Great Britain, *Veterinary Records*, 94:483–490.
- SLMAN, I.E., WISEMAN, A., WRIGHT, N.G. & MURPHY, M. 1978. Transmission studies with bovine malignant catarrhal fever, *Veterinary Records*, 103:102–257.
- WANDERA, J.G. 1979. Malignant catarrhal fever, in *Diseases of cattle in tropical Africa*, 1, edited by G.M. Mugera, Nairobi: Kenya Literature Bureau.