

# Secondary Missile Injury from Lightning Strike

## Ryan Blumenthal

### **Abstract:**

A 48 year-old-female was struck dead by lightning on the 24<sup>th</sup> October 2010 in Pretoria South Africa. The cause of death was due to direct lightning strike. Examination showed secondary missile injury on her legs. This secondary missile (shrapnel) injury was caused by the lightning striking the concrete pavement next to her. Small pieces of concrete were located embedded within the shrapnel wounds. This case report represents the first documented case of secondary missile formation (shrapnel injury) due to lightning strike in the literature.

**Key words:** Lightning; secondary missile formation; shrapnel; keraunopathology; keraunomedicine.

### **Background history:**

A forty-eight year old female, her thirty-four year old son and her ten-year-old daughter were walking on a relatively urbanized road, outside Pretoria in the suburb of Eersterus, on the 24 October 2010. They were walking on the pavement under a Jacarana tree (*Jacaranda mimosifolia*).

There was an electrical thunderstorm and they were caught in heavy rain. All three of the individuals were described as being 'very wet' at the time. At 17:45 a lightning strike hit the Jacaranda tree and killed the forty-eight year old female. Her son was knocked from his feet. Her daughter was also knocked down by the strike. Both the son and the daughter survived the lightning strike. The son sustained a 2,0cm x 1,0cm abrasion on his left knee cap. The daughter was affected psychologically and stayed home from school for one week. No further injuries could be demonstrated on the son and daughter.

This case study will focus on the forty-eight year old female, who died due to the lightning strike. It will focus on an interesting injury phenomenon which she sustained and which thus far has never been described in the literature.

### **Scene investigation:**

Scene examination showed the Jacaranda tree to have been struck by lightning. There were two areas within the branches where the bark had been stripped off by the lightning. Small wood chips from the Jacaranda tree could be identified up to a maximum distance of 5 meters away from the tree.

There were two craters on the concrete on the pavement on the right side of the body of the victim. These two craters measured 11,0cm x 9,0cm x 4,0cm in size and 4,0cm x 4,0cm x 1,0cm in size, respectively. It was confirmed from witness reports that these two craters, which were spaced 7,0cm apart, were not present on the pavement prior to the electrical thunderstorm.

### **Post mortem examination:**

Post mortem examination showed an adult female with torn-and-tattered clothing overlying the abdominal- and right inguinal regions. The clothing showed blackened

charring of the tattered edges. Superficial charring of the skin was noted overlying the midline of the sternum, the anterior aspect of the abdomen and the right inguinal region. Features were in keeping with the available history of direct lightning strike.

An unusual injury phenomenon was discovered on the victim's lower limbs. Signs of secondary missile injury (shrapnel injury) were detected on the right side of the lower legs – it almost looked as if there was an explosion on the right side of the body.

Examination of the shrapnel wounds showed multiple small pieces of concrete embedded relatively superficially within the epidermis and dermis.

Features were in keeping with secondary missile injury (shrapnel injury) from lightning strike. This is the first time such a finding is reported in the literature.

A discussion on lightning barotrauma and secondary missile injury (shrapnel injury) follows.

### **Discussion:**

Shrapnel, in the strict sense, is shot deliberately included in a landmine or shell intended to be scattered by the explosion. More loosely, the term is used to refer to any fragments or debris propelled by an explosion. The word is derived from the name Henry Shrapnel, an English artillery officer, who in 1784 began developing, on his own time and his own expense, an antipersonnel weapon composed of a hollow spherical projectile filled with shot and explosive charge. It was designed to detonate in midair scattering the shot and shell fragments. Shrapnels were invented in 1808 by aforementioned English colonel (1,2). In the context of this case study, the term shrapnel and/or secondary missile injury is used to describe the specific wound phenomenon observed on the victim.

Lightning is a multi-physics phenomenon requiring a multidisciplinary approach. Lightning injury models suggest that lightning injury is chiefly *electrical* and/or *thermal* in nature. While electrothermal phenomena explain the vast majority of injuries observed in lightning strike victims, including cardiac (3), electrothermal (4), and at least some of the neurological injuries observed, a review of the lightning literature shows an interesting injury phenomenon which is difficult to explain with the electrical and/or thermal injury models and which has become the topic of controversy. This phenomenon includes torn and tattered clothing (5), fractures (6), rupture of shoes, traumatic perforation of tympanic membranes (15-23), lung contusion and haemorrhage and even pneumomediastinum (7,8).

These findings are similar to injuries seen in individuals who have been exposed to a bomb explosion and suggest explosive *barotrauma* as a mechanism of injury. To be injured by a blast, one has to be in the immediate vicinity of the explosion, about a meter or so. About 100 lb/inch<sup>2</sup> (690kPa) is the minimum threshold for serious damage to humans (10). Blast lung, bowel contusion and tympanic membrane rupture, all of which may be found in some cases of lightning injury, are typically found in cases of direct transmission of a detonation shockwave (12).

It is customary to use Marshall's Triad when considering the pathology of trauma of bomb explosions. This triad includes punctate-bruises, abrasions and small punctate lacerations all of which are typically found in an explosive bomb blast (11). Although many similarities exist between injury patterns seen in lightning and concussive injuries, Marshall's Triad findings are not typically found in lightning strike injuries.

As to why the son and daughter received no shrapnel injuries, it is possible to opine that they were beyond the shrapnel injury range and/or that they were protected by their clothing. Examination showed no secondary missile injury on the son or daughter.

With regards to the two craters on the concrete on the pavement on the right side of the body of the victim, there are multiple well documented reports of trees being split asunder, blast holes in the ground and flying masonry, which would support the theory of lightning explosive barotrauma (5). *The Physics of Lightning* by D.J. Malan (12) under the heading *Explosive Effect* notes:

‘Should the heavy current of a lightning flash pass through a confined space, the heated air is not free to expand and will exert a pressure on the walls of the cavity. The larger the cavity, the smaller the excess pressure, since only part of the air in a large cavity will be heated. When a lightning flash is incident on rocky soil the electric current tends to follow the interstices between the rocks or cracks, which are filled with moist soil. Rocks may be split asunder or thrown aside with explosive violence’.

Review of the otorhinological medical literature sometimes describes the tympanic membrane following lightning strike as ‘a large tympanic membrane perforation with ossicular chain disruption’ (7-15). Proposed mechanisms of injury have included concussive “blast” effect on the ear, “direct” effect of electrical conduction, “splash” effect, “cylindrical shock wave of electrons” and/or direct “thermal burn”.

Aforementioned review of the biological, medical and engineering literature seems to support barotrauma as an injury mechanism with regards to lightning strike.

### **Conclusion:**

Keraunopathology is the study of the pathology of trauma of lightning on the human and/or animal body. Careful attention to detail in lightning strike cases can further advance the field of keraunomedicine.

This case report demonstrates the phenomenon of secondary missile formation (shrapnel injury) with regard to a lightning strike incident and represents one of the first of its kind reported in the literature.

### **Acknowledgements**

The author would like to thank the family of the deceased, the Director of Public Prosecutions North Gauteng Pretoria, the South African Police Service Eersterus, the community members of Eersterus and all those who helped and assisted in the preparation and publication of this paper.

### **References:**

1. Sellier KG, Kneubuehl BP. Wound Ballistics and the Scientific Background. Elsevier. 1994.
2. Di Maio VJM. Gunshot wounds. Practical Aspects of Firearms, Ballistics, and Forensic Techniques. Second Edition. CRC Press.1999.

3. Zack F, Hammer U. Myocardial Injury due to Lightning. *Int J Legal Med* 1997; 110: 326–328.
4. Wetli CV. Keraunaopathology – An Analysis of 45 Fatalities. *The American Journal of Forensic Medicine and Pathology*. 1996; 17 (2): 89 – 98.
5. Anderson RB, Carte AE. Struck by Lightning. *Archimedes*. August 1989: 25 – 29.
6. Kannan RY, Chester DL, et al. Combined Bennet’s Fracture Subluxation and Scapho-Trapezio-Trapezoidal Dislocation Secondary to Lightning Strike. *The Journal of Trauma* 2004; 57: 1351 – 1353.
7. Soltermann B, Frutiger A. Lightning Injury with Lung Bleeding in a Tracheotomized Patient. *Chest*. 1991: 240 –242.
8. Halldorsson A, Couch MH. Pneumomediastinum Caused by a Lightning Strike. *J Trauma*; 2004; 57:196 – 197.
9. Kannan RY, Chester DL, et al. Combined Bennet’s Fracture Subluxation and Scapho-Trapezio-Trapezoidal Dislocation Secondary to Lightning Strike. *The Journal of Trauma* 2004; 57: 1351 – 1353.
10. Knight B. *Forensic Pathology*. Third Edition. Arnold Publishers. 2004: 274-277.
11. Mason JK and Purdue BN. *The Pathology of Trauma*. Third Edition. 2000. Arnold Publishers. Chapter 7.
12. Malan DJ. *Physics of Lightning*. The English Universities Press. 1963.
13. Rakov VA and Uman MA. *Lightning. Physics and Effects*. Cambridge University Press. 2003. 378.
14. Soltermann B, Frutiger A. Lightning Injury with Lung Bleeding in a Tracheotomized Patient. *Chest*. 1991: 240 –242.
15. *Traumatic Injuries of the Middle Ear*. *Otolaryngeal Clinics of North America*. Volume 16, Number 3, August 1983. 633 – 650.
16. Redleaf MI, McCabe BF. Lightning Injury of the Tympanic Membrane. *Ann Otol Rhinol Laryngol* 102: 1993. 867 – 869.
17. Gordon MA, Silverstein H, et al. Lightning Injury of the Tympanic Membrane. *The American Journal of Otology*. 1995;16 (3). May: 373 – 376.
18. Jones DT, Ogren FP, et al. Lightning and Its Effects on the Auditory System. *Laryngoscope*. 1991; 101: 830 – 834.
19. Bergstrom L, Lewis M, et al. The Lightning Damaged Ear. *Arch Otolaryngol*. August 1974. Vol 100.
20. Otologic Lightning Bolts. Weiss KS. *American Journal of Otolaryngology*. August 1980; 1 (4): 334 – 337.

21. Kristensen S, Tvetaras K. Lightning-Induced Acoustic Rupture of the Tympanic Membrane – A report of Two Cases. *The Journal of Laryngology and Otology*. July 1985; 99: 711 – 713.
22. Glunic I, Roje Z. Ear Injury Caused by Lightning: Report of 18 Cases. *The Journal of Laryngology and Otology*. January 2001; 115: 4 –8.
23. Wright JW. Acoustic and Vestibular Defects in Lightning Survivors. Presented at the meeting of the Middle Section of the American Laryngological, Rhinological and Otological Society, Inc. Kansas City, Mo. January 19 1974.

FIGURE 1. The line diagram shows the whole event taking place.

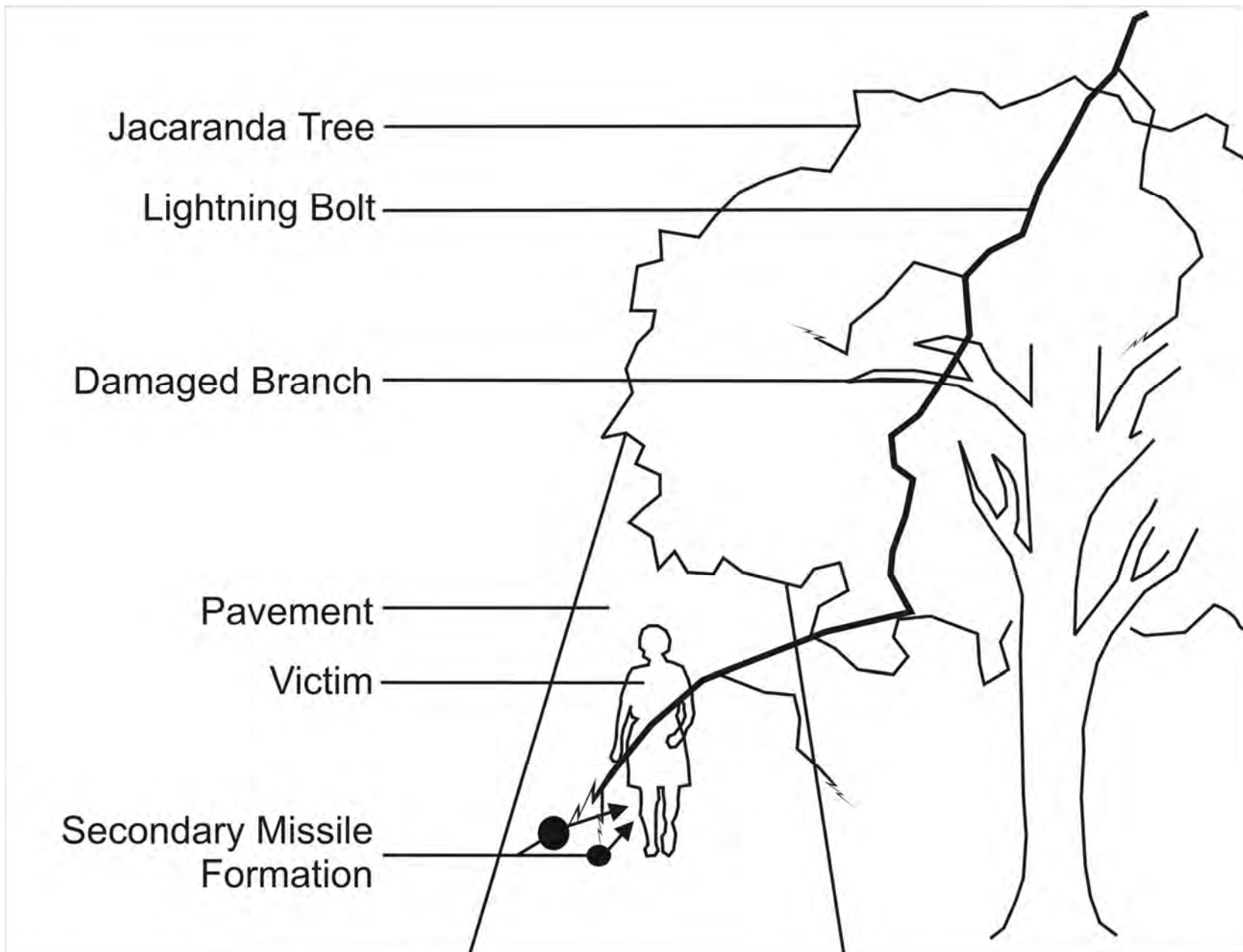


FIGURE 2. Photograph of the jacaranda tree.



FIGURE 3. Photograph of the crater on the pavement.





FIGURE 4. Photograph of both legs.

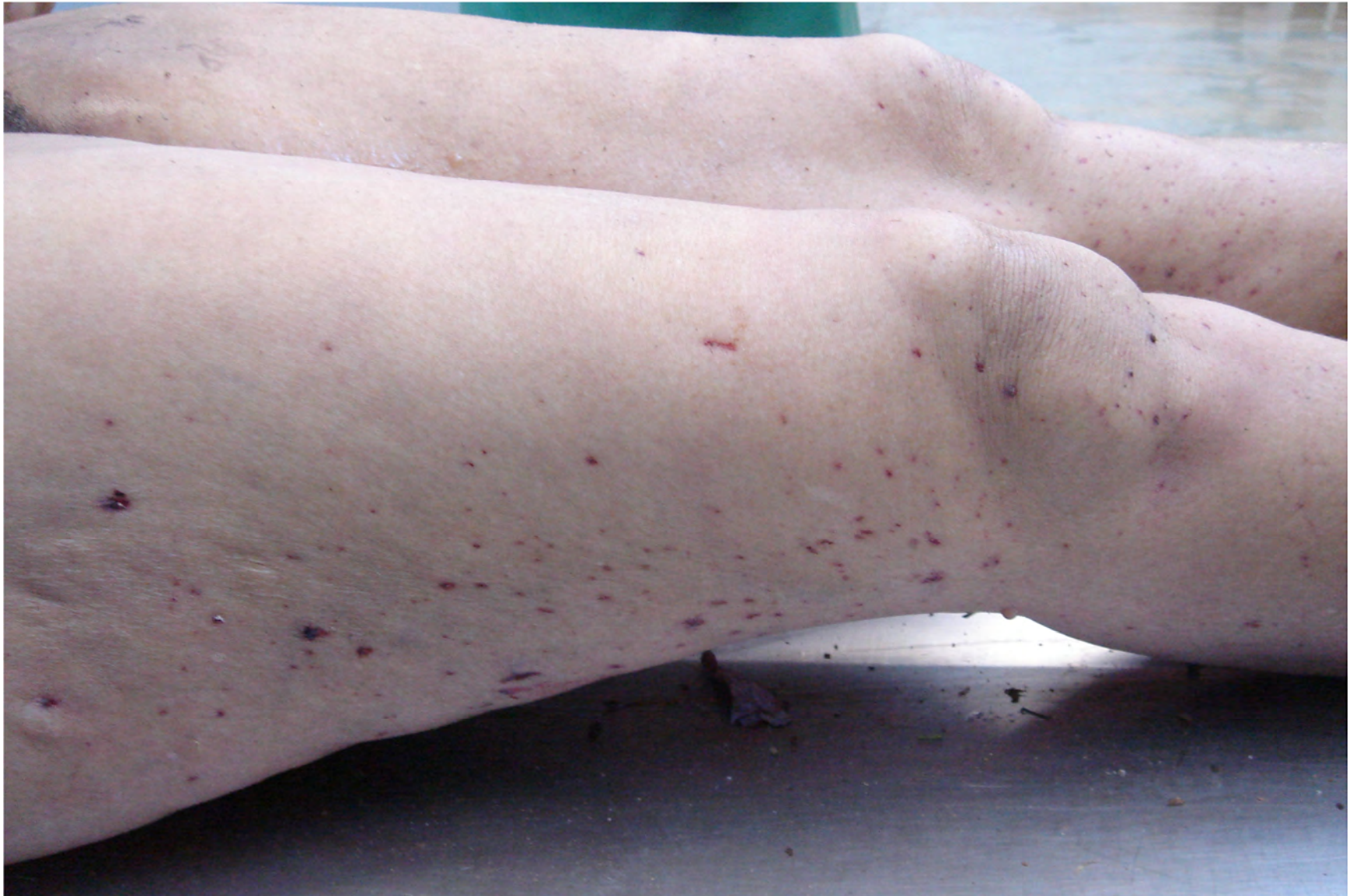

FIGURE 5. Close-up photograph of the shrapnel wounds.

