

## A severe case of astrogliosis and encephalomalacia in a neonate with a massive vein of Galen malformation (VGM)

**F Ismail, FC Rad (D)**

**N Khan, FC Rad (D)**

**I van de Werke, FRCR**

**R Ahmed, MB ChB**

Department of Radiology, Kalafong Hospital and University of Pretoria

Corresponding author: F Ismail (drfismail@yahoo.com)

### Abstract

Vein of Galen malformations (VGMs) are rare anomalies of intracranial circulation that constitute 1% of all intracranial vascular malformations. We describe a case of severe encephalomalacia associated with a VGM, which has not been previously described.

### Clinical presentation

A 19-year-old woman (para 1, gravida 1) delivered a baby girl at 36 weeks' gestational age. Antenatal blood test results showed that the mother was Rhesus positive, the rapid plasma reagin (RPR) for syphilis was negative, and she was HIV-positive (she was receiving treatment). There were no other significant findings in the maternal history. There was no record of antenatal ultrasound findings. The baby was delivered by normal vaginal delivery, with a birth weight of 2 670 g and Apgar scores of 5/10 at 1 minute and 7/10 at 5 minutes. The baby had an initial heart rate of 86 beats per minute, was pale and cyanosed (respiratory rate of 50 breaths per minute), with oxygen saturation levels of 88 - 92%. The baby was resuscitated, after which her pulse and saturation improved.

Examination revealed cardiomegaly with the apex in the sixth intercostal space in the anterior axillary line. A pansystolic murmur and a palpable second heart sound (P2) was present on auscultation. Chest radiographs demonstrated significant cardiac enlargement with signs of congestive cardiac failure (Fig. 1). This prompted cardiac ultrasound which demonstrated right atrial dilatation, an inter-atrial septal aneurysm (Fig. 2) with a right to left shunt. There was pulmonary hypertension with a large tricuspid incompetence and a dilated right ventricle. A patent ductus arteriosus (PDA) with right to left shunt was also visualised. The degree of right to left shunt suggested a possible 'steal phenomenon' owing to an arterio-venous malformation (AVM). In the search for a high-volume extra-cardiac shunt, cerebral ultrasound revealed a vein of Galen malformation (VGM) with massive hydrocephalus with no normal brain parenchyma (Fig. 3). Contrast-enhanced computed tomography confirmed the ultrasound findings, showing dilated, tortuous contrast enhancing vessels, a dilated VGM and massive hydrocephalus with no visualised brain parenchyma (Fig. 4).

The baby died 2 days later and underwent postmortem. The findings confirmed the presence of a large VGM, massive hydrocephalus and no normal brain tissue identified macroscopically. There was hypertrophy of the left atrium (LA) and right myocardium, and right heart failure

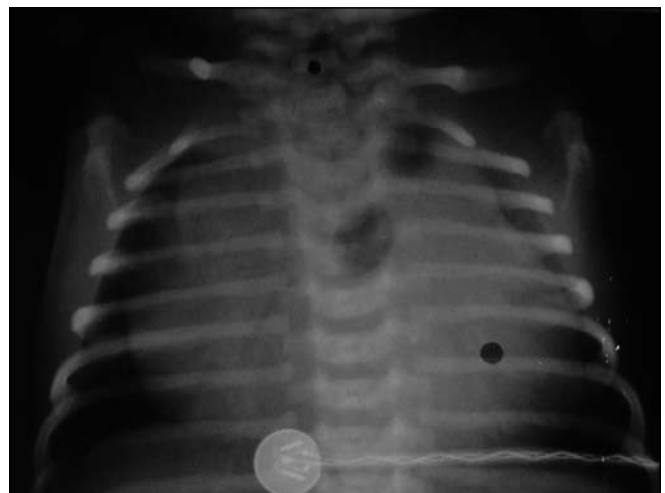

Fig. 1. Frontal radiograph of the patient's chest shows massive global cardiomegaly.

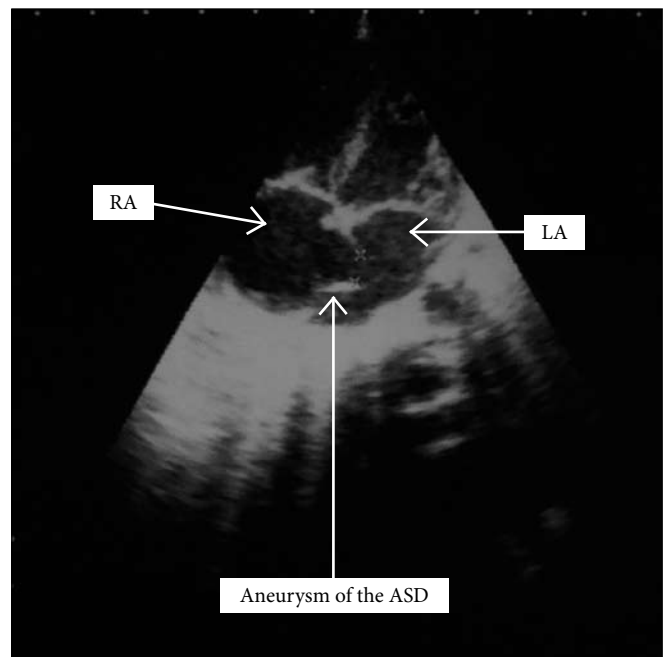


Fig. 2. Four-chamber cardiac ultrasound demonstrates enlargement of the RA with aneurysm of the ASD. Doppler studies (not shown) showed right to left shunting of blood.

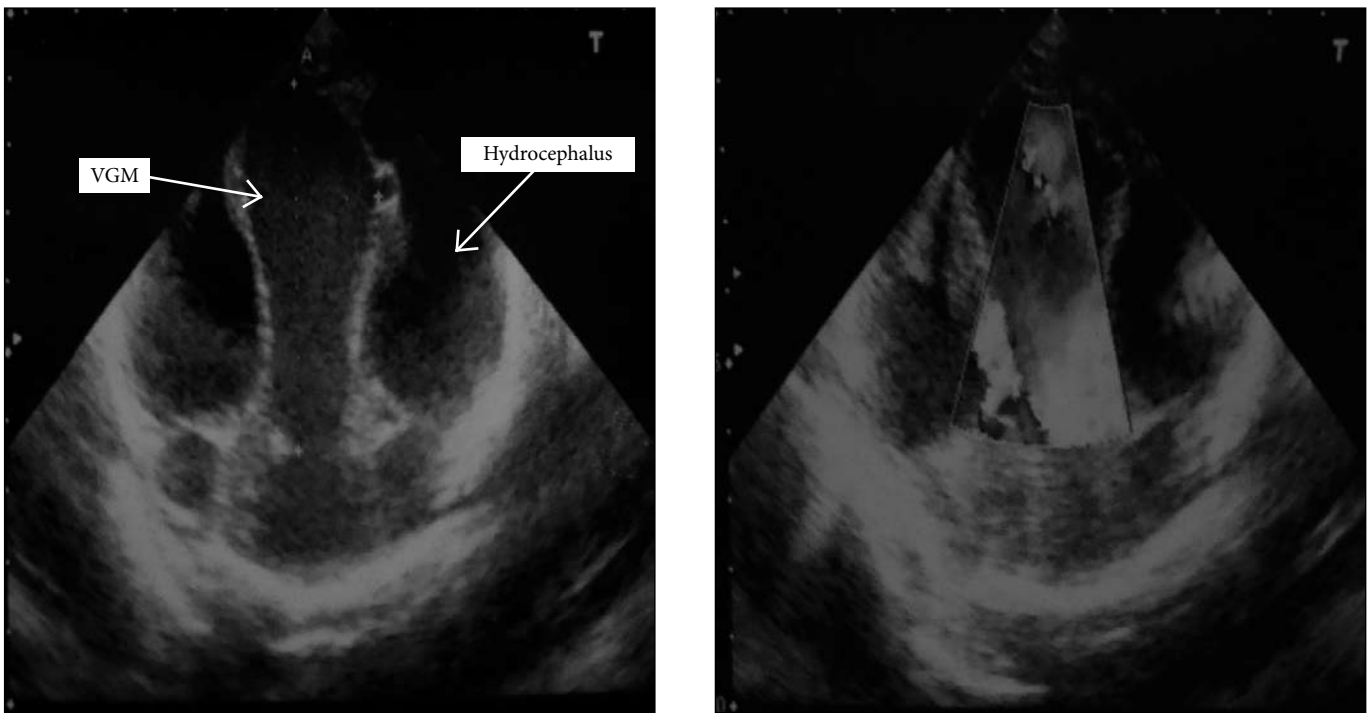


Fig. 3. Coronal cranial ultrasound demonstrates enlarged central vein of Galen with increased blood flow on Doppler study (left) and massive hydrocephalus with no brain parenchyma.

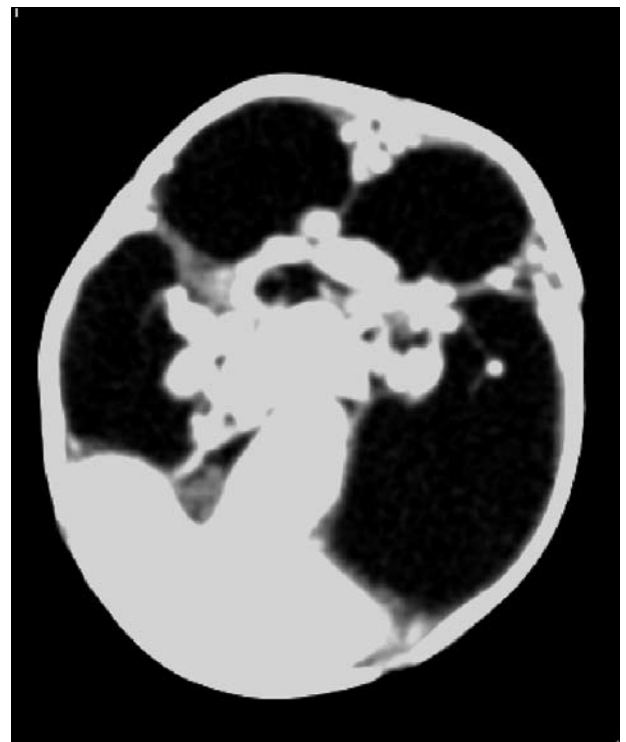
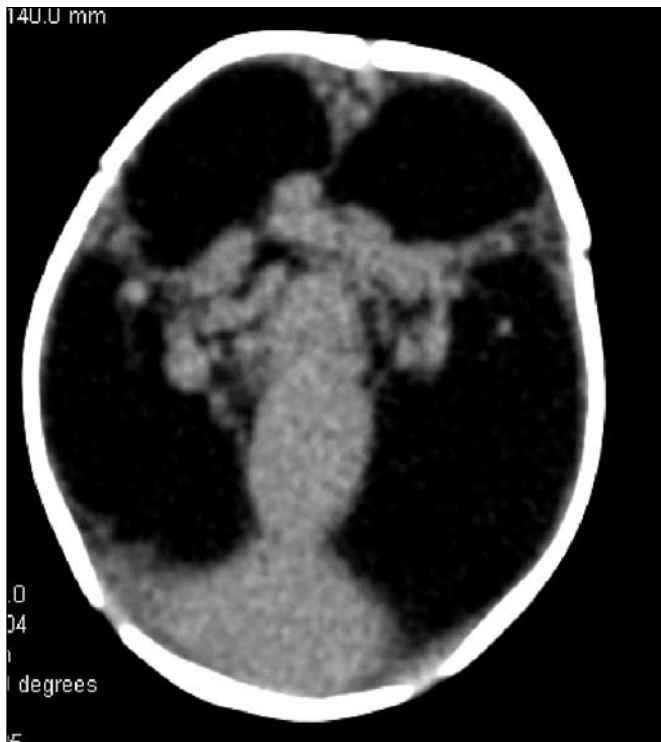

Fig. 4. Axial non-enhanced and enhanced computed tomography of the brain demonstrates dilated, tortuous vessels draining into a large vein of Galen with secondary hydrocephalus and astrogliosis with no brain parenchyma.

owing to the right to left shunt. An atrial septal defect (ASD) and PDA were also noted. No other anomalies were found.

### Discussion

VGMs are rare anomalies of intracranial circulation that constitute 1% of all intracranial vascular malformations.<sup>1</sup> They represent 30% of vascular

malformations in the paediatric age group.<sup>1</sup> The first description of a possible VGM was reported by Steinhel in 1895.<sup>2</sup> Raybaud and co-workers were the first to recognise the ectatic venous structure that is characteristically seen in these lesions representing the median prosencephalic vein (MPV) and not the vein of Galen itself.<sup>1</sup> The MPV is responsible for drainage of the choroid plexus prior to the development

of the internal cerebral veins, during embryogenesis, prior to the 11th week of gestation.<sup>1</sup>

VGMs form during the late somite stages of the 4th week of embryonic life. The malformation consists of persistent primitive connections between the arteries and veins that develop from the sinusoidal vascular network of the telencephalon.<sup>3</sup> Absence of capillaries results in a low-resistance shunt, which results in rapid arterio-venous shunt within the malformation.<sup>3</sup> This results in blood flow away from the parenchyma, resulting in hypoperfusion, with consequent astrogliosis and atrophy.<sup>3</sup> High pressure and shear stresses from turbulent flow may result in the formation of arterial aneurysms, stenosis or occlusion in the draining veins, particularly where the vein enters a dural sinus.<sup>3</sup>

More recently, anatomical and embryological evidence has allowed VGMs to be categorised as specific choroidal type or mural type.<sup>4,5</sup> There is a relationship between the choroidal type of malformation and heart failure in neonates, and it is more severe in presentation than the mural type, as was the case with our patient.<sup>4,6</sup> The mural type is characterised by fewer (1 - 4) large-calibre connections that drain into the wall of the MPV.<sup>5,6</sup> There is also a distinction between the VGM and the Vein of Galen aneurysmal dilation (VGAD) which are AVMs localised in the subpial space, which drain into a tributary of the vein of Galen, resulting in overload and dilatation.<sup>4,5</sup> The vein of Galen varix refers to a varicose dilation of the vein of Galen without an underlying arterio-venous shunt.<sup>4</sup>

Increased venous return to the right heart promotes shunting of blood through a patent foramen ovale and ductus venosus. This leads to cyanosis and often refractory congestive cardiac failure.<sup>1,7</sup>

Neurological manifestations occur as a direct result of cerebral venous hypertension that prevents drainage of cerebrospinal fluid (CSF) via the medullary veins. Transependymal drainage of CSF, followed by medullary venous drainage, supervenes as arachnoid granulations are not fully matured in the neonate.<sup>1,4</sup> This in turn causes chronic hypoxia, ischaemia, hydrocephalus and cerebral oedema.<sup>1</sup> Chronic hypoxia results in progressive cerebral parenchymal damage.<sup>1</sup> Cerebral damage can be severe, as cases of hydranencephaly with arterial and venous malformations have been reported.<sup>7</sup> This was the case in our patient, who developed severe leucomalacia and astrogliosis owing to chronic intra-uterine hypoxia.

## Conclusion

VGMs are rare anomalies that may cause secondary neurological abnormalities. The degree of hypoxic damage and hydrocephalus, as seen in our case, has not been previously documented.

1. Gupta AK, Varma DR. Vein of Galen Malformations: Review. *Neurology India* 2004;52:43-53.
2. Lasjaunias PL, Chng SM, Sachet M, Alvarez H, Rodesch G, Garcia-Monaco R. The management of vein of Galen aneurysmal malformations. *Neurosurgery* 2006;59(5):184-194.
3. Barkovich AJ. *Paediatric Neuroimaging*. 4th ed. Baltimore, USA: Lippincott Williams and Wilkins, 2005:873-878.
4. Alvarez H, Garcia Monaco R, Rodesch G, Sachet M, Krings T, Lasjaunias P. Vein of Galen aneurysmal malformations. *Neuroimaging Clin N Am* 2007;17:189-206.
5. Du Toit J, Bam JA, Mngomezulu V. Endovascular treatment of vein of Galen aneurysmal malformation. *South African Journal of Radiology* 2009;13:12-17.
6. Osborn A, Blaser SI, Salzman KL, et al. *Diagnostic Imaging: Brain*. Salt Lake City, USA: Amirsys, 2007:12-14.
7. Stevenson DA, Hart BL, Clericuzio CL. Hydranencephaly in an infant with vascular malformations. *Am J Med Genet* 2001;104:295-298.