

Case report and images in cardiology

Shone's complex variant associated with a patent ductus arteriosus: Simultaneous treatment of coarctation and patent ductus arteriosus using a covered stent.

Farirai F. Takawira*, **Greenwood Sinyangwe***,
Michael N. Mwangi[#] and **Tshimbiluni M. Mathivha[#]**

*Department of Paediatric Cardiology, Steve Biko Academic Hospital and University of Pretoria, South Africa

[#]Department of Cardiology, Steve Biko Academic Hospital and University of Pretoria, South Africa

Address for correspondence:

Prof F.F. Takawira
Department of Paediatric Cardiology
Level D3 - Department of Paediatrics
Steve Biko Academic Hospital and University of Pretoria
Private Bag X169
Pretoria
0001
South Africa

Email:

fari.takawira@up.ac.za

INTRODUCTION

Shone's complex was first described in 1963 by Shone et al., who noted on post-mortem examinations the tendency of four obstructive left-sided lesions (supramitral ring; parachute mitral valve; subaortic stenosis; and coarctation of the aorta) to co-exist.⁽¹⁾ The developmental complex may exist in its complete form when all four lesions are present or it may be incomplete. Management for these defects has mainly been surgical and early in childhood. We describe an adult with Shone's complex, a patent ductus arteriosus (PDA) and pulmonary hypertension who had a successful percutaneous therapeutic catheterisation procedure. Simultaneous treatment of coexistent coarctation of the aorta and a PDA using a covered stent, in the setting of Shone's complex has not been previously described.

ABSTRACT

Shone's complex is a rare cardiac anomaly consisting of four obstructive lesions of the left heart: supramitral membrane/ring; parachute mitral valve; subaortic stenosis; and coarctation of the aorta. We report on an 18 year-old woman with a variant of Shone's complex, associated with a large patent ductus arteriosus (PDA) and pulmonary hypertension. She underwent a successful percutaneous therapeutic catheterisation for the treatment of the coarctation of the aorta and the large PDA using a 45mm covered stent. To our knowledge, this is the first reported case where a covered stent was deployed to treat a native coarctation of the aorta and a PDA in a patient who also had a parachute mitral valve and a bicuspid aortic valve.

SAHeart 2010; 7:282-286

CASE REPORT

An 18 year-old young woman was referred from a secondary hospital to our cardiology service with a history of decreased effort tolerance, dyspnoea and generalised oedema for three months. She had been confirmed human immune deficiency virus (HIV) positive with a normal CD4 count. On further questioning she admitted to having had exertional dyspnoea for several years and that she had been advised from early childhood that she had a congenital heart defect. She did not seek medical attention since she was orphaned in childhood.

On clinical examination she was in New York Heart Association (NYHA) congestive heart failure (CHF) Class 3 and had a pulse of 75 bpm. She was acyanotic and had no digital clubbing. Her femoral pulses were weak. The blood pressure was 160/90mmHg and 100/70mmHg in the right arm and right leg respectively. A left precordial bulge was evident. There was cardiomegaly with the apex beat in the 5th left intercostal space and lateral to the mid-

clavicular line. A systolic thrill was palpable over the left upper sternal border and the neck. A loud, narrowly split 2nd heart sound was audible. A 4/6 ejection systolic murmur radiating to the neck was heard. She was in congestive cardiac failure as evidenced by generalised oedema, hepatomegaly and orthopnoea.

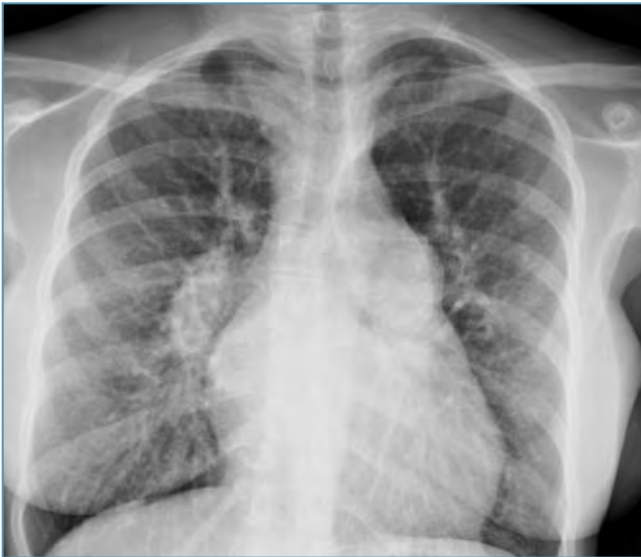

FIGURE 1: Chest radiography demonstrating mild cardiomegaly, large main pulmonary artery segment and peripheral pruning.

Chest radiography (Figure 1) revealed mild cardiomegaly with a large main pulmonary artery segment and peripheral pruning. Electrocardiography (Figure 2) demonstrated right axis deviation, left atrial enlargement and right ventricular hypertrophy.

Transthoracic and transoesophageal echocardiography demonstrated a parachute mitral valve with mild stenosis, with mean and peak diastolic gradients of 10mmHg and 23mmHg respectively (Figure 3). The estimated mitral valve area was 1.8-2.2cm² by the planimetry and pressure half time methods. The gradient across the MV was probably exaggerated by the left to right shunt across the PDA. A bicuspid aortic valve with mild aortic stenosis, severe coarctation of the aorta and a large PDA with severe pulmonary hypertension were also present.

The coarctation of the aorta and PDA were also well demonstrated on spiral computed tomographic (CT) scan (Figure 4).

At cardiac catheterisation both the right femoral artery and vein were cannulated. Severe pulmonary hypertension of 80/50mmHg

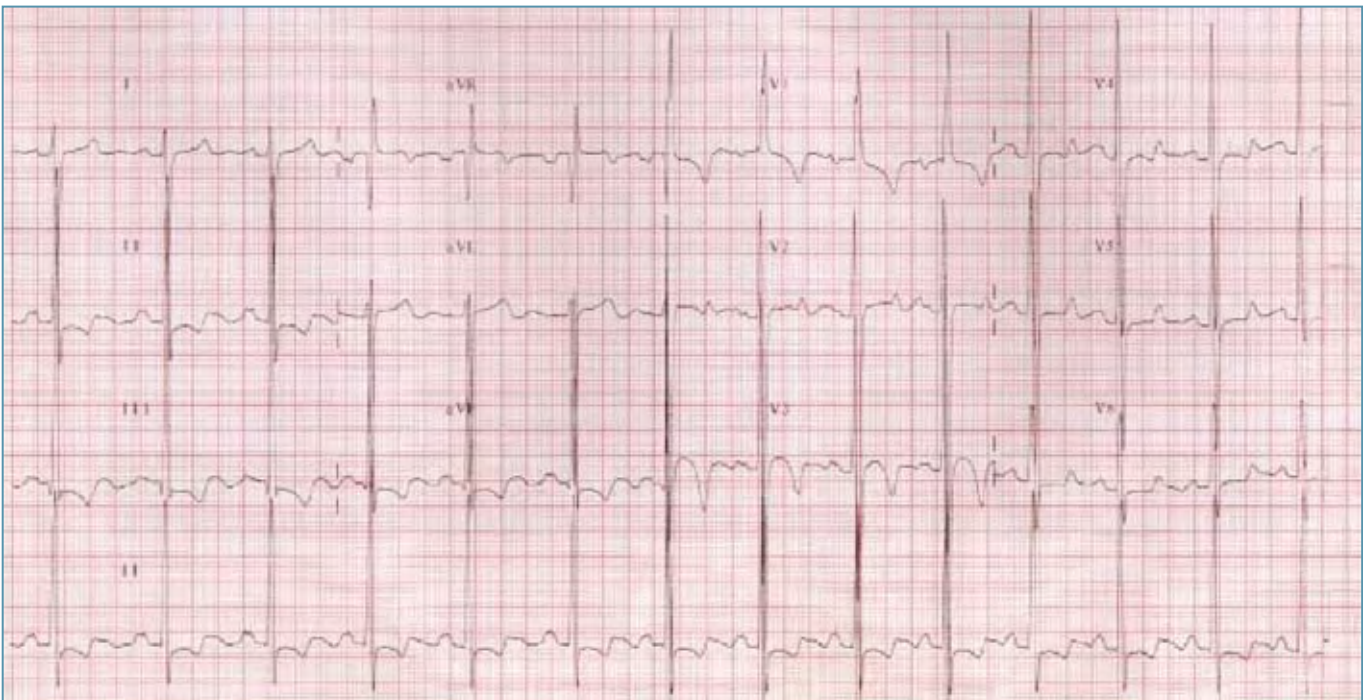

FIGURE 2: Electrocardiography demonstrating right axis deviation, left atrial enlargement and right ventricular hypertrophy.

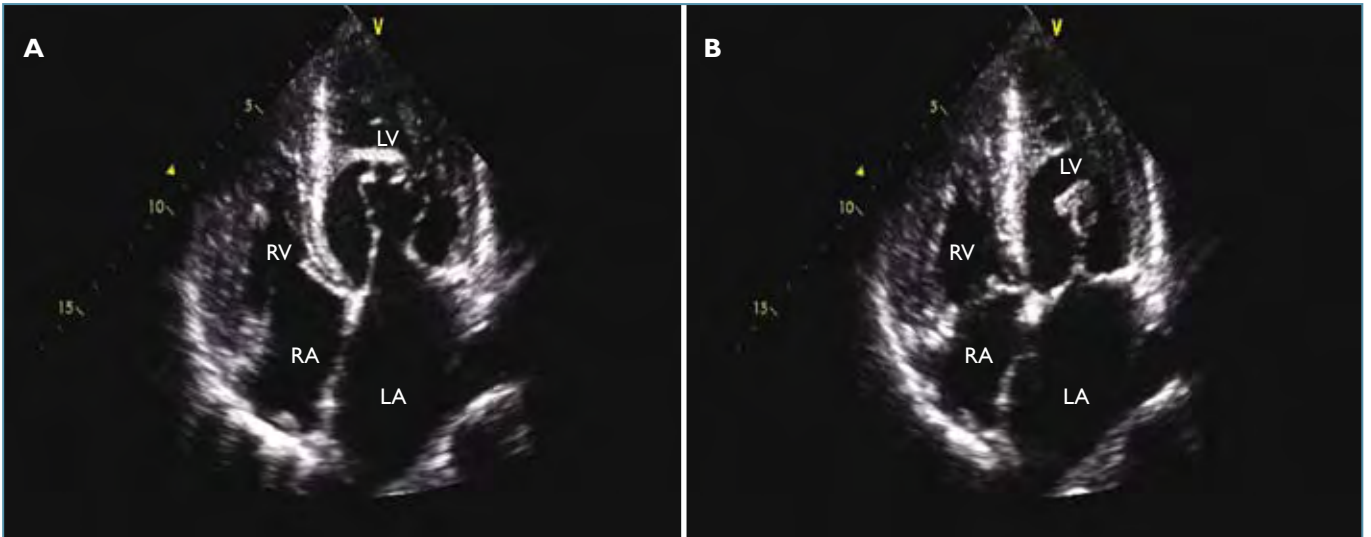


FIGURE 3: Transthoracic echocardiography demonstrating the parachute mitral valve. A: apical four chamber view in diastole; B: apical four chamber view in systole.

LA: left atrium, LV: left ventricle, RA: right atrium, RV: right ventricle

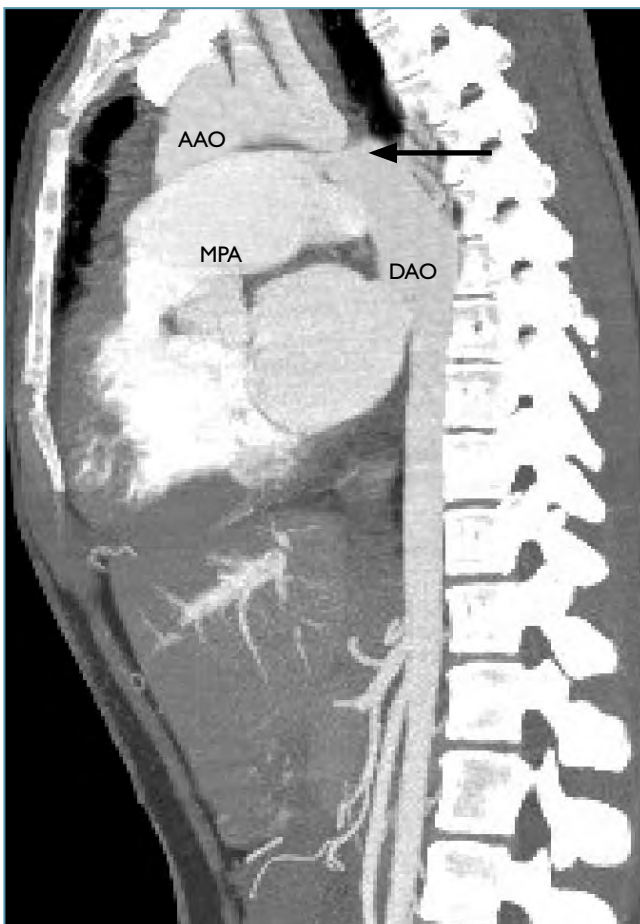


FIGURE 4: Spiral CT angiography scan demonstrating tight, discrete coarctation of the aorta and a large PDA (arrow).

AAO: ascending aorta, CT: computed tomographic, DAO: descending aorta, MPA: main pulmonary artery, PDA: patent ductus arteriosus

was demonstrated. There was a small left to right shunt with a Qp:Qs ratio of 1.3:1. The pulmonary vascular resistance of 9 Wood units on room air dropped to 4.8 Wood units after the administration of 100% inspired oxygen for 10 minutes suggesting the pulmonary hypertension was still reversible and therapeutic intervention still possible. There was a mild gradient of 15mmHg across the left ventricular outflow tract indicating mild aortic stenosis. There was a gradient of 55mmHg across the descending aorta in keeping with severe coarctation of the aorta. Angiography also confirmed discrete, juxtaductal severe coarctation of the aorta with a large PDA. As both the mitral and aortic valve stenoses were deemed to be of little significance, the therapeutic intervention was focused on the PDA and coarctation of the aorta. A percutaneous transcatheter therapeutic approach was chosen over the more invasive, traditional surgical approach due to the perceived decreased morbidity and reduced length of hospital stay. Under general anaesthesia and using the technique described by Sadiq et al. and Kulkarni et al., a 45mm expandable covered stent (NuMed Inc., Hopkinton, New York) was selected and hand crimped over the BIB balloon (NuMed Inc., Hopkinton, New York).^(2,3) The BIB balloon has an 8mm inner and a 16mm outer balloon, which allows for repositioning of the stent after inflation of the inner balloon. Using a wide bore (14F) long sheath (Mullins,

Cook, Bloomington, Indiana) placed over a 0.035-inch extra-stiff Amplatzer® exchange guide wire, the BIB balloon and mounted stent were then positioned and deployed across the coarcted segment ensuring the stent also straddled the PDA. Repeated angiography was used to check for ideal positioning. Once the ideal position was attained, both the inner and outer balloons were inflated serially. On repeat angiography (Figure 5) the narrowed area of coarctation had expanded from 4.8mm to 15mm after the procedure. There was no residual coarctation or pressure gradient across the stented segment. The PDA was completely occluded by the covered stent. There was no dissection, rupture or any other complication. She was discharged from hospital 48 hours after the procedure on metoprolol for mild residual systemic hypertension, but this was subsequently stopped six months later.

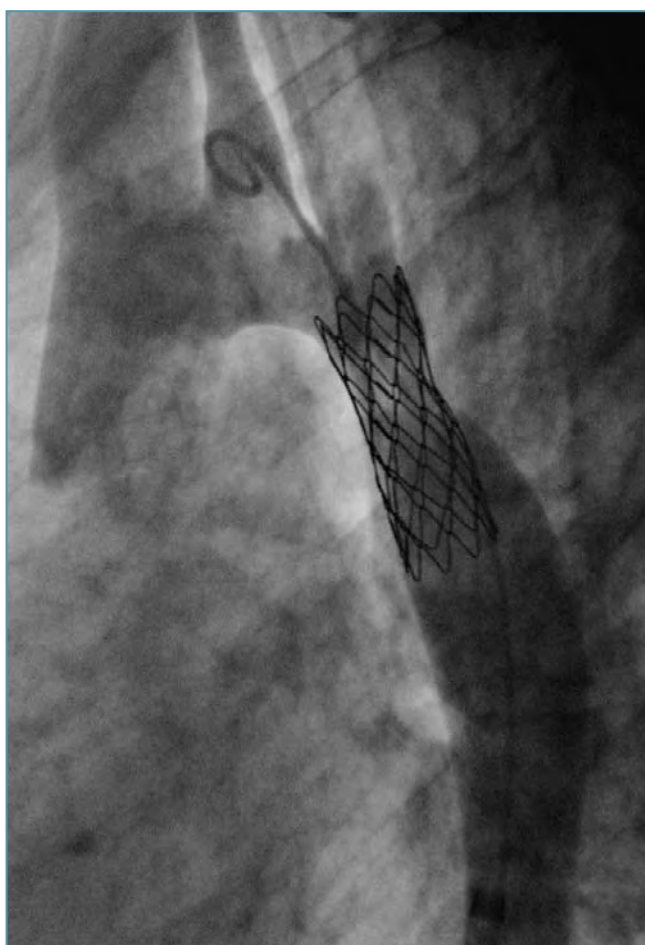


FIGURE 5: Descending aorta angiography demonstrating the deployed covered stent with resolution of the coarctation of the aorta and occlusion of the PDA.

Her mitral stenosis and aortic stenosis have remained mild on follow-up visits. The systolic pulmonary pressure, estimated from spectral Doppler gradient across the tricuspid valve, has dropped to 40mmHg. She has not required the use of any pulmonary vasodilators for the management of residual pulmonary hypertension. She is now out of congestive cardiac failure and is in NYHA (CHF) Class I. Eighteen months after the procedure she carried her first pregnancy through to term with no haemodynamic compromise and delivered a live full-term baby by Caesarean section.

DISCUSSION

Shone's complex is a rare congenital anomaly comprising a supra-mitral ring; parachute mitral valve; subaortic stenosis; and coarctation of the aorta. In literature there is very little information available on adults with this condition. Published information mainly consists of case reports of neonates, infants and young children.^(1,4,5) Only two adult case reports have been published in English literature.^(6,7) The definition of Shone's anomaly has been expanded beyond the original description of 1963 by Shone et al. to include other variants of left heart obstruction.⁽¹⁾ Some of these inclusions are congenital mitral valvulopathy other than parachute mitral valve; tunnel aortic stenosis; valvar aortic stenosis; and supravalvar aortic stenosis.^(1,6,7) The majority of patients with the incomplete forms or forme fruste have other associated congenital anomalies like ventricular septal defect; bicuspid aortic valve; patent ductus arteriosus; and atrial septal defect.^(1,4) Our patient had a parachute mitral valve; bicuspid aortic valve with mild valvar stenosis; severe coarctation of the aorta; and a large PDA with pulmonary hypertension.

Clinical presentation and prognosis of patients with this anomaly are dependent on the complexity and severity of the different obstructive lesions.^(1,2,4,5) Most of the patients have severe lesions and present early in childhood. Our patient had survived into adulthood because of the mild degrees of mitral and aortic stenosis. Most patients, the majority of whom are children, have been managed surgically.^(1,4,5)

The development of pulmonary hypertension was a major concern in the management of our patient due to her late presentation. Fortunately the pulmonary hypertension was still reversible as evidenced by the drop in the pulmonary vascular resistance after the administration of 100% oxygen, excluding the development of Eisenmenger disease. The cause for the pulmonary hypertension is multi-factorial and can be attributed to the mitral stenosis, the large PDA and long standing left to right shunt with elevated pulmonary vascular resistance. The presence of the coarctation of the aorta would also have worsened the left to right shunt. The degree of mitral stenosis and mild residual pulmonary hypertension are being regularly monitored, with a view to mitral valve replacement should this become worse.

Coarctation of the aorta and PDA in combination is a common occurrence in infants with congenital cardiac anomalies, but rare in adults. Treatment of these combined lesions in infants has been mainly surgical, by repairing coarctation of the aorta and ligation of the PDA.⁽⁴⁾ There have been two published case reports of successful simultaneous treatment of native coarctation of the aorta and patent ductus arteriosus with a covered stent as an alternative to surgery or other forms of interventional techniques.^(2,3,8) In the first case report, the Cheatham-Platinum (CP)-covered stent was pre-mounted on the BIB balloon; while in the second case the covered stent was hand-crimped on the BIB balloon.^(2,3) Our case and the two other reported cases demonstrate that the use of covered stents to simultaneously treat coarctation of the aorta and a co-existent PDA in adult patients is a viable option to surgery. The morbidity and hospital stay is reduced as the patient can often be discharged from hospital after 24 to 48 hours. The procedure can even be done under local anaesthesia, though we elected for general anaesthesia in our patient.⁽³⁾ We anticipated the procedure would be lengthened by the need to confirm that the pulmonary hypertension was still reversible and that there was no Eisenmenger disease. The use of stents in pre-adolescent children is limited by the need for a large sheath in the femoral artery and the maximum stent size deployable in a growing child. This is likely to change in future with the advent of expandable covered stents,

which can be re-dilated once full growth has been achieved. There will not be a need to re-expand the stent in our patient who has already achieved her maximum adult growth. Complications that have been described include aortic dissection or rupture and occlusion of vital arterial branches like the spinal artery.^(2,3)

Our patient is the only reported case of an adult with Shone's anomaly where a covered stent was used successfully in the treatment of native coarctation of the aorta and a large patent ductus arteriosus as a single therapeutic catheterisation procedure.

REFERENCES

1. Shone JD, Sellers RD, Anderson RC, et al. The developmental complex of "parachute mitral valve," supraaortic ring of left atrium, subaortic stenosis, and coarctation of aorta. *Am J Cardiol* 1963;11:714-725.
2. Sadiq M, Malik NH, Qureshi SA. Simultaneous treatment of native coarctation of the aorta with patent ductus arteriosus using a covered stent. *Catheter Cardiovasc Interv* 2003;59:387-390.
3. Kulkarni S, Vimala J, Parmar R. Single therapeutic catheterisation for treatment of native coarctation of aorta and large patent ductus arteriosus using a covered stent. *Indian Heart J* 2005;57:713-716.
4. Brown JW, Ruzmetov M, Palaniswamy V, et al. Operative results and outcomes in children with Shone's anomaly. *Ann Thoracic Surg* 2005;79:1358-65.
5. Brauner RA, Laks H, Drinkwater DC Jr, et al. Multiple left heart obstruction (Shone's anomaly) with mitral valve involvement: long-term surgical outcome. *Ann Thoracic Surg* 1997;64:721-9.
6. Prunier F, Furber AP, Laporte J, et al. Discovery of a parachute mitral valve complex (Shone's anomaly) in an adult. *Echocardiography* 2001;18:179-182.
7. Moustafa SE, Lesperance J, Rouleau J, et al. A forme fruste of Shone's anomaly in a 65 year-old patient. *McGill J Med* 2008;11:19-21.
8. Tzifa A, Ewert P, Brzezinska-Rajszyz G, et al. Covered Cheatham-Platinum stents for aortic coarctation. *J Am Coll Cardiol* 2006;47:1457-1463.