
CLINICAL ARTICLE

Chondromyxoid fibroma – A case series and radiological review

J van Heerden MBChB(Pret)

Registrar

JC Verwayen MBChB(Pret), DMRD RCP(London), RCS(Eng), MMed RAD(Pret)

Senior Consultant

DA Bam MBChB (Pret)

Registrar

Department of Radiology, Steve Biko Academic Hospital, University of Pretoria, Faculty of Health Sciences

Reprint requests:

Dr J van Heerden

Private Bag X169

Steve Biko Academic Hospital

Department of Radiology

Level 5, Bridge E, Room 51103

Pretoria

0001

E-mail: jolandivh@hotmail.com

Tel: (012) 354-2406

Fax: (012) 354-2771

Abstract

Chondromyxoid fibromas are rare, benign tumours that resemble cartilage, initially arising in the cortex of affected bones (most commonly the lower limbs).^{1,2}

Their documented incidence is less than 1% of all primary bone tumours (approximately 2% of all benign bone tumours) with males and females being equally affected.^{1,2}

This case series and radiological review demonstrates some of the typical findings associated with this tumour.

Introduction

Chondromyxoid fibromas are rare, benign tumours that consist of immature myxoid mesenchymal tissue with features of primitive cartilaginous differentiation.^{1,2}

Patients most commonly affected tend to be in their second or third decades of life.^{1,2}

The case series that follows depicts some of the classical findings associated with chondromyxoid fibromas.

Case series

The 16-year-old female patient, shown in *Figure 1*, presented with a painful mass in the region of her right distal tibia.

An 18-year-old male patient presented with a painful mass in the region of his right distal femur (*Figures 2 and 3*).

A 20-year-old female patient (*Figure 4*) presented with a mass in the region of her right proximal tibia.

Discussion

Chondromyxoid fibromas are rare, benign cartilage-like tumours. The initial clinical presentation varies from a mass (painful or painless, depending on the size) to a pathological fracture or as an asymptomatic incidental finding.

They occur predominantly in adolescent patients and young adults (patients in their second and third decades).^{2,3}

Common sites of occurrence (*Figure 5*) are the long bones of the lower limb (60%) especially the distal femur, proximal tibia and fibula.⁴ Other (less common) sites that can be affected include the short tubular bones of the hands and feet (20%) and the flat bones such as the pelvis and ribs (<20%).^{2,3} They present as eccentric lesions that may be metaphyseal (47%), meta-diaphyseal (20%), meta-epiphyseal (26%), diaphyseal (4%) or epiphyseal (3%), resulting in thinning and expansion of the adjacent bony cortex.³

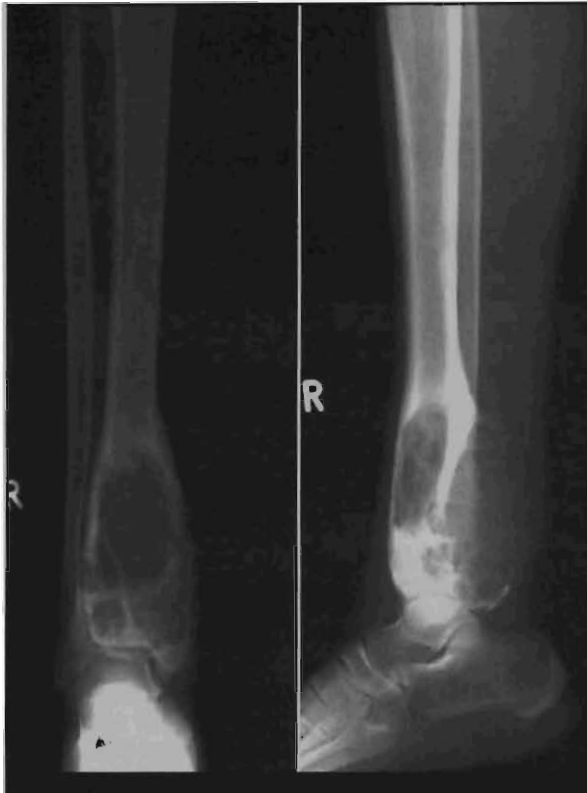

Figure 1: Frontal and lateral X-ray views of the right distal tibia, fibula and ankle demonstrate an eccentric, lobulated, expansile lesion with an ovoid shape and radiolucent centre. Note that the long axis of the lesion corresponds to the long axis of the host bone.

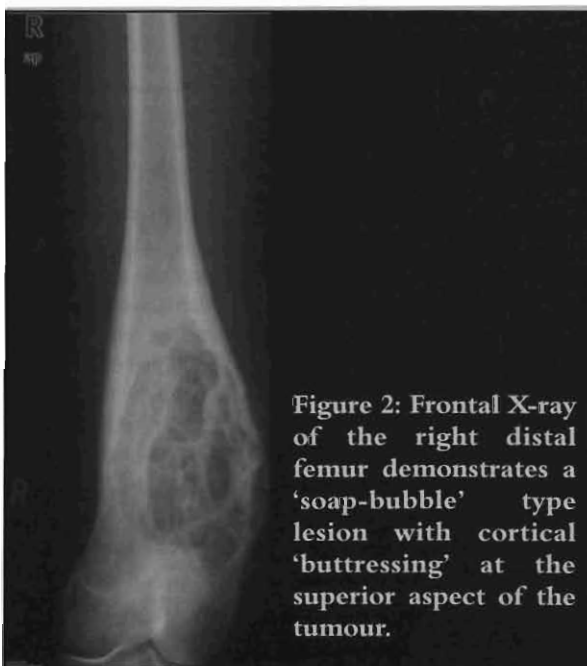


Figure 2: Frontal X-ray of the right distal femur demonstrates a 'soap-bubble' type lesion with cortical 'buttressing' at the superior aspect of the tumour.

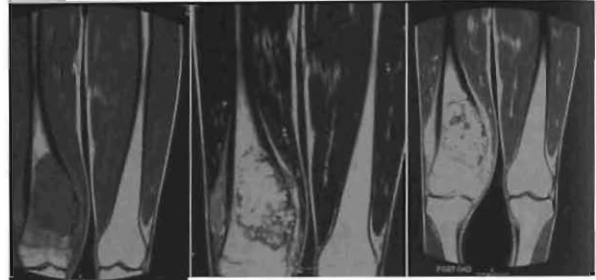


Figure 3: MRI images: T1WI, T2WI and post-Gadolinium T1WI.

The lesion in the distal right femur demonstrates low signal intensity on T1WI, non-homogenous high signal intensity on T2WI and marked non-homogenous contrast enhancement on post-Gadolinium T1WI. The lack of adjacent periosteal reaction and bone oedema suggests a more benign lesion.

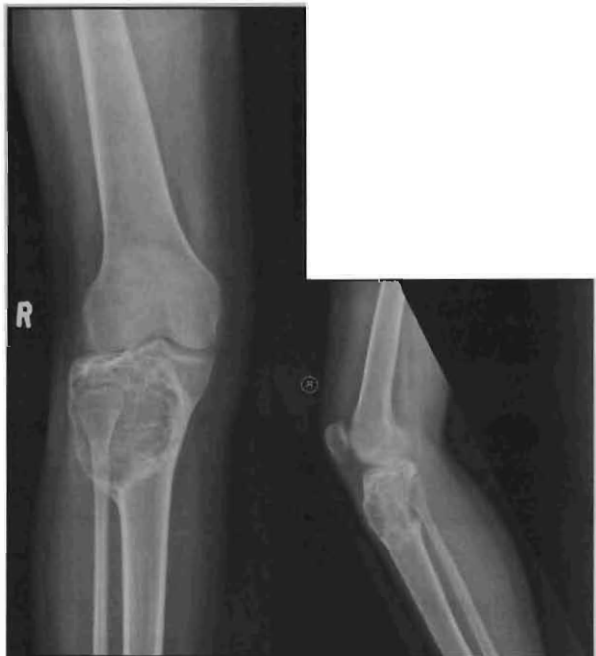

Figure 4: Frontal and lateral X-ray views demonstrating an expansile, 'soap bubble'-like lesion in the proximal right tibia. The lesion appears to demonstrate imaging findings suspicious of partial posterior cortical erosion.

Chondromyxoid fibromas are rare, benign cartilage-like tumours. They occur predominantly in adolescent patients and young adults

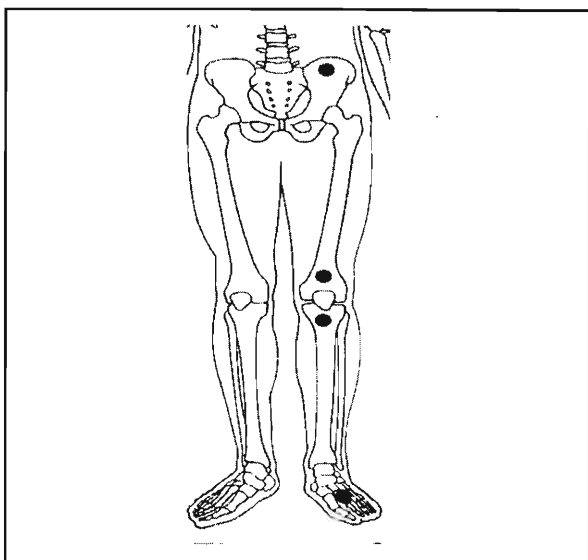


Figure 5: Common sites typically affected by chondromyxoid fibromas⁴

The surgical staging for benign musculoskeletal tumours can also be used when evaluating these tumours:²

- Stage 1: Latent
- Stage 2: Active
- Stage 3: Aggressive

On X-ray views they appear as eccentric and lobulated (soap bubble-like), expansile lesions.^{1,4} These tumours are characteristically ovoid in shape with sclerotic margins and radiolucent centres.³ Partial cortical erosion may be present.³ The long axis of the lesion is usually parallel to the long axis of the host bone.^{3,4} Septations within the lesion may mimic trabeculations.³ These tumours do not commonly demonstrate matrix calcifications or soft tissue extension/swelling.^{2,4} Cortical 'buttressing' at the junction where the expanding tumour abuts against the cortex may be seen.¹

Computed tomography (CT) can be used to further study the nature and extent of the tumour. It is the best imaging modality for detecting sclerotic tumour margins and ridges as well as matrix mineralisation.^{2,4} CT also readily depicts the cortical integrity of the lesion. Chondromyxoid fibromas demonstrate enhancement on post-contrast CT views.^{2,4}

Magnetic resonance imaging (MRI) is the preferred imaging modality for the evaluation of the true soft tissue extent of the lesion in order to aid with pre-operative planning and postoperative confirmation of complete resection.^{1,4} Chondromyxoid fibromas usually demonstrate low signal intensity on T1WI, heterogeneous high signal intensity on T2WI (most likely due to varying amounts of chondroid, myxoid and fibrous tissue) and high signal intensity on STIR (fat suppression) sequences.^{2,4}

Non-homogenous enhancement following intravenous administration of Gadolinium DTPA is typically noted (due to mixed tissue nature described above).^{2,4}

On Technetium-labelled bone scan views, the tumour demonstrates increased radiotracer uptake.² Should angiography be performed, the tumour characteristically demonstrates minimal angiogenesis.²

The treatment in most of the reported cases consists of intralesional curettage.⁴ Curettage with bone graft or osseous cement on its own has a high incidence of recurrence, up to 25%.⁶ Fotiadis *et al.* reported that curettage with a curette and a high frequency burr as well as osseous cement with a Kirschner needle leads to an improvement of bone stamina and a decreased rate of recurrence.⁷

Malignant degeneration is distinctly unusual. However, there have been isolated case reports describing malignant degeneration following radiotherapy.^{3,5} Thus, irradiation as a mode of therapy is contraindicated.⁵

The differential diagnosis includes:

- simple bone cyst^{3,4}
- aneurysmal bone cyst – usually demonstrates fluid-fluid levels and periosteal new bone formation without matrix mineralisation²
- Non-ossifying fibroma – usually no cortical ballooning or cortical erosion²
- Fibrous dysplasia – usually at a central location without internal septations. The peak incidence of osteofibrous dysplasia occurs in the first decade of life and the lesions typically demonstrate more sclerosis²
- Giant cell tumour – expansile, lytic tumour that usually extends to the subchondral bone²
- Enchondroma – more classically involves the hands and feet⁴
- Chondroblastoma – usually epiphyseal lesions with calcified matrix in approximately 50 per cent of tumours²

Conclusion

Chondromyxoid fibromas are rare tumours that should form part of the differential diagnosis to be considered in expansile, ovoid bone tumours with a 'soap bubble'-like appearance and cortical buttressing along the tumour margins.

The final, definitive diagnosis is made by clinical, radiological and pathological evaluation of tumour characteristics. Histologically the tumour consists of primitive cartilaginous tissue, fibrous tissue as well as immature myxoid tissue that may, histologically, mimic a chondrosarcoma – thus necessitating imaging modalities (X-ray, CT and MRI) to aid in the final diagnosis.²

In the absence of exposure to radiotherapy, the potential of malignant degeneration of chondromyxoid fibromas is rare.

Malignant degeneration is distinctly unusual and irradiation as a mode of therapy is contraindicated

Acknowledgements

Prof ZI Lockhat, University of Pretoria – Faculty of Health Sciences, Head: Department of Radiology, Steve Biko Academic Hospital.

No benefits of any form have been received from a commercial party related directly or indirectly to the subject of this article. The content of this article is the sole work of the authors.

References

1. Adam A, Dixon AK. Grainger & Allison's Diagnostic Radiology. 5th ed. In: Stoker DJ, Saiffudin A. *Bone Tumors: General Characteristics and Benign Lesions*. Philadelphia: Elsevier Churchill Livingstone; 2008: 1039-41.
2. Stoller DW, Tirman PFJ, Bredella MA. *Diagnostic Imaging Orthopaedics*. Salt Lake City: Amirsys; 2004: 8/30-8/33.
3. Dähnert W. *Radiology Review Manual*. 6th ed. Philadelphia: Lippincott Williams & Wilkins; 2007: 57-8.
4. Greenspan A. *Orthopedic Imaging*. 4th ed. Philadelphia: Lippincott Williams & Wilkins; 2004: 617-22.
5. Scott S, George J. Chondromyxoid Fibroma. [Data base on Internet]. eMedicine. [Updated: 2009/03/29; Sited: 2009/04/30]. Available from: <http://emedicine.medscape.com/article/388738>.
6. Durr HR, Lienemann A, *et al.* Chondromyxoid fibroma of bone. *Arch Orthop Trauma Surg* (2000)**120**:42-47.
7. Fotiadis E, Akritopoulos P, *et al.* Chondromyxoid fibroma: a rare tumour with an unusual location. *Arch Orthop Trauma Surg* (2008)**128**:371-375.

• SAOJ

PROFESSIONAL, EFFICIENT, SAFE and RELIABLE

Stuart Black the owner of A2B Shuttle Services has been in the transport business for the past 15 years having worked for Avis Chauffeur Drive, Airport Link and Luxury Limos. He began the Company with the aim of offering clients that 'additional extra' that makes their journey more relaxing when you travel with A2B.

A2B Shuttle Services began in 2008 and is an exciting emerging business with service offerings that include; door-to-door shuttle services, transporting clients to and from the airport, return Sun City trips as well as transportation around Gauteng and when required, travel anywhere within and around South Africa.

We also offer VIP chauffeur drive services for the business executive and accommodate those who enjoy an evening out without having to worry about drinking and then driving. We too are affiliated with established tour operators and can arrange any tour clients may wish to go on.



We Look Forward to Being of Shuttle Service to You

For a free quotation and/or booking you are welcome to call us directly on 076 552 6362; or send an email to info@a2bshuttle.com.