

## A visceral pseudoaneurysm: management by EUS-guided thrombin injection

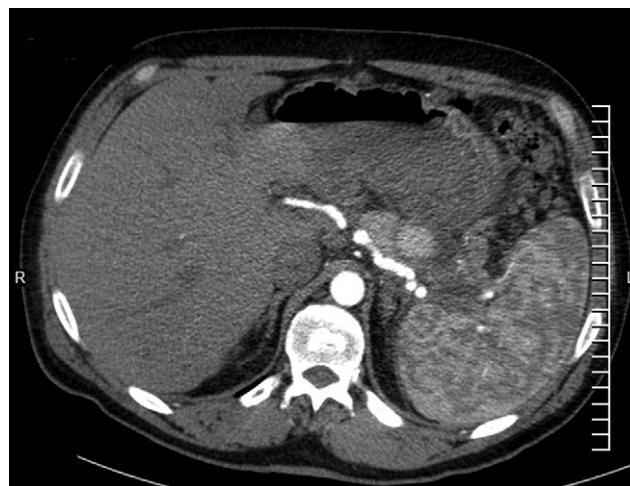Roeland Lameris, Jhannie du Plessis, BSc, Martin Nieuwoudt, BSc, Dipl Nuclear Med, PhD, Albrecht Scheepers, MBChB FC (Rad. Diagnostic), Schalk W. van der Merwe, MBChB, MMed Internal Medicine, PhD

Visceral pseudoaneurysm is a rare but well-described complication of pancreatitis<sup>1,2</sup> caused by the autodigestive function of pancreatic enzymes.<sup>3</sup> The splenic, gastroduodenal, pancreaticoduodenal, and hepatic arteries are most commonly affected.<sup>2,4</sup> Pseudoaneurysms require active management because of the high complication and mortality rates associated with rupture.<sup>2,5</sup> Traditional treatment options include aneurysm exclusion, surgical excision or ligation, revascularization, and endovascular techniques such as angiographic embolization.<sup>2,4,6</sup>

We report a case of a visceral pseudoaneurysm managed by EUS-guided thrombin injection and discuss the role of this novel technique.

### CASE REPORT

A 43-year-old man with chronic alcoholic pancreatitis was admitted with epigastric pain and hematemesis. The patient remained hemodynamically stable, although the hemoglobin count dropped to 9.5 g/dL. Upper GI endoscopy showed no blood in the stomach, and no esophageal or gastric varices or peptic ulcer disease was seen. Spiral CT demonstrated large dilated vessels around the stomach compatible with collateral vessel formation, pronounced inflammation around the pancreas, and a mass at the tail of the pancreas measuring 4 × 3.2 cm with the appearance of a pseudoaneurysm of the splenic artery (Fig. 1). Subsequently, a superselective angiogram was performed by using a C2 and Symmons type 1 catheter (Boston Scientific, Natick, Mass). The celiac trunk, splenic, hepatic, gastroduodenal, left and right gastric, and inferior and superior mesenteric arteries were visualized. The vascular stalk, however, could not be identified (Fig. 2). Neither percutaneous nor surgical management was feasible because of large collateral vessels, the location of the pseudoaneurysm, and the recent attack of acute-on-chronic pancreatitis with subsequent inflammation and adhesions. EUS-guided thrombin injection was selected because of the close proximity of the lesion to the gastric wall. The pseudoaneurysm, originating from the left gastric artery, was located by using a linear echoendoscope (Pentax Hitachi 7500; Pentax Hitachi, Montvale, NJ). A standard 22-gauge needle (Cook Endoscopy, Limerick, Ireland) was used to



**Figure 1.** Contrast-enhanced CT-scan demonstrating a pseudoaneurysm in close proximity to the splenic artery.

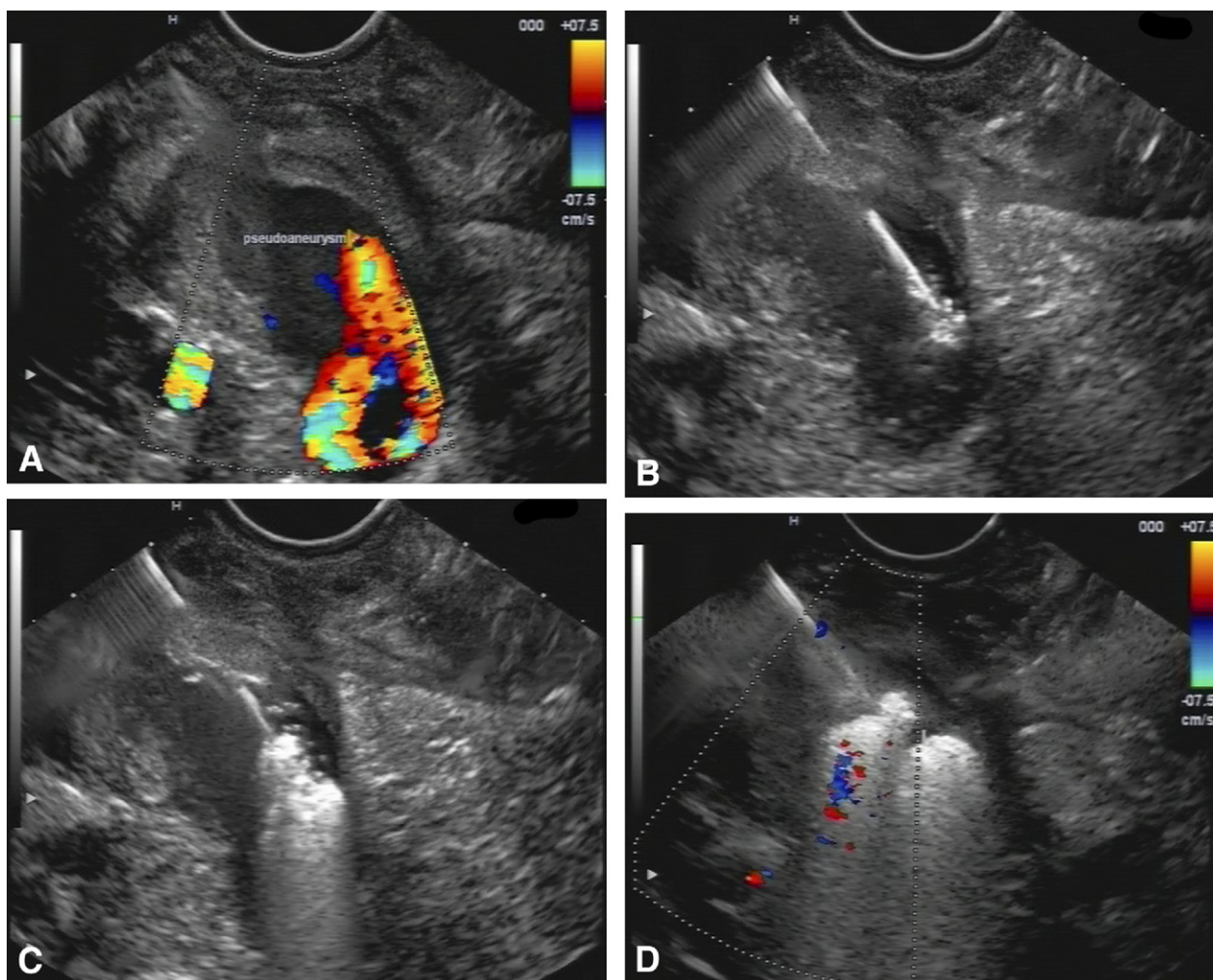
puncture the pseudoaneurysm, which was followed by injection of a total of 7 mL of a thrombin-collagen compound (D-stat; Vascular Solutions Inc, Minneapolis, MN). Color Doppler confirmed the complete obliteration of the lesion (Fig. 3).

The patient recovered fully with complete resolution of all symptoms and was discharged within 24 hours. CT angiographies at 6 weeks and 10 months showed no recurrence of the pseudoaneurysm (Fig. 4). The patient remains asymptomatic, without rebleeding, after 10 months in follow-up.

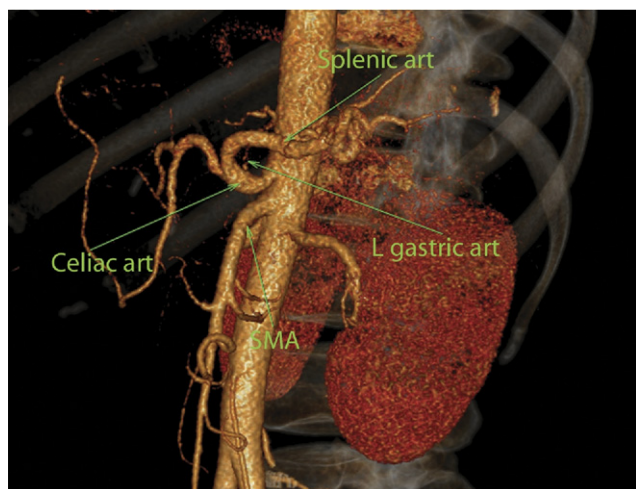
### DISCUSSION

Patients with visceral pseudoaneurysms tend to present with abdominal pain and GI or intra-abdominal bleeding. Eighty-nine percent of patients are symptomatic, and 58% with bleeding are hemodynamically unstable at the time of presentation.<sup>1</sup> The initial diagnosis is commonly made by CT, although small visceral pseudoaneurysms may be missed.<sup>2</sup> Current treatment is by endovascular embolization, with surgery reserved for hemodynamically unstable patients.<sup>2,4,6</sup> Although angiographic embolization is less invasive than surgery, the mortality and complication rates

**Figure 2.** Selective angiograms of the celiac trunk (A) and splenic (B) artery (A.) failing to demonstrate the feeding vessel.



**Figure 3.** A, EUS images. Flow demonstrated by echo Doppler in the pseudoaneurysm. B,C, EUS-guided thrombin injection in the lesion obliterating it completely. D, Echo Doppler confirming the absence of flow after the procedure.



**Figure 4.** CT angiography at 10 months of follow-up shows no recurrence of the pseudoaneurysm.

remain high. Rebleeding is especially common.<sup>2,4,6</sup> Difficulty in reaching and identifying the vascular stalk<sup>2</sup> and the need for general anesthesia in some patients make this technique suboptimal.

EUS-guided thrombin injection bypasses these obstacles. Its close proximity to the lesion allows direct and precise injection of thrombin directly into the lesion. This affords an advantage over percutaneously administered thrombin where multiple layers need to be crossed. The procedure is minimally invasive, can be performed with the patient under conscious sedation, reduces procedure times, and has low complication and mortality rates, resulting in short hospital stays. Possible alternatives for thrombin that have been evaluated in endovascular settings include ethylene vinyl alcohol copolymer,<sup>7</sup> *N*-butyl-2-cyanoacrylate with or without coils, and endovascular coils alone.<sup>2,5</sup> Ethylene vinyl alcohol copolymer mixed with micronized tantalum powder (Onyx) becomes radiopaque, allowing radiological imaging in addition to US, which may be of further benefit in the evaluation of distal escape.

A possible disadvantage of EUS is the complexity of the procedure. Complications when using endovascular techniques that may also apply to EUS therapy are rare but include distal embolisms and immunoreactions.<sup>8</sup> Distal escape when using EUS control can be prevented by carefully guided thrombin administration, and immunoreactions should be avoided by using autologous thrombin.<sup>9</sup> Recanalization after thrombin administered by endovascular techniques has been reported in the literature. In these reports recanalization could be successfully treated by a second thrombin administration.<sup>10,11</sup> This makes careful follow-up mandatory.

This is the third case report in which EUS-guided thrombin injection was successfully used in the management of a visceral pseudoaneurysm.<sup>12,13</sup> Although limited

data still exist, this novel technique is very promising as a first-line diagnostic and therapeutic tool in the management of visceral pseudoaneurysms. Further investigation to determine the usefulness and safety of this technique in open-label, single-arm study designs with safety monitoring or randomized pilot studies should be undertaken.

## DISCLOSURE

*All authors disclosed no financial relationships relevant to this publication.*

## REFERENCES

1. Tessier DJ, Stone WM, Fowl RJ, et al. Clinical features and management of splenic artery pseudoaneurysm: Case series and cumulative review of literature. *J Vasc Surg* 2003;38:969-74.
2. Kirby JM, Vora P, Midia M, et al. Vascular complications of pancreatitis: imaging and intervention. *Cardiovasc Intervent Radiol* 2008;31:957-70.
3. Hsu JT, Yeh CN, Hung CF, et al. Management and outcome of bleeding pseudoaneurysm associated with chronic pancreatitis. *BMC Gastroenterol* 2006;6:3.
4. Balachandra S, Siriwardena A. Systematic appraisal of the management of the major vascular complications of pancreatitis. *Am J Surg* 2005;190:489-95.
5. Tulsyan N, Kashyap VS, Greenberg RK, et al. The endovascular management of visceral artery aneurysms and pseudoaneurysms. *J Vasc Surg* 2007;45:276-83.
6. Udd M, Leppäniemi AK, Bidel S, et al. Treatment of bleeding pseudoaneurysms in patients with chronic pancreatitis. *World J Surg* 2007;31:504-10.
7. Medel R, Crowley RW, Hamilton DK, et al. Endovascular obliteration of an intracranial pseudoaneurysm: the utility of Onyx. *J Neurosurg Pediatr* 2009;4:445-8.
8. Vlachou PA, Karkos CD, Bains S, et al. Percutaneous ultrasound-guided thrombin injection for the treatment of iatrogenic femoral artery pseudoaneurysms. *Eur J Radiol* 2009 Aug 4. [Epub ahead of print]
9. Quarmby JW, Engelke C, Chitolie A, et al. Autologous thrombin for treatment of pseudoaneurysms. *Lancet* 2002;359:946-7.
10. Puri S, Nicholson AA, Breen DJ. Percutaneous thrombin injection for the treatment of a post-pancreatitis pseudoaneurysm. *Eur Radiol* 2003;13:L79-82.
11. Armstrong EM, Edwards A, Kingsnorth AN, et al. Ultrasound guided thrombin injection to treat a pseudoaneurysm secondary to chronic pancreatitis. *Eur J Vasc Endovasc Surg* 2003;26:448-9.
12. Roach H, Roberts SA, Salter R, et al. Endoscopic ultrasound-guided thrombin injection for the treatment of pancreatic pseudoaneurysms. *Endoscopy* 2005;37:876-8.
13. Robinson M, Richards D, Carr N. Treatment of a splenic artery pseudoaneurysm by endoscopic ultrasound-guided thrombin injection. *Cardiovasc Intervent Radiol* 2007;30:515-7.

Hepatology and Gastroenterology Research Unit (R.L., J.dP., M.N., S.W.vdM.), Department of Immunology, Pathology Building Lab 2-75, Basic Medical Sciences Campus, Dr. Savage Road, University of Pretoria, South Africa. Units Intervention Radiology Unit (A.S.), Pretoria-East Interventional GI Unit (S.W.vdM.), Pretoria East Hospital, South Africa.

Reprint requests: Schalk W. van der Merwe, MBChB, PhD, Department of Internal Medicine and Gastroenterology, Pretoria-East Interventional GI Unit, Suite M31, Pretoria East Hospital, Pretoria, South Africa.

Copyright © 2010 by the American Society for Gastrointestinal Endoscopy 0016-5107/\$36.00

doi:10.1016/j.gie.2010.05.019