

Clinical Paper
 Cleft Lip and Palate

Cleft soft palate reconstruction: prospective study on infection and antibiotics

H. P. Mýburgh, K.-W. Bütow

Department of Maxillo- Facial and Oral Surgery, University of Pretoria, South-Africa

H. P. Mýburgh, K.-W. Bütow: Cleft soft palate reconstruction: prospective study on infection and antibiotics. *Int. J. Oral Maxillofac. Surg.* 2009; xxx: xxx-xxx. © 2009 International Association of Oral and Maxillofacial Surgeons. Published by Elsevier Ltd. All rights reserved.

Abstract. The aim of this prospective study was to identify possible pathogenic organisms associated with wound complications in the form of wound infections, wound breakdown and the formation of oro-nasal fistulas. The organisms' resistance profile to antibiotics was also evaluated. This prospective study consisted of the evaluation of the intra-oral microbiological profile of 100 babies with soft palate cleft deformities peri-operatively. A wide spectrum of pathogenic organisms from the upper aero-digestive track was isolated, as well as a group of organisms that originated from the colon/perineum. The latter organisms were mostly associated with postoperative complications. The antibiotic resistance profile showed a high resistance to commonly used antibiotics such as ampicillin, amoxycillin-clavulanic acid, and first- and second-generation cephalosporins. The resistance profile of the organisms needs to be reassessed and appropriate antibiotics must be used in combination with an antimicrobial mouth rinse.

Keywords: cleft soft palate; microbiology; antibiotics; postoperative complications.

Accepted for publication 27 April 2009

The surgeon involved in the reconstruction of cleft facial deformities in the infant, is under pressure to 'normalise' the appearance of the baby as soon as possible. It is important that the correct surgical technique, performed at the correct time, and resulting in the fewest complications, is used⁶.

The success of surgery depends on the surgeon and his/her technique and on the host factors of the baby, especially on the intra-oral organisms harboured by the baby. Certain intra-oral organisms are pathogenic and lead to wound breakdown, the formation of oro-nasal fistulas and to a lesser extent, poor aesthetic results⁵. This is particularly true in the case of a cleft of

the soft palate. The organisms that have been most often identified and associated with wound breakdown and failure of skin grafts, are *Staphylococcus aureus* and the β -haemolytic group of streptococci, and it is well-known that these organisms are also present in the upper aero-digestive passages^{5,6}.

Staph. aureus is usually found in high numbers in the anterior nares of humans. In the patient with cleft facial deformity there is also an increased incidence of this organism intra-orally, due to its direct spread through the anatomical cleft defect⁸.

The aim of this study was to evaluate the spectrum of organisms cultured peri-

operatively, to identify recurrently occurring organisms associated with postoperative wound complications and to evaluate their antibiotic sensitivity and resistance.

A search of the international literature did not reveal a study of this nature had been conducted previously.

Materials and methods

This study consisted of a prospective analysis of 100 babies with cleft facial deformities who received soft palate surgery between 1990 and 2007 in one specific hospital and performed by one specific surgeon. Microbiological cultures were done on days 0, 2, 4 and 6.

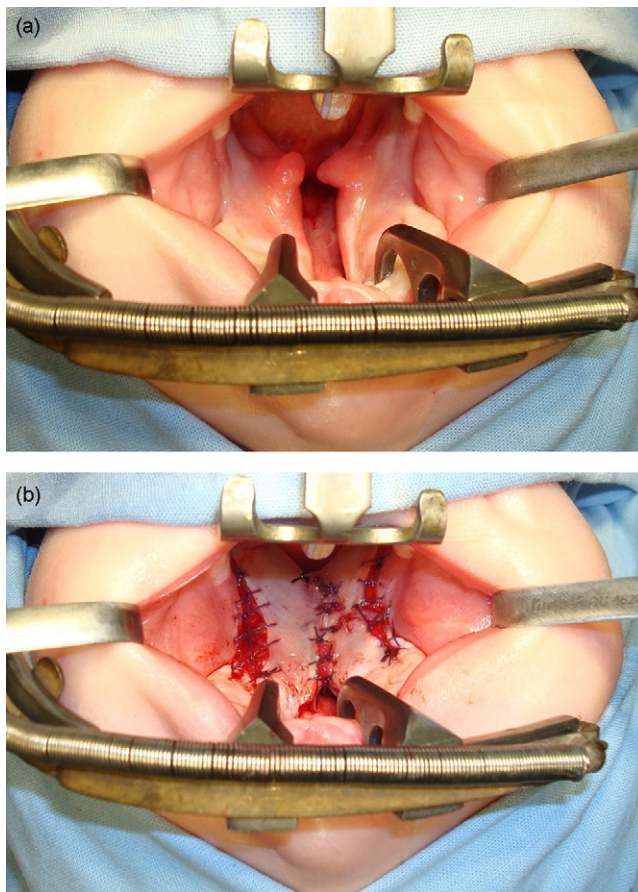


Fig. 1. (a) Preoperative and (b) direct postoperative cleft soft palate.

Data were recorded in the patients' files and included the following biodemographic information: sex, soft palate surgery for an isolated soft palate cleft or for a combination of cleft types, involving the hard palate and/or alveolus and lip; microbiological results for oral swabs taken peri-operatively on days 0, 2, 4 and 6 (including resistance and sensitivity); and postoperative wound complications. Consent was obtained, as a standard procedure, from the parent or guardian during the first consultation. All information was handled confidentially and data were collected according to the protocol.

The surgical technique (Fig. 1) consisted of an intravelar veloplasty as originally described by KRIENS⁷ and modified by BÜTOW^{3,4}. All the babies were admitted to the hospital on the day of surgery and stayed in the same paediatric ward, up to for 7 days postoperatively.

Parents of babies with acrylic feeding devices (jaw-orthognathic suction and drinking plate, BÜTOW³) were instructed to remove these devices 2 weeks prior to surgery to prevent contamination of the oral cavity with organisms¹¹ on the non-shed-

ding surface of these feeding devices. These devices can also cause ulceration and irritation of the oral mucosa, which could interfere with surgery and wound healing.

Swabs for microbiological culture and sensitivity were taken in theatre preoperatively on day 0 and postoperatively on days 2, 4 and 6. The swabs were taken at the soft palate/nasopharynx interface on day 0 and from the reconstructed soft palate on days 2, 4, and 6.

All patients received the same antibiotics as a standard prophylactic dose preoperatively in the theatre and continued postoperatively with a standard antibiotic. The antibiotic was only altered if and when the microbiological and sensitivity results showed resistance to the specific antibiotic being used.

All babies had a nasogastric tube placed in position and postoperative feeds were given through them for the 7 intra-hospital days. Contamination of the surgical wound was minimized as much as possible by the avoidance of oral feeds.

Results

100 babies (52 males and 48 females) underwent soft palate surgery and full microbiological analyses of the swabs taken from their soft palates were made for days 0, 2, 4 and 6. Peri-operatively, 400 microbiological cultures and their sensitivity were analysed. 15 different pathogenic organisms were cultured from the swabs on day 0 (organisms considered as normal flora, found in 38 babies were not include). The pathogenic organisms were: *Aeromonas hydrophila* (1), *Aeromonas sobria* (1), *Candida albicans* (9), *Enterobacter aerogenes* (1), *Enterobacter agglomerans* (3), *Enterobacter cloacae* (5), *Enterococcus faecalis* (1), *Escherichia coli* (9), *Haemophilus influenzae* (8), *Klebsiella oxytoca* (1), *Klebsiella pneumoniae* (18), *Moraxella catarrhalis* (6), *Serratia marcescens* (4), *Staph. aureus* (22) and *Streptococcus pneumoniae* (7) (Fig. 2).

13 different pathogenic organisms were cultured from the swabs taken on day 2. (40 babies presented with normal flora). The organisms were: *Argobacterium radiobacter* (1), *C. albicans* (28), *Enterobacter aerogenes* (1), *Enterobacter*

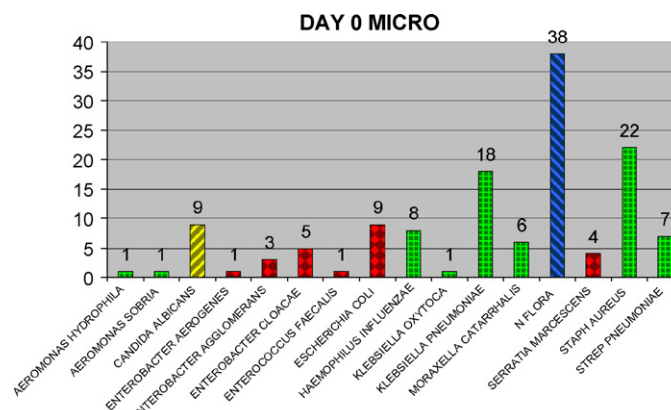


Fig. 2. Day 0 microbiological analysis.

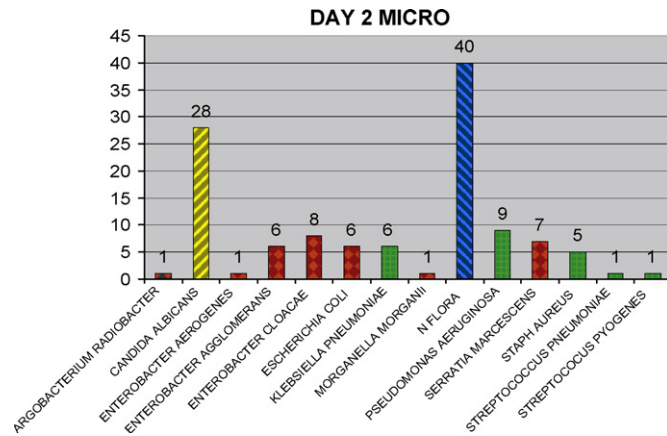


Fig. 3. Day 2 microbiological analysis.

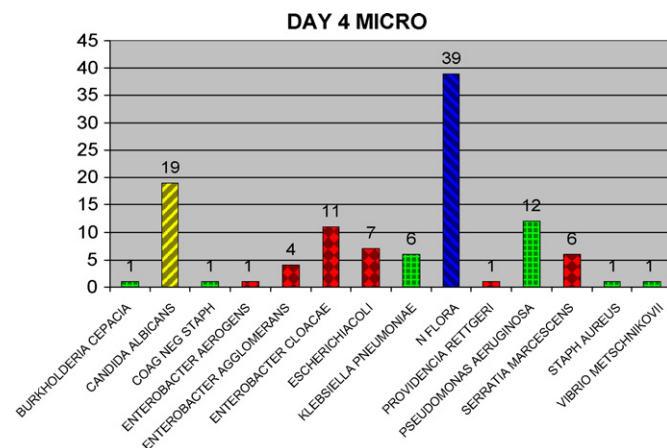


Fig. 4. Day 4 microbiological analysis.

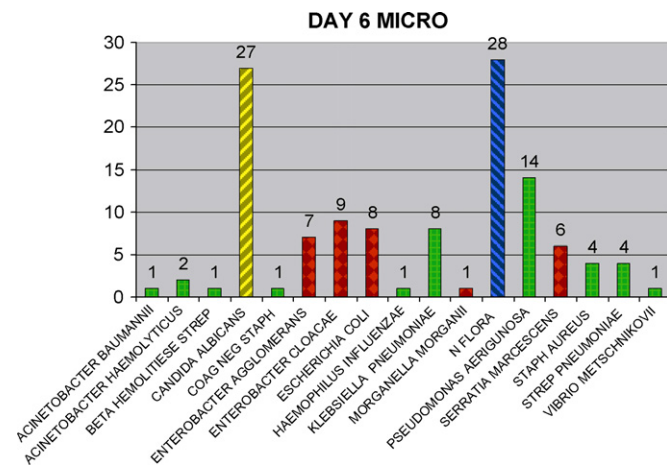


Fig. 5. Day 6 microbiological analysis.

agglomerans (6), *Enterobacter cloacae* (8), *E. coli* (6), *K. pneumoniae* (6), *Morganella morganii* (1), *Pseudomonas aeruginosa* (9), *Serratia marcescens* (7), *Staph. aureus* (5) and *Streptococcus pyogenes* (1) (Fig. 3).

The swabs taken on day 4 revealed a similar spectrum of organisms as the previous two days (normal flora 39 cases): *Burkholderia cepacia* (1), *C. albicans* (19), coagulase negative staphylococcus (1), *Enterobacter aerogens* (1), *Entero-*

bacter agglomerans (4), *Enterobacter cloacae* (11), *E. coli* (7), *K. pneumoniae* (6), *Providencia rettgeri* (1), *Pseudomonas aeruginosa* (12), *Serratia marcescens* (6), *Staph. aureus* (1) and *Vibrio metschnikovii* (1) (Fig. 4).

The swabs from day 6 indicated a slight difference in the spectrum of organisms compared with the previous three recordings. The microbiological analyses were (normal flora in 28 cases): *Acinobacter baumannii* (1), *Acinetobacter haemolyticus* (2), β -haemolytic streptococcus (1), *C. albicans* (27), coagulase negative staphylococcus (1), *Enterobacter agglomerans* (7), *Enterobacter cloacae* (9), *E. coli* (8), *Haemophilus influenzae* (1), *K. pneumoniae* (8), *Morganella morganii* (1), *Pseudomonas aeruginosa* (14), *Serratia marcescens* (6), *Staph. aureus* (4), *Streptococcus pneumoniae* (4), and *Vibrio metschnikovii* (1) (Fig. 5).

Postoperative complications were reported in 9 of the 100 babies. These consisted of five oro-nasal fistulas and four patients with a much lesser degree of wound breakdown postoperatively.

The following organisms were associated with these complications: two of the patients who developed oro-nasal fistulas had normal flora cultured from the swabs taken on days 0, 2, 4 and 6. The three other patients with oro-nasal fistulas had pathogenic organisms cultured: *Enterobacter agglomerans*, *Enterobacter cloacae*, *Haemophilus influenzae*, and *Serratia marcescens*.

Three of the four patients who developed partial wound breakdown had *Staph. aureus* cultured from the swabs taken on day 0 (preoperatively). The other associated organisms, which appeared on days 2 or 4 were *Burkholderia cepacia*, *Enterobacter agglomerans*, *Enterobacter cloacae*, *K. pneumoniae*, and *Serratia marcescens*.

Micro-organisms showed resistance to the following antibiotics (ranked from highest to lowest in frequency): ampicillin 62%, first-generation cephalosporins 50%, amoxicillin-clavulanic acid 45%, second-generation cephalosporins 29%, piperacillin 29%, cotrimoxazole 20%, third-generation cephalosporins 11%, tetracycline 11%, tobramycin 10%, macrolides 5%, gentamycin 4%, clindamycin 4%, amikacin 2%, fourth-generation cephalosporins 2%, levofloxacin 1%, aztreonam 0.4%, carbanemms 0.4%, cloxacillin 0.4% (Fig. 6).

Discussion

A study of this nature has not been undertaken before, and the reason for identify-

4 Mýburgh, and K.W. Bütow

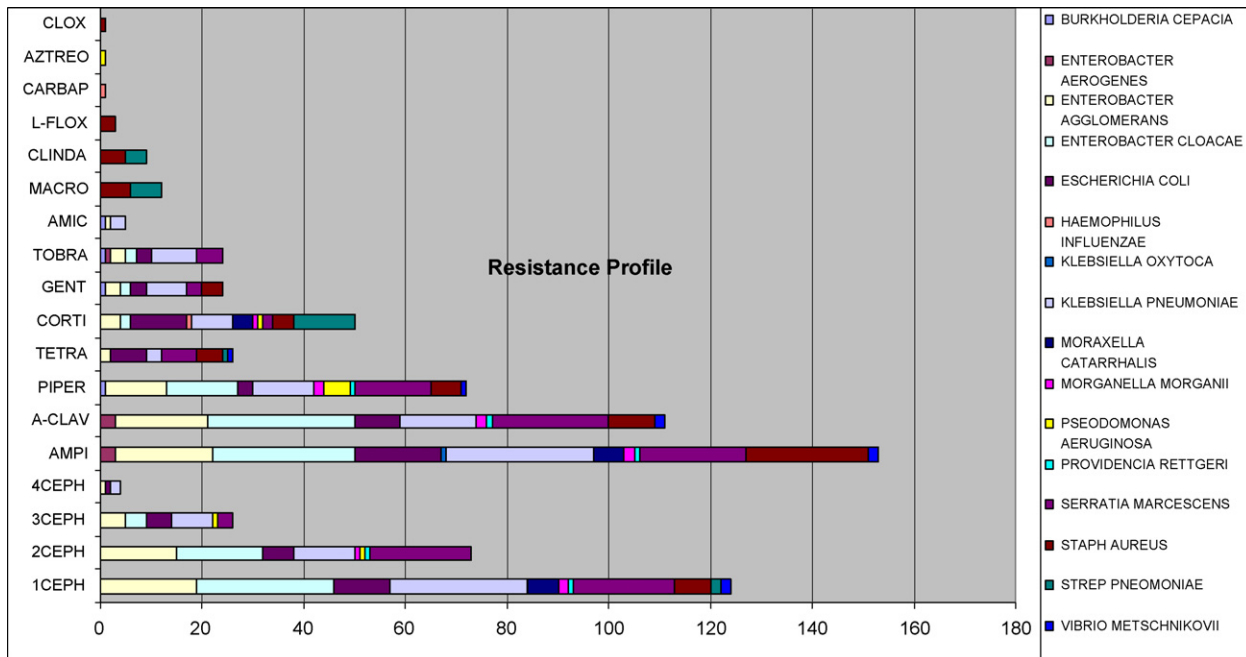

Fig. 6. Resistance profile to antibiotics.

ing pathogenic intra-oral organisms in babies with cleft facial deformities is that this information may be used to prevent postoperative complications. The additional information gained about the resistance profile of the organisms cultured may be used to supplement the existing knowledge on antibiotic resistance.¹

In the spectrum of normal intra-oral organisms, taken on all the specific days, *C. albicans* was present in each culture. It could be argued that *Candida* found intra-orally in babies may be grouped with the normal flora, yet most paediatricians treat *Candida* as an infection. Most of the remaining pathogenic organisms were found in the upper aero-digestive system, and were consistent in infections in that area.

A number of organisms from the colon/urinary tract were also observed. The origin of these organisms in the oral cavity can only be surmised, but the study group consisted of babies wearing nappies. Firstly, the nasogastric tube, kept in place for the 7 days of hospital care for feeding purposes, might cause regurgitation of gastrointestinal content along the nasogastric tube, thereby contaminating the oral cavity². The lower esophageal valve in infants is underdeveloped and these patients have a high incidence of reflux. Secondly, organisms contaminating the perineum of babies could be the source of cross-contamination by the parents and/or carers who change the nappies of these children preoperatively and during the healing phase. Auto-con-

tamination by the babies themselves preoperatively, is also a possibility, since children of this age are prone to placing their hands in their mouths.

Five of the nine patients who had postoperative complications, developed oronasal fistulas and of these, two were formed in the presence of normal flora. This complication might follow after excessive tension has been exerted on the mucosa, after reconstruction of an extraordinary wide cleft as seen in these cases with median facial dysgenesis⁹.

Four patients, certified as clinically healthy preoperatively, developed breakdown of their wounds. Three of these four babies had swabs from which *Staph. aureus* was cultured on day 0 (preoperatively). The swabs taken postoperatively, indicated that the organisms had changed to those associated with the colon (Fig. 7).

There was a very high resistance profile to antibiotics, but these patients were hospitalised for the days on which swabs were taken. If swabs had been taken on days 2, 4 and 6 postoperatively on babies who were

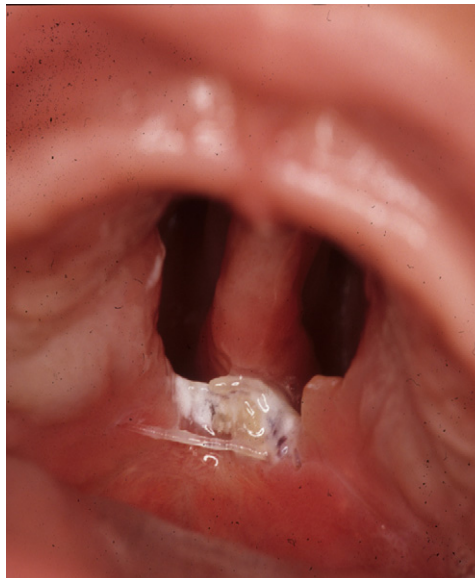


Fig. 7. Partial infection with wound breakdown.

not hospitalised, more community acquired organisms might have been cultured, which might have shown a decreased resistance to antibiotics.

In this study, the highest incidence of resistance to antibiotics was for ampicillin, first-generation cephalosporins, amoxicillin-clavulanic acid, second-generation cephalosporins, piperacillin, cotrimoxazole, followed by a lesser incidence of resistance to the remainder of the tested antibiotics. This resistance profile correlates with the spectrum of antibiotics commonly in use.

In conclusion, a wide spectrum of organisms was cultured from the oral swabs taken peri-operatively in cases where reconstruction of the soft palate cleft was involved. The organisms showed resistance to certain antibiotics. Some postoperative complications were associated with specific perineal organisms.

It is recommended that an attempt should be made to prevent the contamination of the oral cavity with organisms from the perineum by means of strict hand-washing protocols for parents and carers. Regarding the possibility of contamination through the nasogastric tube, removing this device might be considered but how would feeding be accomplished without contaminating the oral wound with food? Total parenteral feeding is too expensive and has associated complications.¹⁰ If the nasogastric tube were to be retained a chlorhexidine oral spray, used intermittently to keep the wound clean,

might suffice. A baby cannot gargle the oral rinse without swallowing it, so the aerosol oral rinse could be applied directly to the palate. The baby will still swallow part of this solution.

The question remains whether infants scheduled for palatal surgery should have cultures taken 4–7 days preoperatively (the incubation period for cultures is on average 3 days), and if pathogenic organisms are cultured, should the surgery be rescheduled? The use of prophylactic antibiotic treatment postoperatively should be kept to a minimum, in the light of the organisms' increased resistance to antibiotics.

References

1. ARIEF EM, MOHAHAMED Z, IDRIS FM. Study of Viridans Streptococci and Staphylococcus species in cleft lip and palate patients before and after surgery. *Cleft Palate-Craniofac J* 2005; **42**: 277–279.
2. BOKHOUT B, VAN LOVEREN C, HOFMAN FXWM, BUIJS JF, VAN LIMBEEK J, PRAHL-ANDERSON B. Prevalence of Streptococcus mutans and Lactobacilli in 18 month old children with cleft lip and/or palate. *Cleft Palate-Craniofac J* 1996; **33**: 424–428.
3. BÜTOW K-W. Primary surgical repair of palate. *Treatment of Facial Cleft Deformities. An illustrated guide.* St. Louis/Tokyo: IshiyakuEuroAmerica, Inc. Publishers 1995: 21–23.
4. BÜTOW K-W, JACOBS FJ. Intravelar veloplasty: Surgical modification according to anatomical defect. *Int J Oral Maxillofac Surg* 1991; **20**: 296–301.
5. CHUO CB, TIMMONS MJ. The bacteriology of children before primary cleft lip and palate surgery. *Cleft Palate-Craniofac J* 2005; **42**: 272–276.
6. JOUSIMIES-SOMER H, GRENMAN R, RINTALA A. Bacteriological investigation of secretory otitis media in children with cleft palate. *Scand J Plast Reconstr Surg* 1986; **20**: 297–302.
7. KRIENS OB. An anatomical approach to veloplasty. *Plast Reconstr Surg* 1969; **43**: 29–41.
8. MERCER NSG. Letter: The use of preoperative swabs in cleft lip and palate repair. *Br J Plast Surg* 2002; **55**: 533–541.
9. NOORDHOFF MS, CHENG WS. Median facial dysgenesis in cleft lip and palate. *Ann Plast Surg* 1982; **8**: 83–92.
10. PINGELTON SK. Enteral nutrition as a risk factor for nosocomial pneumonia. *Europ J Clin Microbiology Infec Dis* 1989; **1**: 51–55.
11. VAN LOVEREN C, BUIJS JF, BOKHOUT B, PRAHL-ANDERSON. TEN CATE JM. Incidence of Mutans Streptococci and Lactobacilli in oral cleft children wearing acrylic plates from shortly after birth. *Oral Microbiol Immunol* 1998; **13**: 286–291.

Address:

Prof. Kurt-W Bütow

PO Box 1266

Pretoria 0001

South Africa

Tel.: +27 12 3192232

fax: +27 12 3192172

E-mail: kwbutow@medic.up.ac.za