

# The airway in face, head and neck injury

**Milner A**

Department of Anaesthesia, Pretoria Academic Hospital, Pretoria

**Correspondence to:** Prof Analee Milner, e-mail: anamil@iafrica.com

*SAJAA 2008; 14(1): 52-57*

## INTRODUCTION

Penetrating neck injury was first described 5 000 years ago on a piece of papyrus. Hugh Munro closed a longitudinal tracheal laceration in 1792 by using external straps. Horizontal lesions were sutured over a stent and the patient's neck remained in the flexed position while the wound was allowed to heal. The first successful management of a penetrating vascular injury in the neck was achieved in 1952 (with no resultant stroke or hemiplegia), and the first bronchial laceration was repaired in 1945. Current mortality rates for penetrating neck injuries are quoted as ~2 to 6%. In the wars of the twentieth century, ending with the Vietnam War, the incidence was 7 to 15%. Mortality rates from the massive aspiration of blood, related cervicothoracic vascular injuries and other injured organs, can be as high as 15 to 30%. The highest mortality occurs with gunshot injuries (35%), followed by blunt trauma (25%) and stab wounds of the upper airway (22%).

## ANATOMY OF THE AIRWAY

The airway stretches from the lips and nose via the oropharynx down to the larynx, the trachea and finally the main bronchi. Any pathology to these structures, as well as to the surrounding structures, has the potential to obstruct the airway. The anatomy of the neck is unique, with multiple vital structures concentrated in a small anatomic area, yet generally unprotected by bone or dense muscular coverings. The anterior triangle contains all the vital structures of the neck. Its contents are as follows:

- Respiratory: larynx and trachea
- Digestive: pharynx and oesophagus
- Vascular: jugular vein and carotid artery
- Neurological: cranial nerves and cervical nerves
- Endocrine: thyroid and parathyroid glands

The anterior triangle is divided into three zones, defined by horizontal planes (See Figure 1)

- Zone I Clavicle to the cricoid cartilage: injuries here have the highest mortality.
- Zone II Cricoid cartilage to the angle of the jaw: most common zone to be injured.
- Zone III Angle of the mandible to the base of the skull: surgical exposure is very difficult in this zone.

Different zones of entry mandate different protocols for evaluation and management. In this respect, facial injuries fall under zone 3.

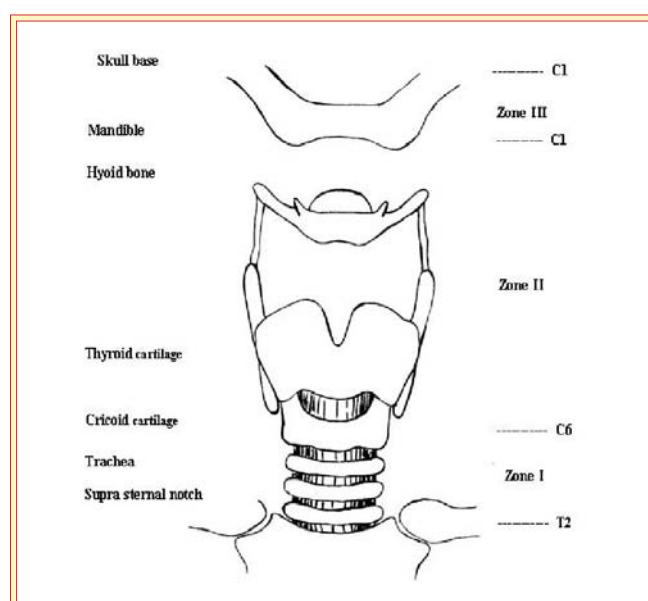
Facial injuries can be classified as follows ( Figure 2):

- Zone a: Midface injuries: superior orbital rim superiorly to the oral commissure inferiorly, and to the external auditory meatus laterally.
- Zone b: Mandible injuries<sup>1</sup>
- Zone c: A combination of a and b

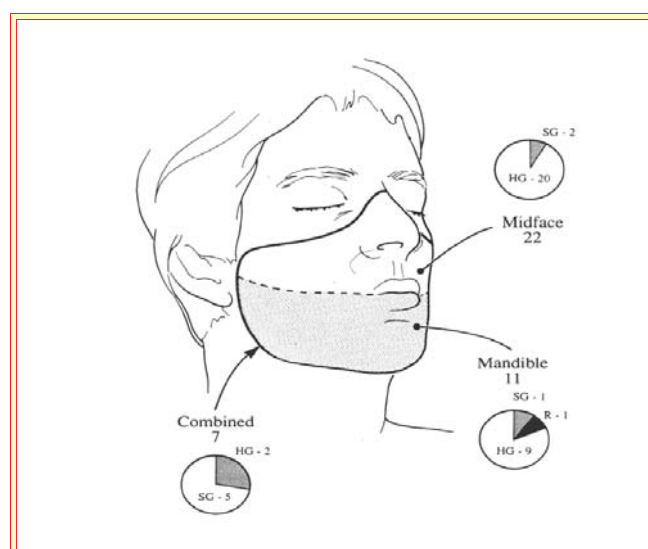The laryngotracheal junction (at the level of C6) is the most important anatomical area. The cricoid cartilage joins the trachea, the pharynx joins the oesophagus and in addition the recurrent laryngeal nerve runs between the trachea and oesophagus to enter the larynx through the cricothyroid membrane. The connective tissue in this area is relatively weak.

The recurrent laryngeal nerve is the motor nerve to the intrinsic muscles of the larynx and sensation below the vocal cords. It

**Figure 1:** Zones of the neck



**Figure 2:** Zones of the face



penetrates between the cricoid and thyroid cartilages, and is frequently damaged in patients with laryngeal injury.

## Classification of airway trauma

The overall incidence of airway trauma is rare (0,5%). The exact incidence is, however, difficult to determine, as the more serious

injuries are usually fatal and might only be detected on autopsy. Factors that contribute to the low survival and inability to detect injuries to the larynx and trachea are:

- Mechanism of injury
- Injury site
- Time until diagnosis
- Additional injuries
- Interventions undertaken, i.e. endotracheal intubation with undiagnosed laryngotracheal injury
- Age of patient

Airway trauma can be broadly classified into external airway trauma and internal airway trauma (See Frame 1).

#### Frame 1: Classification of airway trauma

<p><b>External</b></p> <p><b>Blunt injuries</b></p> <ul style="list-style-type: none"> <li>- Assault</li> <li>- MVA, safety belts and airbags</li> <li>- Sport</li> <li>- Strangulation and hanging (results in thyroid and hyoid fractures).</li> </ul> <p><b>Sharp penetrating injuries</b></p> <ul style="list-style-type: none"> <li>- Stab wounds</li> <li>- Gunshots – high and low velocity</li> <li>- Foreign objects, e.g. from lawn mowers</li> </ul>
<p><b>Internal</b></p> <p><b>a. Iatrogenic injuries</b></p> <ul style="list-style-type: none"> <li>• Endotracheal intubation and laryngeal mask</li> <li>• Diagnostic procedures</li> <li>• Surgical intervention/laser: thyroidectomy and recurrent laryngeal nerve</li> <li>• Percutaneous tracheostomy or tracheostomy</li> <li>• Penetrating trauma, e.g. from intravascular lines</li> </ul> <p><b>b. Burns, inhalation of noxious or hot gas fumes</b></p> <p><b>c. Aspiration of foreign bodies</b></p> <p><b>d. Reflux</b></p>

#### Incidence

Blunt injury to the lower airways is uncommon (0,4%) due to the protection of the sternum and mandible anteriorly, the spinal column posteriorly, and the elasticity of the upper airway itself. In North America, blunt injury appears to be the most common cause of airway trauma. (See Table I) Airway trauma accounts for less than 1% of their hospital admissions. These figures would probably not correlate with those in South Africa.

**Table I:** American figures on airway trauma

Structures affected by blunt trauma in descending order of prevalence	
Cervical trachea	45%
Larynx above the cricoid	35%
Cricoid cartilage	15
Other	5%
Incidence in blunt and penetrating trauma	
Thyroid cartilage	47%
Arytenoid cartilage	24%
Cricoid cartilage	22%

*Note:* The mortality from such injuries appears to be 20 to 25%, and the incidence appears to be increasing over the past 30 years

#### Mechanism of injury

Most injuries are the result of direct blows, severe flexion/extension injuries, and crush injuries to the chest. (See Frame 2)

#### Frame 2: Mechanisms of blunt external injuries to the airway

##### Direct blows:

- More energy is transferred over a broader area during blunt trauma. As a result injury to the airway may occur despite no closely associated injuries. Direct blows can be categorised as high-energy (e.g. auto-pedestrian) and low-energy transfer (blunt assault, bicycle accidents)
- May cause injury to the cartilage of the larynx
- Blunt injury to the anterior cervical structures is typically the result of a rapid deceleration, neck extension and inertial impact of the steering column or dashboard during a motor vehicle accident (MVA)
- Laryngeal impact between the vertebral bodies and an anterior object results in high-energy shearing of the laryngeal ligament or arytenoid cartilages. This can result in laryngeal crush injuries or laryngotracheal separation (see classification in Figure 4)
- Interruption of venous and lymphatic drainage from complete laryngotracheal separation can result in significant airway compromise, secondary to stasis and oedema
- Damage to the cervical spine occurs in 10 to 50% of cases. Always assume that such an injury is present, and avoid flexion/extension of the neck until it has been excluded
- Many of these patients may have associated head injuries or maxillofacial injuries
- Cricoid cartilage fractures are associated with a high incidence of recurrent laryngeal nerve damage
- Damage to the oesophagus should also be ascertained
- Clinical features of tracheobronchial injury include:
  - haemoptysis
  - dyspnoea and air leak
  - 10% of patients have no clinical or radiological signs

##### Severe flexion/extension injuries:

- These are commonly associated with tracheal tears and laryngotracheal separation, and also with paramedian vertical fracture of larynx and trachea.
- Signs: stridor, subcutaneous emphysema, haemoptysis, haematoma, ecchymosis, laryngeal tenderness, flattened thyroid dashboard contour, neck pain and crepitus over the laryngeal shield
- Hyperextension usually results from acute deceleration in an unrestrained front seat driver – “the padded dashboard syndrome”

##### Crush injuries to the chest:

Anterior-posterior crush injuries result in a rapid rise in intrathoracic pressure against a closed glottis, causing tracheal and bronchial disruption. The trachea tears as it is crushed between the manubrium and vertebral column. Air cannot escape as the glottis closes reflexively. There is a marked increase in intraluminal pressure. La Place's Law states that the largest increase in wall tension occurs in the larger airways. Vertical tears in the membranous portion of the trachea or bronchi occur, usually 2,5 cm from the trachea. The right main bronchus is affected more often because the left bronchus is protected by the aorta.<sup>11</sup> Causes of these injuries include:

- MVAs where the patient is pinned between the car seat and the steering wheel or ejected and pinned beneath the wreckage.
- Slippage of car jacks.
- Construction site accidents.

#### LARYNGOTRACHEAL AND LARYNGEAL INJURIES

The classification and management are summarised in table II. The Legacy Emanuel Hospital and Health Centre laryngeal injury classification is commonly used, and is summarised in table III.

#### EXTERNAL PENETRATING AIRWAY TRAUMA

##### Incidence

- In the overseas literature, these injuries appear to be relatively uncommon (4,5%)? (fewer than three cases per year per reported centre)
- Incidence usually increases with an upsurge in crime

**Table II:** Classification and management of laryngotracheal injuries

	Classification	Management
<b>Group 1</b>	Minor endolaryngeal haematoma or laceration without detectable fracture followed by CT scan. Close observation	Indirect laryngoscopy (IL) or flexible nasopharyngoscopy (FN) in casualty, with repeat IL and FN if necessary
<b>Group 2</b>	Oedema, haematoma, minor mucosal disruption without exposed cartilage, non-displaced fractures noted on CT scan	IL or FN in casualty, followed by immediate tracheostomy. Direct laryngoscopy and oesophagoscopy. CT scan of larynx
<b>Group 3</b>	Massive oedema, mucosal tears, exposed cartilage, cord immobility, displaced fractures	IL or FN in casualty. Immediate tracheostomy. Direct laryngoscopy and oesophagoscopy. CT scan of larynx
<b>Group 4</b>	Same as group 3, with more than two fracture lines, or massive trauma to laryngeal mucosa	Same as group 3
<b>Group 5</b>	Complete laryngotracheal separation	Immediate tracheostomy, direct laryngoscopy and oesophagoscopy followed by exploration

**Table III:** LEHHC\* laryngeal injury classification

	Clinical presentation	Diagnostic findings	Management
<b>Stage 1</b>	<ul style="list-style-type: none"> <li>Minor airway symptoms ~ voice changes</li> </ul>	<ul style="list-style-type: none"> <li>Minor lacerations</li> <li>Small lacerations</li> <li>No detectable fractures</li> </ul>	<ul style="list-style-type: none"> <li>Observation</li> <li>Humidified air</li> <li>Head of bed elevation</li> </ul>
<b>Stage 2**</b>	<ul style="list-style-type: none"> <li>Airway compromise, ~ voice changes</li> <li>Subcutaneous emphysema</li> </ul>	<ul style="list-style-type: none"> <li>Oedema/haematoma</li> <li>Nondisplaced fracture</li> <li>Minor mucosal disruption</li> <li>No cartilage exposure</li> </ul>	<ul style="list-style-type: none"> <li>Direct laryngoscopy</li> <li>+/- ORIF</li> </ul>
<b>Stage 3**</b>	<ul style="list-style-type: none"> <li>Airway compromise</li> <li>Palpable laryngeal fracture</li> <li>Subcutaneous emphysema</li> <li>Voice changes</li> </ul>	<ul style="list-style-type: none"> <li>Massive oedema</li> <li>Mucosal tears</li> <li>Class 2 side effects</li> <li>Exposed cartilage</li> <li>Vocal cord immobility</li> </ul>	<ul style="list-style-type: none"> <li>Direct laryngoscopy</li> <li>Exploration/ORIF</li> </ul>
<b>Stage 4**</b>	<ul style="list-style-type: none"> <li>Airway compromise</li> <li>Palpable laryngeal fracture</li> <li>Subcutaneous emphysema</li> <li>Voice changes</li> </ul>	<ul style="list-style-type: none"> <li>Massive oedema</li> <li>Mucosal tears</li> <li>Multiple displaced fractures</li> <li>Skeletal instability</li> <li>Exposed cartilage</li> <li>Vocal cord immobility</li> </ul>	<ul style="list-style-type: none"> <li>Direct laryngoscopy</li> <li>Exploration/ORIF</li> <li>Consider stent</li> </ul>

\* LEHHC = Legacy Emanuel Hospital and Health Centre (Portland, Oregon)

\*\* Stages 2–4 to receive immediate awake tracheostomy if airway has not already been secured in the field

### Mechanism of injury

#### a. Gunshot wounds

In the USA, one in four deaths in the age group 15 to 24 years is related to firearms. High-velocity wounds are associated with extensive tissue loss and high morbidity, while low-velocity bullets tend to cause less damage to the surrounding tissue. Kinetic energy (KE) can be calculated as follows:

$$KE = MV^2$$

V = velocity, (therefore the higher the velocity the higher the kinetic energy)

M = mass

The degree of airway management required does not correlate with the entrance wound or type of weapon used. Shotgun injuries are divided into close range (7 m) (= high velocity) and long range. Yaw from bullet is important, as it causes tumbling

of the bullet as it penetrates the tissue. Cavitation causes perpendicular shock waves sent out by the missile. This may cause compression of the surrounding tissues. The wounds created may vary from superficial skin damage to transcervical injuries with extensive damage such as blindness, mandibular malunion, cardiovascular accident, quadriplegia, upper extremity weakness, Brown-Sequard syndrome, facial nerve weakness and oral nasal fistula.

Transcervical gunshots cause:

- Vascular injuries in 48% of cases – mostly requires airway management
- Spinal cord injury in 24% of cases
- Mandible and maxillary fractures in 9% of cases. None appear to be Le Fort type fractures
- Laryngeal and pharyngeal injuries in 2% of cases

#### b. Stab wounds

- These wounds are inflicted by knives and other instruments such as screwdrivers

- Knife wounds cause minimal damage to the areas surrounding the path of the knife
- Blunt instruments tear, and the repair is more difficult
- All instruments should always be considered to be infected
- Bullingham et al. described a patient impaled on a spike of a railing who was intubated fibre-optically
- Joly et al. described a feathered arrow that penetrated the cranium and face. Fibre-optic intubation was utilised
- Stab wounds most commonly injure the trachea. The larynx is injured in approximately 1/3 of cases and the cervical trachea in 2/3
- Death is usually associated with a vascular injury

#### *Associated injuries*

- Oesophageal damage in 25% of cases
- Vascular damage
- Thoracic injuries

#### **c. Other associated upper airway pathology**

Oedema fluid in suprasubglottic areas decreases the circumferential diameter of the airway. It occurs six hours after the trauma. Subcutaneous emphysema. Air dissecting the submucosal space or the soft tissues (subcutaneous emphysema). Vascular haematoma may be aggravated by straining, coughing and speaking. Older patients have calcified cartilages and are more prone to trauma. Adult laryngeal structures are rigid, while the paediatric larynx is pliable. With its loose attachments to the underlying structures, the lower fracture risk is replaced by increased risk of soft tissue injury and massive oedema.

**Compounding the difficulty to evaluate and manage penetrating neck wounds is the complicated anatomy of the area, in which a dense concentration of vital vascular, aerodigestive and central nervous system structures are located within a very small space.**

#### **INTERNAL IATROGENIC AIRWAY INJURIES**

The following are causes of tracheal trauma:

- Endotracheal tube and tracheostomy
- Cicatrix (scarring) of the subglottic area, with resultant stenosis especially prevalent in the paediatric population, where the subglottis is the narrowest portion of the airway
- Tracheo-oesophageal fistulas
- Tracheal erosions
- Trachea-innominate artery fistula
- Bronchial rupture

#### **Trauma caused by endotracheal intubation**

The overall incidence of endotracheal intubation trauma is thought to be 0.1%. The most common indication for tracheal resection and reconstruction is damage caused by an endotracheal intubation. Although low-pressure, high-volume cuffs have been around for 20 years, the incidence of tracheal stenosis from high pressures in cuffs has not disappeared. Note that injury may occur even after a brief period of intubation. The perfusion pressure in the trachea dictates how long the tracheal mucosa can tolerate excessive pressure. After inhalational burns, cuff pressures are critical to ensure that no tracheal damage occurs. A study at the Massachusetts General Hospital looked at 208 patients in this category:

- 185 had tracheostomy injuries, 50% were from the cuff
- 23 had injuries from endotracheal intubation, and 22 of these were from overinflation of the cuff, i.e. 95%

The endotracheal tube is more likely to move, and the cuff tends to be inflated all the time, whereas the tracheostomy is less likely to move and the cuff usually is uninflated.

#### *Mechanisms of injury*

- The endotracheal tube leads to abrasions which lead to erosion of the tracheal lining. As the patient moves, shearing of the lining from either the cuff or the endotracheal tube itself, leads to disruption of the mucosal membrane, allowing

bacterial colonisation. Granulation tissue formation, perichondritis or cicatricial scarring is the next step. Perichondritis may lead to tracheal malacia.

- The above pathology can occur any time, from after one day to several months.
- Possible factors in the development of stenosis include:
  - a) Traumatic intubation
  - b) Patient susceptibility to infection secondary to immune or diabetic status
  - c) Type of sedation used during intubation
  - d) Length of intubation
  - e) Size of endotracheal tube

- The most common site for stenosis is the subglottic area or posterior laryngeal area
- The exact role of the gastro-oesophageal reflux is unknown, but it presumed to be significant. Acid or bile accumulation bathing the posterior glottis or subglottis aggravates mucosal injury by stimulating inflammation and predisposing to bacterial colonisation
- Tracheostomy may lead to granulation tissue formation and scarring and tracheomalacia at the stomal site or the distal tip of the tracheostomy tube

#### **Injuries caused by laryngeal mask airway placement**

Cuff pressures in laryngeal masks can increase when N<sub>2</sub>O is used over a three-hour period. Lingual nerve, hypoglossal nerve and recurrent laryngeal nerve injury have been reported. Displacement of arytenoid cartilage has also been described. There is also a report of an inadvertent pharyngeal tear after an easy LMA insertion, causing aspiration of a large amount of blood. It became extremely difficult to ventilate the patient until she coughed out a blood cast of her entire tracheobronchial tree. The presence of blood in the pharynx after LMA insertion is not uncommon. The classic LMA also does not protect against lower airway soiling. This usually happens when the mask becomes displaced. The LMA causes more sore throat and dysphagia, but less jaw pain than the face mask.

#### **Airway injury during anaesthesia**

Airways may be traumatised during routine intubations. The common injuries that have reached the ASA closed claims database are as follows:

- Pharyngoesophageal perforation
  - Early diagnosis is difficult (approximately 23% die)
  - Usually due to difficult intubation: obesity, cervical arthritis, improper head positioning, poor muscle relaxation and haste
  - Cricoid pressure, long-term indwelling nasogastric catheter
  - Rigid or flexible stylet (even if the tip was not exposed)
  - Older than 60 years
  - Female gender
  - Emergency intubation
  - Intubation by inexperienced personnel
- Laryngeal and tracheal injuries
  - Abrasion of mucosa by movement of the endotracheal tube
  - Pressure on the posterior laryngeal mucosa
  - Especially tracheal perforation
- Temporomandibular joint injuries
  - Female, young to middle-aged
  - May be due to underlying temporomandibular joint pathology

#### **INTERNAL BURN INJURIES**

These injuries have also been seen with the inhalation of hot steam, gas or other noxious fumes of incomplete combustion. Injuries occur primarily to the larynx (supraglottis, glottis and upper cervical trachea), and seldom lower. Twenty per cent of patients admitted to regional burn centres have inhalation injury. This has adverse effects on both gas exchange and haemodynamics. The diagnosis depends on history and examination and the anaesthetist should pay attention to the following:

- Presence of carbonated debris in mouth or sputum, singed nasal hairs and facial burns.
- CXR and bronchoscopy are gold standards.
- Radioisotope imaging, as well as tracheobronchial lavage and cytology have been used to diagnose.

### Mechanisms of injury

In patients subjected to direct burning of the upper airway with resultant mucosal oedema and airway obstruction, the swelling is exacerbated by the diffuse capillary leak associated with a cutaneous burn. The major airways are denuded of their normal mucosal layer, and the ciliary transport mechanism is thereby impaired. The small airways become obstructed by debris and accumulated secretions. Alveolar flooding occurs due to disruption of alveolar epithelium from toxic products. Clinically important problems that predictably occur include:

- Loss of airway patency due to mucosal oedema
- Bronchospasm
- Intrapulmonary shunting from small airway occlusion
- Diminished compliance, secondary to alveolar flooding and collapse
- Pneumonia secondary to loss of ciliary clearance
- Respiratory failure secondary to a combination of the above factors
- Bronchiectasis and variable degrees of obstructive and restrictive defects
- Necrosis and scar formation occur and deform the affected area
- Early intubation and tracheostomy are essential in most cases due to the development of laryngeal oedema. (Remember the intubation and/or tracheostomy can produce additional injury)
- Heliox can be used in children in an attempt to avoid intubation. However, subsequent intubation in those who fail on heliox may be even more difficult. Therefore it is probably wiser to carefully intubate a child with progressive stridor.

### DIAGNOSIS OF AIRWAY TRAUMA

#### Physical findings

Airway trauma may present with a wide spectrum of signs and symptomatology. It may have no visible sign of trauma (25% have no physical evidence and manifest 24 to 48 hours later). It is, therefore, imperative to take the following into consideration (Table IV):

- Type of accident
- Signs of local contusion, subcutaneous emphysema
- Hoarseness, inspiratory stridor, respiratory distress
- Haemoptysis
- Pneumothorax

**Table IV:** Physical signs seen in patients with trauma to the head, neck and chest

<b>Respiratory</b>	<ul style="list-style-type: none"> <li>• Stridor</li> <li>• Airway obstruction</li> </ul>
<b>Digestive</b>	<ul style="list-style-type: none"> <li>• Dysphagia</li> <li>• Haematemesis</li> <li>• Subcutaneous emphysema</li> </ul>
<b>Vascular</b>	<ul style="list-style-type: none"> <li>• Shock</li> <li>• Expanding haematomas</li> <li>• External haemorrhage</li> <li>• Decreased carotid pulse</li> </ul>
<b>Neurological</b>	<ul style="list-style-type: none"> <li>• Lateralising neurological deficit</li> <li>• Altered state of consciousness</li> <li>• Brachial plexus injury</li> </ul>

Furthermore, airway trauma may have gross signs of tissue destruction. Thus surgical emphysema and oesophageal perforation that is missed, may lead to mediastinitis and death.

### Radiological assessment

This assessment should be sufficient to diagnose 60% of patients with cervical airway trauma as well as fractures of the cervical spine. Cervical mediastinal emphysema (airway disruption), disruption of airway contours, displacement of endotracheal tube. Persistent pneumothorax, despite properly placed intercostal drains should alert one to airway rupture. Subtle trauma to the oesophagus can also be diagnosed radiologically. However, definitive airway management should not be delayed excessively, as an obstructed airway may occur during this time. Also, patients who are dyspnoeic may be unable to lie down. Thus prolonged radiological investigations will not be applicable. Use of intravenous sedatives is not advised. Flexion-extension X-rays may have detrimental consequences, and may even cause avulsion of the bronchus.

Other useful radiological examinations include:

- CAT scans, which are the investigation of choice for laryngeal fractures
- Contrast enhanced oesophageal studies
- Computerised tomography
- MRI
- High resolution helical CAT-scanning

Note: In "tracheobronchial injury" (TBI) the 'fallen lung sign' is pathognomonic. This occurs due to the loss of central anchoring of the avulsed bronchus.

### Airway management

Many patients are successfully managed with traditional techniques. Always remember to have additional suction. A rigid bronchoscope should always be available. Airway obstruction may be caused by the presence of foreign material such as blood or secretions in the trachea or larynx, laryngotracheal damage or an expanding haematoma. In TBI, radiology and fibre-optic endoscopy should be used in the diagnosis.

**The specific technique and route of intubation is multifactorial and depends on the patient's anatomy, the extent and type of injury, urgency, the location of the patient, the skills of the airway professional, the equipment available and the presence of surgical colleagues.**

### Head trauma and cervical spine injury

Serious head injury requiring intubation usually does not present a problem for intubation. Some care should be taken to avoid excessive increases in intracranial pressure. Use of an opiate such as fentanyl is advocated. One should have a high index of suspicion for cervical spine injuries and cricoid fractures. Endotracheal intubation in these scenarios may be disastrous. A cricoid fracture may be dislocated or may disrupt a partial tracheal transection, producing complete airway obstruction. Virtually all victims of blunt trauma are immobilised on a spine board with a cervical collar. It is essential to keep the head in a neutral position for intubation, with a colleague maintaining in-line mobilisation. The equipment and personnel must be present prior to manipulation of the injured airway.

### Facial trauma

Usually it is not a problem to intubate if the oral cavity is readily accessible. Suction can be used to manage the blood in the upper airways. Bleeding may make intubation by direct vision with a laryngoscope or fibre-optic laryngoscope very difficult. If the entire central face is disrupted and there is no access to the upper airway, then tracheostomy/cricothyroidotomy is indicated. The need for emergency airway management differs according to both weapon type and entry site. Gunshot wounds require early airway establishment. These patients may initially appear to maintain their airway and then rapidly decompensate. Nasal intubation should probably be avoided in some cases due to a possible fractured base of the skull. One should always look at the X-ray of the face to check for impacted bones, such as the zygomatic arch, that may prevent mouth opening.

### Anterior neck trauma

Rapid production of anaesthesia, together with the use of neuromuscular blocking agents can cause loss of the airway and the inability to give positive pressure ventilation. Blunt trauma to the neck can disrupt continuity of the airway (see cricoid fracture above), cause subcutaneous emphysema, or result in haematoma formation. As laryngeal trauma is rare due to the bony structures that protect it, diagnosis may be missed. Even when diagnosed, controversy exists as to how it should be treated. When intubating a patient with laryngeal trauma, a smaller tube should be used. Intubation failure rates can be as high as 76%, and intubation may worsen an already significant injury and create false passages. Tracheostomy is the gold standard in this scenario. Positive pressure ventilation can exacerbate air leaks and rapidly worsen symptoms from pneumothorax, pneumomediastinum and air dissecting around the airway structures. Wherever possible, the patient should be permitted to breathe spontaneously. Flexible bronchoscopy may occlude the airway in a critical stenosis. Although of limited use in trauma patients (see later), it may be useful in some patients. Awake intubation – either blind nasal or orally under vision – may have to be done. Gunshot wounds and penetrating wounds that appear to be causing haematoma formation should be intubated early to prevent expanding haematomas.

Gas induction with the patient breathing spontaneously may be another option. Rigid laryngoscopes and bronchoscopes are inserted, with the patient breathing spontaneously. This is especially useful when there is blood or debris present. Small doses of propofol may be necessary to supplement anaesthesia. One should always have a tracheostomy set open and ready in theatre, with the surgeon present and gloved in the eventuality that an emergency tracheostomy has to be done. Tracheostomy with local anaesthetic is probably the safest option. If the trachea is damaged and further tracheal wall repair is anticipated, it is probably wise to place the tracheostomy through the area of injury. If a tracheostomy is done after the patient has been successfully intubated, NEVER withdraw the endotracheal tube completely from the trachea until you are sure that the tracheotomy tube is correctly sited. Cardiopulmonary bypass has been used to provide emergency support after complete tracheal disruption. Other techniques, such as lighted stylets, retrograde intubation (careful), Bullard laryngoscope, laryngeal mask airway and the combitube may be of value in individual cases. Tracheobronchial injuries (TBI) may be very difficult to handle. Chen et al advise awake fibre-optic intubation or, if the patient is uncooperative, the use of a general anaesthetic.

#### SUMMARY

- Sometimes the injuries are obvious and initial management is straightforward
- Often the diagnosis is difficult. Prompt diagnosis requires a high index of suspicion and judicious use of endoscopy and radiological imaging
- Initial management may be complicated by associated head, neck and thoracic injuries
- A patient's airway can be lost with injudicious use of sedation and rough endotracheal intubation
- Mortality rates and incidence of late complications remain high and have been related to delays in diagnosis and definitive treatment
- Open trauma to the larynx often facilitates rather than impedes intubation
- Closed injury or separation of the trachea from the larynx are much more serious. Paralysis should preferably be avoided. Plan for surgical exploration with formal tracheostomy
- Careful evaluation of each patient is essential and the management of the patient has to be individualised
- There are scenarios that are 'no-win' situations and, despite sophisticated manipulations by yourself and the ENT surgeon, it might not be possible to secure the airway
- Do not allow the surgeon to "scope" the trauma patient before the airway has been secured

It is imperative to evaluate and treat each one of these cases individually.

#### IN CONCLUSION

Plans A, B and C must be in place. Be flexible and ready to convert to the next plan in seconds. Fibre-optic intubation in the trauma situation is not advocated for most cases for the following reasons:

- Difficulty in handling secretions and blood with limited suction
- Operator inexperience
- A degree of patient cooperation is necessary, and these patients may not be able to cooperate.

SAJAA

#### BIBLIOGRAPHY

1. Peralta R, Hurford WE. Airway trauma. *International Anesthesiology Clinics* 1999;Summer:111–27.
2. Davidge-Pitts KJ. Head and neck trauma. p. 628–48.
3. Cole RD, Brown DJ, Phipps CD. Gunshot wounds to the mandible and midface: evaluation, treatment, and avoidance of complications. *Otolaryngology – Head and Neck Surgery* 1994;December:739–45.
4. Kendall JL, Anglin D, Demetriades D. Penetrating neck trauma. *Emergency Medicine Clinics of North America* 1998;16(1):85–105.
5. Walls RM. Management of the difficult airway in the trauma patient. *Emergency Medicine of North America* 1998;16(1):45–61.
6. Mason RA, Fielder CP. Editorial. The obstructed airway in head and neck surgery. *Anaesthesia* 1999;54:625–8.
7. Bent JP, Silver JR, Porubsky ES. *Otolaryngology – Head and Neck Surgery* 1993;September:441–9.
8. Courcy MS. Airway obstruction. The problems and its causes. *Otolaryngologic Clinics of North America* 1995;28(4):673–83.
9. Sheridan RL. Airway management and respiratory care of the burn patient. *International Anesthesiology Clinics* 1999;Summer:129–45.
10. Chen AY, Stewart MG, Raup G. Penetrating injuries of the face. *Otolaryngology – Head and Neck Surgery* 1996;November:464–70.
11. Chu CPW, Chen PP. Tracheobronchial injury secondary to blunt chest trauma: diagnosis and management. *Anaesth Intensive Care* 2002;30:145–52.
12. Ouellette RG. The effect of nitrous oxide on laryngeal mask cuff pressure. *AANA J* 2000;68(5):411–4.
13. Gaylard D. Lingual nerve injury following the use of the laryngeal mask airway. *Anaesth Intensive Care* 1999;27(6):668.
14. Laxton CH, Kipling R. Lingual nerve paralysis following the use of the laryngeal mask airway. *Anaesthesia* 1996;51:869–70.
15. Lowinger D, Benjamin B, Gadd L. Recurrent nerve injury caused by the laryngeal mask airway. *Anaesth Intensive Care* 1999;27:202–5.
16. King C, Street MK. Twelfth cranial nerve paralysis following use of laryngeal mask airway. *Anaesthesia* 1994;49:786–7.
17. Norton A, Gemonpre J, Semple T. *Anaesth Intensive Care* 1998;26(2):213–5.
18. Brimacombe J, et al. Pharyngolaryngeal, neck, and jaw discomfort after anaesthesia with a face mask and the laryngeal mask airway at high and low cuff volumes in males and females. *Anesthesiology* 2000;93(1):26–31.
19. Domino WB, et al. Airway injury during anaesthesia. Closed claims analysis. *Anesthesiology* ;91(6):1703–11.
20. Rosenberg M, et al. Arytenoid cartilage dislocation caused by a laryngeal mask airway treated with chemical splinting. *Anesth Analg* 1996;83:1335–6.
21. Bullingham A, et al. An impaled neck. Management of difficult airway access. *Anaesthesia* 1994;49:866–9.
22. Joly LM, et al. Difficult tracheal intubation as a result of penetrating cranio-facial injury by an arrow. *Anesth Analg* 2002;94(1):231–2.
23. Zonies D, et al. Diagnosis and management of laryngotracheal injuries. *Intensive Care* 2004;Winter:161–6.
24. Verschuere DMD, et al. Management of laryngo-tracheal injuries associated with craniomaxillofacial trauma. *Journal of Oral and Maxillofacial Surgery* 2006;64(2):203–14.
25. Nelson LA. Airway trauma. *International Anesthesiology Clinics* 2007;45(3):99–118.