



## Original Research

# Sentinel lymph node mapping and intraoperative assessment in a prospective, international, multicentre, observational trial of patients with cervical cancer: The SENTIX trial



David Cibula <sup>a,\*</sup>, Roman Kocian <sup>a,1</sup>, Andrea Plaikner <sup>b</sup>, Jiri Jarkovsky <sup>c</sup>, Jaroslav Klat <sup>d,1</sup>, Ignacio Zapardiel <sup>e</sup>, Radovan Pilka <sup>f,1</sup>, Aureli Torne <sup>g</sup>, Borek Sehnal <sup>h,1</sup>, Marcela Ostojich <sup>i</sup>, Almerinda Petiz <sup>j</sup>, Octavio A. Sanchez <sup>k</sup>, Jiri Presl <sup>l,1</sup>, Alessandro Buda <sup>m</sup>, Francesco Raspagliesi <sup>n</sup>, Peter Kascak <sup>o,1</sup>, Luc van Lonkhuijzen <sup>p</sup>, Marc Barahona <sup>q</sup>, Lubos Minar <sup>r,1</sup>, Pawel Blecharz <sup>s,1</sup>, Maja Pakiz <sup>t,1</sup>, Dariusz Wydra <sup>u,1</sup>, Leon C. Snyman <sup>v</sup>, Kamil Zalewski <sup>w,1</sup>, Cristina Zorrero <sup>x</sup>, Pavel Havelka <sup>y,1</sup>, Mikulas Redecha <sup>z,1</sup>, Alla Vinytska <sup>aa,1</sup>, Ignace Vergote <sup>ab,2</sup>, Solveig Tingulstad <sup>ac</sup>, Martin Michal <sup>ad,1</sup>, Barbara Kipp <sup>ae</sup>, Jiri Slama <sup>a,1</sup>, Simone Marnitz <sup>af</sup>, Sylva Bajsova <sup>d</sup>, Alicia Hernandez <sup>e</sup>, Daniela Fischerova <sup>a,1</sup>, Kristyna Nemejcova <sup>ag</sup>, Christhardt Kohler <sup>b</sup>

<sup>a</sup> Gynecologic Oncology Center, Department of Obstetrics and Gynecology, First Faculty of Medicine, Charles University and General University Hospital, Prague, Czech Republic

<sup>b</sup> Department of Special Operative and Oncologic Gynaecology, Asklepios-Clinic Hamburg, Hamburg, Germany

<sup>c</sup> Institute of Biostatistics and Analyses, Faculty of Medicine, Masaryk University, Brno, Czech Republic

<sup>d</sup> Department of Obstetrics and Gynecology, University Hospital Ostrava, Ostrava Poruba, Czech Republic

<sup>e</sup> Gynecologic Oncology Unit, La Paz University Hospital, Madrid, Spain

<sup>f</sup> Department of Obstetrics and Gynecology, Faculty of Medicine and Dentistry, Palacky University, University Hospital Olomouc, Olomouc, Czech Republic

<sup>g</sup> Unit of Gynecological Oncology, Institute Clinic of Gynaecology, Obstetrics, and Neonatology, Hospital Clinic-Institut d'Investigacions Biomèdiques August Pi i Sunyer (IDIBAPS), University of Barcelona, Barcelona, Spain

<sup>h</sup> Department of Obstetrics and Gynecology, Bulovka Hospital, First Faculty of Medicine, Charles University, Prague, Czech Republic

<sup>i</sup> Department of Gynecology, Institute of Oncology Angel H. Roffo, University of Buenos Aires, Buenos Aires Autonomous City, Argentina

\* Corresponding author: Department of Obstetrics and Gynecology, First Faculty of Medicine, Charles University and General University Hospital, Apolinaraska 18, Prague 2, 12801, Czech Republic.

E-mail address: [david.cibula@vfn.cz](mailto:david.cibula@vfn.cz) (D. Cibula).

<sup>1</sup> Central and Eastern European Gynecologic Oncology Group, CEEGOG. <sup>2</sup> Belgium and Luxembourg Gynaecological Oncology Group, BGOG.

<sup>j</sup> Department of Gynecology, Francisco Gentil Portuguese Oncology Institute, Porto, Portugal

<sup>k</sup> Department of Gynecologic Oncology, University Hospital of the Canary Islands, Las Palmas de Gran Canaria, Spain

<sup>l</sup> Department of Gynaecology and Obstetrics, University Hospital Pilsen, Charles University, Prague, Czech Republic

<sup>m</sup> Department of Obstetrics and Gynecology, Unit of Gynecologic Oncology Surgery, San Gerardo Hospital, Monza, Italy

<sup>n</sup> Fondazione IRCCS Istituto Nazionale Tumori - Milan, Milan, Italy

<sup>o</sup> Department of Obstetrics and Gynecology, Faculty Hospital Trencin, Trencin, Slovakia

<sup>p</sup> Center for Gynecologic Oncology, Amsterdam University Medical Center, Amsterdam, the Netherlands

<sup>q</sup> Department of Gynecology, University Hospital of Bellvitge, Biomedical Research Institute of Bellvitge, University of Barcelona, Barcelona, Spain

<sup>r</sup> Department of Gynecology and Obstetrics, Faculty of Medicine, Masaryk University, Brno, Czech Republic

<sup>s</sup> Department of Gynecologic Oncology, Centre of Oncology, M. Skłodowska-Curie Memorial Institute, Cracow Department, Cracow, Poland

<sup>t</sup> University Clinic for Gynaecology and Perinatology, University Medical Centre Maribor, Maribor, Slovenia

<sup>u</sup> Department of Gynecology, Gynecologic Oncology and Gynecologic Endocrinology, Medical University of Gdansk, Poland

<sup>v</sup> Gynaecologic Oncology Unit, Department of Obstetrics and Gynaecology, University of Pretoria, Pretoria, South Africa

<sup>w</sup> Department of Gynecologic Oncology, Holycross Cancer Center, Kielce, Poland

<sup>x</sup> Gynecology Department, Instituto Valenciano de Oncologia (IVO), Valencia, Spain

<sup>y</sup> Department of Obstetrics and Gynecology, KNTB a.s Zlin, Czech Republic

<sup>z</sup> Department of Gynaecology and Obstetrics, University Hospital, Comenius University, Bratislava, Slovakia

<sup>aa</sup> LISOD - Israeli Oncological Hospital, Plyuty, Ukraine

<sup>ab</sup> Department of Gynecology and Obstetrics, University Hospital Leuven, Leuven Cancer Institute, Leuven, Belgium

<sup>ac</sup> Department of Gynaecology, St Olav's Hospital, Trondheim, Norway

<sup>ad</sup> Department of Obstetrics and Gynaecology, Hospital Ceske Budejovice, JSC, Ceske Budejovice, Czech Republic

<sup>ae</sup> Department of Obstetrics and Gynecology, Cantonal Hospital of Lucerne, Lucerne, Switzerland

<sup>af</sup> Department of Radiation Oncology, CyberKnife and Radiotherapy University Hospital Cologne, Cologne, Germany

<sup>ag</sup> Institute of Pathology, First Faculty of Medicine, Charles University and General University Hospital in Prague, Prague, Czech Republic

Received 13 May 2020; received in revised form 25 June 2020; accepted 30 June 2020

Available online 1 August 2020

## KEYWORDS

Cervical cancer;  
Sentinel lymph node;  
Frozen section;  
Mapping;  
Ultrastaging;  
Micrometastases

**Abstract Background:** SENTIX (ENGOT-CX2/CEEGOG-CX1) is an international, multi-centre, prospective observational trial evaluating sentinel lymph node (SLN) biopsy without pelvic lymph node dissection in patients with early-stage cervical cancer. We report the final preplanned analysis of the secondary end-points: SLN mapping and outcomes of intraoperative SLN pathology.

**Methods:** Forty-seven sites (18 countries) with experience of SLN biopsy participated in SENTIX. We preregistered patients with stage IA1/lymphovascular space invasion-positive to IB2 (4 cm or smaller or 2 cm or smaller for fertility-sparing treatment) cervical cancer without suspicious lymph nodes on imaging before surgery. SLN frozen section assessment and pathological ultrastaging were mandatory. Patients were registered postoperatively if SLN were bilaterally detected in the pelvis, and frozen sections were negative. Trial registration: [ClinicalTrials.gov](https://clinicaltrials.gov/ct2/show/study/NCT02494063) (NCT02494063).

**Results:** We analysed data for 395 preregistered patients. Bilateral detection was achieved in 91% (355/395), and it was unaffected by tumour size, tumour stage or body mass index, but it was lower in older patients, in patients who underwent open surgery, and in sites with fewer cases. No SLN were found outside the seven anatomical pelvic regions. Most SLN and positive SLN were localised below the common iliac artery bifurcation. Single positive SLN above the iliac bifurcation were found in 2% of cases. Frozen sections failed to detect 54% of positive lymph nodes (pN1), including 28% of cases with macrometastases and 90% with micrometastases.

**Interpretation:** SLN biopsy can achieve high bilateral SLN detection in patients with tumours of 4 cm or smaller. At experienced centres, all SLN were found in the pelvis, and most were located below the iliac vessel bifurcation. SLN frozen section assessment is an unreliable tool for intraoperative triage because it only detects about half of N1 cases.

© 2020 The Author(s). Published by Elsevier Ltd. This is an open access article under the CC BY-NC-ND license (<http://creativecommons.org/licenses/by-nc-nd/4.0/>).

## 1. Research in context panel

### 1.1. Evidence before the study

We searched Medline and Embase for studies published between January 2009 and December 2019, without language restrictions, using the following key words: sentinel lymph node (SLN), frozen section, SLN detection, indocyanine green, blue dye, lymphatic mapping and cervical cancer. Reviews and single institutional cohort studies involving fewer than 40 subjects were excluded. We found 46 articles reporting the bilateral SLN detection in patients with cervical cancer. This frequency varied widely, from 55% to 100%, depending on the detection technique, study design, cohort size and year of publication. Bilateral mapping over 90% was only reported in single institutional studies using indocyanine green. Factors influencing detection included tumour size, body mass index, surgical approach, previous neoadjuvant chemotherapy, age and lymphovascular space invasion. The frequency of atypical SLN localisation ranged from 0% to 20% and included the paraaortic region in up to 5% of cases. Some studies, however, considered the common iliac and presacral regions to be atypical. Twenty-one articles compared the outcomes of SLN frozen sections and pathological ultrastaging. The false negative frequency, taking into account only macrometastases and micrometastases, ranged from 0% to 45%. The studies showed significant heterogeneity in terms of sample size, study design and the protocol used for SLN ultrastaging.

### 1.2. Added value of this study

SENTIX is the largest, prospective, multicentre trial on SLN biopsy in patients with cervical cancer. Only sites with experience of performing SLN biopsy were eligible to join the trial. We designed protocol to mimic current clinical practice, without restrictions on the technique used for SLN detection or the surgical approach. To our knowledge, this is the first trial involving prospective central pathology review. This, in combination with an intensive protocol for SLN ultrastaging, facilitated reliable detection of macrometastases and micrometastases.

### 1.3. Implications of all the available evidence

The trial showed that SLN biopsy techniques can be standardised to achieve optimal SLN pelvic mapping (bilateral detection) in more than 90% of patients with cervical cancers smaller than 4 cm, irrespective of the patient's body mass index or tumour size. At experienced sites, all SLN were detected in the pelvis, and most were found in two well-defined anatomical regions below the iliac vessel bifurcation. The risk of isolated

positive SLN above this anatomical landmark was less than 2%. Frozen section is an unreliable tool for intraoperative triage because it fails to detect about half of cases with lymph node involvement.

## 2. Introduction

SLN biopsy has been implemented into the standard of care for most gynaecological cancers, including vulvar, endometrial and cervical cancers. For cervical cancer, SLN biopsy is currently recommended for pelvic lymph node staging in patients with stage IA2 and lymphovascular space invasion in European guidelines [1], while full pelvic lymphadenectomy is still considered the standard of care for all early-stage cervical cancer in the National Comprehensive Cancer Network guidelines [2]. The main motive for avoiding systematic lymph node dissection is to decrease long-term morbidities, especially lower-leg lymphoedema [3,4]. Although the first studies of SLN in cervical cancer were published about 20 years ago [5,6], only a few studies have focused on patients undergoing SLN biopsy without subsequent pelvic lymph node dissection [7].

SENTIX is the first prospective, multicentre, observational trial of SLN in patients with cervical cancer in which the primary end-point is the oncological outcome [8] defined as the recurrence rate at 24 months after the surgery, which will be reached in 2021. In this article, we report the final preplanned analysis of the secondary end-points, including the SLN mapping and frozen section in 395 patients.

## 3. Methods

### 3.1. Study design and participants

Patients were preregistered into the study if their International Federation of Gynecology and Obstetrics (FIGO) stage was IA1 (with lymphovascular space invasion), IA2 or IB1 according to the FIGO 2009 classification, lacked suspicious lymph nodes on preoperative imaging, had a common histological type (squamous cell carcinoma, adenocarcinoma or adenosquamous carcinoma), and the largest tumour diameter was less than 4 cm or less than 2 cm for patients scheduled for a fertility-sparing procedure. Preregistered patients were registered after surgery if they met additional intraoperative criteria such as bilateral SLN detection, no metastasis of any size found on frozen sections and no evidence of more advanced disease (exceeding stage IB1).

The final analysis of the secondary end-points was performed as preplanned, once 300 patients were registered postoperatively. The detection frequency was calculated in the broader cohort of 395 patients who

were preregistered before surgery once the target of 300 registered cases was reached (Fig. 1).

The quality criteria used to assess the participating sites were published previously [8]. The SENTIX Steering Committee excluded two sites (2/49) because of critical deviations from the SLN pathological assessment that were identified by central pathological review.

SENTIX was conducted as a European Network of Gynaecological Oncology Trial Groups (ENGOT) trial (ENGOT Cx2) and was led by the Central and Eastern European Gynaecologic Oncology Group (CEEGOG; CEEGOG Cx1). The protocol was approved by the institutional review board at the leading institution (General University Hospital in Prague) in June 2016 and was subsequently approved by the institutional review boards at all participating institutions (appendix Supplementary Fig. 1). The study was performed according to ENGOT Model A [9].

### 3.2. Procedures

#### 3.2.1. SLN detection

The protocol for SLN detection was published previously [8]. The protocol permitted open surgery or minimally invasive techniques, and the use of any (or combinations) of the three main tracers: blue dye, radiocolloid and indocyanine green. All blue, ‘hot’ or fluorescent LN were to be removed. Patients were to be excluded from the study if SLN were not bilaterally identified; these patients were managed according to the institutional guidelines.

#### 3.2.2. Definition of anatomical regions in the pelvis

Seven anatomical regions of the pelvis were identified using anatomical landmarks [10]. If SLN were identified in more than one region, they were to be submitted for pathology separately. The following anatomical landmarks defined individual anatomical regions: (a) external iliac region (right and left): paravesical fossa medially, psoas muscle laterally, superior ramus of the pubic bone ventrally and common iliac artery bifurcation dorsally; (b) interiliac region (also known as the obturator region) (right and left): caudal wall of the external iliac vein cranially, common iliac artery bifurcation dorsally, paravesical space medially, pubic bone together with the levator muscle ventrally, psoas muscle laterally and obturator vessels caudally; (c) common iliac region (right and left): aortic bifurcation cranially, medial aspect of the common iliac vessels medially, psoas muscle laterally, bifurcation of common iliac vessels ventrally and sacral bone caudally; (d) presacral region: common iliac vessels cranially and laterally, sacral bone caudally and the level of right common iliac vessels bifurcation ventrally. The distribution of SLN was assessed for anatomical levels I and II separately. Level I was defined as below the common iliac artery bifurcation and comprised the external iliac and interiliac regions. Level II comprised the common iliac regions and the presacral region.

#### 3.2.3. Frozen sections

Intraoperative pathological assessment of all SLN was mandatory. Intraoperatively, all SLN were grossly

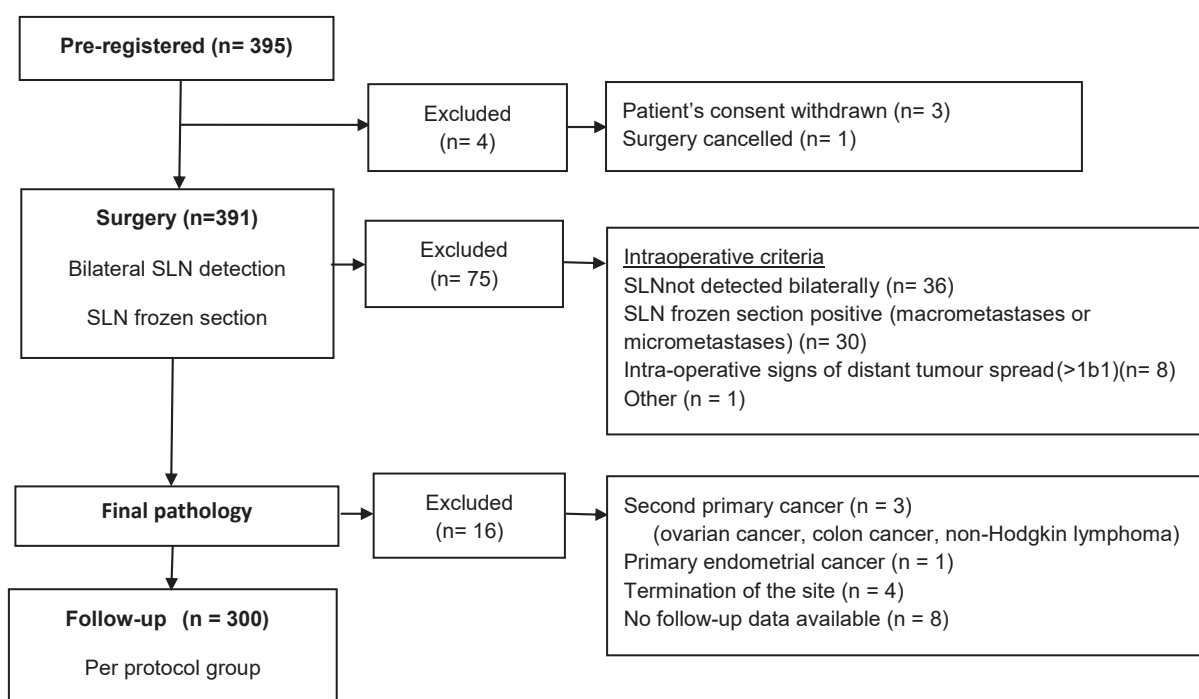


Fig. 1. Flow chart of patients registered in the SENTIX trial. SLN, sentinel lymph node.

assessed by a pathologist, and any SLN with suspected metastasis was sent for frozen section assessment. For unsuspected SLN, one randomly selected slice was taken and evaluated. If frozen sections revealed metastatic involvement, the patient was to be excluded from the study during surgery and managed according to the institutional guidelines.

#### 3.2.4. SLN ultrastaging protocol

After intraoperative processing, all SLN were sent for ultrastaging. This involved cutting two consecutive sections (4 µm thick) at 150-µm intervals from each paraffin block until there was no LN tissue left. The first section was stained with haematoxylin and eosin, and the second section was examined immunohistochemically with anti-cytokeratin antibodies (AE1/AE3). Macrometastases were defined as metastatic lesions of at least 2 mm in diameter, micrometastases as lesions of more than 0.2 to 2 mm or less in diameter and isolated tumour cells as individual cells or small clusters of cells of up to 0.2 mm in diameter (less than 200 cells) [11].

#### 3.2.5. Central pathological review

All SLN slides with corresponding paraffin blocks and the full pathology report from at least two patients per site were submitted to the central laboratory at the General University Hospital, Prague, for central review. Any sites with major or critical deviations were asked to submit samples and pathology reports from all enrolled patients for a second round of assessment.

#### 3.3. Statistical analysis

We used standard descriptive statistical analyses, including determination of the absolute and relative frequencies for categorical variables and the median with the 5th–95th percentile range for continuous variables. Fisher's exact test was used for between-group comparisons of categorical variables. Logistic regression was used to determine factors that may influence the SLN detection frequency using the forward stepwise algorithm in a multivariable model. The overall predictive power of the model was computed by receiver operator characteristic curve analysis by calculating the area under the curve with 95% confidence intervals. Two-sided  $\alpha = 0.5$  was adopted as the level of statistical significance. All analyses were performed using SPSS 25.0.0.1 (IBM Corporation 2019). This study was registered with [ClinicalTrials.gov](https://clinicaltrials.gov/ct2/show/study/NCT02494063) (NCT02494063).

#### 3.4. Role of the funding source

The Czech Research Council was not involved in the design of the trial; in the collection, analyses or interpretation of data; in the writing of the manuscript or in the decision to publish the results.

## 4. Results

The characteristics of the preregistered patients are shown in Table 1. Most of the patients had stage IB1 disease (N = 342; 88%) and tumours less than or equal to 2 cm in the largest diameter (N = 256; 66%). Squamous cell cancer was the most frequent tumour type (N = 277; 71%), followed by adenocarcinoma (N = 105; 27%) and adenosquamous carcinoma (N = 9; 2%). Majority of SLN were removed by

Table 1  
Preoperative characteristics of patients (N = 391).

Variables	Value
Number of patients registered per site	
≤10	150 (38.4%)
11–20	89 (22.8%)
>20	152 (38.9%)
Age (continuous) (years)	43 (29–69)
Age category (years)	
≤40	153 (39.1%)
41–60	180 (46.0%)
>60	58 (14.8%)
Body mass index (continuous) (kg/mg <sup>2</sup> )	24.6 (18.7–36.1)
Body mass index category (kg/mg <sup>2</sup> )	
≤25	218 (55.8%)
26–30	91 (23.3%)
>30	82 (21.0%)
ECOG performance status	
0	373 (95.4%)
1	18 (4.6%)
Diagnostic procedure	
Biopsy	178 (45.5%)
Conisation	219 (56.0%)
FIGO stage (preoperative)	
IA1 + lymphovascular space invasion	19 (4.9%)
IA2	30 (7.7%)
IB1	342 (87.5%)
Grade	
G1	88 (22.5%)
G2	216 (55.2%)
G3	83 (21.2%)
NA	4 (1.0%)
Tumour type	
Squamous cell carcinoma	277 (70.8%)
Adenocarcinoma	105 (26.9%)
Adenosquamous carcinoma	9 (2.3%)
Tumour size (preoperative imaging)	
≤2 cm	256 (65.5%)
>2 cm	134 (34.3%)
Not applicable	1 (0.3%)
Surgical approach	
Laparotomy	121 (30.9%)
Laparoscopy	169 (43.2%)
Robotic	26 (6.6%)
Vaginal-laparoscopic	74 (18.9%)
Lymphovascular space invasion (n = 377)	
Yes	120 (31.8%)
No	251 (66.6%)
Not applicable	6 (1.6%)

Values are no. of patients (%) or median (5th–95th percentile). ECOG, Eastern Cooperative Oncology Group; FIGO, International Federation of Gynecology and Obstetrics.

minimally invasive surgery (N = 270; 69%), including laparoscopic or robotic approach.

SLN were detected bilaterally in 351 patients (91%) with a median of 3 (2–12) SLN per patient (Table 2). All three detection techniques and their combinations were eligible in the study; the most prevalent was a combination of blue dye and radiocolloid (N = 141; 36%), followed by blue dye alone (N = 58; 15%) or indocyanine green alone (N = 59; 15%) and a combination of blue dye and indocyanine green (N = 51; 13%). The mean number of SLN per patient was highest when all three tracers were used in combination (5.28 SLN per patient), and it was similar for the three tracers used individually or in other combinations (2.79 to 3.97 SLN per patient) (appendix Supplementary Table 1).

Fig. 2 shows the anatomical distribution of the detected SLN and positive SLN. Most SLN were detected in anatomical Level I of the pelvis (N = 351; 90%), comprising the external iliac and interiliac regions (appendix Supplementary Tables 2 and 3). Metastatic involvement of the SLN was found in 62 patients, including macrometastases, micrometastases and isolated tumour cells in 29, 21 and 12 patients, respectively (Table 3). There were no differences in the anatomical distributions of SLN and positive SLN between the pelvic sides. Pelvic mapping of positive SLN

corresponded to the overall SLN distribution. SLN were detected in Level II above the interiliac bifurcation in only 16 (4%) patients, and only seven (2%) patients had isolated positive SLN in this region without simultaneous positivity in Level I (appendix Supplementary Table 3).

Four variables were significantly associated with successful bilateral SLN detection in univariate analysis: use of indocyanine green, age, surgical approach and number of patients per site (Table 4). Only two significant variables remained in the multivariable analysis: age and number of patients per site (appendix Supplementary Fig. 1, Supplementary Table 4). SLN detection was not influenced by the patient's body mass index, tumour size, tumour type or lymphovascular space invasion. However, larger tumour size and lymphovascular space invasion were associated with a higher risk of SLN involvement (appendix Supplementary Table 5).

The results of the frozen section and definitive ultrastaging are displayed in Table 3. Of 29 patients with macrometastases, 21 (72%) were identified by frozen section and eight by ultrastaging. The majority of micrometastases were detected by ultrastaging (19/21; 90%) and two by frozen sections. All 12 patients with isolated tumour cells were detected by ultrastaging. The sensitivity of frozen section assessment of SLN status was 75.9% for macrometastases and 45.8% for N1 (macrometastases and micrometastases).

Table 2  
SLN detection (N = 391).

Variables	Value
SLN detection per pelvic side	
None or unilateral	36 (9.2%)
Bilateral	355 (90.8%)
Detection method	
Not applicable	2 (0.5%)
Blue dye	58 (14.8%)
Radiocolloid	14 (3.6%)
Indocyanine green	59 (15.1%)
Blue dye + radiocolloid	141 (36.1%)
Blue dye + indocyanine green	51 (13.0%)
Radiocolloid + indocyanine green	36 (9.2%)
Blue dye + radiocolloid + indocyanine green	30 (7.7%)
No. of SLN per patient	
0	10 (2.7%)
1	6 (1.6%)
2	121 (32.1%)
3	85 (22.5%)
4	52 (13.8%)
>4	103 (27.6%)
Median no. of SLN per patient	3 (2–12)
No. of patients with positive SLN	
Total	62 (16.5%)
Bilateral SLN	59 (15.6%)
Unilateral SLN	3 (0.8%)
No. of positive SLN	
0	316 (83.8%)
1	47 (12.5%)
2	11 (2.9%)
3	4 (1.1%)

Values are no. of patients (%) or median (5th–95th percentile).  
SLN, sentinel lymph node.

## 5. Discussion

We achieved the highest bilateral SLN detection in cervical cancer patients ever reported in a multicentre trial. We hypothesise that this high detection frequency reflects the selection of sites with prior experience of performing SLN biopsy in patients with gynaecological tumours. Only 9% of patients were excluded from the trial because of failure to detect bilateral SLN in the pelvis. Many variables were not significantly associated with the detection frequency, most notably the patient's body mass index, tumour size and tumour stage. However, the detection frequency was lower in older patients and in sites that enrolled a small number of cases. None of the SLN were localised outside of the seven standard anatomical regions of the pelvis. Interestingly, a sole positive SLN above the level of iliac vessels bifurcation was found in 2% of cases. These findings suggest that surgical exploration of the external iliac and interiliac regions is crucial for pelvic LN staging of cervical cancer. Frozen sections provided an inaccurate assessment of SLN metastatic involvement because it failed to detect 90% of micrometastases and nearly a third (28%) of macrometastases. Consequently, frozen sections yielded a low sensitivity of 46% for patients with FIGO

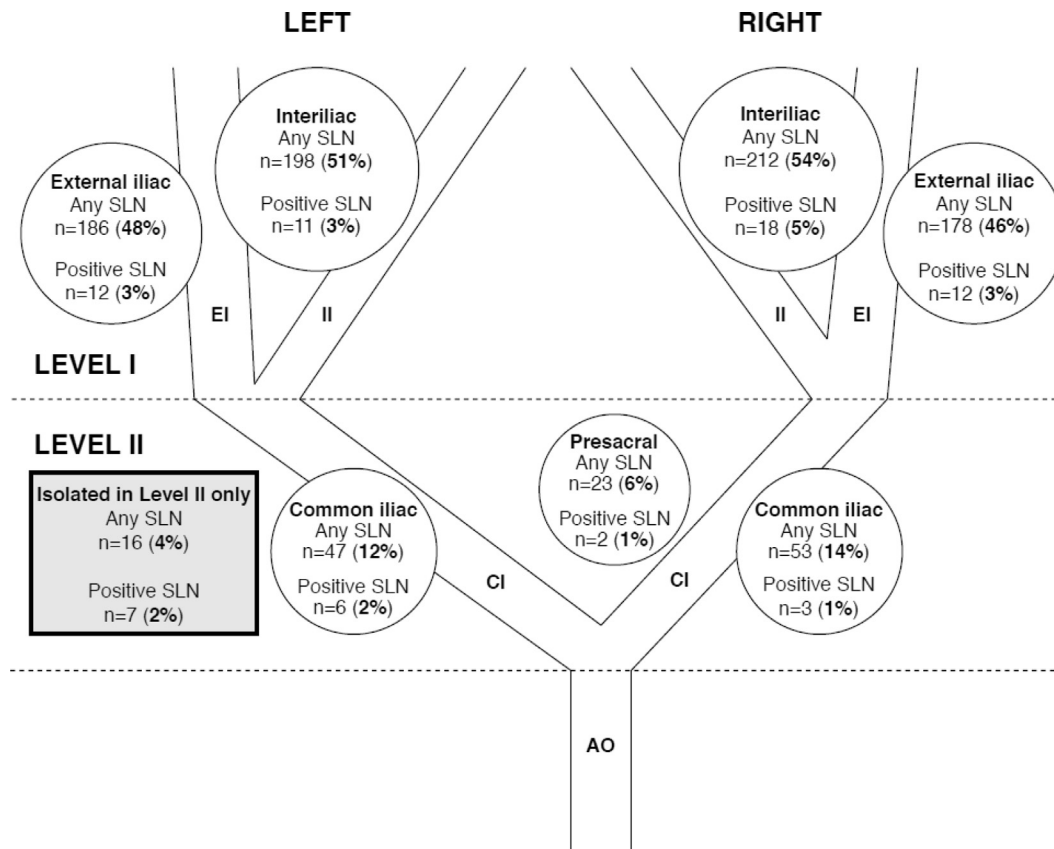


Fig. 2. Anatomical distribution of SLN in the pelvis. AO, aorta; CI, common iliac; EI, external iliac; II, internal iliac; SLN, sentinel lymph node.

N1 (i.e. patients with macrometastases plus micrometastases).

SENTIX is the first prospective observational multi-centre trial powered to assess the oncological outcomes after SLN biopsy without simultaneous pelvic lymphadenectomy. Although survival data will not be mature before 2021, the final analysis of secondary end-points, including the SLN detection frequency and the accuracy of SLN frozen sections, was preplanned in a cohort of the first 300 registered patients.

The trial was designed to reflect current clinical practice. Therefore, the protocol permitted all surgical approaches and all of the main SLN detection techniques. SLN frozen section evaluation was mandatory and was performed to detect nearly all patients with positive SLN and exclude them from the study. Only patients in whom the bilateral SLNs were negative on frozen sections could be registered postoperatively.

In addition to its prospective design, another strength of the SENTIX trial was the intensive SLN ultrastaging protocol. As we recently described, pathological protocols are often incompletely described in the literature, and the differences between studies are so substantial that the outcomes cannot be compared reliably [12]. Our intention in the SENTIX trial was to minimise the risk of missing any metastasis larger than 0.2 mm

(micrometastasis). While two to four levels of paraffin blocks are usually examined in routine practice, here, the SLN were processed completely until no residual tissue remained. Moreover, SENTIX was the first study to include prospective central pathological review of SLN in patients with cervical cancer. If any major deviation was identified at central review, the SLN assessment was completed according to the protocol in a central laboratory. The quality of SLN pathological assessment was considered crucial for maintaining patient safety. It has been shown that patients with micrometastases or isolated tumour cells in their SLN may have macrometastases in other pelvic LN [13]. These patients may not be considered high-risk without SLN ultrastaging. Furthermore, their positive LN may not be removed, and they may not receive adjuvant treatment. For the safety of patients, it is important that the avoidance of full LN dissection is balanced by more intensive pathological assessment of SLN.

As the cervix is a central pelvic organ, staging of pelvic LN on both sides should be conducted separately. The sensitivity of SLN status for pelvic LN staging is greatest for patients with bilateral SLN detection. Therefore, bilateral SLN detection was an intra-operative inclusion criterion in the SENTIX trial [8]. A lower detection frequency was reported in earlier studies

Table 3  
SLN status assessed by frozen section and final ultrastaging (N = 391).

Type of SLN involvement	SLN status (no. of patients)			SLN frozen section outcome (%)		
	Frozen section	Ultrastaging	Final status <sup>a</sup>	Sensitivity	False negatives	NPV
Macrometastases	21	8	29	72.4	27.6	97.8
Micrometastases	2	19	21	9.5	90.5	94.7
Isolated tumour cells	0	12	12	0	100	96.7
Macrometastases + micrometastases	23	27	50	46.0	54.0	92.5
Macrometastases + micrometastases + isolated tumour cells	23	39	62	37.1	62.9	89.2

SLN, sentinel lymph node; NPV, negative prediction value.

<sup>a</sup> Combined results of frozen section and ultrastaging.

when SLN biopsy techniques were being developed, especially for larger tumours [14,15]. In an earlier literature review published in 2013, the difference in side-specific detection was 25% between groups with tumours of less than 2 cm (n = 768) and greater than 2 cm (n = 724) in size [16]. Many other factors have also been reported to influence the detection of SLN, including body mass index, age, surgical approach, lymphovascular space invasion and previous administration of neoadjuvant chemotherapy [17,18]. With better standardisation of SLN biopsy techniques, the differences in detection between smaller and larger tumours has progressively decreased [19,20]. Bilateral detection was achieved in 72% of patients in the largest retrospective cohort of 645 patients to date [21] and in 77% of patients in a French prospective multicentre study involving 145 patients [22] with tumours of up to 4 cm in diameter. In a combined analysis of two French prospective studies, conducted consecutively, a learning curve was also apparent because the detection frequency was significantly higher in the latter study [17].

Previous experience of SLN detection in patients with gynaecological pelvic cancers was a prerequisite for an institution to join the SENTIX trial. To our knowledge, the achieved bilateral detection above 90% is the highest reported in a multicentre study in patients with cervical cancer. This indicates that the SLN biopsy technique can be standardised for all patients with tumours up to 4 cm in size. An important message for routine practice is that variables, such as body mass index, tumour size and surgical approach, did not negatively influence SLN detection. We found just two significant factors with a negative impact on successful bilateral detection, namely the number of patients per site and age. A smaller number of patients per site and older age were associated with lower detection frequencies.

An advantage of the SLN concept is that it provides an opportunity to identify a small number of LN at the highest risk of involvement, allowing a frozen section to be sent for pathological assessment [1]. The median number of SLN per patient in our trial was 3. The literature is, however, discrepant when it comes to the reliability of intraoperative SLN assessment. In the

French prospective study, frozen sections were performed in 102 patients, and in these patients, it failed to detect 70% of patients with macrometastases (4/9) or all patients with micrometastases (4/4) [23]. In a large retrospective cohort of 225 cases, frozen sections identified just 56% of patients with macrometastases or micrometastases [24]. Other studies, however, reported a higher reliability of frozen sections [25–30]. The intraoperative technique of assessing SLN is fairly uniform and usually involves assessment of one slice from each SLN or from each half SLN. A higher number of sections would prolong surgery, and it may result in the loss of a substantial part of SLN tissue that would otherwise be available for further ultrastaging. Therefore, the key factor that influences the sensitivity of frozen sections is the quality of the final SLN processing. More intensive ultrastaging protocols allow pathologists to detect a higher number of small metastases, which are often missed intraoperatively.

Thirty patients (8%) were excluded from our trial due to intraoperative detection of SLN involvement (Fig. 1). Among the total cohort of 395 preregistered patients, at least one type of SLN involvement was found in 62 (16%) patients. The frozen sections failed to identify 54% of patients with FIGO stage N1 (i.e. macrometastases plus micrometastases). Our findings indicate that intraoperative assessment is not only unable to detect micrometastases, but also about one-third of macrometastases. Consequently, for about half of patients in our study, information about LN involvement was not available during surgery and was instead obtained from the final pathology report several days after surgery.

Some single-centre studies have favoured indocyanine green as the tracer for SLN detection [31–33]. Comparison of the detection frequency between the different tracers was not a preplanned end-point of our trial. The protocol allowed each institution to use the technique they were most comfortable with using. Indocyanine green was indeed a significant factor associated with a higher detection frequency in the univariate analysis. However, considering the high bilateral SLN detection in the overall cohort, the difference in



Table 4  
Parameters associated with bilateral SLN detection (N = 391).

Parameters	SLN detection, no. of patients (%)		OR (95% CI)	p
	Both sides	None or one side		
Technique: blue dye				
No	101 (91.0%)	10 (9.0%)	Reference	
Yes	254 (90.7%)	26 (9.3%)	1.034 (0.481–2.222)	0.932
Technique: radiocolloid				
No	152 (89.4%)	18 (10.6%)	1.336 (0.672–2.653)	0.409
Yes	203 (91.9%)	18 (8.1%)	Reference	
Technique: indocyanine green				
No	189 (87.9%)	26 (12.1%)	2.284 (1.070–4.876)	0.033
Yes	166 (94.3%)	10 (5.7%)	Reference	
Number of patients registered per site				
≤10	129 (86.0%)	21 (14.0%)	6.023 (2.015–18.005)	0.001
11–20	78 (87.6%)	11 (12.4%)	1.266 (1.609–16.926)	0.006
>20	148 (97.4%)	4 (2.6%)	Reference	
Age category (years)				
≤40	147 (96.1%)	6 (3.9%)	Reference	
41–60	167 (92.8%)	13 (7.2%)	1.907 (0.707–5.145)	0.202
>60	41 (70.7%)	17 (29.3%)	10.159 (3.763–27.421)	<0.001
Body mass index category (kg/m <sup>2</sup> )				
≤25	202 (92.7%)	16 (7.3%)	Reference	
26–30	79 (86.8%)	12 (13.2%)	1.918 (0.868–4.236)	0.107
>30	74 (90.2%)	8 (9.8%)	1.365 (0.561–3.322)	0.493
ECOG performance status				
0	340 (91.2%)	33 (8.8%)	Reference	
1	15 (83.3%)	3 (16.7%)	2.061 (0.567–7.486)	0.272
Open surgery				
No	245 (93.2%)	18 (6.8%)	Reference	
Yes	110 (85.9%)	18 (14.1%)	2.227 (1.116–4.445)	0.023
Tumour size				
≤2 cm	235 (91.8%)	21 (8.2%)	Reference	
>2 cm	119 (88.8%)	15 (11.2%)	1.411 (0.702–2.836)	0.334
Tumour type				
Squamous cell	250 (90.3%)	27 (9.7%)	Reference	
Adenocarcinoma	98 (93.3%)	7 (6.7%)	0.661 (0.279–1.568)	0.348
Adenosquamous	7 (77.8%)	2 (22.2%)	2.646 (0.523–13.379)	0.239
Lymphovascular space invasion				
Yes	114 (95.0%)	6 (5.0%)	Reference	
No	230 (91.6%)	21 (8.4%)	1.735 (0.681–4.417)	0.248

OR, odds ratio; CI, confidence interval; ECOG, Eastern Cooperative Oncology Group.

detection frequency between the tracers was less than reported in previous smaller studies [31–34].

For surgical pelvic exploration, knowledge of the anatomical regions with a high probability of SLN localisation is crucial. Unnecessary dissection can lead to retroperitoneal fibrosis and increases the risk of postoperative complications. Our data indicate that the majority of SLN are localised in two main regions: the external iliac region and the interiliac region between the external and internal iliac vessels. Both of these regions are caudal to the iliac vessel bifurcation. The mapping of positive SLN corresponded to the overall distribution of detected SLN. No SLN was found outside the seven standard anatomical regions of the pelvis. Some earlier studies suggested that 2%–5% of SLN are atypically localised, but the regions were not consistently defined [19,35]. In our trial, the presacral and common iliac regions were considered as part of

Level II of the pelvis (between the aortic and iliac vessel bifurcations). Importantly, no SLN was found in the paraaortic region. We hypothesise that improvements in SLN detection techniques have resulted in more reliable detection in the pelvis. This trend in diminishing proportion of cases with extra-pelvic SLN localisation is apparent in two consecutive studies from France, in which paraaortic localisation of SLN was reported in 5% of patients in the older study and in 1.5% of patients in a combined analysis of both trials [35,36]. It is very unlikely that lymphatic channels from the cervix skip the whole pelvic region and lead directly to the paraaortic region. Importantly, only seven patients (2%) in our trial had isolated positive SLN in anatomical Level II of the pelvis. Therefore, surgeons should pay particular attention to the two regions below the iliac vessel bifurcation.

In conclusion, the SENTIX trial showed that a bilateral SLN detection of over 90% can be achieved in sites with good experience in SLN biopsy techniques. Bilateral detection was less frequent in older patients and in sites that registered fewer patients. Most SLN are localised in the two anatomical regions below the iliac vessel bifurcation, and positive SLN are very rarely (2%) localised above this anatomical landmark (i.e. in Level II). SLN intraoperative evaluation fails to detect about 50% of metastatic cases if both macrometastases and micrometastases are considered LN positive.

#### Author contributions

The trial protocol was designed by D.C. K.N. and P.D. processed and reviewed the histological materials provided by the trial sites and guaranteed the quality of the central pathologic evaluation. D.C. wrote the first draft of the manuscript, which was then critically reviewed and revised by the other authors. All authors contributed to patient enrolment, and data acquisition, were involved in writing and revising the manuscript and gave final approval of the manuscript. J.J. performed data cleaning, interpretation and final statistical analysis.

#### Funding source

The Czech Research Council (NV19-03-00023).

#### Data sharing

Qualified researchers can request access to study documents (study protocol and amendments, statistical analysis plan, informed consent form) and individual anonymised patient data related to the secondary endpoints reported in this publication. Data requests will be reviewed and approved by the SENTIX trial Steering Committee. Requests should be submitted to the corresponding author.

#### Conflict of interest statement

The authors declare no conflict of interest.

#### Acknowledgements

The authors would like to acknowledge the investigators from all 47 sites participating in the SENTIX trial (Adamik Zdenek, Department of Obstetrics and Gynecology, KNTB a.s Zlin, Czech Republic; Cadron Isabelle, AZ Turnhout, Turnhout, Belgium; Cornez Nathalie, CHU Ambroise Pare, Mons, Belgium; Coronado Martin Pluvio Jesus, Hospital Clinico San Carlos, Madrid, Spain; de Santiago Garcia Francisco Javier, MD Anderson Cancer Center, Madrid, Spain; Dostalek Lukas, Gynecologic Oncology Center, Department of

Obstetrics and Gynecology, First Faculty of Medicine, Charles University and General University Hospital, Prague, Czech Republic; Dundr Pavel, Institute of Pathology, First Faculty of Medicine, Charles University and General University Hospital, Prague, Czech Republic; Fastrez Maxime, CHU Saint Pierre, Brussels, Belgium; Germanová Anna, Gynecologic Oncology Center, Department of Obstetrics and Gynecology, First Faculty of Medicine, Charles University and General University Hospital, Prague, Czech Republic; Gil-Ibanez Blanca, Unit of Gynecological Oncology, Institute Clinic of Gynaecology, Obstetrics and Neonatology, Hospital Clinic-Institut d'Investigacions Biomediques August Pi i Sunyer (IDIBAPS), University of Barcelona, Barcelona, Spain; Giuliani Daniela, Department of Obstetrics and Gynecology, Unit of Gynecologic Oncology Surgery, San Gerardo Hospital, Monza, Italy; Haidopoulos Dimitrios, Alexandra Hospital, Athens, Greece; Hryhorenki Andriy, Podilskyy Regional Oncological Centre, Vinnytsia, Ukraine; Kridelka Frederic, CHU de Liege, Notre Dame des Bruyeres, Belgium; Luyckx Mathieu, Saint-Luc University Clinics, Brussels, Belgium; Martinelli Fabio, Gynecologic Oncology Department; Fondazione IRCCS Istituto Nazionale Tumori – Milan, Milan, Italy; Martinez Martin Alicia, Department of Gynecologic Oncology, University Hospital of the Canary Islands, Las Palmas de Gran Canaria, Spain; Novotny Zdenek, University Hospital Pilsen, Pilsen, Czech Republic; Paderno Mariachiara; Department of Obstetrics and Gynecology, Unit of Gynecologic Oncology Surgery, San Gerardo Hospital, Monza, Italy; Poka Robert, University of Debrecen, Department of Obstetrics and Gynaecology, Debrecen, Hungary; Sawicki Sambor, Department of Gynecology, Gynecologic Oncology and Gynecologic Endocrinology, Medical University of Gdansk, Poland; Sebastia Jordi Ponce, Hospital Universitari de Bellvitge, Barcelona, Spain; Smrkolj Spela, University Medical Centre Ljubljana, Ljubljana, Slovenia; Staringer Juan Carlos, Hospital Espanol de Buenos Aires, Caba, Argentina and Hospital de Alta Complejidad de Formosa, Formosa, Argentina; Szweczyk Grzegorz, Institute of Mother and Child, Department of Gynecology and Obstetrics, Warsaw, Poland; Szymczak Paulina, Department of Gynecology, Gynecologic Oncology and Gynecologic Endocrinology, Medical University of Gdansk, Poland; Tamussino Karl, Medical University of Graz, Graz, Austria; Toth Robert, Oncology Institute of East Slovakia, Košice, Slovakia; Tummers Philippe, University Hospital Gent, Belgium; Marcin Misiek, Department of Gynecologic Oncology, Holycross Cancer Center, Kielce, Poland) and members of the Steering Committee (Dusek Ladislav, Institute of Biostatistics and Analyses, Masaryk University, Brno, Czech Republic; Kucukmetin Ali, Northern Gynaecological Oncology Centre, Queen Elizabeth Hospital, Gateshead, UK; Querleu Denis,

Institut Bergonie, Bordeaux, France; van der Zee Ate, University Medical Center, Groningen, The Netherlands). They also thank all of the medical specialists, data and case managers, secretaries, study coordinators and other people involved in the SENTIX trial.

## Appendix A. Supplementary data

Supplementary data to this article can be found online at <https://doi.org/10.1016/j.ejca.2020.06.034>.

## References

- [1] Cibula D, Pötter R, Planchamp F, et al. The European society of gynaecological Oncology/European society for radiotherapy and Oncology/European society of pathology guidelines for the management of patients with cervical cancer. *Virchows Arch* 2018;472:919–36.
- [2] National Comprehensive Cancer Network. NCCN clinical practice guidelines in Oncology (NCCN Guidelines®) cervical cancer. 2020. January 14, 2020. Available at: Version 1. [https://www.nccn.org/professionals/physician\\_gls/pdf/cervical.pdf](https://www.nccn.org/professionals/physician_gls/pdf/cervical.pdf). [Accessed 21 April 2020].
- [3] Biglia N, Librino A, Ottino M, Panuccio E, Daniele A, Chahin A. Lower limb lymphedema and neurological complications after lymphadenectomy for gynecological cancer. *Int J Gynecol Canc* 2015;25:521–5.
- [4] Hareyama H, Hada K, Goto K, et al. Prevalence, classification, and risk factors for postoperative lower extremity lymphedema in women with gynecologic malignancies: a retrospective study. *Int J Gynecol Canc* 2015;25:751–7.
- [5] Dargent D, Martin X, Mathevet P. Laparoscopic assessment of the sentinel lymph node in early stage cervical cancer. *Gynecol Oncol* 2000;79:411–5.
- [6] Brown J, Sawaya G, Thom D, Grady D. Hysterectomy and urinary incontinence: a systematic review. *Lancet* 2000;356:535–9.
- [7] Niikura H, Okamoto S, Otsuki T, et al. Prospective study of sentinel lymph node biopsy without further pelvic lymphadenectomy in patients with sentinel lymph node–negative cervical cancer. *Int J Gynecol Canc* 2012;22:1244–50.
- [8] Cibula D, Dusek J, Jarkovsky J, et al. A prospective multicenter trial on sentinel lymph node biopsy in patients with early-stage cervical cancer (SENTIX). *Int J Gynecol Canc* 2019;29:212–5.
- [9] Vergote I, Pujade-Lauraine E, Pignata S, et al. European Network of Gynaecological Oncological Trial Groups' requirements for trials between academic groups and pharmaceutical companies. *Int J Gynecol Canc* 2010;20:476–8.
- [10] Cibula D, Abu-Rustum N. Pelvic lymphadenectomy in cervical cancer—surgical anatomy and proposal for a new classification system. *Gynecol Oncol* 2010;116:33–7.
- [11] International Union against Cancer (UICC). In: Sobin LH, Gospodarowicz MK, Wittekind CH, editors. TNM classification of malignant tumours. 7th ed. New York: Wiley; 2009.
- [12] Dunder P, Cibula D, Němejcová K, Tichá I, Bártů M, Jakša R. Pathologic protocols for sentinel lymph nodes ultrastaging in cervical cancer. *Arch Pathol Lab Med* 2019. <https://doi.org/10.5858/arpa.2019-0249-RA>.
- [13] Cibula D, Abu-Rustum N, Dusek L, et al. Bilateral ultrastaging of sentinel lymph node in cervical cancer: lowering the false-negative rate and improving the detection of micrometastasis. *Gynecol Oncol* 2012;127:462–6.
- [14] Wydra D, Sawicki S, Wojtylak S, Bandurski T, Emerich J. Sentinel node identification in cervical cancer patients undergoing transperitoneal radical hysterectomy: a study of 100 cases. *Int J Gynecol Canc* 2006;16:649–54.
- [15] Altgassen C, Hertel H, Brandstädt A, Köhler C, Dürst M, Schneider A. Multicenter validation study of the sentinel lymph node concept in cervical cancer: AGO Study Group. *J Clin Oncol* 2008;26:2943–51.
- [16] Rob L, Robova H, Halaska MJ, Hrudá M, Skapa P. Current status of sentinel lymph node mapping in the management of cervical cancer. *Expert Rev Anticancer Ther* 2013;13:861–70.
- [17] Balaya V, Bresset A, Guani B, et al. Risk factors for failure of bilateral sentinel lymph node mapping in early-stage cervical cancer. *Gynecol Oncol* 2020;156:93–9.
- [18] Zarganis P, Kondi-Pafiti A, Arapantoni-Dadioti P, et al. The sentinel node in cervical cancer patients: role of tumor size and invasion of lymphatic vascular space. *In Vivo* 2009;23:469–73.
- [19] Salvo G, Ramirez P, Levenback C, et al. Sensitivity and negative predictive value for sentinel lymph node biopsy in women with early-stage cervical cancer. *Gynecol Oncol* 2017;145:96–101.
- [20] Dostálek L, Zikan M, Fischerova D, et al. SLN biopsy in cervical cancer patients with tumors larger than 2 cm and 4 cm. *Gynecol Oncol* 2018;148:456–60.
- [21] Cibula D, Abu-Rustum N, Dusek L, et al. Prognostic significance of low volume sentinel lymph node disease in early-stage cervical cancer. *Gynecol Oncol* 2012;124:496–501.
- [22] Lécuru F, Mathevet P, Querleu D, et al. Bilateral negative sentinel nodes accurately predict absence of lymph node metastasis in early cervical cancer: results of the SENTICOL study. *J Clin Oncol* 2011;29:1686–91.
- [23] Bats A, Buénerd A, Querleu D, et al. Diagnostic value of intraoperative examination of sentinel lymph node in early cervical cancer: a prospective, multicenter study. *Gynecol Oncol* 2011;123:230–5.
- [24] Slama J, Dunder P, Dusek L, Cibula D. High false negative rate of frozen section examination of sentinel lymph nodes in patients with cervical cancer. *Gynecol Oncol* 2013;129:384–8.
- [25] Du X, Sheng X, Jiang T, et al. Sentinel lymph node biopsy as guidance for radical trachelectomy in young patients with early stage cervical cancer. *BMC Canc* 2011;11:157.
- [26] Roy M, Bouchard-Fortier G, Popa I, et al. Value of sentinel node mapping in cancer of the cervix. *Gynecol Oncol* 2011;122:269–74.
- [27] Martínez A, Mery E, Filleron T, Boileau L, Ferron G, Querleu D. Accuracy of intraoperative pathological examination of SLN in cervical cancer. *Gynecol Oncol* 2013;130:525–9.
- [28] Deng X, Zhang Y, Li D, et al. Abdominal radical trachelectomy guided by sentinel lymph node biopsy for stage IB1 cervical cancer with tumors >2 cm. *Oncotarget* 2016;8:3422–9.
- [29] Papadia A, Morosi C, Wang J, et al. SLN mapping in early-stage cervical cancer as a minimal-invasive triaging tool for multimodal treatment. *Eur J Surg Oncol* 2019;45:679–83.
- [30] Rychlik A, Angeles M, Migliorelli F, et al. Frozen section examination of sentinel lymph nodes can be used as a decisional tool in the surgical management of early cervical cancer. *Int J Gynecol Canc* 2020;30:358–63.
- [31] Imboden S, Papadia A, Nauwerk M, et al. A comparison of radiocolloid and indocyanine green fluorescence imaging, sentinel lymph node mapping in patients with cervical cancer undergoing laparoscopic surgery. *Ann Surg Oncol* 2015;22:4198–203.
- [32] Di Martino G, Crivellaro C, De Ponti E, et al. Indocyanine green versus radiotracer with or without blue dye for sentinel lymph node mapping in stage >IB1 cervical cancer (>2 cm). *J Minim Invasive Gynecol* 2017;24:954–9.
- [33] Lührs O, Ekdahl L, Lönnfors C, Geppert B, Persson J. Combining Indocyanine Green and Tc99-nanocolloid does not

- increase the detection rate of sentinel lymph nodes in early stage cervical cancer compared to indocyanine green alone. *Gynecol Oncol* 2020;156:335–40.
- [34] Buda A, Crivellaro C, Elisei F, et al. Impact of indocyanine green for sentinel lymph node mapping in early stage endometrial and cervical cancer: comparison with conventional radiotracer <sup>99m</sup>Tc and/or blue dye. *Ann Surg Oncol* 2015;23:2183–91.
- [35] Bats A, Mathevet P, Buenerd A, et al. The sentinel node technique detects unexpected drainage pathways and allows nodal ultra-staging in early cervical cancer: insights from the multicenter prospective SENTICOL study. *Ann Surg Oncol* 2012;20:413–22.
- [36] Balaya V, Mathevet P, Magaud L, et al. Predictive factors of unexpected lymphatic drainage pathways in early-stage cervical cancer. *Gynecol Oncol* 2019;154:102–9.