

New Imaging Tracers for the Infected Diabetic Foot (Nuclear and Optical Imaging)

Alfred O. Ankrah^{1,2}, Hans C. Klein¹ and Philip H. Elsinga^{1,*}

¹University of Groningen, University Medical Center Groningen, Department of Nuclear Medicine and Molecular Imaging, Groningen, The Netherlands; ²University of Pretoria, Steve Biko Academic Hospital, Department of Nuclear Medicine, Pretoria, South Africa

Abstract: Diabetic foot infections (DFIs) are associated with increased morbidity, an economic burden on patients, their families and healthcare systems and increased mortality. Early diagnosis with prompt, appropriate and adequate treatment of the infected diabetic foot is crucial. The determination of DFIs, however, may be quite perplexing and invasive. Imaging is useful in the evaluation of certain cases of DFIs, especially in suspected instances with no overt clinical features, or in the diagnosis of osteomyelitis. Nuclear medicine imaging is currently used in the evaluation of DFIs; however, like all the imaging techniques now available, it has its limitations. Several radiopharmaceuticals presently available play useful roles in the management of DFIs, while new ones are being evaluated. Optical imaging techniques have recently demonstrated promising results in the evaluation of many infections including DFIs. Using the same molecule, a tracer can be labeled with a radioisotope or an optical imaging dye. This enables infections to be evaluated both pre- and intra-operatively when surgery is required in their management. In some cases, tracers have been simultaneously labeled with both a radioisotope and an optical imaging dye to produce a hybrid tracer. These new tracers potentially provide powerful and new opportunities in the management of DFIs. In this review, we briefly examine tracers that have been used in the evaluation of the infected diabetic foot. We then explore the potential of new imaging tracers currently under development for infection that may be useful in the management of DFIs.

Keywords: Optical imaging, radiopharmaceuticals, diabetic foot infections, nuclear medicine, osteomyelitis, SPECT/CT, PET/CT, bacteria-specific imaging.

1. INTRODUCTION

Diabetic foot infections (DFIs) have high morbidity and are associated with a high financial burden on patients, their relatives, and healthcare delivery systems worldwide [1]. DFIs also frequently result in lower extremity amputation, which has been associated with increased mortality [2]. The worldwide prevalence of diabetes mellitus (DM) is estimated to be 425 million, far exceeding previous estimates, with an exponential increase projected in the coming years [3, 4]. The foot of patients with DM may be complicated by neuropathy and peripheral artery disease. These conditions frequently lead to a pedal ulcer, which is the usual portal of entry of infection in the diabetic foot. A pedal ulcer in a diabetic patient is the most common risk factor for amputation. The risk of amputation and other morbidities associated with DFIs make the diagnosis of the infection crucial [5]. Furthermore, osteomyelitis which may be present in DFIs and it is frequently overlooked [6]. Diabetic foot osteomyelitis (DFO) is associated with increased and prolonged hospitalization, and the risk of amputation. If DFIs are not recognized early and prompt appropriate treatment is not started, mortality may occur due to overwhelming sepsis. [7]. In the evaluation of the diabetic foot by metabolic imaging, the clinician usually wants to know whether there is an infection, and if an infection is present whether it involves only the soft tissue or if there is an associated osteomyelitis. If the infection is limited to soft tissue, the clinician wants to know whether abscesses, gangrene and other features that suggest a complicated infection are present, as these would require surgical intervention [8]. Imaging plays an important role in assess-

ing the diabetic foot. In this review, we give a brief overview of imaging agents that have been evaluated or used in DFIs. We then focus on the new or emerging tracers that would potentially play a role in the management of DFIs.

1.1. Diagnosis of DFIs

1.1.1. Clinical Diagnosis

The diagnosis of DFIs is essentially clinical [9]. The presence of two classic signs of inflammation in a patient with DM often in the presence an ulcer establishes the diagnosis. A DFI may also be diagnosed when a diabetic ulcer is discharging purulent fluid. Unfortunately, many factors may confound the diagnosis of a DFI. Clinical diagnosis may not be able to determine if there is osteomyelitis present. In some cases, the ulcers overlying an infected bone may have healed resulting in a DFO with no overlying ulcers. Clinical assessment can easily miss DFO in the absence of a pedal ulcer. Again, patients with DM may have neuro-osteoarthropathy or other pathology that may have signs of inflammation, which may mimic an infection even in the absence of a DFI. Furthermore, peripheral neuropathy or peripheral arterial disease may diminish the signs of inflammation of a DFI [10, 11]. Imaging assumes an important role in these intricate clinical scenarios.

1.1.2. Assessment of Osteomyelitis

Clinicians use the probe-to-bone test to determine the presence of DFO when it is suspected. In this test, after proper debridement of a wound, a sterile metal is probed into a diabetic pedal ulcer. If a hard, gritty surface is felt when the probe is moved in the wound, the test is said to be positive. This test, while being very helpful, has several limitations. The test is about sixty to eighty percent sensitive and has a relatively low negative predictive value [12, 13]. Furthermore, the inter-observer concordance is relatively low, especially, among inexperienced clinicians [14]. The pre-test probability

*Address correspondence to this author at the University of Groningen, University Medical Center Groningen, Department of Nuclear Medicine and Molecular Imaging, Groningen, The Netherlands;
E-mail: p.h.elsinga@umcg.nl

of osteomyelitis as determined by clinical data or imaging is important in the interpretation of the test [10]. Imaging is therefore valuable in evaluating patients with suspected DFO not only in the absence of pedal ulcers but also when pedal ulcers are present which is more common in the clinical setting.

1.1.3. Serum Inflammatory Markers

Serum inflammatory markers are useful supportive tools in the management of DFIs. These markers appear to be more useful in systemic infections and osteomyelitis. Like most other superficial infections, serum inflammatory markers do not appear to correlate with soft tissue infections in DFIs. The erythrocyte sedimentation rate (ESR) is useful in the evaluation of DFO, with values above 60-70mm fall per hour found to be a useful cut-off [11]. Procalcitonin and C-reactive protein demonstrated some usefulness in distinguishing uninfected ulcers from infected ones. However, these markers are not recommended as diagnostic tools, but rather they are used to support the diagnosis suspected DFIs [15]. Other serum inflammatory markers such as alkaline phosphate, bone sialoprotein, amino-terminal peptide, and cytokines have varying degrees of suitability in different situations in the evaluation of DFIs [16, 17].

1.1.4. Culture

The gold standard for infection diagnosis is the recovery of offending microorganism from a usually sterile site usually deep soft tissue or even bone. The method of collection of samples for culture in DFIs is crucial as colonized bacteria could easily contaminate it. The microbiologic culture of wound swabs and wound dressing, which are relatively easy may grow microorganisms, that colonize the wound or are present on the surrounding skin. Sampling deep soft tissues as in most infection is invasive but usually more representative [18]. The growth of the microorganism by culture allows drug susceptibility testing of these organisms to help in directing therapy. The results of culture may take at least two days to be available which is not ideal. The delay in identification and susceptibility testing leads to the initiation of empiric therapy which has been found to be inappropriate in a substantial proportion of patients worsening the already existing problem of microbial resistance. Moreover, in DFIs, there may be sampling errors in which the biopsy may miss the site of infection; on the other hand, the sampling method may result in contamination of the sample with microorganisms that colonize a diabetic ulcer.

1.1.5. Microscopy

Microscopy may identify the organisms earlier. However, the diagnostic yield tends to be lower than culture, and drug susceptibility testing is not possible.

1.1.6. Histology

In the evaluation of bone, histology may help establish the diagnosis of DFO. Histology sampling of bone is however also invasive [19]. Histological assessment of samples may not be standardized and may also be confounded by bone changes that can occur in DM patients in the absence of infection [10]. The results from histology must be combined with results from culture to identify the offending organism and identify susceptibility to antimicrobial therapy.

1.1.7. Molecular Techniques in Microbiology

Advances in microbiology have led to the use of molecular techniques that can determine parts of microorganisms such as their nucleic acid sequence. Microbiologic molecular techniques can differentiate colonizing organism from infective organisms. These molecular laboratory methods can provide results in minutes, detect molecular sequences that can predict drug resistance and even detect mutations that may have occurred in existing colonies [20]. These advances in microbiology open an entirely new chapter in the diagnosis of DFIs [21]. Molecular imaging has potential to complement these methods. Molecular imaging may determine the most appropriate biopsy site for the diagnosis by the microbiologic mo-

lecular techniques. Furthermore, the molecular characteristics of the microorganism detected by molecular techniques may be tagged with an imaging agent to provide an *in vivo* evaluation of the infection. The combination of molecular imaging with microbiology molecular techniques will provide a real-time assessment the infection. This may allow monitoring of therapy in DFIs and detect resistance much earlier than the currently available techniques.

1.1.8. Microorganism in DFIs

The most common microorganism present in acute uncomplicated DFIs with no previous exposure is gram-positive cocci of which *Staphylococcus aureus* (*S. aureus*) is the most predominant. *S. aureus* is present in about 30% of acute uncomplicated DFIs. This percentage rises to over 60% when osteomyelitis in DFIs is considered. In warmer tropical climates, or when patients have been previously exposed to antibiotic therapy, a polymicrobial flora is usually present with an increasing presence of gram-negative organisms such as the *Pseudomonas aeruginosa* (*P. aeruginosa*) and *Escherichia coli* (*E. coli*) [9]. When necrotic tissue is present, anaerobic bacteria are likely to be encountered. In addition to bacteria, other microorganisms such as fungi may cause superficial or deep infections in DFIs. The knowledge of the type of microorganisms occurring in DFIs is essential because the development of new tracers for infection imaging is increasingly moving in the direction of targeting specific organisms. This trend has both advantages and disadvantages. A specific tracer may miss another organism that may be the cause of infection or it may not visualize a particular organism when the microbe develops resistance to the mechanism of uptake of the tracer. On the other hand, once the microorganism is identified, imaging to localize infection, determine disease extension, pre-and intraoperative imaging, monitoring therapy and evaluating for recurrence of an infection can be done.

1.2. Current Imaging Practice for the Diabetic Foot

Several imaging modalities are available to the clinician to evaluate the infected diabetic foot. The plain radiograph of the foot should be the first imaging investigation requested and can provide information on both the bone and soft tissue. Early changes of osteomyelitis may not be detected, as it needs more than 30-50% of bone mineralization to be lost before changes are visible [22]. Magnetic resonance imaging (MRI) is currently considered to be the imaging modality of choice providing excellent anatomic resolution and also defining bone structures. This method is unable to reliably distinguish neuro-osteoarthropathy from osteomyelitis, and the procedure may be unsuitable for some patients with metallic prosthesis or who are claustrophobic. Nuclear medicine has been used to image diabetic foot with changes in the tracers used as newer tracers that are more specific for DFIs have emerged. A recent meta-analysis of the literature showed two of the currently used tracers [¹⁸F]fluorodeoxyglucose ([¹⁸F]FDG) and ^{99m}Tc-labeled white blood cells used as hybrid imaging usually integrated with computed tomography (CT) cells had similar sensitivity and even higher specificity than MRI [23].

1.3. Metabolic Imaging in DFIs

Nuclear medicine imaging has been used in the diagnosis of infections including DFIs for more than half a century [24]. The use of hybrid imaging and dual time point imaging has dramatically improved diagnostic accuracy in nuclear medicine evaluation of DFIs [7, 25]. Optical imaging provides a desirable alternative to imaging of infections [10]. Recent studies using optical imaging in infection have produced some promising results for diabetic wound healing and infection [26, 27]. The use of a radiopharmaceutical or optical imaging agent for evaluation of infection is dictated by some factors that include:

- Type, site and extent of infection
- Pathology of the infection

- Pathophysiology of concomitant conditions
- Clinical problem clinicians encounter in a particular infection

1.4. Nuclear Imaging Tracers

Many nuclear medicine tracers used in clinical medicine such as ^{99m}Tc -labeled bisphosphonates have the limitation of non-specificity. Others such as ^{67}Ga citrate have multiple gamma photons and require a long duration (48 hours or more) to complete imaging. As a result, tracers like ^{99m}Tc -labeled bisphosphonate and ^{67}Ga citrate have been supplanted by tracers such as ^{99m}Tc hexamethylpropyleneamine oxine (^{99m}Tc]HMPAO) labeled white blood cells or ^{18}F]FDG which are currently the most frequently used radiopharmaceuticals in the evaluation of DFIs. Some other less commonly used radiopharmaceuticals that have been used in DFIs include anti-granulocyte antibodies. Newer tracers such as ^{64}Cu -labeled white blood cells have been evaluated. Tracers such as ^{68}Ga citrate as a PET tracer and specific antibiotic labeled radiotracers may be useful in imaging DFIs. Many tracers that hold promise in infections in general and most likely DFIs are still in the preclinical stage. The radiopharmaceuticals that have been used or evaluated for the role of infection with emphasis on DFIs have been summarized in Table 1 and discussed below.

1.4.1. ^{99m}Tc -labeled Bisphosphonates

Bone scintigraphy using ^{99m}Tc -labeled bisphosphonates was used in the past for evaluating the diabetic foot. Soft tissue infections were distinguished from bone infection by doing a 3-phase bone scan and finding a positive first and second phase for soft tissue with mild or no uptake on the third phase while with osteomyelitis it was positive on all three phases. The bone scan is sensitive for detecting osseous pathology but is not specific to DFIs. Many conditions in a diabetic foot may mimic osteomyelitis on diabetic foot, so bone scintigraphy is no longer used to evaluate osteomyelitis in DFIs. Bone scan has been used in combination with other tracers such as radiolabeled white blood cells or radiolabeled antimicrobial peptides in an attempt to increase specificity or to exclude osteomyelitis [28, 29]. With the use of hybrid imaging and the advent of more specific tracers, the incremental value of the bone scintigraphy is minimal and is no longer recommended [6].

1.4.2. ^{67}Ga citrate

^{67}Ga citrate has been used in combination with bone scintigraphy in the evaluation of diabetic foot. The interpretation is based on both the intensity and spatial distribution of the two tracers. If there was more intense tracer uptake on the ^{67}Ga citrate but spatially congruent with the bone scan or if there was spatial incongruence between the ^{67}Ga citrate and the bone scan it was considered positive. The multiple gamma rays emitted by ^{67}Ga results in high radiation burden and the need to wait at least 24 hours post-injection is undesirable. Also, the resulting sensitivities and specificities for DFIs were modest at best. This led to the replacement of this agent with agents with more favorable characteristics. Using SPECT/CT and bedside percutaneous biopsy some investigators used ^{67}Ga citrate to diagnose or exclude osteomyelitis in patients with suspected DFIs in the absence of soft tissue infection. This prevented unnecessary use of antibiotics in more than half of the patients studied [30].

1.4.3. ^{99m}Tc]HMPAO or ^{111}In]Oxine Labeled White Blood Cells

The most common tracer being currently in DFIs is radiolabeled white blood cells that accumulate at the infectious sites as a result of the immune response. ^{99m}Tc]HMPAO labeling is more often used than ^{111}In]Oxine [31, 32]. This imaging method (leukocyte-SPECT) is specific for infection imaging; however, the leukocyte labeling procedure is quite laborious and time-consuming as it requires dual-time-point imaging with SPECT/CT. Furthermore, the procedure requires the manipulation and re-injection of blood products which carries the risk of transmission of highly infectious

agent originating from body fluids to both the patient and the personnel involved in the labeling process. Radiolabeled white blood cells may accumulate at sites of sterile inflammation, and ^{99m}Tc -sulphur colloid has been shown to improve the sensitivity. A criterion for imaging radiolabeled white blood cells without any additional tracer using early and late (24 hours) time point with decay correction and semi-quantitative analysis has been developed and validated for infection imaging [33, 34]. This criterion has led to the improved specificity of the radiolabeled blood cell imaging of infection and been used in DFIs [35].

1.4.4. ^{18}F]FDG-PET/CT

^{18}F]FDG-PET offers advantages over leukocyte-SPECT; there is no manipulation with blood, short acquisition time and high image resolution [36]. ^{18}F]FDG has been used extensively in the management of cancer. In last decade ^{18}F]FDG has been increasingly used to image inflammatory processes. ^{18}F]FDG is easily available through distribution networks and can be produced daily in high amounts. The main disadvantage is that ^{18}F]FDG as an infection imaging agent is that it is a not specific and will accumulate in other pathology. There is currently no consensus how to discriminate bacterial infection from other causes of increased ^{18}F]FDG uptake. A recent meta-analysis demonstrated ^{18}F]FDG-PET/CT to be as sensitive as radiolabeled white cells with and also found a higher specificity than MRI for osteomyelitis in DFIs [23].

1.4.5. Anti-granulocyte Monoclonal Antibody Fragments

An alternative to radiolabeled leukocytes that are labeled *in vitro* are the anti-granulocyte antibodies resulting in *in vivo* labeling of leukocytes. The obtained results are comparable to imaging results from leukocytes without handling, manipulation, and reintroduction of the patient's blood [37-39]. These have been used in the clinical setting but have not gained prominence probably due to the cost and the withdrawal of one of such agents from the market due to adverse events [40].

1.5. Potential Improvements of Currently Used Imaging Agents for the Diabetic Foot

1.5.1. ^{64}Cu -radiolabeled White Blood Cells

To address part of the limitations of the traditional imaging agents, potential improvements can be made to existing tracers. As an example, PET imaging has the advantage of better spatial resolution over SPECT imaging. Radiolabeled leukocyte-based imaging may be improved by radiolabeling the leukocytes with the PET-radionuclide ^{64}Cu . Dual-time-point imaging on consecutive days which has been validated with SPECT tracers can be done with ^{64}Cu labeled leukocytes PET/CT because of ^{64}Cu 's half-life of 12.7 hours [33, 34]. An exploratory study demonstrated the labeling efficiency of ^{64}Cu -leukocytes was comparable to ^{111}In -leukocytes, but leakage from the cells was somewhat higher for ^{64}Cu [41]. The amount of ^{64}Cu retained in the labeled leukocyte however is sufficient to justify the use of this tracer in the clinical setting.

1.5.2. ^{68}Ga citrate PET/CT

Again, the use of ^{68}Ga citrate to substitute ^{67}Ga citrate is another logical choice based on the better resolution of PET over SPECT. ^{68}Ga citrate has already been tested in 31 patients with bone infection, and overall accuracy of 90% was observed [42]. The anatomic localization provided by the CT component of the study allows PET/CT with ^{68}Ga citrate to discriminate between bone and soft tissue uptake. This is important in DFIs as in determining whether the is osteomyelitis present. ^{68}Ga citrate, however, is not specific and accumulates in malignancy and other non-infective inflammatory processes [43]. ^{68}Ga citrate has potential to become a widely used tracer due to the availability of Good manufacturing practice (GMP) compliant ^{68}Ga -generators and the relative ease of preparation of tracer within nuclear medicine facilities [44].

Table 1. Table summarizing past, current and potential tracers for imaging DFIs.

Molecule	Label	Tracer Used at the Clinical Stage	Organisms to be Imaged/ Process Imaged	Remarks	Author (Year) Journal
Tracers used currently or previously in DFIs					
Bisphosphonates	^{99m} Tc	Yes	No specific organism/ osteoblastic reaction of bone due to infection	Replaced by more specific tracer	Palestro <i>et al.</i> (2009) Semin Nucl Med [6]
Citrate	⁶⁷ Ga	Yes	No specific organism/ iron carrying proteins like transferrin and siderophores at sites of infection	Replaced by more specific agent with better dosimetry properties	Palestro <i>et al.</i> (2009) Semin Nucl Med [6]
Radiolabeled WBCs	^{99m} Tc, ¹¹¹ In	Yes	No specific organism/ WBC accumulation at infected sites	Widely used tracer, proven usefulness in DFIs	Familiari <i>et al.</i> (2011) J Nucl Med [35]
FDG	¹⁸ F	Yes	No specific organism/ increased glucose utilization by inflammatory cells	Widely used tracer, proven usefulness DFIs	Familiari <i>et al.</i> (2011) J Nucl Med [35]
Anti-granulocytes monoclonal antibody fragment	^{99m} Tc	Yes	No specific organism/ WBC accumulation at infected sites	Not widely available, proven usefulness in DFIs	Dominguez-Gadea <i>et al.</i> (1993) Nucl Med Commun [39]
Potential tracers based on tracers that are currently in use or previously used					
Radiolabeled white blood cells	⁶⁴ Cu	-	No specific organism/ WBC accumulation at infected sites	Human WBC labeled but no imaging done	Bhargava <i>et al.</i> (2009) Nucl Med Biol [41]
Citrate	⁶⁸ Ga	Yes	No specific organism/ iron carrying proteins like transferrin and siderophores at sites of infection	Evaluated in osteomyelitis but not specifically in DFIs	Nanni <i>et al.</i> (2010) J Nucl Med [42]
Tracers imaging specific inflammatory response					
AMPs					
UBI 29-41	^{99m} Tc, ⁶⁸ Ga, ¹¹¹ In ICG02, MPA Cy5, NP	Yes (^{99m} Tc and ⁶⁸ Ga only)	Wide array of gram-positive, gram-negative bacteria and fungi, ⁶⁸ Ga UBI 29-41 showed some specificity to <i>S. aureus</i>	^{99m} Tc-UBI 29-41 has been used in DFIs, ⁶⁸ Ga citrate used in imaging infections in humans.	Assadi <i>et al.</i> (2011) Nucl Med Commun [61]
Other AMPs	^{99m} Tc	No	Array of bacteria		Welling <i>et al.</i> Eur J Nucl Med (2000) [67]
Cytokines	¹²³ I, ¹²⁵ I	No	Tested in <i>S. aureus</i> and <i>E. coli</i> infected animals	Not being vigorously pursued as an infection tracer.	Signore <i>et al.</i> (2000) Cytokine [70]
Tracers imaging substances released from or presented by bacteria					
Radiolabeled antibiotics					
Ciprofloxacin	^{99m} Tc	Yes	Wide spectrum of gram-positive and gram-negative bacteria/ DNA gyrase inhibitor but factors affecting uptake poorly understood. <i>S. aureus</i> and <i>E. coli</i> were the commonest organisms detected in a study specifically for DFIs	Variable results with different bacteria in different studies. Sensitivity and specificity of 66.7% and 85.7% respectively for the diagnosis of DFIs	Britton <i>et al.</i> (2002) J Clin Pathol [76] Dutta <i>et al.</i> (2006) Foot Ankle Int [77]

Molecule	Label	Tracer Used at the Clinical Stage	Organisms to be Imaged/ Process Imaged	Remarks	Author (Year) Journal
Other e.g. sitafloxacin	^{99m} Tc ¹⁸ F ⁶⁸ Ga	No	<i>S. aureus</i> is biological target/ DNA gyrase inhibitor	Tracers can distinguish between infection and inflammation. Sitafloxacin has highest target-to-nontarget ratio	Qaiser <i>et al.</i> (2010) J Radioanal Nucl Chem [78]
Trimethoprim	¹⁸ F	No	<i>S. aureus</i> , <i>E. coli</i> , <i>P. aeruginosa</i> / folic acid synthesis inhibitor	High target-to-background	Sellmyer <i>et al.</i> (2017) PNAS [79]
Sulfonamides	^{99m} Tc	No	<i>S. aureus</i> / inhibits folic acid synthesis	Uptake was 2-fold higher in infected muscle	Essouissi <i>et al.</i> (2015) Radiochemistry [80]
Vancomycin	^{99m} Tc IRD-ye800CW	No	<i>S. aureus</i> / inhibition of bacterial cell wall synthesis	Specific for gram-positive not gram negative	van Oosten <i>et al.</i> (2013) Nat Commun [81]
Beta-lactam based agents	^{99m} Tc	No	Gram-positive and gram-negative bacteria/ bacteria cell wall synthesis inhibition	Labeling in some cases uses direct method giving rise to a mixture of compounds and unpredictable behavior	Shahzadi <i>et al.</i> (2015) Arabian J Chem [83]
Puromycin	⁶⁸ Ga, ¹⁸ F	No	<i>S. aureus</i> for ⁶⁸ Ga compound/ protein synthesis inhibitor	Biological evaluation of the ¹⁸ F compound is still pending	Eigner <i>et al.</i> (2013) J Nucl Med [85]
Aminoglycoside	^{99m} Tc	No	<i>S. aureus</i> for kanamycin/ protein synthesis inhibition with irreversible uptake of tracer	Direct labeling resulting in mixture of compounds	Ercan <i>et al.</i> (1992) Int J Rad Appl Instr [88]
Doxycycline	^{99m} Tc	No	<i>E. coli</i> /protein synthesis inhibition	Further studies needed to see if it selectively images bacterial infections	Ozdemir <i>et al.</i> (2014) J. Lab Compnds Radiopharm [91]
Lincosamides	^{99m} Tc	No	<i>S. aureus</i> / protein synthesis inhibition	^{99m} Tc labeled erythromycin a member of this class showed uptake in inflammatory lesions	Hina <i>et al.</i> (2014) Appl Biochem Biotechnol [92]
Oxazolidinones	¹³¹ I	No	<i>S. aureus</i> / protein synthesis	5-fold higher in infection compared to control	Lambrecht <i>t al.</i> (2009) J Radioanal Nucl Chem [94]
Nitrofurantoin	^{99m} Tc	No	No specific bacteria published/protein synthesis	-	Shah <i>et al.</i> (2010) J Radioanalytical Nucl Chem [95]
Rifampicin	^{99m} Tc, ¹¹ C	No	An anti-mycobacterial agent but has activity against <i>S. aureus</i> / RNA synthesis inhibitors	May be useful in other infections	Işeri <i>et al.</i> (1991) Boll Chim Farm [96]
Tracers imaging substances presented by bacteria other than antibiotics					
Nucleoside analogues (FIAU)	¹²⁴ I, ¹²⁵ I	Yes	<i>S. aureus</i> / substrate for bacteria thymidine kinase	Initial studies in a small group of patients was promising but a more recent study showed poor images in prosthetic joints	Diaz <i>et al.</i> (2007) PLoS One [100]
Zinc-dipicolylamine	¹¹¹ In, Cy5, NIR dye	No	Wide range of gram-positive and gram-negative bacteria/ positively charged molecule interacts with bacteria	The tracer also binds to apoptotic and necrotic mammalian cells.	Liu <i>et al.</i> (2012) Nucl Med Biol [103]
Concanavalin A	NIR dye IR750	No	Gram-positive and gram-negative bacteria/ lectin-binding protein with high affinity for cell-surface residues	Advantage is the tracer is applied superficially	Tang <i>et al.</i> (2014) J Biomed Nanotechnol [105]

Molecule	Label	Tracer Used at the Clinical Stage	Organisms to be Imaged/ Process Imaged	Remarks	Author (Year) Journal
Prothrombin	⁶⁴ Cu, Alex-aFluor680	No	<i>S. aureus</i> / activation of prothrombin by staphylocoagulase	Developed for endocarditis	Panizzi <i>et al.</i> (2011) Nat Med 2011 [106]
Peptidoglycan aptemers	^{99m} Tc	No	<i>S. aureus</i> / complex molecule specific to outer membrane of bacteria cell wall	Capable of distinguishing <i>S. aureus</i> from fungal infections (<i>Candida sp.</i>)	Ferreira <i>et al.</i> (2017) Biomed Pharmacother [109]
Siderophores	⁶⁸ Ga	No	<i>Aspergillus sp.</i> and bacteria/ a siderophore -an iron concentrating protein unique to fungi and bacteria	TAFC has shown excellent imaging features for <i>Aspergillus sp.</i>	Petrik <i>et al.</i> (2017) Clin Transl Imaging [110]
Bacteria specific antibodies	⁶⁴ Cu	No	<i>Yersinia sp., P. aeruginosa/ antibodies</i>	More research to produce smaller molecules with a better imaging profile needed	Wiehr <i>et al.</i> (2016) Oncotarget 2016 [111]
Bacteriophage	^{99m} Tc,	No	<i>E. coli</i> high affinity for <i>E. coli</i>	By modifying it can be applied to different bacteria and different methods such as FRET can be used in imaging	Hernandez <i>et al.</i> (2014) Nat Med 2014 [115]
Tracers imaging metabolites of bacteria					
Bacteria carbohydrates					
Glucose-6-phosphate	NBD fluorescent dye	No	Specific bacteria/ transported UHPT which is only present in certain bacteria including <i>E. coli</i> and <i>S. aureus</i>	Was also labeled with NIR-dye was unable to image bacteria	O'Neil <i>et al.</i> (2005) Mol Imaging Biol [118]
Sorbitol	¹⁸ F,	Yes	Gram-negative bacteria <i>E. coli, Klebsiella pneumonia, P. aeruginosa/</i> metabolite used by these bacteria	No fluorescent analogues are currently available	Weinstein <i>et al.</i> (2014) Sci Transl Med [119]
Amino sugars	¹⁸ F	No	<i>E. coli</i> / component of cell wall of gram-positive and gram-negative bacteria	Can discriminate infection from inflammation	Martinez <i>et al.</i> (2011) Nucl Med Biol [121]
Maltohexaose	NIR dye IR786, ¹⁸ F	No	Both gram-positive and gram-negative bacteria	Can discriminate between dead and life bacteria and can as low as 10 ⁵ colonies in vivo	Huang <i>et al.</i> (2015) Anal Chem [123]
D-mannitol	¹⁸ F, ³ H	No	<i>S. aureus</i> and <i>E. coli</i> Used as an energy source in some bacteria or intermediate product of energy metabolism		Ordonez <i>et al.</i> (2017) J Nucl Med [53]
Vitamins					
Biotin	¹¹¹ In, ¹⁸ F	No	Possibly <i>S. aureus</i> , involved in fatty acid synthesis	Selective uptake in <i>S. aureus</i> colonies	Shoup <i>et al.</i> (1994) J Nucl Med [130]
Vitamin B12 derivative	^{99m} Tc	No	<i>S. aureus, E. coli</i> accumulates in rapidly proliferating cells for trans-methylation reaction	Discriminates infection from inflammation with high target -to-nontarget ratios	Baldoni <i>et al.</i> (2015) Mol Imaging Biol [131]
PABA	¹⁸ F, ³ H	No	Wide range of bacteria species/ folic acid biosynthesis pathway	Also shows binding to resistant species. A very promising tracer to translate to the clinic	Ordonez <i>et al.</i> (2017) J Nucl Med [53]

1.6. Potential New Imaging Agents to Selectively Image Bacterial Infections

Bacteria are the most common microorganisms causing DFIs. Developing new imaging agents for bacterial infections is an important field of research. The field makes use of knowledge of specific metabolic pathways and bacterial structures, e.g., unique cell wall

properties that give opportunities for imaging. These unique properties offer promising opportunities for specific imaging of bacterial infections in the diabetic foot. Different imaging modalities are used to image bacterial infections (Fig. 1). These different medical imaging modalities have their pros and cons with regard to costs, sensitivity, and spatial resolution. Hybrid imaging can further in-

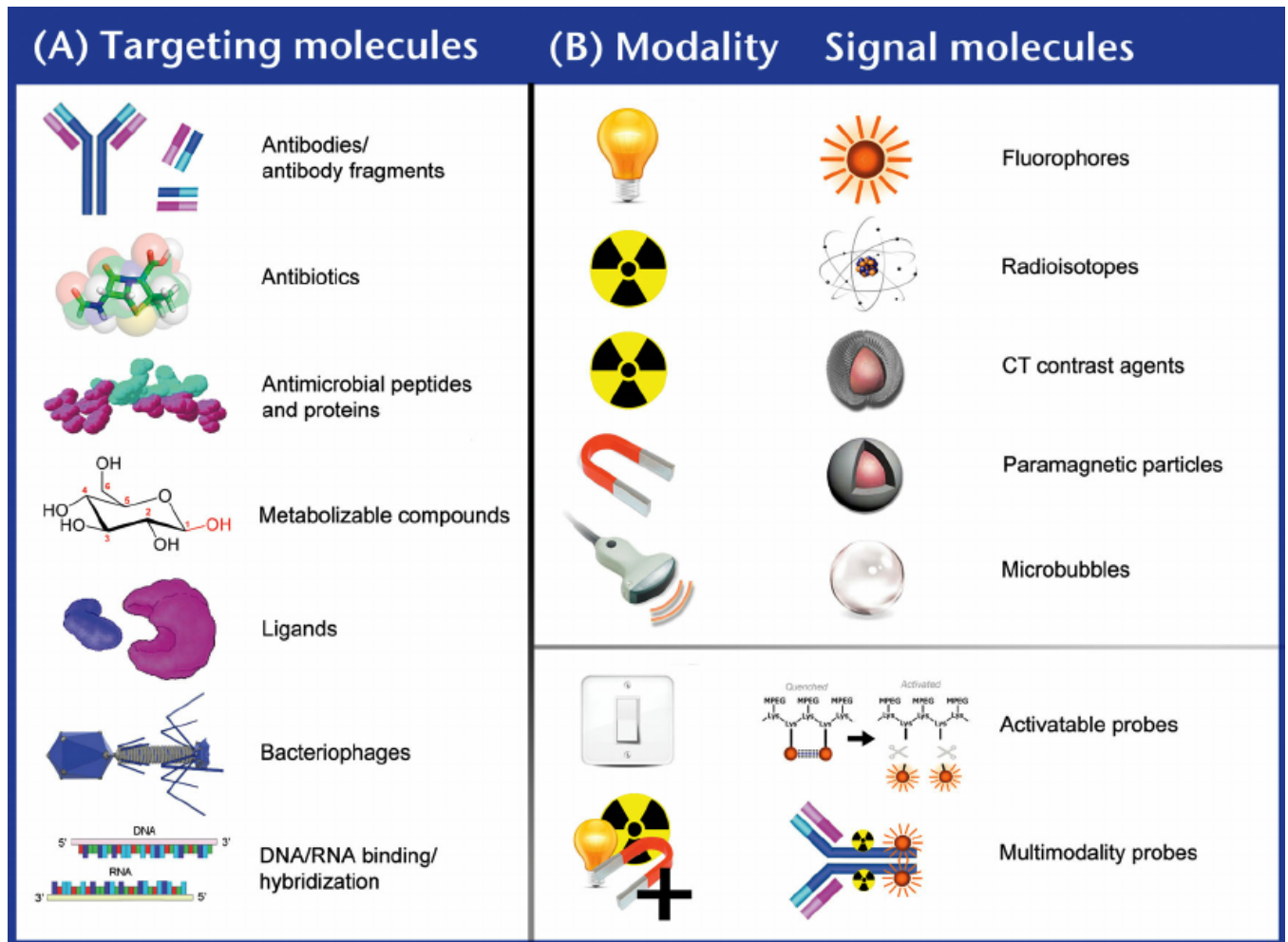


Fig. (1). Adapted from “van Oosten M, Hahn M, Crane LM, Pleijhuis RG, Francis KP, van Dijl JM, van Dam GM. FEMS Microbiol Rev 2015; 39(6): 892-916” [47].

crease the possibilities for bacterial imaging. As a further application, these imaging tracers can be combined with antibiotics to allow targeted delivery of antibiotics to sites of infection or labeled with a therapeutic radioisotope for radioimmunotherapy in infectious disease which can transform the treatment of DFIs [45]. By far, most of the work is still in the preclinical stage. Research efforts have been going on for many years, and yet to be translated to humans. The long time for the translation from the preclinical to the clinical stage is a reflection of the challenges encountered in developing bacteria-specific methods for clinical use. Several excellent review papers have recently been published on targeted imaging of bacterial infections [46, 47]. This current review provides an overview of the current status of optical and nuclear imaging tracers for DFIs and reviews new tracers that could potentially be used imaging in the DFIs.

Bacteria-specific imaging is essential in DFIs because:

1. In DFIs, early and accurate diagnosis is crucial to reduce morbidity and even mortality associated with the infection. Bacteria-specific imaging is vital as it helps in the diagnosis of DFIs which may not be clinically apparent as in some cases of osteomyelitis.
2. The duration of treatment of DFIs varies depending on the type and severity of the infection. The duration of treatment is shorter for uncomplicated soft tissue infection typically about a week or two and usually with oral antibiotics. On the other hand, in complicated soft tissue infection or osteomyelitis may

involve surgery and antibiotic treatment is usually given for longer periods and may initially require intravenous administration. Specific bacterial imaging is a useful clinical tool in determining the type and duration of therapy.

3. The growing prevalence of antibiotic-resistant pathogens has resulted in bacterial infections that have shown to be a huge threat to human health worldwide. Treatment of drug-resistant microorganisms is quite challenging. DFIs caused by methicillin-resistant *S. aureus* (MRSA) are more difficult to treat and the treatment more expensive than methicillin-susceptible *S. aureus* infections (MSSA). Specific bacterial imaging may help in the early diagnosis of these resistant species and allow appropriate treatment to be initiated.
4. Bacteria preferentially form biofilms that promote drug resistance. Bacterial biofilms consist of clusters of bacteria, embedded in a self-secreted matrix of extracellular polymeric substances forming a three-dimensional structure. Recent studies have demonstrated biofilm formation in DFIs with colonized flora aggregating and causing chronic inflammation [48-50]. Specific bacterial imaging may in combination with microbiology molecular technology help identify bacteria that would have otherwise considered as ‘innocent bystanders’ (colonizers) in DFIs.

The following aspects of DFIs may be assessed with bacteria-specific imaging tracers:

- pathophysiology of the infection

- identification of the tissues or cells involved
- detection of specific bacterial targets
- quantification pathogenic bacteria

Bacteria-specific imaging agents may help appropriate treatment to be chosen, and the therapeutic effect can be assessed and tailored to patients need if required. Furthermore, bacteria-specific imaging may help to distinguish infective foci from other lesions due to other pathology.

Specific bacteria imaging has its challenges. These challenges have been expressed in some published letters and opinions with some even suggesting it is not worth the effort [51, 52]. Studies conducted by other researchers have showed however that bacteria-specific imaging is beneficial with some tracers being singled out as more favorable candidates [53-55].

Bacteria-specific imaging is challenging because:

- There are many different bacterial species meaning a lot of different tracers would need to be developed
- The number of colonies present and the dimension of infective foci may be below the detection threshold or resolution of imaging system
- Bacteria may be difficult to reach as a result of low blood perfusion in infective lesion
- Condition of the host (immune system) has an impact on the status of microorganisms
- Imaging agents should be able to discriminate bacteria lesions from sterile inflammation and cell proliferation processes such as cancer

Different imaging modalities are used in the research of bacteria-specific imaging. Imaging with PET, SPECT and optical is uniquely placed for bacteria-specific in imaging. Based on their mechanism of action these tracers can be divided into several categories:

- inflammatory responses of the host
- substances released from or presented by the bacteria
- metabolism specific for bacteria.

In each category and subheading, we will address both tracers for nuclear imaging and optical imaging, because of similar chemical "backbone" to target bacteria.

1.6.1. Imaging Specific Inflammatory Responses

1.6.1.1. Antimicrobial Peptides (AMPs)

AMPs are produced as a result of the immune response of the infected host/organism towards bacterial infections. AMPs have broad-spectrum activity, low toxicity and a lower rate of resistance developed by pathogens. It is theoretically possible that these biologically active compounds may exert a biologic effect on the immune system. However, the human studies in which these peptides do not seem to suggest this. There is little data available on the safety profile of AMPs in humans [56]. One meta-analysis raised concerns about nephrotoxicity and neurotoxicity when AMPs are used as therapeutic agents [57]. AMPs, however, are considered to have a good safety profile compared to small drug molecules based on the short half-life and the degradation products which are naturally occurring amino acids [56, 58]. A well-studied AMP is ubiquicidin. This 51-amino acid peptide has a cationic character and preferentially binds to the cell wall of bacteria. Fragments of ubiquicidin (UBI 29-41) have been labeled with radionuclides, optical dyes and nanoparticles.

Radiolabeled UBI 29-41

UBI29-41 has been labeled with ^{99m}Tc and ^{68}Ga [59]. The ^{99m}Tc -analog was prepared by ^{99m}Tc -labeling of the HYNIC-UBI 29-41 precursor [60]. This tracer has been evaluated in 20 patients with osteomyelitis with more than 50% due to DFIs [61]. The tracer

was found to be 100% accurate exceeding all other modalities it was compared to including MRI. The ^{68}Ga -analog was prepared by radiolabeling of the NOTA-UBI 29-41. [^{68}Ga]Ga-NOTA-UBI 29-41 showed specificity towards *S. aureus* and distinguished between infection and inflammation. Another PET-analog [^{18}F]fluoro-UBI 29-41 prepared by S[^{18}F]FB showed significant defluorination and specific binding towards *S. aureus* could unfortunately not be confirmed *in vivo* [62]. More studies are required to determine the role of these radiolabeled in DFIs. In a recent *ex vivo* study in which the ^{99m}Tc -labeled analog was compared to other tracers, the ^{99m}Tc -labeled analog showed good *in vivo* binding to *E. coli* although there was poor *in vitro* binding to *E. coli* [63]. This study demonstrates how *in vitro* studies may not reflect what the tracer does *in vivo*.

Optical Imaging of UBI 29-41

In optical imaging UBI 29-41, has been labeled with the Near Infrared (NIR) dyes ICG02 and MPA [64]. Specific binding to bacteria, as opposed to sterile inflammation, was demonstrated as proved by blocking experiments and controls with dyes only.

Hybrid Nuclear and Optical Labeling of UBI 29-41

UBI 29-41 has been labeled simultaneously with both optical imaging tracer Cy5 and ^{111}In . This hybrid UBI 29-41 tracer has been investigated for infection in a preclinical setting. The hybrid tracer accumulated at sites of bacterially infected tissue. This hybrid tracer may enable the pre-operative assessment of infection with whole-body SPECT/CT scan and intraoperative visualization of infected tissue with optical imaging [65]. This could potentially improve the management of DFIs by providing a pre-operative assessment of infection and real-time visualization of infected tissue during the debridement of infected and necrotic tissue.

Similar studies combining PET-analogues of UBI-29-41 with optical tracer are highly recommended. As PET/MRI is increasingly gaining prominence, it is conceivable that using this hybrid tracer with multimodality PET/MRI imaging, management of DFIs can be greatly enhanced as functional and anatomical information can be combined. Overall, the various UBI-based imaging agents give encouraging results and several options are available to choose the right multimodality imaging combination.

Nanoparticles (NPs) Labeled with UBI 29-41 and Conjugated Antibiotics (Therapeutic Role of UBI 29-41 in Infection)

The role of UBI 29-41 has been explored as a therapeutic agent. For this purpose, UBI 29-41 was linked to functionalized selenium nanoparticles (NPs) or quantum dots [66]. This enhanced the stability of the antimicrobial peptide. This nanoparticle labeled UBI was then conjugated of vancomycin to specifically target bacterial infection. This directed the antibiotic to the site of infection and enhanced the potency of the vancomycin. The resulting nanoprobe were injected into mice by intravenous injection. They were found to be effective to treat sites of bacterial infection. Multifunctional UBI-based NPs offer many opportunities to further fine-tune properties for selective imaging and targeted therapy. This will enable delivery of high concentration antibiotic to the infective site at lower serum concentration reducing toxicity due to the antibiotic. This may enable the theranostic use of UBI 29-41 based molecules in the management of DFIs if these preclinical results can be translated to humans.

Other Radiolabeled AMPs

Other AMPs like human neutrophil peptide (HNP), neutrophil elastase inhibitors peptide, human-beta-defensin (HBD), human lactoferrin-derived peptide (hLF) have been labeled with ^{99m}Tc and showed bacterial specificity in mouse models [67]. These AMPs may have a role similar to UBI 29 in the evaluation of infection, but the evidence is lacking. Further evaluation is required to assess their ability to image infection in general and DFIs in particular. To improve these imaging agents, it would be useful to label these AMPs

with the PET-radionuclides ^{68}Ga or ^{18}F as the availability both radionuclides and the radiolabeling options for peptides have improved dramatically in the last decade.

1.6.1.2. Cytokines

Cytokines are small proteins or peptides released by immune cells to regulate immune and inflammatory response. Early work done with radiolabeled cytokines demonstrated that they are useful for specific infection imaging in animal models [68, 69]. Interleukin 1 alpha (IL 1 α), interleukin 1 beta (IL 1 β), interleukin1 receptor antagonist (IL ra) and the chemotactic peptide formyl-methionyl-leucyl-phenylalanine were radiolabeled with ^{123}I and compared [70]. The radiolabeled IL 1 β was found to offer the best imaging characteristics, but differences in imaging characteristic between species were found (mouse vs. rabbit) when tested with *E. coli* infected animal models [71]. The IL ra was considered potentially useful because of the absence of biological activity causing side effects. IL 1 β , IL 6, IL 8 and IL 10 have been radiolabeled with ^{125}I and investigated for imaging infection in animal models [70]. The ^{125}I -radiolabeled IL 8 is reported to have visualized infective foci in a pilot study of 8 patients with osteomyelitis [72]. Radiolabeled cytokines have not been explored as infection agents to the same extent as AMPs [46].

1.6.2. Imaging Substances Released from or Presented by Bacteria

1.6.2.1. Antibiotic Binding

Using antibiotic derivatives as imaging agents is a widely studied approach. Most of the studies done with labeled antibiotics are in the preclinical setting. There are several categories of antibiotics with different mechanisms of action (Fig. 2). One drawback of using labeled antibiotics is that bacteria that are already resistant to the drug will give an unpredictable response. While some resistant bacteria may accumulate tracer others may not depending on the mechanism of uptake of tracer and resistance of the bacteria.

Antibiotics interfering with nucleic acid synthesis and therefore inhibiting bacterial DNA-synthesis have been quite extensively studied as imaging agents. The most studied antibiotic imaging agent is [$^{99\text{m}}\text{Tc}$]ciprofloxacin. The development of this tracer dates back to the 90s, followed by the development of other radiolabeled fluoroquinolones [70]. It was found that different chelators for labeling [$^{99\text{m}}\text{Tc}$]ciprofloxacin resulted in radiopharmaceuticals displaying different target-non-target ratios. Some antibiotic molecules have been modified, and the resulting compounds were tested for imaging bacterial infections. An example is [$^{99\text{m}}\text{Tc}$]ciprofloxacin dithiocarbamate which was modified from ciprofloxacin. [$^{99\text{m}}\text{Tc}$]ciprofloxacin dithiocarbamate was found to have higher uptake at infective sites and better abscess to muscle and abscess to blood ratios compared to [$^{99\text{m}}\text{Tc}$]ciprofloxacin [73].

1.6.2.1.1. Radiolabeled DNA Synthesis Inhibitors

[$^{99\text{m}}\text{Tc}$]ciprofloxacin

[$^{99\text{m}}\text{Tc}$]ciprofloxacin and derivatives could be considered as a general identifier of gram-positive and gram-negative bacteria, but *in vivo*, the biological evaluation gave variable results. Also, the imaging agents showed the variable capacity to discriminate between infection and sterile inflammation. Dead bacteria were also found to accumulate [$^{99\text{m}}\text{Tc}$]ciprofloxacin making it difficult/impossible to distinguish treated and dead bacteria from actively replicating microorganisms [46]. Moreover, drug-resistant bacteria may or may not accumulate [$^{99\text{m}}\text{Tc}$]ciprofloxacin depending on the mechanism of resistance [74, 75]. A large multicenter trial found high sensitivity and specificity for both soft tissue and osteomyelitis [76]. Another study evaluated 25 patients with diabetes mellitus with foot ulcers using [$^{99\text{m}}\text{Tc}$]ciprofloxacin. The study found a sensitivity, specificity and accuracy in diagnosing DFIs as 66.7%, 85.7% and 72% respectively. They authors concluded that [$^{99\text{m}}\text{Tc}$]ciprofloxacin was both sensitive and specific in diagnosing

osteomyelitis in DFI. However, they suggested that fastidious and ciprofloxacin-resistant bacteria flora may result in false-negative results [77]. A recent review noted that the uptake mechanism and the factors affecting ciprofloxacin uptake are not entirely understood, more research is needed to determine the appropriate use of [$^{99\text{m}}\text{Tc}$]ciprofloxacin [46].

Other Radiolabeled Fluoroquinolones

Other fluoroquinolones have been investigated as next-generation radiopharmaceuticals for infection imaging. Several compounds (such as ofloxacin, levofloxacin, gemifloxacin, lomefloxacin) were labeled with different radionuclides like $^{99\text{m}}\text{Tc}$, ^{18}F , and ^{68}Ga . These radiolabeled quinolones were able to distinguish between infection and inflammation. Of all tested fluoroquinolones, sitafloxacin has shown the highest target-to-non-target ratios (23 at two h post injection) resulting in higher image contrast [78]. The biological target was an *S. aureus* infection. This radiopharmaceutical should be further evaluated, and it will be worth testing PET-analogs of sitafloxacin as well. The antibacterial spectrum and results in the preclinical setting suggest a possible role of the tracers in the management of DFIs.

1.6.2.1.2. Radiolabeled Folic Acid Synthesis Inhibitors

Radiolabeled Trimethoprim

Trimethoprim inhibits the formation of tetrahydrofolic acid, which is an essential precursor in the biosynthesis of the nucleic acid thymidine. This antibiotic compound was labeled with a [^{18}F]fluoropropyl group [79]. [^{18}F]fluoropropyl-trimethoprim, or [^{18}F]FPTMP, showed a greater than 100-fold increased uptake *in vitro* in live bacteria (*S. aureus*, *E. coli*, and *P. aeruginosa*) relative to controls and did not accumulate in sterile inflammatory tissues and cancer. In a rodent myositis model, [^{18}F]FPTMP identified active bacterial infection without any confounding uptake in the same animal resulting from chemical inflammation (turpentine) and cancer (breast carcinoma). Additionally, the biodistribution of [^{18}F]FPTMP in a nonhuman primate showed low background uptake in many tissues that are the usual sites of infection such as the lungs and soft tissues. The antibiotic spectrum suggests this tracer may have a potential role in DFI imaging, but there are no clinical studies.

Radiolabeled Sulfonamides

Sulfonamides inhibit synthesis of folic acid and are used as broad-spectrum gram-positive and gram-negative antibiotics. One sulphonamide, sulfadiazine, was labeled with [$^{99\text{m}}\text{Tc}$]pertechnetate directly resulting in various complexes formed by the interaction of electron donating nitrogen groups and the reduced [$^{99\text{m}}\text{Tc}$] pertechnetate core. Uptake of [$^{99\text{m}}\text{Tc}$]sulfadiazine was more than 2-fold higher in *S. aureus*-infected muscles compared to controls [80]. The spectrum of activity suggests a potential role in the evaluation of DFIs, but clinical studies are lacking.

1.6.2.1.3. Radiolabeled Bacteria Cell wall Synthesis Inhibitors

Radiolabeled Vancomycin

Antibiotics interfering with the bacterial cell wall synthesis have been much less studied. Vancomycin binds to the D-ala-D-ala moiety of a lipid in the cell wall of gram-positive bacteria that results in the inhibition of cell wall (peptidoglycan) synthesis. Promising results were obtained with IRDye800CW vancomycin that accumulates at the bacterial site of infection of gram-positive *S. aureus* but not of gram-negative *E. coli* [81]. The imaging agent might offer the possibility to detect biofilms on implanted medical devices. The amino group of vancomycin that is used to conjugate the IRDye800CW can be a versatile handle to attach a variety of tags for imaging. For SPECT-imaging, [$^{99\text{m}}\text{Tc}$]vancomycin, not regioselectively labeled using chelators but by direct labeling, showed an affinity for *S. aureus* infection foci. Vancomycin was also labeled through [$^{99\text{m}}\text{Tc}$]Te-HYNIC tetrazine click chemistry. A

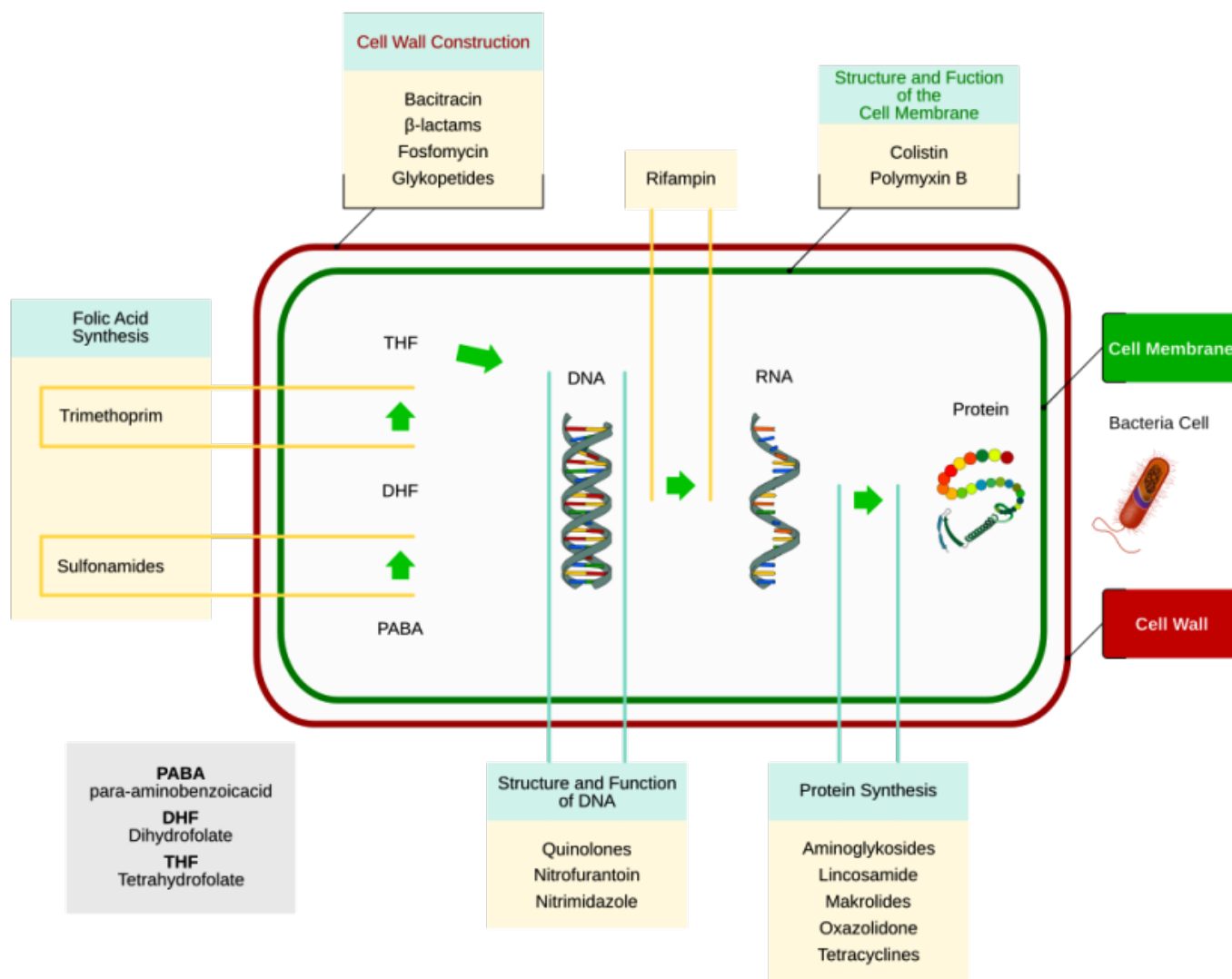


Fig. (2). Overview of different categories of antibiotics and their mechanism of action (Antibiotics – Wikipedia 13 September 2017).

3-fold uptake at the *S. aureus* infection site compared to control was found [82].

For PET imaging, options like attaching a chelator followed by radiolabeling with a metal, or conjugation to a ^{18}F -labelled activated ester offer great possibilities for further research. As vancomycin is sometimes used in the treatment of DFIs, using an analog for imaging purposes is clinically very relevant to assess whether the therapeutic antibiotic agent reaches its target at sufficient dose to become effective. In DFIs, *S. aureus* is usually the offending pathogen and vancomycin is used in the treatment of some infections. The antibacterial spectrum of vancomycin suggests that its radiolabeled compound may be useful in the management of DFIs.

Radiolabeled Beta-lactam Based Agents

Beta-lactam based imaging has been evaluated at the preclinical stage. Beta-lactams inhibit synthesis of the bacterial cell wall. The molecules contain a heterocyclic four-membered beta-lactam ring and selectively inhibit DD-transpeptidase, an enzyme that is involved in prokaryotic cell wall synthesis. Beta-lactams are broad-spectrum antibiotics that affect both gram-positive and gram-negative pathogens. Beta-lactams include penicillins and cephalosporins. The structural differences are found in the fused ring connected to the beta-lactam ring. Cephalosporins are less susceptible to beta-lactamases and therefore more stable as compared to penicillins.

Within the family of penicillin derivatives: an aminopenicillin, amoxicillin, was labeled with $^{99\text{m}}\text{Tc}$. The $^{99\text{m}}\text{Tc}$ -core forms a complex with two amoxicillin molecules and this dimer was only preliminary evaluated *in vivo*. Biodistribution studies in rabbits showed rapid excretion via kidney to the bladder and *in vivo* binding to *Streptococcus pneumoniae* was observed [83]. Another penicillin analog tazobactam was labeled with $^{99\text{m}}\text{Tc}$. [$^{99\text{m}}\text{Tc}$]Tazobactam can be used to diagnose bacterial infection and to discriminate between infected and inflamed tissues [84].

Some cephalosporins (ceftizoxime, cefuroxime, cefoperazone) were labeled with $^{99\text{m}}\text{Tc}$ using the direct method and showed specific uptake in bacterial infections in animal models. The disadvantage of the direct labeling method is that mixtures of $^{99\text{m}}\text{Tc}$ -complexes can be formed. Therefore, the radiopharmaceutical can display unpredictable behavior regarding its binding properties.

All beta-lactam derived radiopharmaceuticals have only been tested *in vitro* or in animal models. The obtained target-to-non-target ratios were very variable. With [$^{99\text{m}}\text{Tc}$]ceftriaxone the highest target-to-non-target ratio 12.66 was found. Beta-lactams are used to treat DFIs suggesting that radiolabeled beta-lactams may play a role in the management of diabetic foot but there is currently no clinical data to support this.

1.6.2.1.4. Radiolabeled Protein Synthesis Inhibitors

Radiolabeled Puromycin

Puromycin is a protein synthesis inhibitor acting by inhibition of the translation process from RNA. Puromycin causes chain termination during the translation in the ribosomes. [⁶⁸Ga]Ga-DOTA-puromycin showed highly selective uptake in *S. aureus*-infected foci in comparison to sterile inflammation, and its uptake was very low in lung, brain, abdomen and the musculoskeletal system, which are potential organs for bacterial infections [85].

Recently, a ¹⁸F-fluorinated puromycin analog has been synthesized by ¹⁸F-fluorination of a tosylate precursor, but the publication of biological evaluation is still pending [86]. Although

no clinical data is available, the spectrum of antibacterial activity suggests that it could play a role in the management of DFIs.

Radiolabeled Aminoglycosides

Another class of molecules is the aminoglycosides that are polycationic entities that are protein synthesis inhibitors. Aminoglycosides block ribosomes and prevent translation of proteins, and there is an irreversible uptake of the antibiotic. Kanamycin, streptomycin and gentamicin were labeled with ^{99m}Tc by direct labeling of the parent aminoglycoside with [^{99m}Tc]TcO₄⁻ in the presence of tin chloride. The compounds contain oxygen atoms, amino and hydroxyl groups that can coordinate to the ^{99m}Tc-core. Again, this direct ^{99m}Tc-labeling method produced mixtures of different ^{99m}Tc-complexes. Although mixed ^{99m}Tc-complexes were used in imaging, [^{99m}Tc]kanamycin showed a 2-fold higher uptake in *S. aureus*-infected muscle of animals (rats and rabbits) compared to controls [87]. [^{99m}Tc]streptomycin was only evaluated in turpentine-infected mice where it was shown that uptake in the inflamed lesion was 2-fold increased [88]. [^{99m}Tc]gentamicin was only evaluated as renal functional imaging agent [89].

Radiolabeled Tetracycline

Tetracyclines prevent binding of aminoacyl-tRNA to the ribosome resulting in inhibition of protein synthesis. [^{99m}Tc]doxycycline which is a tetracyclic compound with several functional groups that can coordinate to ^{99m}Tc was evaluated in rats and displayed higher uptake in infected muscle compared to sites of sterile inflammation [90]. In another article, [^{99m}Tc]doxycycline was evaluated for its potency to image bacterial infection and displayed increased (2-fold) uptake in *E. coli* infection sites [91]. Again, though no human studies have been performed the spectrum of antibacterial activity suggests it may be useful in the management of DFIs.

Radiolabeled Lincosamides

The class of lincosamides binds to the 50S-unit of bacterial ribosomes and thereby blocks the exit of newly formed peptides. Two examples of this class of antibiotics are clindamycin and lincomycin. Both antibiotics were labeled using the direct method with [^{99m}Tc]TcO₄⁻ in the presence of a reducing agent. Slightly higher accumulation in *S. aureus*-infected lesion in Sprague-Dawley rats was found [92].

Radiolabeled Macrolides

Macrolides are structurally different than lincosamide both have the same mechanism of action. Erythromycin is a representative of this family of molecules containing a macrocyclic ring of 14 atoms with sugar-like side chains and several oxygen-based functional groups. As described above erythromycin was directly labeled with ^{99m}TcO₄⁻ in the presence of SnCl₂. The radiopharmaceutical was only evaluated in turpentine-induced inflammation animal models and showed increased uptake in the sterile inflammatory lesions [88]. Clarithromycin has also been labeled with ^{99m}Tc. The uptake of the labeled clarithromycin was higher in *S. aureus* lesions as compared to sterile inflammation [93].

Oxazolidinones, like linezolid, inhibit bacterial protein synthesis initiation by disrupting translation of mRNA into protein in the ribosomes. They act against the gram-positive bacteria. Linezolid was labeled with ¹³¹I by the iodogen method and used for imaging *S. aureus* in a rat infection model in comparison with a sterile inflammation [94]. Uptake in the *S. aureus* infected lesion was higher than the turpentine-induced inflammation was 5-fold higher as compared to control. Linezolid is a small molecule containing an aromatic fluorine atom and two carbonyl functionalities that would make the compound interesting for labeling with either ¹⁸F or ¹¹C.

Radiolabeled Nitrofurans

Nitrofurans target and damage DNA and act in the control of translation from mRNA to proteins. To be effective nitrofurans are reduced by flavoproteins. Nitrofurantoin was labeled with ^{99m}Tc in which it was used to image *E. coli*. In a rat model [95]. This radiolabeled antibiotic may play a role in the management of DFIs.

1.6.2.1.5. Radiolabeled RNA Synthesis Inhibitors

Anti-mycobacterial agents like rifampicin (inhibition of RNA-synthesis by inhibiting DNA-dependent RNA polymerase) and ethambutol (disturbance of cell wall synthesis) were radiolabeled with ^{99m}Tc and evaluated as tuberculosis imaging agents [96, 97]. Also, some compounds were produced with ¹¹C: rifampicin was prepared by ¹¹C-methylation of the corresponding desmethyl precursor with [¹¹C]methyl triflate and pyrazinamide by reaction with K[¹¹C]CN followed by oxidation. The pharmacokinetics and biodistribution of these tuberculosis frontline drugs were investigated in several organs in baboons. In another article, the kinetics was measured in *M. tuberculosis*-infected mice. There was reduced penetration of [¹¹C]rifampicin in lung lesions and brain [98]. Rifampicin has a broad antibacterial spectrum. *S. aureus* is particularly susceptible to rifampicin. Radiolabeled rifampicin may be useful in the management of DFIs [99].

1.6.2.2. Other Classes of Bacteria Detecting Imaging Probes

1.6.2.2.1. Nucleoside Analogs

2'-Fluoro-2'-deoxy-1β-D-arabinofuranosyl-5-[¹²⁴I]iodouracil ([¹²⁴I]FIAU) is a nucleoside analog which is a substrate for bacterial thymidine kinase specifically. After its phosphorylation, the compound is irreversibly trapped in the cell. The PET-tracer was examined in patients with musculoskeletal bacterial infections, and the efficacy to detect prosthetic joint infections was assessed. Early studies in patients show that it was an optimal imaging agent correctly identifying or excluding infective site [100]. In a more recent study, metal artifacts interfered with the uptake of tracer thus more research must be done to determine the appropriate use of this tracer [101]. [¹²⁵I]FIAU has recently been used to image and quantify bacterial load in the lung of mice [55].

1.6.2.2.2. Zinc-dipicolylamine (Zn-DPA)

Zn-DPA is positively charged complex and interacts with the negatively charged gram-negative bacterial cells. Zn-DPA was first labeled with Cy5 and NIR-dyes [102]. Later, an ¹¹¹In-derivative, [¹¹¹In]In-DOTA-biotin/SA/biotin-Zn-DPA was developed [103]. In all cases, Zn-DPA derivatives could well discriminate between bacterial infections from other infections and inflammation. The disadvantage is that Zn-DPA also binds to negatively charged membranes of apoptotic and necrotic mammalian cells making Zn-DPA a potential apoptosis marker as well. In the management of DFIs, this may be exploited by identifying not only infected but necrotic tissue during debridement. The usefulness of this tracer as an infection-imaging agent was confirmed in a more recent animal study [104].

1.6.2.2.3. Concanavalin A

Concanavalin A nanoprobe is a lectin-binding protein with high affinity for cell-surface mannose residues. This imaging agent binds to both gram-positive and gram-negative bacteria. Concanavalin A

was conjugated with NIR dye IR750 and bound to infectious locations [105]. The imaging agent was evaluated *in vitro* and the ability to detect bacterial colonization on wounds and catheters was demonstrated.

1.6.2.2.4. Prothrombin

Prothrombin uptake is due to blood clotting on bacteria to cover its antigens and evade the immune system because of the activation of prothrombin by staphylocoagulase. *S. aureus* was detected by application of an AlexaFluor680-labeled and ^{64}Cu -labelled (^{64}Cu)Cu-DTPA) prothrombin [106]. Both imaging agents accumulated at the *S. aureus* infection site and were developed for endocarditis imaging. This has application in the management of DFIs as *S. aureus* is the most common pathogen, and the immune evasion may explain the persistence of some bacteria after therapy.

1.6.2.2.5. Peptidoglycan Aptamers

Peptidoglycans are essential macromolecules of the cell wall of bacteria. Gram-positive bacteria have about 80% of their cell wall made of peptidoglycan. Gram-negative bacteria on the other hand have 5-20% made of peptidoglycan and this is located between the plasma membrane of the bacteria and the lipopolysaccharide envelope. Aptamers are short single-stranded oligonucleotides that bind molecules with high specificity and affinity [107]. Peptidoglycan aptamers have several properties that make them suitable for molecular imaging [108]. One peptidoglycan aptamer (Antibac1) was labeled with $^{99\text{m}}\text{Tc}$ using the direct method and evaluated by biodistribution studies and scintigraphic imaging in infected mice [109]. This radiolabeled aptamer seems to be suitable in distinguishing between bacterial (*S. aureus*) and fungal (*Candida albicans*) infection.

1.6.2.2.6. Siderophores

Siderophores are iron-chelating peptide-like metabolites produced by bacteria. During infection siderophore production and transport systems are unregulated. Administered siderophores are taken up by gram-negative bacteria, and they show no selective uptake in bacteria, but also accumulate in fungi. The iron atom can be replaced by ^{68}Ga [110]. A proof-of-principle to visualize infection was shown with ^{68}Ga -labelled triacetylfusarinine (TAFc). In the management of DFIs, the siderophore ^{68}Ga -ferrioxamine E (FOXc) may be more useful as *in vitro* studies showed high uptake of *S. aureus*. Curiously, this uptake was not demonstrated *in vivo*, and further studies are needed to translate this tracer that has demonstrated excellent and specific imaging features with fungi to bacteria. Another approach was the production of siderophore conjugates with DOTAM for metal ions which also enables radionuclide therapy by inserting appropriate metal radionuclides. (e.g., ^{68}Ga and ^{64}Cu for PET-diagnosis and ^{90}Y for radionuclide therapy). Siderophores have been applied as a bifunctional chelator to complex ^{89}Zr instead of desferrioxamine.

1.6.2.2.7. Radiolabeled Antibodies

The acquired immune system produces antibodies against microorganisms when an infection occurs. These antibodies are specific to the particular microbe, and this provides a unique opportunity to image microorganisms when these antibodies are labeled with tracers. Recently, a bacterial-specific antibody was labeled with ^{64}Cu . Systemic *Yersinia enterocolitica* infections were imaged using immunoPET (antibody-targeted positron emission tomography) with [^{64}Cu]Cu-NODAGA-labeled *Yersinia*-specific polyclonal antibodies which are targeting the outer membrane protein YadA [111]. In contrast to [^{18}F]FDG, [^{64}Cu]Cu-NODAGA-YadA uptake co-localized in a dose-dependent manner with bacterial lesions of *Yersinia*-infected mice. There was increased uptake of [^{64}Cu]Cu-NODAGA-YadA in infected tissues. Another example was a radiolabeled antibody against the O-side of *Pseudomonas aeruginosa* immunotype 1 lipopolysaccharide (LPS) showing specific uptake in bacterial infections. Specific accumulation of anti-

bodies can amount up to several days which is a significant drawback. Using antibody fragments (Fab₂, Fab, affibodies, scFv etc) instead could be a next step in the development of specific imaging agents [112].

1.6.2.2.8. Bacteriophage

Bacteriophage M13 is a filamentous, non-lytic phage with an affinity for *E. coli*. The bacteriophage was used as a scaffold for attaching carbon nanotubes. They fluoresce in the NIR2 region with enhanced depth penetration [113]. Attaching antibodies against bacteria species of choice can further modify the agent to image other bacteria. Good results have been demonstrated for *S. aureus* and *E. coli*. Also, $^{99\text{m}}\text{Tc}$ -labeled bacteriophages have been developed and tested in a mouse infection model (*K. pneumoniae*, *Enterococcus faecalis*, *Salmonella enterica* and *P. aeruginosa*). Infection/normal tissue uptake ranged between 2 and 14 depending on the version of the bacteriophage and bacterial species [114].

In an attempt to increase sensitivity, a nuclease-activated FRET (Fluorescence Resonance Energy Transfer) probe was developed. An oligodeoxynucleotide susceptible to specific bacterial nucleases was functionalized with the fluorescent dye Cy 5.5 at 5' and quenching groups at 3' at the cleavage site [115]. A study in *S. aureus*-infected mice showed that the imaging probe was silent until contact and cleaved by a nuclease.

This principle has also shown to work with a beta-lactamase-activated and a nitroreductase FRET probe [116, 117]. It will be interesting to see the development of new strategies using activatable optical probes. These optical probes can lead to highly sensitive measurements of a small number of bacterial colonies. The combination with PET-imaging agents will be a unique and powerful combination to obtain information of the infection status in the diabetic foot.

1.6.3. Imaging Metabolism of Bacteria

1.6.3.1. Bacterial Carbohydrate Imaging

Bacteria utilize different sugars compared to mammalian cells and contain specific transport systems for sugars (sorbitol, maltose, maltohexaose and glucose-6-phosphate) which make sugars an attractive class of imaging agents to specifically image bacterial infections. As with most antibiotic imaging tracers most of the studies with these tracers are preclinical, but as these tracers selectively target bacteria, they can play a role in the management of DFIs.

1.6.3.1.1. Glucose-6-Phosphate

Glucose-6-phosphate has utilized in certain bacteria such as *E. coli* and *S. aureus*. This glucose metabolite is transported via the universal hexose phosphate transporter (UHPT) that is only present in bacterial cells. Glucose-6-phosphate was labeled with nitrobenzoxadiazole (NBD) and NIR fluorescent dyes. Only the NBD-derivative was transported by UHPT [118]. Very likely the NIR-dye was too large to be transported by UHPT. It could be worth studying the use of [^{18}F]FDG-6-phosphate as PET-radiopharmaceutical that is formed after the hexokinase phosphorylation of [^{18}F]FDG.

1.6.3.1.2. Sorbitol

Sorbitol is a metabolite utilized by gram-negative bacteria including *E. coli*, *Klebsiella pneumoniae*, and *P. aeruginosa*. These bacteria are the usual offending microorganism when there is a gram-negative DFI making sorbitol an attractive tracer for imaging DFI. [^{18}F]Fluorodesoxysorbitol ([^{18}F]FDS) was labeled with ^{18}F from [^{18}F]FDG by reduction with NaBH_4 [119]. [^{18}F]FDS was selectively taken in infected lesions. [^{18}F]FDS was successfully used for following treatment with antibiotics by monitoring infection levels. A first-in-man study with [^{18}F]FDS was published recently [120]. Healthy volunteers were scanned for 3 hours post-injection. The tracer had low background uptake and fast clearance from the plasma tissues which is an advantage in infection imaging. Uptake

of [^{18}F]FDS by Enterobacteriaceae in the gut still needs to be further explored. Despite encouraging results with [^{18}F]FDS, no fluorescent sorbitol analogs have been tested although it is very questionable if such fluorescent imaging agent will show similar behavior to [^{18}F]FDS because the properties will change dramatically for a small molecule like sorbitol.

1.6.3.1.3. Amino Sugars

Another bacterial sugar is the amino sugar that is a component of the bacterial cell wall in both gram-positive and gram-negative bacteria. [^{18}F]FAG is 2-deoxy-2-[^{18}F]fluoroacetamido-D-glucopyranose and was successfully used to identify *E. coli* in rat models and to make a discrimination of sterile inflammation from infection. Uptake data were confirmed by histological analysis [121].

1.6.3.1.4. Maltodextrose

Maltodextrin-based imaging probes (MDPs) can detect bacteria *in vivo* with a sensitivity two orders of magnitude higher than previously reported imaging agents and can detect bacteria using a bacteria-specific mechanism that is independent of host response and secondary pathologies. MDPs are rapidly internalized through the bacteria-specific maltodextrin transport pathway, favoring the MDPs with a unique combination of high sensitivity and specificity for bacteria. MDPs selectively accumulate within bacteria at millimolar concentrations and are a thousand-fold more specific for bacteria than mammalian cells. MDPs can image as few as 10^5 colony-forming units *in vivo* and can discriminate between active bacteria and inflammation induced by either lipopolysaccharides or metabolically inactive bacteria [122].

Maltodextrose is such a sugar transported by the maltodextrin transporter and was labeled with the NIR dye IR786 [123]. As the maltodextrin transporter is very active and because maltodextrin is hydrophilic and therefore will not diffuse through mammalian cell membranes, the maltodextrose imaging agents proved to show high sensitivity and high target-to-non-target ratios as measured with *E. coli* infections. Maltodextrose was also labeled with ^{18}F for PET-imaging. Uptake was observed in both gram-positive and gram-negative bacteria. Also, *P. aeruginosa* was detected in a clinically relevant mouse model of wound infection [124, 125].

1.6.3.1.5. D-mannitol

Some bacteria are capable of using D-mannitol as a primary energy source or in the metabolic pathway for energy [126]. This has been exploited and used in the imaging of bacteria. D-mannitol was radiolabeled with ^{18}F and found to have a rapid uptake in *S. aureus* and *E. coli* with good tracer clearance from plasma and issues. The ^{18}F radiolabeled mannitol was taken up by all isolates including drug resistant MRSA and extended spectrum beta-lactamases (ESBL) *E. coli* in an infected murine pyomyositis model. This tracer may be useful in the evaluation of DFI and a recent publication suggested it has great potential for translation into the clinic [53].

1.6.3.2. Bacterial Amino Acid Uptake Imaging

1.6.3.2.1. D-Methionine

In most organism and in humans only the L-stereoisomers (L-amino acids) are manufactured and incorporated into cells. Some D-stereoisomers of amino acids (D-amino acids) are found in the cell wall of bacteria but are not present in humans. This allows them to be targeted for bacteria-specific imaging. D-methionine has been labeled with some optical dyes including the NBD dyes and showed uptake in *E. coli* and other bacteria [127]. An analog of D-methionine has recently been labeled with ^{11}C to produce D-[methyl- ^{11}C]methionine tracer and used to differentiate *E. coli* and *S. aureus* infections in mice from sterile inflammation [128]. This tracer could potentially be labeled with longer acting radionuclides and find application in imaging of DFIs.

1.6.3.3. Imaging Vitamin Uptake by Bacteria

1.6.3.3.1. Biotin

Biotin was labeled with ^{111}In as an essential growth factor for some bacteria including *S. aureus*. As it is involved in the production of fatty acids, [^{111}In]In-DTPA-biotin showed uptake in *S. aureus* cultures and was selective in its uptake [129]. This may play a role in DFIs. No *in vivo* data are available yet. A ^{18}F -analog of biotin has been developed, but this molecule was only tested as ^{18}F -synthon for radiolabelling of macromolecules using the biotin-avidin system [130].

1.6.3.3.2. Vitamin B12

[$^{99\text{m}}\text{Tc}$]Tc-PAMA-Cyano-cobalamin is a labeled derivative of vitamin B12 that has been investigated for infection imaging. It accumulates in rapidly proliferating cells and is important for transmethylation reactions. [$^{99\text{m}}\text{Tc}$]PAMA was effectively prepared by the $^{99\text{m}}\text{Tc}$ -tricarbonyl method. The imaging agent showed specificity towards *S. aureus* and *E. coli* in *in vitro* cell cultures and in infected mice [131].

1.6.3.3.3. Para-aminobenzoic Acid (PABA)

PABA is a compound used in the biosynthesis of folic acid in many microorganisms including bacteria. PABA was labeled with ^3H and found to accumulate in a wide range of bacteria species including resistance microorganisms including MRSA, carbapenem-resistant *K. pneumoniae*, and extended spectrum beta-lactamases *E. coli*. The uptake in the microorganisms was more than a hundred times more than mammalian cells. It was then labeled with ^{18}F and showed good uptake in *S. aureus*. PABA was determined to one of the numerous tracers at the preclinical stage that holds great promise for future translation to the clinic [53].

1.7. Future Perspectives

There are many potential tracers for imaging DFIs. Most of the agents for imaging infection are still in the preclinical stage. A significant proportion of the tracers developed are labeled with $^{99\text{m}}\text{Tc}$ using the indirect method resulting in mixed complexes. Considering the advantages of better resolution of PET over SPECT imaging, the PET equivalents of the tracers that are potential candidates for infection are recommended to be researched and developed. ^{18}F -labeling options are now available for most of the compounds using conjugation techniques (succinimides, click chemistry, [^{18}F]AIF-methodology) [132-135]. These methods can replace $^{99\text{m}}\text{Tc}$ by ^{18}F in most of the tracers at the preclinical level. The use of radiometals such as generator-produced ^{68}Ga offers more possibilities for labeling especially peptides. The availability of GMP-compliant generators would make ^{68}Ga labeled compounds a desirable mode of chelating compounds to produce useful tracers in the management of DFIs [135]. Radioisotopes with longer half-lives such ^{64}Cu and ^{89}Zr may offer a good alternative for labeling of peptides which are currently labeled with ^{68}Ga . These relatively longer acting radioisotopes will make delayed imaging, which is a requirement in infection imaging, possible. The half-life of ^{64}Cu is 12.7 hours, however its utility in clinical practice has been limited because of the difficulty in the production of this radioisotope. ^{64}Cu is likely to be more available as a simpler method of production has recently become available [136]. The long half-life of 78 hours of ^{89}Zr also makes it an attractive label for large proteins such as antibodies, however, the benefit must be weighed against the radiation burden the patient is exposed to with a long-lived radioisotope [137]. The possibility of hybrid imaging would also allow the application of these potential new tracers in PET/MRI or even PET/CT when MRI cannot be performed to allow pre-and intra-operative assessment of DFIs requiring surgery. The ability to assess DFIs both pre- and intra-operatively is a significant future development to reduce the number of amputations and possible save some lower limbs [138, 139]. The use of nanoparticles to deliver antibiotics to infected areas may allow delivery of high doses of antibiotic to the infected

site with minimal systemic toxicity. Furthermore, radioimmunotherapy with antibiotics may offer new and exciting possibilities when these tracers are labeled with therapeutic radioisotopes to shorten the duration of antibiotic therapy and to treat resistant organisms [45]. MRI is currently the imaging method of choice due to its excellent soft tissue resolution and ability to diagnose bone and soft tissue early. PET/MRI is now available in clinical practice. Developing PET-tracers to be used in PET/MRI would offer an excellent imaging tool for the patient; getting the 'best of both worlds' from a metabolic and anatomic point of view in one sitting. The development of synthetic methods for PET-labeling, which can be applied in hospitals without the need for highly trained radiochemists and GMP makes PET/MRI an even more attractive option for DFI imaging. It may be impractical to expect that all the potential tracers will be translated to the clinic. It is likely that suitable candidates will be chosen by different criteria including *in silico* methods from this large number of potential infection tracers [53]. An agent that is specific for infection but accumulates in different bacteria like AMPs or PABA may be more likely to be translated into clinical practice [53, 140]. It is also likely that a bacteria-specific imaging tracer will be translated to clinic for different infections such as tuberculosis or fungal infection and may be repurposed for DFIs [141, 142]. There are several regulations, directives, and guidelines on clinical trials and the requirements for the newly developed radiopharmaceuticals to be used [143]. For optical imaging agents, this situation is even more complicated. Besides all the regulatory text, several guidelines are published to assist researchers in the interpretation of these texts. The guidelines are dealing, e.g., with toxicity testing, GMP and first-in-man studies [144, 145]. Authorities have recognized that the high regulatory burden hampers innovation. As a result, the European Union has accepted a new regulation 536/2014 which includes streamlining of the application process for clinical trials and exceptions for requirement of GMP for radiopharmaceuticals in these trials. This new regulation may pave the way for accelerated translation of these tracers for use in infections including DFIs from the preclinical setting to the clinic.

CONSENT FOR PUBLICATION

Not applicable.

CONFLICT OF INTEREST

The authors declare no conflict of interest, financial or otherwise.

ACKNOWLEDGEMENTS

Declared none.

REFERENCES

- [1] Boulton AJ, Vileikyte L, Ragnarson-Tennvall G, Apelqvist J. The global burden of diabetic foot disease. *Lancet* 2005; 366: 1719-24.
- [2] Chammas NK, Hill RL, Edmonds ME. Increased Mortality in Diabetic Foot Ulcer Patients: The Significance of Ulcer Type. *J Diabetes Res* 2016; 2016: 2879809.
- [3] International Diabetic Federation. IDF DIABETES ATLAS Eighth edition 2017. www.diabetesatlas.org/across-the-globe.html accessed 29th December 2017.
- [4] Zimmet P, Alberti KG, Magliano DJ, Bennett PH. Diabetes mellitus statistics on prevalence and mortality: facts and fallacies. *Nat Rev Endocrinol* 2016; 12: 616-22.
- [5] Pemayun TG, Naibaho RM, Novitasari D, Amin N, Minuljo TT. Risk factors for lower extremity amputation in patients with diabetic foot ulcers: a hospital-based case-control study. *Diabet Foot Ankle* 2015; 6: 29629.
- [6] Palestro CJ, Love C. Nuclear medicine and diabetic foot infections. *Semin Nucl Med* 2009; 39: 52-65.
- [7] Heiba S, Knešarek K. Evaluation of diabetic foot infection in nuclear medicine. *Q J Nucl Med Mol Imaging* 2017; 61: 283-91.
- [8] Israel O, Sconfienza LM, Lipsky BA. Diagnosing diabetic foot infection: the role of imaging and a proposed flow chart for assessment. *Q J Nucl Med Mol Imaging* 2014; 58: 33-45.
- [9] Grigoropoulou P, Eleftheriadou I, Jude EB, Tentolouris N. Diabetic Foot Infections: an Update in Diagnosis and Management. *Curr Diab Rep* 2017; 17: 3.
- [10] Glaudemans AW, Uçkay I, Lipsky BA. Challenges in diagnosing infection in the diabetic foot. *Diabet Med* 2015; 32: 748-59.
- [11] Lipsky BA, Aragón-Sánchez J, Diggle M, *et al.* IWGDF guidance on the diagnosis and management of foot infections in persons with diabetes. *Diabetes Metab Res Rev* 2016; 32: 45-74.
- [12] Lavery LA, Armstrong DG, Peters EJ, Lipsky BA. Probe-to-bone test for diagnosing diabetic foot osteomyelitis: reliable or relic? *Diabetes Care* 2007; 30: 270-4.
- [13] Mutluoglu M, Uzun G, Sildiroglu O, Turhan V, Mutlu H, Yildiz S. Performance of the probe-to-bone test in a population suspected of having osteomyelitis of the foot in diabetes. *J Am Podiatr Med Assoc* 2012; 102: 369-73.
- [14] Garcia ME, Lazaro-Martinez JL, Ragon-Sanchez FJ, Cecilia-Matilla A, Eit-Montesinos J, Gonzalez Jurado MA. Inter-observer reproducibility of probing to bone in the diagnosis of diabetic foot osteomyelitis. *Diabet Med* 2011; 28: 1238-40.
- [15] Dinh T, Snyder G, Veves A. Current techniques to detect foot infection in the diabetic patient. *Int J Low Extrem Wounds* 2010; 9: 24-30.
- [16] Michail M, Jude E, Liaskos C, *et al.* The performance of serum inflammatory markers for the diagnosis and follow-up of patients with osteomyelitis. *Int J Low Extrem Wounds* 2013; 12: 94-9.
- [17] van Asten SA, Jupiter DC, Mithani M, La Fontaine J, Davis KE, Lavery LA. Erythrocyte sedimentation rate and C-reactive protein to monitor treatment outcomes in diabetic foot osteomyelitis. *Int Wound J* 2017; 14: 142-8.
- [18] Bonham PA. Swab cultures for diagnosing wound infections: a literature review and clinical guideline. *J Wound Ostomy Continence Nurs* 2009; 36: 389-95.
- [19] Senneville E, Morant H, Descamps D, *et al.* Needle puncture and transcutaneous bone biopsy cultures are inconsistent in patients with diabetes and suspected osteomyelitis. *Clin Infect Dis* 2009; 48: 888-93.
- [20] Lavigne JP, Sotto A, Dunyach-remy C, Lipsky BA. New molecular techniques to study the skin microbiota of diabetic foot ulcers. *Adv Wound Care (New Rochelle)* 2015; 4: 38-49.
- [21] Malone M, Gosbell IB, Dickson HG, Vickery K, Espedido BA, Jensen SO. Can molecular DNA-based techniques unravel the truth about diabetic foot infections? *Diabetes Metab Res Rev* 2017; 33: e2834.
- [22] Pineda C, Espinosa R, Pena A. Radiographic imaging in osteomyelitis: the role of plain radiography, computed tomography, ultrasonography, magnetic resonance imaging, and scintigraphy. *Semin Plast Surg* 2009; 23: 80-9.
- [23] Lauri C, Tamminga M, Glaudemans AWJM, *et al.* Detection of osteomyelitis in the diabetic foot by imaging techniques: A systematic review and meta-analysis comparing MRI, white blood cell scintigraphy, and FDG-PET. *Diabetes Care* 2017; 40: 1111-20.
- [24] Goldsmith SJ, Vallabhajosula S. Clinically proven radiopharmaceuticals for infection imaging: mechanisms and applications. *Semin Nucl Med* 2009; 39: 2-10.
- [25] Familiari D, Glaudemans AW, Vitale V, *et al.* Can sequential 18F-FDG PET/CT replace WBC imaging in the diabetic foot? *J Nucl Med* 2011; 52: 1012-9.
- [26] Godavarty A, Rao PN, Khandavilli Y, Jung YJ. Diabetic Wound Imaging Using a Noncontact Near-Infrared Scanner: A Pilot Study. *J Diabetes Sci Technol* 2015; 9: 1158-9.
- [27] Mills B, Bradley M, Dhaliwal K. Optical imaging of bacterial infections. *Clin Transl Imaging* 2016; 4: 163-74.
- [28] Heiba S, Kolker D, Ong L, *et al.* Dual-isotope SPECT/CT impact on hospitalized patients with suspected diabetic foot infection: saving limbs, lives, and resources. *Nucl Med Commun* 2013; 34: 877-84.
- [29] Saeed S, Zafar J, Khan B, *et al.* Utility of ^{99m}Tc-labelled antimicrobial peptide ubiucidin (29-41) in the diagnosis of diabetic foot infection. *Eur J Nucl Med Mol Imaging* 2013; 40: 737-43.
- [30] Aslangul E, M'Bemba J, Caillat-Vigneron N, *et al.* Diagnosing Diabetic Foot Osteomyelitis in Patients Without Signs of Soft Tissue Infection by Coupling Hybrid 67Ga-SPECT/CT With Bedside Percutaneous Bone Puncture. *Diabetes Care* 2013; 36: 2203-10.

- [31] De Vries EFJ, Roca M, Jamar F, *et al.* Guidelines for the labelling of leucocytes with [99mTc]HMPAO. *Eur J Nucl Med Mol Imaging* 2010; 37: 842-8.
- [32] Roca M, de Vries EFJ, Jamar F, *et al.* Guidelines for the labelling of leucocytes with ¹¹¹In-oxine. *Eur J Nucl Med Mol Imaging* 2010; 37: 835-41.
- [33] Glaudemans AW, de Vries EF, Vermeulen LE, Slart RH, Dierckx RA, Signore A. A large retrospective single-centre study to define the best image acquisition protocols and interpretation criteria for white blood cell scintigraphy with 99mTc-HMPAO-labelled leucocytes in musculoskeletal infections. *Eur J Nucl Med Mol Imaging* 2013; 4: 1760-9.
- [34] Erba PA, Glaudemans AW, Veltman NC, *et al.* Image acquisition and interpretation criteria for 99mTc-HMPAO-labelled white blood cell scintigraphy: results of a multicentre study. *Eur J Nucl Med Mol Imaging* 2014; 41: 615-23.
- [35] Familiari D, Glaudemans AW, Vitale V, *et al.* Can sequential 18F-FDG PET/CT replace WBC imaging in the diabetic foot? *J Nucl Med* 2011; 52: 1012-9.
- [36] Glaudemans AWJM, de Vries EFJ, Galli F, Dierckx RA, Slart RH, Signore A. The Use of [18F]FDG-PET/CT for Diagnosis and Treatment Monitoring of Inflammatory and Infectious Diseases. *Clin Dev Immunol* 2013; 2013: 623036.
- [37] Rubello D, Casara D, Maran A, Avogaro A, Tiengo A, Muzzio PC. Role of anti-granulocyte Fab' fragment antibody scintigraphy (LeukoScan) in evaluating bone infection: acquisition protocol, interpretation criteria and clinical results. *Nucl Med Commun* 2004; 25: 39-47.
- [38] Harwood SJ, Valdivia S, Hung GL, Quenzer RW. Use of Sulesomab, a radiolabeled antibody fragment, to detect osteomyelitis in diabetic patients with foot ulcers by leukoscintigraphy. *Clin Infect Dis* 1999; 28: 1200-5.
- [39] Dominguez-Gadea L, Martin-Curto LM, de la Calle H, Crespo A. Diabetic foot infections: scintigraphic evaluation with 99Tcm-labelled anti-granulocyte antibodies. *Nucl Med Commun* 1993; 14: 212-8.
- [40] Palestro CJ. In vivo leukocyte labeling: the quest continues. *J Nucl Med* 2007; 48: 332-4.
- [41] Bhargava KK, Gupta RK, Nichols KJ, Palestro CJ. In vitro human leukocyte labelling with ⁶⁴Cu: an intraindividual comparison with [¹¹¹In]oxine and [18F]FDG. *Nucl Med Biol* 2009; 36: 545-9.
- [42] Nanni C, Errani C, Boriani L, *et al.* ⁶⁸Ga-citrate PET/CT for evaluating patients with infections of the bone: preliminary results. *J Nucl Med* 2010; 51: 1931-6.
- [43] Behr SC, Aqqarwal R, Seo Y, *et al.* A feasibility study showing [⁶⁸Ga]citrate detects prostate cancer. *Mol Imaging Biol* 2016; 18: 946-51.
- [44] Vorster M, Maes A, Wiele Cv, Sathekge M. Gallium-68 PET: A Powerful Generator-based Alternative to Infection and Inflammation Imaging. *Semin Nucl Med* 2016; 46: 436-47.
- [45] Dadachova E, Casadevall A. Radiolabeled antibodies for therapy of infectious diseases *Microbiology spectrum* 2014; 2: 0023
- [46] Auletta S, Galli F, Lauri C, Martinelli D, Santino I, Signore A. Imaging bacteria with radiolabelled quinolones, cephalosporins and siderophores for imaging infection: a systematic review. *Clin Transl Imaging* 2016; 4: 229-52.
- [47] van Oosten M, Hahn M, Crane LM, *et al.* Targeted imaging of bacterial infections: advances, hurdles and hopes. *FEMS Microbiol Rev* 2015; 39: 892-916.
- [48] Gardner SE, Hillis SL, Heilmann K, Segre JA, Grice EA. The neuropathic diabetic foot ulcer microbiome is associated with clinical factors. *Diabetes* 2013; 62: 923-30.
- [49] Banu A, Noorul Hassan MM, Rajkumar J, Srinivasa S. Spectrum of bacteria associated with diabetic foot ulcer and biofilm formation: A prospective study. *AMJ* 2015; 8: 280-5.
- [50] Swarna SR, Radha M, Gomathi S, *et al.* A study of Biofilm on Diabetic Foot Ulcer. *Int J Res Pharm Biomed Sci* 2012; 3: 1809-14.
- [51] Alavi A, Werner TJ, Hoiland-Carlson PF. What Can Be and What Cannot Be Accomplished With PET: Rectifying Ongoing Misconceptions. *Clin Nucl Med* 2017; 42: 603-5.
- [52] Hess S, Alavi A, Werner T, Hoiland-Carlson PF. Molecular Imaging of Bacteria in Patients is an Attractive Fata Morgana, Not a Realistic Option. *J Nucl Med* 2018 Jan 11. pii: jnumed.117.207001. [Epub ahead of print]
- [53] Ordonez AA, Weinstein EA, Bambarger LE, *et al.* A Systematic Approach for Developing Bacteria-Specific Imaging Tracers. *J Nucl Med* 2017; 58: 144-50.
- [54] Wang X, Murthy N. Bacterial imaging comes of age. *Sci Transl Med* 2014; 6: 259fs43.
- [55] Pullambhatla M, Tessier J, Beck G, Jedynak B, Wurthner JU, Pomper MG. [(125)I]FIAU imaging in a preclinical model of lung infection: quantification of bacterial load. *Am J Nucl Med Mol Imaging* 2012; 2: 260-70.
- [56] Mahlapuu M, Håkansson J, Ringstad L, Björn C. Antimicrobial Peptides: An Emerging Category of Therapeutic Agents. *Front Cell Infect Microbiol* 2016; 6: 194.
- [57] Falagas ME, Kasiakou SK. Toxicity of polymyxins: a systematic review of the evidence from old and recent studies. *Crit Care* 2006; 10: R27.
- [58] Vlieghe P, Lisowski V, Martinez J, Khrestchatsky M. Synthetic therapeutic peptides: science and market. *Drug Discov Today* 2010; 15: 40-56.
- [59] Vilche M, Reyes AL, Vasilskis E, Oliver P, Balter H, Engler H. [⁶⁸Ga]Ga-NOTA-UBI-29-41 as a PET Tracer for Detection of Bacterial Infection. *J Nucl Med* 2016; 57: 622-7.
- [60] Welling MM, Visentin R, Feitsma HI, Lupetti A, Pauwels EK, Nibbering PH. Infection detection in mice using 99mTc-labeled HYNIC and N2S2 chelate conjugated to the antimicrobial peptide UBI 29-41. *Nucl Med Biol* 2004; 31: 503-9.
- [61] Assadi M, Vahdat K, Nabipour I, *et al.* Diagnostic value of 99mTc-ubiquicidin scintigraphy for osteomyelitis and comparisons with 99mTc-methylene diphosphonate scintigraphy and magnetic resonance imaging. *Nucl Med Commun* 2011; 32: 716-23.
- [62] Salber D, Gunawan J, Langen KJ, *et al.* Comparison of [99mTc]- and [18F]ubiquicidin autoradiography to anti-Staphylococcus aureus immunofluorescence in rat muscle abscesses. *J Nucl Med* 2008; 49: 995-9.
- [63] Auletta S, Baldoni D, Varani M, *et al.* Comparison of 99mTc-UBI 29-41, 99mTc-Ciprofloxacin, 99mTc-Ciprofloxacin dithiocarbamate and ¹¹¹In-biotin for targeting experimental Staphylococcus aureus and Escherichia coli foreign-body infections: an ex-vivo study. *Q J Nucl Med Mol Imaging* 2017; [Epub ahead of print].
- [64] Chen H, Liu C, Chen D, *et al.* Bacteria-targeting conjugates based on antimicrobial peptide for bacteria diagnosis and therapy. *Mol Pharm* 2015; 12: 2505-16.
- [65] Welling MM, Bunschoten A, Kuil J, *et al.* Development of a Hybrid Tracer for SPECT and Optical Imaging of Bacterial Infections. *Bioconjug Chem* 2015; 26: 839-49.
- [66] Chen H, Zhang M, Li B, *et al.* Versatile antimicrobial peptide-based ZnO quantum dots for in vivo bacteria diagnosis and treatment with high specificity. *Biomaterials* 2015; 53: 532-44.
- [67] Welling MM, Paulusma-Annema A, Balter HS, Pauwels EK, Nibbering PH. 99mTc-labelled antimicrobial peptides discriminate between bacterial infections and sterile inflammations. *Eur J Nucl Med* 2000; 27: 292-301.
- [68] van der Laken CJ, Boerman OC, Oyen WJ, *et al.* Specific targeting of infectious foci with radioiodinated human recombinant interleukin-1 in an experimental model. *Eur J Nucl Med* 1995; 22: 1249-55.
- [69] van der Laken CJ, Boerman OC, Oyen WJ, *et al.* Imaging of infection in rabbits with radioiodinated interleukin-1 (alpha and beta), its receptor antagonist and a chemotactic peptide: a comparative study. *Eur J Nucl Med* 1998; 25: 347-52.
- [70] Signore A, Procaccini E, Annovazzi A, Chianelli M, van der Laken C, Mire-Sluis A. The developing role of cytokines for imaging inflammation and infection. *Cytokine* 2000; 12: 1445-54.
- [71] Fuster D, Soriano A, Garcia S, *et al.* Usefulness of [99mTc]ciprofloxacin scintigraphy in the diagnosis of prosthetic joint infections. *Nucl Med Commun* 2011; 32: 44-51.
- [72] Shapiro B, Gross MD, Shreve PD, *et al.* Imaging of inflammation and infection with radiolabelled cytokines. *Nucl Med Commun* 1997; 18: 472.
- [73] Zhang J, Zhang S, Guo H, Wang X. Synthesis and biological evaluation of a novel 99mTc(CO)₃ complex of ciprofloxacin dithiocarbamate as a potential agent to target infection. *Bioorg Med Chem Lett* 2010; 20: 3781-4.
- [74] Hall AV, Solanki KK, Vinjamuri S, Britton KE, Das SS. Evaluation of the efficacy of 99mTc-Infecton, a novel agent for detecting sites of infection. *J Clin Pathol* 1998; 51: 215-9.

- [75] Sierra JM, Rodriguez-Puig D, Soriano A, Mensa J, Píera C, Vila J. Accumulation of 99mTc-Ciprofloxacin in *Staphylococcus aureus* and *Pseudomonas aeruginosa*. *Antimicrob Agents Chemother* 2008; 52: 2691-2.
- [76] Britton KE, Wareham DW, Das SS, *et al.* Imaging bacterial infection with (99m)Tc-ciprofloxacin (Infecton). *J Clin Pathol* 2002; 55: 817-23.
- [77] Dutta P, Bhansali A, Mittal BR, Singh B, Masoodi SR. Instant 99mTc-ciprofloxacin scintigraphy for the diagnosis of osteomyelitis in the diabetic foot. *Foot Ankle Int* 2006; 27: 716-22.
- [78] Qaiser SS, Khan AU, Khan MR. Synthesis, biodistribution and evaluation of [99mTc]sitafoxacin kit: a novel infection imaging agent. *J Radioanal Nucl Chem* 2010; 284: 189-93.
- [79] Sellmyer MA, Lee I, Hou C, *et al.* Bacterial infection imaging with [18F]fluoropropyltrimethoprim. *Proc Natl Acad Sci USA* 2017; 114: 8372-7.
- [80] Essouissi I, Darghoutha F, Saied NM, Saidi M. Radiolabeling, quality control and biodistribution of [99mTc]sulfadiazine as an infection imaging agent. *Radiochemistry* 2015; 57: 307-11.
- [81] van Oosten M, Schäfer T, Gazendam JA, *et al.* Real-time in vivo imaging of invasive- and biomaterial-associated bacterial infections using fluorescently labelled vancomycin. *Nat Commun* 2013; 4: 2584.
- [82] Vito A, Alarabi H, Czorny S, *et al.* A 99mTc-Labelled Tetrazine for Bioorthogonal Chemistry. Synthesis and Biodistribution Studies with Small Molecule trans-Cyclooctene Derivatives. *PLoS One* 2016; 11: e0167425.
- [83] Shahzadi SK, Qadir MA, Shahzad S, *et al.* [99mTc]amoxicillin: a novel radiopharmaceutical for infection imaging. *Arab J Chem* 2015;
- [84] Rasheed R, Naqvi SA, Gillani SJ, Zahoor AF, Jielani A, Saeed N. [99mTc]tazobactam, a novel infection imaging agent: radiosynthesis, quality control, biodistribution and infection imaging studies. *J Lab Compnds Radiopharm* 2017; 60: 242-9.
- [85] Eigner S, Beckford Vera D, Lebeda O, Eigner Henke K. 68Ga-DOTA-Puromycin: In vivo imaging of bacterial infection. *J Nucl Med* 2013; 54: 1218.
- [86] Betts HM, Milicevic Sephton S, Tong C, *et al.* Synthesis, in vitro evaluation, and radiolabeling of fluorinated puromycin analogues: Potential candidates for PET imaging of protein synthesis. *J Med Chem* 2016; 59: 9422-30.
- [87] Roohi S, Mushtaq A, Jehangir M, Malik SA. Synthesis, quality control and biodistribution of [99mTc]kanamycin. *J Radioanal Nucl Chem* 2006; 267: 561-6.
- [88] Ercan MT, Aras T, Unsal IS. Evaluation of [99mTc]erythromycin and [99mTc]streptomycin sulphate for the visualization of inflammatory lesions. *Int J Rad Appl Instr* 1992; 19: 803-6.
- [89] Ozker K, Urgancioglu I. [99mTc]gentamycin: chemical and biological evaluation. *Eur J Nucl Med* 1981; 6: 173-6.
- [90] Ozdemir DI, Asikoglu M, Ozkiliç H. Biodistribution of [99mTc]doxycycline hyclate. *FABAD J Pharm Sci* 2010; 35: 185-9.
- [91] Ozdemir DI, Asikoglu M, Ozkiliç H, Yilmaz F, Limoncu MH, Ayhan S. [99mTc]doxycycline hyclate: a new radiolabeled antibiotic for bacterial infection imaging. *J Lab Compnds Radiopharm* 2014; 57: 36-41.
- [92] Hina S, Rajoka MI, Roohi S, Haque A, Qasim M. Preparation, biodistribution and scintigraphic evaluation of [99mTc]clindamycin: an infection imaging agent. *Appl Biochem Biotechnol* 2014; 174: 1420-33.
- [93] Hina S, Roohi S, Rajoka M, Bokhari T, Sohaib M, Haque A. Preparation, Quality control and biological evaluation of 99mTc-clarithromycin in animal models for detection of bacterial infection. *J Chem Soc Pakistan* 2016; 38: 762-70.
- [94] Lambrecht FY, Yilmaz O, Durkan K, Unak P, Bayrak E. Preparation and biodistribution of [131I]linezolid in animal model infection and inflammation. *J Radioanal Nucl Chem* 2009; 281: 415-9.
- [95] Shah S, Khan A, Khan M. Radiosynthesis of 99mTc-nitrofurantoin a novel radiotracer for in vivo imaging of *Escherichia coli* infection. *J Radioanal Nucl Chem* 2010; 287
- [96] Işeri E, Ercan MT, Kaş HS, Hincall AA. The in vivo distribution of the 99mTc-labelled albumin and gelatin microspheres of a tuberculostatic agent, rifampicin. *Boll Chim Farm* 1991; 130: 66-70.
- [97] Causse JE, Pasqualini R, Cypriani B, *et al.* Labeling of ethambutol with 99mTc using a new reduction procedure. Pharmacokinetic study in the mouse and rat. *Int J Rad Appl Instrum [A]* 1990; 41: 493-6.
- [98] DeMarco VP, Ordonez AA, Klunk M, *et al.* Determination of [11C]rifampin pharmacokinetics within *Mycobacterium tuberculosis*-infected mice by using dynamic positron emission tomography bioimaging. *Antimicrob Agents Chemother* 2015; 59: 5768-74.
- [99] Thornsberrry C, Hill BC, Swenson JM, McDougal LK. Rifampin: spectrum of antibacterial activity. *Rev Infect Dis* 1983; 5: S412-7.
- [100] Diaz LA Jr, Foss CA, Thornton K, *et al.* Imaging of musculoskeletal bacterial infections by [124I]FIAU-PET/CT. *PLoS One* 2007; 2: e1007.
- [101] Zhang XM, Zhang HH, McLeroth P, *et al.* [124I]FIAU: Human dosimetry and infection imaging in patients with suspected prosthetic joint infection. *Nucl Med Biol* 2016; 43: 273-9.
- [102] Leevy WM, Gammon ST, Johnson JR, *et al.* Noninvasive optical imaging of staphylococcus aureus bacterial infection in living mice using a Bis-dipicolylamine-Zinc(II) affinity group conjugated to a near-infrared fluorophore. *Bioconjug Chem* 2008; 19: 686-92.
- [103] Liu X, Cheng D, Gray BD, *et al.* Radiolabeled Zn-DPA as a potential infection imaging agent. *Nucl Med Biol* 2012; 39: 709-14.
- [104] Rice DR, Plaunt AJ, Turkyilmaz S, *et al.* Evaluation of [¹¹¹In]-labeled zinc-dipicolylamine tracers for SPECT imaging of bacterial infection. *Mol Imaging Biol* 2015; 17: 204-13.
- [105] Tang EN, Nair A, Baker DW, Hu W, Zhou J. In vivo imaging of infection using a bacteria-targeting optical nanoprobe. *J Biomed Nanotechnol* 2014; 10: 856-63.
- [106] Panizzi P, Nahrendorf M, Figueiredo JL, *et al.* In vivo detection of *Staphylococcus aureus* endocarditis by targeting pathogen-specific prothrombin activation. *Nat Med* 2011; 17: 1142-6.
- [107] Lakhin AV, Tarantul VZ, Gening LV. Aptamers: problems, solutions and prospects. *Acta Naturae* 2013; 5: 34-43.
- [108] Ferreira IM, de Souza Lacerda CM, de Faria LS, de Faria LS, Corrêa CR, de Andrade AS. Selection of peptidoglycan-specific aptamers for bacterial cells identification. *Appl Biochem Biotechnol* 2014; 174: 2548-56.
- [109] Ferreira IM, de Sousa Lacerda CM, Dos Santos SR, *et al.* Detection of bacterial infection by a technetium-99m-labeled peptidoglycan aptamer. *Biomed Pharmacother* 2017; 93: 931-8.
- [110] Petrik M, Zhai C, Haas H, Decristoforo C. Siderophores for molecular imaging applications. *Clin Transl Imaging* 2017; 5: 15-27.
- [111] Wiehr S, Warnke P, Rolle A, *et al.* New pathogen-specific immunoPET/MR tracer for molecular imaging of a systemic bacterial infection. *Oncotarget* 2016; 7: 10990-1001.
- [112] Kaur S, Venktaraman G, Jain M, Senapati S, Garg PK, Batra SK. Recent trends in antibody-based oncologic imaging. *Cancer Lett* 2012; 315: 97-111.
- [113] Ghosh D, Bagley DF, Na YJ, Birrere MJ, Bhatia SN, Belchera AM. Deep, noninvasive imaging and surgical guidance of submillimeter tumors using targeted M13-stabilized single-walled carbon nanotubes. *Proc Natl Acad Sci USA* 2014; 111: 13948-53.
- [114] Ruscowski M, Gupta S, Liu G, Dou S, Hnatowich DJ. Investigation of four 99mTc-labelled bacteriophages for infection-specific imaging. *Nucl Med Biol* 2008; 35: 433-40.
- [115] Hernandez FJ, Huang L, Olson ME, *et al.* Non-invasive Imaging of *Staphylococcus aureus* infections with a nuclease-activated probe. *Nat Med* 2014; 20: 301-6.
- [116] Kong Y, Yao H, Ren H, *et al.* Imaging tuberculosis with endogenous beta-lactamase reporter enzyme fluorescence in live mice. *Proc Natl Acad Sci USA* 2010; 107: 12239-44.
- [117] Roldán MD, Pérez-Reinado E, Castillo F, Moreno-Vivian C. Reduction of polynitroaromatic compounds: the bacterial nitroreductases. *FEMS Microbiol Rev* 2008; 32: 474-500.
- [118] O'Neil RG, Wu L, Mullani N. Uptake of a fluorescent deoxyglucose analog (2-NBDG) in tumor cells. *Mol Imaging Biol* 2005; 7: 388-92.
- [119] Weinstein EA, Ordonez AA, DeMarco VP, *et al.* Imaging Enterobacteriaceae infection in vivo with [18F]fluorodeoxyisorbitol positron emission tomography. *Sci Transl Med* 2014; 6: 259.
- [120] Yao S, Xing H, Zhu W, *et al.* Infection imaging with [18F]FDS and first-in-human evaluation. *Nucl Med Biol* 2015; 43: 206-14.
- [121] Martinez ME, Kiyono Y, Noriki S, *et al.* New radiosynthesis of 2-deoxy-2-[18F]fluoroacetamido-D-glucopyranose and its evaluation as a bacterial infections imaging agent. *Nucl Med Biol* 2011; 38: 807-17.

- [122] Ning X, Lee S, Wang Z, *et al.* Maltodextrin-based imaging probes detect bacteria in vivo with high sensitivity and specificity. *Nat Mater* 2011; 10: 602-7.
- [123] Huang T, Ning X, Wang X, Murthy N, Tzeng Y-I, Dickson RM. Rapid cytometric antibiotics susceptibility testing utilizing adaptive multidimensional statistical metrics. *Anal Chem* 2015; 87: 1941-9.
- [124] Ning X, Seo W, Lee S, *et al.* PET imaging of bacterial infections with fluorine-18 maltohexaose. *Angew Chem* 2014; 53: 14096-101.
- [125] Gowrishankar G, Hardy J, Wardak M, *et al.* Specific imaging of bacterial infection using 6"-18F-fluoromaltotriose: A second-generation PET tracer targeting the maltodextrin transporter in bacteria. *J Nucl Med* 2017; 58: 1679-84.
- [126] Neves AR, Ramos A, Shearman C, Gasson MJ, Santos H. Catabolism of mannitol in *Lactococcus lactis* MG1363 and a mutant defective in lactate dehydrogenase. *Microbiology* 2002; 148(Pt 11): 3467-76.
- [127] Kuru E, Tekkam S, Hall E, Brun YV, Van Nieuwenhze MS. Synthesis of fluorescent D-amino acids and their use for probing peptidoglycan synthesis and bacterial growth in situ. *Nat Protoc* 2015; 10: 33-52.
- [128] Neumann KD, Villanueva-Meyer JE, Mutch CA, *et al.* Imaging Active Infection in vivo Using D-Amino Acid Derived PET Radiotracers. *Sci Rep* 2017; 7: 7903.
- [129] Erba PA, Cataldi AG, Tascini C, *et al.* [¹¹¹In]In-DTPA-Biotin uptake by *Staphylococcus aureus*. *Nucl Med Commun* 2010; 31: 994-7.
- [130] Shoup TM, Fischman AJ, Jaywook S, *et al.* Synthesis of fluorine-18-labeled biotin derivatives: biodistribution and infection localization. *J Nucl Med* 1994; 35: 1685-90.
- [131] Baldoni D, Waibel R, Bläuenstein P, *et al.* Evaluation of a Novel Tc-99m Labelled Vitamin B12 Derivative for Targeting *Escherichia coli* and *Staphylococcus aureus* in vitro and in an Experimental Foreign-Body Infection Model. *Mol Imaging Biol* 2015; 17: 829-37.
- [132] van der Born D, Pees A, Poot AJ, Orru RVA, Windhorst AD, Vugts DJ. Fluorine-18 labelled building blocks for PET tracer synthesis. *Chem Soc Rev* 2017; 46: 4709-73.
- [133] Campbell-Verduyn LS, Mirfeizi L, Schoonen AK, *et al.* Species-promoted copper-free "click" chemistry for 18F radiolabeling of bombesin. *Angew Chem Int Ed Engl* 2011; 50: 11117-20.
- [134] McBride WJ, D'Souza CA, Sharkey RM, Goldenberg DM. The radiolabeling of proteins by the [¹⁸F]AIF method. *Appl Radiat Isot* 2012; 70: 200-4.
- [135] Velikyán I. 68Ga-Based radiopharmaceuticals: production and application relationship. *Molecules* 2015; 20: 12913-43.
- [136] Alves F, Alves VHP, Do Carmo SJC, Neves ACB, Silva M, Abruñhosa AJ. Production of copper-64 and gallium-68 with a medical cyclotron using liquid targets. *Mod Phys Lett* 2017; 32: 1740013(1-21).
- [137] Apelqvist J, Larsson J. What is the most effective way to reduce incidence of amputation in the diabetic foot? *Diabetes Metab Res Rev* 2000; 16: S75-83.
- [138] Decristoforo C, Penueles I, Patt M, Todde S. European regulations for the introduction of novel radiopharmaceuticals in the Clinical setting. *Q J Nucl Med* 2017; 61: 135-44.
- [139] Botezatu I, Laptoiu D. Minimally invasive surgery of diabetic foot – review of current techniques. *J Med Life* 2016; 9: 249-54.
- [140] Lawal I, Zeevaart J, Ebenhan T, *et al.* Metabolic Imaging of Infection. *J Nucl Med* 2017; 58: 1727-32.
- [141] Ankrah AO, van der Werf TS, de Vries EF, Dierckx RA, Sathekge MM, Glaudemans AW. PET/CT imaging of *Mycobacterium tuberculosis* infection. *Clin Transl Imaging* 2016; 4: 131-44.
- [142] Ankrah AO, Klein HC, Span LFR, *et al.* The role of PET in monitoring therapy in fungal infections. *Curr Pharm Des* 2018; 24: 1-11.
- [143] Koziorovski J, Behe M, Decristoforo C, *et al.* Position paper on requirements for toxicological studies in the case of radiopharmaceuticals. *Eur J Nucl Med Radiopharm Chem* 2016; 1
- [144] Elsinga PH, Todde S, Penueles I, *et al.* Guidance on current good manufacturing practice (cGMP) for the small-scale preparation of radiopharmaceuticals. *Eur J Nucl Med Mol Imaging* 2010; 37: 1049-62.
- [145] Vugts DJ, Klaver C, Sewing C, *et al.* Comparison of the octadentate bifunctional chelator DFO*-pPhe-NCS and the clinically used hexadentate bifunctional chelator DFO-pPhe-NCS for 89Zr-immuno-PET. *Eur J Nucl Med Mol Imaging* 2017; 44: 286-95.