

Diffuse Idiopathic Skeletal Hyperostosis (DISH): diagnostic, clinical and paleopathological considerations

Holgate RL¹, Steyn M²

¹Forensic Anthropology Research Centre, Department of Anatomy, University of Pretoria, Pretoria, South Africa. rachelholgate87@gmail.com.

²School of Anatomical Sciences, University of the Witwatersrand, Johannesburg, South Africa.

Abstract

Diffuse idiopathic skeletal hyperostosis is a disease primarily affecting the spine. However, it is also associated with the ossification/calcification of tendon, ligament and capsule insertions (entheses) occurring at multiple peripheral sites. The etiology of the condition is unknown, as the name suggests (diffuse *idiopathic* skeletal hyperostosis), although some correlations with diabetes mellitus, obesity and age have been noted. Clinical diagnostic criteria have been adapted for paleopathological assessment of archeological skeletal remains, revealing some interesting patterns between monastic and lay populations; showing a higher incidence of DISH amongst individuals buried in monastic cemeteries. Although fascinating, the mechanisms behind this difference in prevalence are still not fully understood and have been attributed to the relatively richer diets of the monks and priests. The development of diagnostic criteria where earlier cases of DISH can be identified as well as a better understanding of its causes are paramount to the prevention of this potentially debilitating condition and perhaps this is where paleopathologists can assist. The use of dry bone rather than living patients for detailed assessment means that paleopathologists are less restricted by the techniques they can use in their investigations and the conditions occurrence in various archeological assemblages can provide interesting insights into its etiology.

Introduction

Previously referred to as Forestier's disease, senile ankylosis and ankylosing hyperostosis, diffuse idiopathic skeletal hyperostosis (DISH) was first described by Forestier and Rotés-Querol in

1950. Diagnosed by the flowing ossification (or 'candle wax' appearance) along the anterior longitudinal ligament (ALL) on the anterolateral surface of contiguous vertebrae (most prominent in

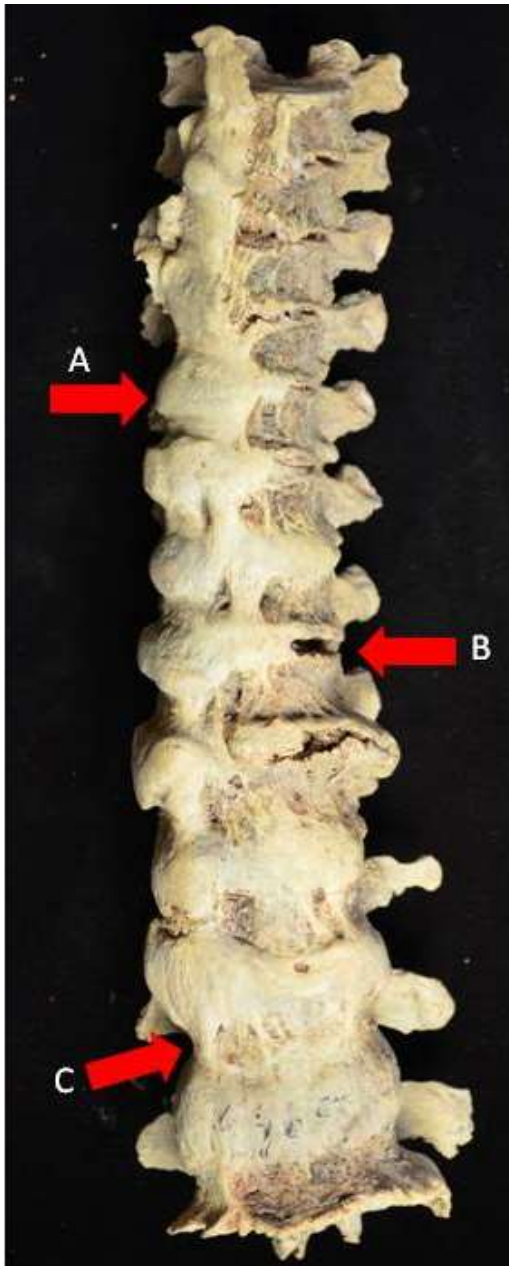


Figure 1. Example of DISH from the cadaver derived Pretoria Bone Collection. (A) Note the 'candle-wax' appearance of the ossification. (B) In DISH, the intervertebral disc space is retained. (C) The ossification along the anterior longitudinal ligament can be seen to start from the centre of the vertebral bodies, rather than from the margins of the end plates, as seen in osteophytes. Note the involvement on the right side of the thoracic vertebrae which has been attributed to the pulsation of the aorta, preventing ossification.

the thoracic region) with eventual fusion of the spine (Fig. 1), DISH, as the name suggests is idiopathic in nature (Forestier and Rotés-Querol, 1950). Although the etiology of the condition is

unknown, some causative agents have been suggested, such as diabetes mellitus, obesity, age, hyperuricemia, hypertension, hyperinsulinemia and elevated insulin-like growth factor (Cassim et al., 1990; Rogers and Waldron, 1995; Rogers and Waldron, 2001; Mader and Lavi, 2009; Reuven Mader et al., 2009; Roberts and Manchester, 2010). A familial or genetic predisposition for the disease has been proposed and explored with little success in finding a definitive answer (Pappone et al., 1996; Sarzi-Puttini and Atzeni, 2004; Gorman, 2005). The manifestations of this disease are not limited to the spine alone, with ossification of tendon, ligament and capsule insertions (entheses) occurring at multiple peripheral sites (Fig. 2), a concomitant feature of the spinal disease (Resnick et al., 1975; Resnick and Niwayama, 1988; Rogers and Waldron, 2001; Mader et al., 2009; Roberts and Manchester, 2010). Extraspinal manifestations have been frequently noted (bilaterally) in the calcanea, patellae, ulnae and ossa coxae (Rogers and Waldron, 1995).

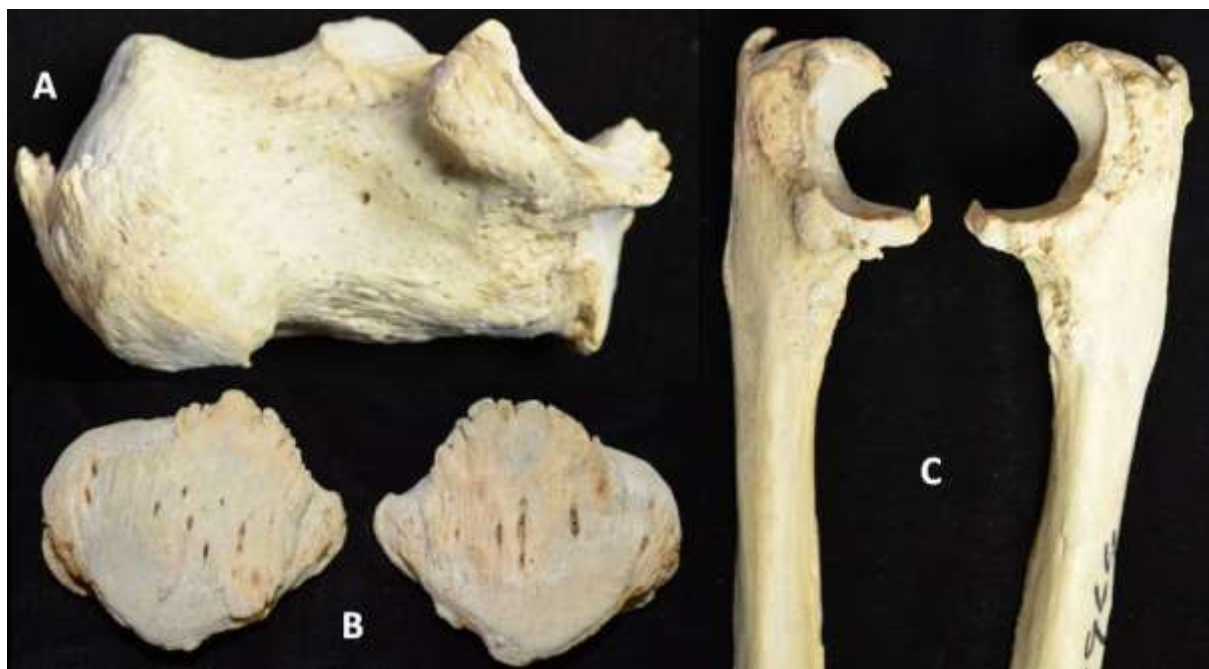

Figure 2. Extraspinal manifestation sometimes incorporated into the diagnosis of DISH. A) Image showing ossification on the calcaneus (insertion of *M. triceps surae*), B) on the patellae (insertion of *M. quadratus femoris*), and C) at the proximal ulnae (insertion of *M. triceps brachii*).

DISH in a Clinical Context

Some patients with DISH can be asymptomatic, however others can present with back and/or neck pain, restriction of mobility of the spine, peripheral joint affection, dysphagia due to distorsion or compression of the oesophagus, foreign body sensation, hoarseness, myelopathy due

to ossification of the posterior longitudinal ligament, hyperuricemia, obesity, hypercholesterolaemia and resulting cardiovascular comorbidities (Artner et al., 2012). A higher frequency of DISH has been shown in certain population groups over others with the disease apparently being common in Japanese and Pima Indian populations, but relatively rare in African-American and Asian groups (Mazières and Rovinsky, 2000). In a study of the lateral chest radiographs of 1500 black South Africans, the reported overall prevalence of DISH was 3.9%, with 52.4% of the individuals diagnosed with DISH (using a modified Resnick and Niwayama (1976) criteria) also having diabetes (Cassim et al., 1990). DISH has an estimated prevalence of 25% in males over the age of 50 years and 15% in females over the age of 50 years in American Midwesterners (Weinfeld et al., 1997; Vigorita, 2008), while other studies report 3-6% prevalence of the population over the age of 40 and 11% over the age of 70 (Sarzi-Puttini and Atzeni, 2004; Gorman, 2005).

The large variation in the reported incidence could be associated with the methods used to assess and record the disease, but most probably reflects the varying underlying predisposition for the disease in various groups. It is therefore still not completely understood whether this is truly a disease of lifestyle, or what the contribution of genetics is.

The treatment for DISH seems to focus on pain management and treatment for stiffness. Nonsteroidal anti-inflammatory drugs (NSAIDs) are prescribed for pain and physical therapy to improve the range of movement. In severe and rare cases, a patient may require surgical intervention to remove excess bone at joint margins.

DISH in the Paleopathological Literature

Paleopathologic studies of DISH have focused on linking its prevalence in past populations to certain divisions of society. Several studies have assessed the frequency of DISH between monastic and lay populations and a pattern has emerged showing a higher frequency of DISH amongst individuals buried in monastic cemeteries (Waldron, 1985; Rogers and Waldron, 2001; Jankauskas, 2003; Mays, 2006; Verlaan et al., 2007), indicating that people living in monasteries (monks/priests) had a distinguishable contributing factor to DISH. This factor was mostly suggested to be a generally better, but much richer diet that was high in protein. Four of these studies are discussed in more detail below, in order to illustrate the association of signs of DISH with individuals who are well or over nourished.

In a study of the monastic site of Merton Priory (1140 – 1540 CE) in Surrey, England, there was an overall prevalence of 8.6% of DISH out of 35 burials found at the site. Waldron (1985) did not

state what criteria was used to make a positive diagnosis of DISH in his study at Merton Priory, however a reference was made to the extraspinal manifestations described by Resnick et al. (1975). The individuals from Merton Priory, with the exception of the one female found at the site (presumably a benefactress of the priory), are assumed to have been priors (Waldron, 1985). In a similar analysis of two archaeological cemeteries by Rogers and Waldron (2001), a trend between monastic cemeteries and DISH was emerging.

The first sample of skeletons came from excavations (1978 and 1982) at the Wells Cathedral in England where DISH was analysed from three groups; individuals from the lay cemetery (n=93), individuals from the 13th century Lady chapel (n=15) and individuals from the 16th century Stilington's chapel (n=13). The prevalence of DISH was assessed using the Rogers and Waldron (1995) criteria and was reported as 6.5%, 13.3% and 23.1% for each of the groups respectively. The second group of skeletons to be analysed were excavated from the Royal Mint site in London, England, where there were representations from the lay cemetery (n=99) and individuals buried in the church and chapels (n=52). There was no DISH diagnosed amongst the individuals in the lay cemetery, however, there was a prevalence of 11.5% found in the individuals of the church and chapels (Rogers and Waldron, 2001).

Skeletal material (n=458) from several archaeological sites which covered a long time period (spanning from the 1st millennium AD to the 2nd millennium AD) in Lithuania were studied for the incidence of DISH; the diagnostic method used to diagnose the condition was not specified (Jankauskas, 2003). The total sample was divided into three categories of social status dependant on where an individual was found buried. If an individual was found buried inside a church, they were considered to be of high status ("Rich"), if an individual was excavated from an urban cemetery then they were assumed to have been of 'middle to lay' status ("Lay"), and if an individual was found buried in a rural area they were assumed to be of low or a peasant status ("Poor"). With both the sexes pooled together there was a prevalence of 27.13% (36% males, 5% females) of DISH within the individuals considered to be of a 'Rich' social status, 11.86% (11.86% males, 3.13% females) of individuals were diagnosed with DISH from the 'Lay' social status and 7.14% (16.96% males, 1.64% females) from those considered to be from a 'Poor' social status (Jankauskas, 2003).

An analysis of 42 adults (275-1795 CE) excavated from the Pandhof site in the city of Maastricht, The Netherlands also continued this trend of investigating ancient clergymen and their apparent predisposition towards DISH, with a 40.4% prevalence rate (Verlaan et al., 2007). All studies discussed showed a strong correlation between the prevalence of DISH and increasing age. Also, the main factor identified to be contributing to DISH is a generally rich diet, one that is

specifically higher in animal protein than those of other individuals. This led to the consideration that DISH is a disease of lifestyle, mainly acquired by individuals in a higher socio-economic status, who could afford to eat a diet rich in animal protein and calories, such as monks in medieval Europe (Waldron, 1985; Rogers and Waldron, 2001; Jankauskas, 2003; Verlaan et al., 2007). The intricacies of socio-economic status across different countries and how it has changed over time cannot be explored here and it should be kept in mind that the converse is not true - an archaeological skeleton diagnosed with DISH does not imply that the individual was of a high status (Rogers and Waldron, 2001). Rather it seems that certain lifestyles may be a precursor to, but not the only causative agent of DISH and this seems a plausible explanation that needs further validation in contemporary populations. However, it seems a comparison between archaeological and clinical studies cannot be fully explored until the issue of a standardised diagnostic method is faced.

Diagnostic Criteria

There can be practical difficulties when it comes to assessing and diagnosing DISH, especially with regard to the choice of diagnostic criteria (Resnick and Niwayama, 1976; Arlet and Mazières, 1985; Utsinger, 1985; Crubézy, 1990; Crubézy and Crubézy-Ibáñez, 1993; Rogers and Waldron, 1995; Kacki and Villotte, 2006). Some criteria have been developed solely for clinical assessments (Resnick and Niwayama, 1976; Arlet and Mazières, 1985) while some have been adapted or created for paleopathological applications (Crubézy, 1990; Rogers and Waldron, 1995; Kacki and Villotte, 2006). The main issue with a clear standard criterion for diagnosing DISH (specifically in skeletal remains) is the lack of consensus among researchers on definitive characteristics of the disease. Two types of criteria exist, namely rachidian (spinal) and extra-rachidian (Crubézy, 1990).

The Resnick criterion (Resnick and Niwayama, 1976) is considered a rachidian method and is widely used as a diagnostic tool for DISH. There are three main features for diagnosis, (1) flowing bony ossification along the anterolateral aspect of at least four contiguous vertebral bodies; (2) preservation of the intervertebral disc height of the affected vertebrae; and (3) absence of apophyseal joint bony ankylosis and sacroiliac joint erosion. Primarily a clinical diagnostic method using radiography, the Resnick criterion has been adapted by various authors for diagnosing DISH in skeletal material, both in an archaeological and forensic context. However, the main issue associated with the Resnick diagnostic criterion lies with the diagnosis of earlier or developing cases of DISH, as the characteristic flowing ossification may take many years to fully form and for several contiguous vertebrae to fuse. Individuals are commonly observed to present with characteristic bony changes of DISH even with little spinal involvement (Rogers and Waldron, 2001). It is a very rigid method that discounts a diagnosis of DISH if there is the presence of degenerative disc disease, or vertebral

osteoarthritis also present within the same individual. This seems counterintuitive considering the frequency of vertebral osteoarthritis and degenerative disease in older individuals, and DISH's propensity towards individuals of an older age. It seems likely that the conditions might occur together and should be considered as such. In addition, it means the one can only diagnose the disease when it is in a rather advanced stage (for obvious observational reasons), nonetheless, perhaps leaving a patient in a stage too late to consider any treatment to prevent its progression.

Arlet and Mazières (1985) is another clinical rachidian method, excluding the presence of extra-rachidian (extraspinal) manifestations, and is an adaptation of the Resnick criteria. There must be flowing ossification of the anterior longitudinal ligament of three contiguous vertebral bodies in the lower thoracic region. Para-articular ossification of the iliolumbar or sacroiliac ligaments may be observed, with retention of the sacroiliac joint surface, however, no ankylosis of the sacroiliac joint occurs. The cervical vertebrae may be affected anteriorly, with ossification of the apical ligament of the axis and retention of the intervertebral disc space and apophyseal joints (as seen in the thoracic and lumbar regions). In affected lumbar vertebrae the ossification is described as often extensive but discontinuous. Again, when met, the criteria only seems to identify individuals in the advanced stages of the disease, leaving earlier cases undiagnosed and although the method attempt to alleviate the ambiguous nature of the disease's development throughout the vertebrae, the study does not consider extraspinal manifestations bar the ossification of the sacroiliac and iliolumbar ligaments.

Utsinger's (1985) method also confronts the issue of rigidity with the characteristics used to diagnose DISH by providing descriptions for diagnosing cases of 'definite DISH', 'probable DISH' and 'possible DISH'. For a 'definite DISH' diagnose an individual must possess ossification across the anterolateral surface of four contiguous vertebrae, in the thoraco-lumbar region. There should be retention of the intervertebral disc space and apophyseal facets with no evidence of ankylosis. A diagnosis of 'probable DISH' is given to individuals displaying ossification across the anterolateral surface of two vertebrae in conjunction with the presence of bilateral extraspinal enthesophytes at the ulnae (insertion of the *m. triceps brachii*), patellae (insertion of the *m. quadriceps femoris*) and calcanea (insertion of the *m. triceps surae*). If an individual possesses ossification across the anterolateral surface of two contiguous vertebrae but has no extraspinal enthesophytes, then a diagnosis of 'possible DISH' is given. This criteria provides flexibility with three categorisations of DISH and according to the criterion, those who were diagnosed with 'probable DISH' would in time, advance to 'definite DISH' (Utsinger, 1985). This method also addresses the issue of extraspinal

manifestations, a characteristic frequently associated with DISH. It is also apparent that Utsinger is trying to address the issue of diagnosing earlier cases of DISH.

Rogers and Waldron (2001) have also provided a criterion, but developed specifically for the paleopathological diagnosis of DISH. The diagnosis takes both spinal and extraspinal manifestations into account. For diagnosing DISH in skeletal remains, ossification/calcification across at least three contiguous vertebrae, (with or without ankylosis) should be present and the changes confined to the right side in the thoracic region. There should be retention of the intervertebral disc space and apophyseal facets with no evidence of ankylosis. There should be evidence of bilateral extraspinal ossifications/calcifications. Although not specifically mentioned they may include enthesophytes at one or all of the following; ulnae (insertion of the *M. triceps brachii*), patellae (insertion of the *M. quadriceps femoris*), calcanea (insertion of the *M. triceps surae*), tibial tuberosities and ossification of the *lig. flava*. This method provides a more flexible diagnosis of DISH in skeletal remains, considering that the progression and time scale in which the disease manifests is still not fully understood. Rogers and Waldron (2001) comment on the frequency with which vertebral osteoarthritis (VO) and degenerative disc disease (DDD) affect individuals of an older age. DISH is primarily a disease of individuals over 45 years of age, who could also be susceptible to developing VO and DDD, which is why the absence of such conditions should not be used for diagnostic purposes.

A comprehensive study assessing the comparability of four different sets of diagnostic criteria on the same human skeletal sample was undertaken by Van der Merwe et al. (2012) and has shown a large amount of variability in diagnosis depending on the choice of criterion used. The Resnick and Niwayama (1976), Arlet and Mazières (1985), Utsinger (1985) and Rogers and Waldron (2001) diagnostic criteria for DISH were applied to a sample of 253 skeletons to assess the difference in their rates of diagnosis. The prevalence of DISH according to the four different diagnostic criteria was 5.5%, 11.5%, 11.1% and 17.0% respectively. This clearly shows the difficulty with firmly diagnosing this condition; an issue that has still not been fully resolved.

Differential Diagnosis in paleopathology

DISH is relatively easy to diagnose paleopathologically, when the bony lesions are well developed and the preservation is good. This suggests that paleopathologists can make significant contributions to the understanding of the condition, although there are still issues with early diagnosis. However, a differential diagnosis of DISH should always be considered and can be challenging when an early presentation of the disease can be confused with some variants of spinal degenerative disease and ankylosing spondylitis, and can occur with other conditions such as erosive

arthropathies and osteoarthritis (Ortner, 2003). In fact it has been suggested that previous to the 1950s, individuals may have been misdiagnosed, as DISH was not mentioned in the contemporary literature (Rogers et al., 1985).

DISH vs. Ankylosing Spondylitis

Ankylosing spondylitis is clinically characterised as a chronic inflammatory rheumatic disease, and like DISH has some enthesal involvement. Ankylosing spondylitis is described as a seronegative spondyloarthropathy, while also being strongly associated with a subtype of the human leukocyte antigen B27 (HLA- B27) (Rogers and Waldron, 1995; Ortner, 2003; Aliabadi et al., 2006; Baraliakos et al., 2013; Sieper and Braun, 2014).

Differences in the skeletal presentation between DISH and ankylosing spondylitis can be used for positive identification in paleopathological cases, and this distinction can be made in a clinical setting (Aliabadi et al., 2006). Ankylosing spondylitis usually begins in the lumbar spine and sacroiliac joints, while DISH occurs in the thoracic region of the vertebrae. Although there may be sacroiliac involvement observed in both ankylosing spondylitis and DISH, ankylosing spondylitis usually presents with bilateral involvement, whereas DISH could be unilateral. In individuals with ankylosing spondylitis the sacroiliac joint will reduce in space, usually as a result of cartilage destruction, and will ultimately result in ankylosis between the auricular surface of the ilium and sacrum, complete obliteration of the joint and a continuity in trabecular bone at the junction (Rogers and Waldron, 1995; Ortner, 2003). The macroscopic appearance of the spinal involvement of each disease when fully formed are very different, with DISH frequently being referred to as 'candle-wax' in appearance and the syndesmophytes of ankylosing spondylitis (bony outgrowths at the margins of the vertebral bodies) having been said to resemble "bamboo" (Rogers and Waldron, 1995; Ortner, 2003). This effect is created due to a sequence of events; the first step being inflammation, the erosion of structural bone and cartilage, followed by invasion of repair tissue and the subsequent ossification of the repair tissue (Sieper and Braun, 2014). As previously stated, ankylosing spondylitis begins in the lumbar region and can extend superiorly through the spine to involve the thoracic vertebrae and the costovertebral joints, potentially progressing to the cervical spine – with no 'skipped' lesions (Waldron, 2009). In DISH the costovertebral joints are less affected by the progression of the disease throughout the spine. The development of the syndesmophytes in ankylosing spondylitis can include the entire vertebral body, whereas in DISH the ossification/calcification is limited to the right anterolateral side of the thoracic vertebrae. This unique presentation has been attributed to the pulsation of the aorta, preventing the ossification/calcification (Fig. 3). Ankylosing spondylitis tends to affect younger individuals, with a

peak onset being between 20 and 30 years of age (Aliabadi et al., 2006; Sieper and Braun, 2014). In contrast, DISH usually occurs in individuals aged 40+ years, with the disease increasing with advancing age (Rogers and Waldron, 1995; Aliabadi et al., 2006; Mader, 2008; Roberts and Manchester, 2010). Therefore, age at death (in paleopathology specifically), can be used as a positive diagnostic tool.

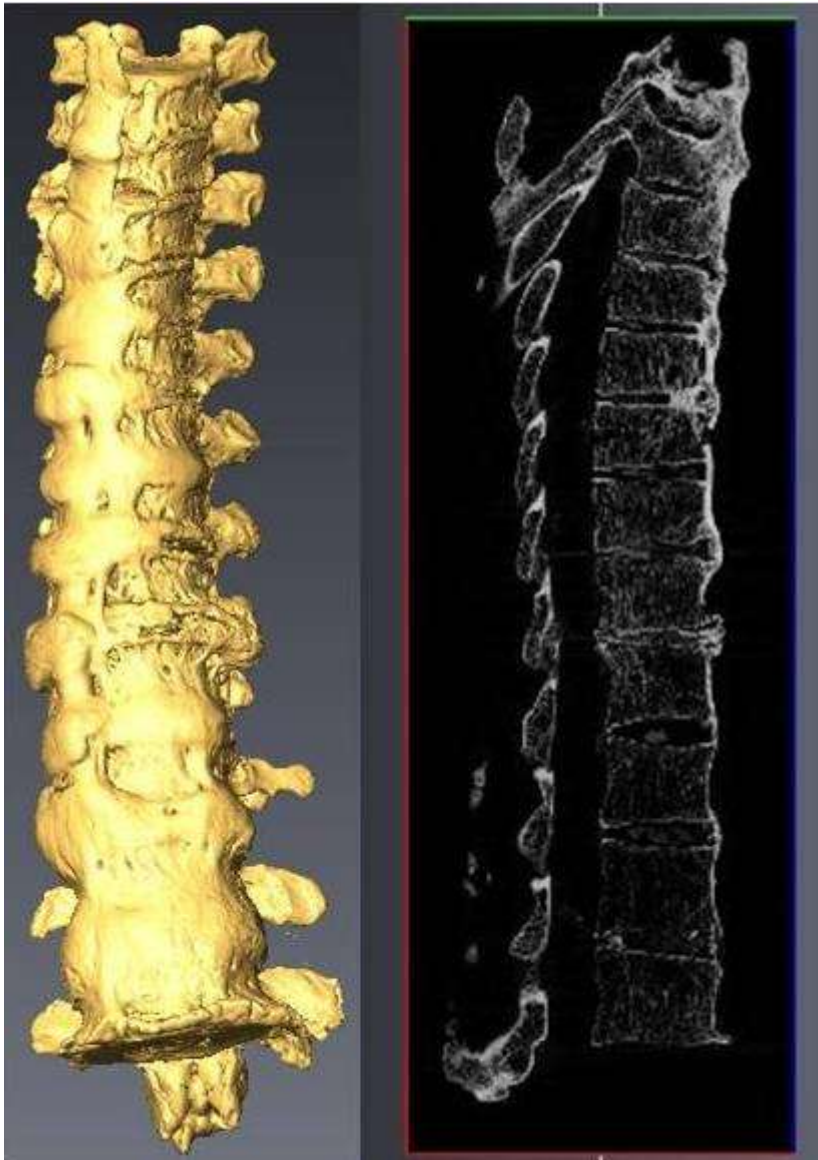


Figure 3. 3D reconstruction of vertebrae shown in Fig 1, with a sagittal slice. Reconstructed with Avizo 7.1 software (VSG). Radiography is useful to see the retention of the intervertebral disc space when ankylosis across the whole vertebral body has occurred, which is a key diagnostic feature of DISH.

There are some cases where DISH and ankylosing spondylitis have been reported to have occurred in the same individual simultaneously, but this is very rare (Tischler and Yaron, 1992; Moreno et al., 1996).

DISH vs. Vertebral Osteophytes

Vertebral osteophytes are extremely common in the paleopathological literature and, similar to DISH, its prevalence increases with age (Rogers and Waldron, 2001; Ortner, 2003). Vertebral osteophytes take origin from where the fibres of the annulus fibrosus of the intervertebral discs attach, and have been known to develop horizontally and over time may become vertically inclined. This is different from the formation of the syndesmophytes seen in AS, which tend to be more vertically inclined (Rogers and Waldron, 1995). They occur for a variety of reasons, one of which is as a result of mechanical stress on the intervertebral disc as primary weight bearing structures (Maat et al., 1995). Vertebral osteophytes can also occur with disc changes in vertebral osteoarthritis, which also has a correlation with increasing age (Maat et al., 1995; van der Kraan and van den Berg, 2007). Some might argue that vertebral osteophytes are a typical feature of growing old and may not be diagnostically significant in some cases (Rogers and Waldron, 1995; van der Kraan and van den Berg, 2007).

Discussion

It is clear from paleopathological studies that DISH is truly a disease of antiquity, but a condition which is still very relevant and common today. Considering how debilitating the disease could potentially become when complete ankylosis of the spine occurs - with conditions such as severe kyphosis and dysphagia - there may not be enough emphasis placed on the prevention of the condition. Of course this can be difficult due to the unknown etiology of the disease. However, exercise and physical therapy concentrating on the spine might be a key preventative measure. Perhaps movement or activity may be the key mechanism behind the pulsation of the aorta along the left side of the anterior surface of the vertebrae, preventing ossification/calcification. Other aspects that remain unexplored are whether control of blood sugar and/or cholesterol levels (if it is a disease of lifestyle) play any role in the prevention of the development of these ligamentous ossifications. The development of diagnostic criteria where earlier cases of DISH can be identified is paramount to this prevention and perhaps this is where paleopathologists can assist.

The issue of a standardised diagnostic criterion is something that needs to be addressed not only for early detection of DISH to implement preventative measures for patients but for analytical reasons. Studies have shown that no direct comparisons between the prevalence rates of DISH of different populations, let alone between archaeological and clinical populations, can be made due to these discrepancies (van der Merwe et al., 2012). This becomes increasingly problematic when the diagnostic criteria utilised to establish DISH in certain studies are not stated.

Although paleopathologists are limited by the static snapshot of the conditions they are presented with, researchers use modern collections with known medical records and biological profiles, to limit error in these classifications and open them to a wealth of knowledge. The use of dry bone rather than living patients means that paleopathologists are less restricted by the techniques they can use in their investigations – not to say there aren't ethical considerations. For example, the use of micro-CT scans in human imaging is limited to a resolution of ~82 µm due to concerns of radiation exposure, but dry bone can achieve images with a voxel size of 8 µm (Burghardt et al., 2011). Studies in a paleopathological context can open up research to a great degree of exploration in the types of techniques and technologies one can employ. Therefore, it seems that we could potentially see more differences in the details of the conditions manifestations in dry bone with the use of advanced imaging techniques such as micro-CT- without having to worry about radiation damages to the specimen.

Acknowledgements

We would like to thank the staff at the South African Nuclear Energy Corporation (Necsa) for their time and assistance in providing the micro-CT images referenced within the text. The research of M Steyn is supported by the National Research Foundation (NRF) of South Africa.

References

- Aliabadi H, Biglari D, Gonzalez LF, Nakaji P. 2006. Diffuse Idiopathic Skeletal Hyperostosis versus Ankylosing Spondylitis: Brief Case Review. *Barrow Quarterly* 22:10-14.
- Arlet J, Mazières B. 1985. La maladie hyperostotique. *Rev Med Interne* 6:553-564.
- Artner J, Leucht F, Cakir B, Reichel H, Lattiq F. 2012. Diffuse idiopathic skeletal hyperostosis: current aspects of diagnostics and therapy. *Orthopade* 41:916-922.
- Baraliakos X, Haibel H, Fritz C, Listing J, Heldmann, F, Braun J, Sieper J. 2013. Long-term outcome of patients with active ankylosing spondylitis with etanercept-sustained efficacy and safety after seven years. *Arthritis Res Ther* 15:R67.
- Burghardt AJ, Link TM, Majumdar S. 2011. High-resolution Computed Tomography for Clinical Imaging of Bone Microarchitecture. *Clin Orthop Relat R* 469:2179-2193.
- Cassim B, Mody GM, Rubin DL. 1990. The Prevalence of Diffuse Idiopathic Skeletal Hyperostosis in African Blacks. *Br J Rheumatol* 29:131-132.

- Crubézy E. 1990. Diffuse Idiopathic Skeletal Hyperostosis: Diagnosis and importance in Paleopathology. *J Paleopathol.* 3:107-118.
- Crubézy E, Crubézy-Ibáñez E. 1993. Evaluation of diagnostic criteria for hyperostotic disease on a series of skeletons. Epidemiological implications. *Rev Rhum Engl Ed* 60:586-590.
- Eckertova M, Krskova K, Penesova A, Radikova Z, Zlnay D, Rovensky J. 2009. Impaired insulin secretion and uptake in patients with diffuse idiopathic skeletal hyperostosis. *Endocr Regul.* 43:149–155.
- Forestier J, Rotés-Querol J. 1950. Senile ankylosing hyperostosis of the spine. *Ann Rheum Dis* 9:321-330.
- Gorman C. 2005. A family with diffuse idiopathic skeletal hyperostosis. *Ann Rheum Dis* 64:1794-1795.
- Jankauskas R. 2003. The incidence of diffuse idiopathic skeletal hyperostosis and social status correlations in Lithuanian skeletal materials. *Int J Osteoarchaeol* 13:289-293.
- Kacki S, Villotte S. 2006. Diffuse idiopathic skeletal hyperostosis and way of life: A bioarchaeological approach. *Bull Mém Soc Anthropol Paris* 18:55-64.
- Maat GJR, Mastwijk RW, van der Velde EA. 1995. Skeletal Distribution of Degenerative Changes in Vertebral Osteophytosis, Vertebral Osteoarthritis and DISH. *Int J Osteoarchaeol* 5:289-298.
- Mader R. 2008. Diffuse idiopathic skeletal hyperostosis: time for a change. *J Rheumatol* 35:377-379.
- Mader R, Lavi I. 2009. Diabetes mellitus and hypertension as risk factors for early diffuse idiopathic skeletal hyperostosis (DISH). *Osteoarthritis Cartilage* 17:825-828.
- Mader R, Novofestovski I, Adawi M, Lavi I, 2009. Metabolic Syndrome and Cardiovascular Risk in Patients with Diffuse Idiopathic Skeletal Hyperostosis. *Semin Arthritis Rheum* 38:361-365.
- Mader R, Sarzi-Puttini P, Atzeni F, Olivieri I, Pappone N, Verlaan JJ, Buskila D. 2009. Extraspinal manifestations of diffuse idiopathic skeletal hyperostosis. *Rheumatology* 48:1478-1481.
- Mays S. 2006. The Osteology of Monasticism in Mediaeval England. In: Gowland R and Knüsel C, editors. *Social Archaeology of Funerary Remains*. Oxford: Oxbow Books. p 327-346.

- Mazières B, Rovensky J. 2000. Non-inflammatory enthesopathies of the spine: a diagnostic approach. *Rheumatology* 14:201-217.
- Moreno AC, Gonzalez ML, Duffin M, Lopez-Longo FJ, Carreno L, Forrester DM. 1996. Simultaneous occurrence of diffuse idiopathic skeletal hyperostosis and ankylosing spondylitis. *Rev Rhum Engl Ed* 63:292-295.
- Ortner DJ. 2003. Identification of pathological conditions in human skeletal remains. 2nd Ed. London: Academic Press.
- Pappone N, Di Girolamo C, Del Puente A, Scarpa R, Oriente P. 1996. Diffuse idiopathic skeletal hyperostosis (DISH): a retrospective analysis. *Clin Rheumatol* 15:121-124.
- Pillai S, Littlejohn G. 2014. Metabolic Factors in Diffuse Idiopathic Skeletal Hyperostosis - A Review of Clinical Data. *Open Rheumatol. J.* 8, 116–128.
- Resnick D, Niwayama G. 1988. Diagnosis of bone and joint disorders. 2nd Ed. Philadelphia: WB Saunders.
- Resnick D, Niwayama G. 1976. Radiographic and Pathologic Features of Spinal Involvement in Diffuse Idiopathic Skeletal Hyperostosis (DISH). *Radiology* 119:559-568.
- Resnick D, Shaul S R, Robins J M. 1975. Diffuse Idiopathic Skeletal Hyperostosis (DISH): Forestier's Disease with Extraspinal Manifestations. *Radiology* 115, 513-524.
- Roberts C, Manchester K. 2010. The Archaeology of Disease. 3rd Ed. Stroud: The History Press.
- Rogers J, Waldron T. 2001. DISH and the monastic way of life. *Int J Osteoarchaeol* 11:357-365.
- Rogers J, Waldron T. 1995. A field guide to joint disease in archaeology. Chichester : John Wiley and Sons.
- Rogers J, Watt I, Dieppe P. 1985. Palaeopathology of spinal osteophytosis, vertebral ankylosis, and vertebral hyperostosis. *Ann Rheum Dis* 44:113-120.
- Sarzi-Puttini P, Atzeni F. 2004. New developments in our understanding of DISH (diffuse idiopathic skeletal hyperostosis). *Curr Opin Rheumatol* 16:287-292.
- Sieper J, Braun J. 2014. Overview of Axial Spondyloarthritis. In: Sieper J, editor. *Clinician's Manual on Axial Spondyloarthritis*. London: Springer Healthcare Ltd. p 5-16.

- Tischler M, Yaron M. 1992. Two cases of diffuse idiopathic skeletal hyperostosis and ankylosing spondylitis. *Br J Rheumatol* 31:569-571.
- Utsinger PD. 1985. Diffuse idiopathic skeletal hyperostosis. *Clin Rheum Dis* 11:325-351.
- van der Kraan PM, van den Berg WB. 2007. Osteophytes: relevance and biology. *Osteoarthritis Cartilage* 15:237-244.
- van der Merwe AE, Maat GJR, Watt I. 2012. Diffuse idiopathic skeletal hyperostosis: Diagnosis in a palaeopathological context. *HOMO - J. Comp. Hum. Biol.* 63:202-215.
- Verlaan JJ, Oner FC, Maat GJR. 2007. Diffuse idiopathic skeletal hyperostosis in ancient clergymen. *Eur Spine J* 16:1129-1135.
- Vigorita VJ. 2008. *Orthopaedic Pathology*. 2nd ed. Philadelphia: Lippincott Williams & Wilkins.
- Waldron T. 1985. DISH At Merton Priory: Evidence For A "New" Occupational Disease. *B M J.* 291:1762-1763.
- Waldron T. 2009. *Palaeopathology*. Cambridge: Cambridge University Press.
- Weinfeld RM, Olson PN, Maki DD, Griffiths HJ. 1997. The prevalence of diffuse idiopathic skeletal hyperostosis (DISH) in two large American Midwest metropolitan hospital populations. *Skeletal Radiol* 26:222-225.