

Deaths from bee stings: A report of three cases from Pretoria, South Africa

Authors:

Corresponding author: Lorraine du Toit-Prinsloo
Co-Authors: Neil Kenneth Morris
Pieter Meyer
Gert Saayman

Affiliation and addresses of the authors:

L du Toit-Prinsloo: Specialist / Lecturer; University of Pretoria; Department of Forensic Medicine, Private Bag X323, ARCADIA, 0007 SOUTH AFRICA
MBChB, Dip For Med(SA)Path, FCForPath(SA), MMed(Path)(Forens)

NK Morris: Lecturer; University of Pretoria; Department of Forensic Medicine, Private Bag X323, ARCADIA, 0007 SOUTH AFRICA
BSc, BSc(hons) medical criminalistics, MSc medical criminalistics

P Meyer: Senior Lecturer / Specialist; University of Pretoria & National Health Laboratory Service, Tshwane Academic Division; Faculty of Health Sciences, Department of Immunology, Private Bag X323, ARCADIA, 0007 SOUTH AFRICA
NH Dip Biomedical Technology, MTech, PhD (Immunology)

G Saayman: Chief specialist / Head of Department; University of Pretoria; Department of Forensic Medicine, Private Bag X323, ARCADIA, 0007 SOUTH AFRICA
MBChB, MMed(Med)(Forens), FCForPath(SA)

E-mail address, telephone and fax numbers of the corresponding author:

L du Toit-Prinsloo
Email: lorraine.dutoit@up.ac.za
Telephone numbers: +27 (0)12 323 5298 (work)
+27 (0)83 406 4056 (mobile)
Fax number: +27 (0)12 323 0921

Abstract:

In South Africa bee stings are most commonly caused by either *Apis mellifera capensis* or *A. mellifera scutellata*, indigenous species which are notoriously aggressive when compared to European honey bees. According to Statistics South Africa, 109 deaths were documented for the period 2001 to 2011 as having been caused by hornets, wasps and bees (ICD10 – X26). This appears to be a small number but, as was reported in Australia, these statistics might be inaccurate due to either over- or under-reporting of cases. We report 3 cases of fatalities due to bee stings, including one with post mortem features of diffuse intravascular coagulopathy. A brief overview of the venom of the honey bee, reactions following a bee sting and possible mechanisms of death are presented. Confirming the diagnosis in these cases may be very problematic for the forensic pathologist, as in many cases minimal history is available and both external and internal examination could fail to reveal any specific signs of bee sting or other obvious morphologic abnormalities. There is thus a need for reliable confirmatory or supportive diagnostic tests.

Keywords: Beestings; anaphylaxis; tryptase; medico-legal post mortem examination; envenomation

Introduction:

Most bees in South Africa are from the species *Apis mellifera capensis* and *Apis mellifera scutellata*. [1] *A. mellifera* in South Africa is a notoriously aggressive species when compared to the European honey bee. [2] In 1968 it was documented that for the period 1961-1967 there were 24 fatal outcomes due to bee stings in the Transvaal province. [2] More recently, Statistics South Africa (Stats SA) recorded 109 fatalities due to contact with hornets, wasps and bees (ICD10 – X26) for the period 2001-2011 (Figure 1). [3] According to Stats SA the associated mortality rate ranges from 0.008 per 100 000 population to 0.030 per 100 000 per year for the stated period. [3]

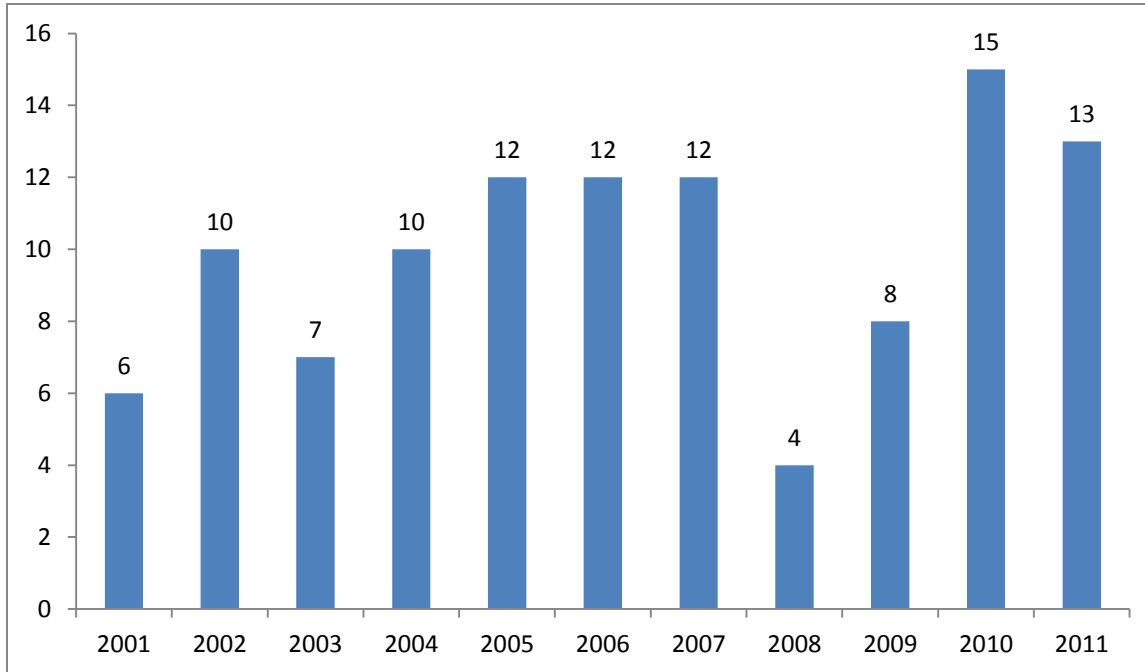


Figure 1: Number of deaths due to contact with hornets, wasps and bees (including yellow jacket) 2001-2011. (n=109)

In Australia, Harvey *et al* reported on the findings of the Australian Bureau of statistics and indicated that the overall bee sting-related death rate for Australia as 0.086 per 1 000 000 per year (varying from 0.05 to 0.26 per 1 000 000 per year). [4] These statistics are however deemed to be inaccurate due to both over-reporting (inclusion of deaths unrelated to bee venom) and under-reporting (sudden deaths where either a bee sting is not in the history or obvious at post-mortem examination). [4,5] Previous reports indicate that 80% of deaths associated with bee stings occurred in individuals who are younger than 5 years or older than 40 years of age and that they rarely occur in the 6-20 year age group. [4] In Sweden, Johansson *et al* reported on 20 deaths (19 due to wasps and only 1 due to bee sting) for the period 1975-1984 and also indicated that most of the decedents were adults (average age of 61 years). [6]

Death from bee stings may be the result of various pathophysiological mechanisms: an allergic / anaphylactic mechanism may be involved whilst envenomation from many bees may have a direct fatal outcome. The presence of pre-existing or underlying disease in the victim (co-morbid factors) may confound the picture further, as these may play an important contributory or even dominant role. The post mortem diagnosis of anaphylaxis remains problematic for the forensic pathologist. Da Broi *et al* have listed reasons for this:

1. Many anaphylactic deaths are unwitnessed and do not occur in hospitals, thus no recorded vital parameters or supporting history (suggesting an allergic response) are available;
2. Macroscopic and histological signs of anaphylaxis may be minimal or absent at autopsy;
3. Body fluids may not be available for testing;
4. There is a lack of reliable laboratory markers for anaphylaxis in the post mortem setting;
5. The background and experience of the forensic medical practitioner may play a role. [7]

The aim of this paper is to present three fatalities which resulted from bee stings (cases which were investigated at the Pretoria Medico-Legal Laboratory [PMLL]), with a view to critically assess the difficulties and opportunities in diagnosing this condition and to make further proposals regarding the medico-legal management of these cases.

Case reports:

Case 1:

A 38 year old male presented to a medical emergency room after having been stung by numerous bees. He was resuscitated for almost an hour, but despite resuscitative efforts, he died in the emergency department.

At autopsy, external examination showed approximately 25 sting sites consisting of small elevated red wheals on the abdomen as well as 2 sting marks on the right forearm, 2 on the left upper arm and 3 on the right ankle. The epiglottis and surrounds showed no obvious mucosal erythema and only minimal signs of edema. Features of iatrogenic injury included a fractured sternum and bilateral (anterior) fractures of the 4th and the 5th ribs with some intercostal contusion. In addition, there was patchy film-like subarachnoid hemorrhage over the brain and an ecchymotic subendocardial hemorrhage in the outflow tract of the left ventricle of the heart. An incidental finding of comorbid pathology was that of a well circumscribed, encapsulated tumor in the left adrenal gland, measuring 7 x 5cm and weighing 40g. Histological examination showed this to be a pheochromocytoma. Tissue slides of the lungs revealed small numbers of eosinophils and some intra-alveolar macrophages. Sections of the skin at one of sting sites showed slight dermal edema, vascular congestion and some extravasated free red blood cells in the underlying fibro-fatty tissues, but with no inflammatory infiltrate.

A post mortem blood sample was taken from the axillary vessels, approximately 15 hours after death. The serum tryptase level was found to be 70.2µg/L (normal levels being <10µg/L) and venom IgE antibodies were detected, with a level of 3.2 kAU/L (normal level being <0.35 kAU/L). The finding of elevated levels of specific IgE antibodies to bee venom is in keeping with bee venom hypersensitivity and indicative of previous sensitization with circulating specific IgE antibodies.

Case 2:

A 58 year old male, with a known bee allergy, was rushed to the emergency department after sustaining a bee sting. His condition was critical upon arrival, requiring active resuscitation. Unfortunately, he died soon after presenting to the emergency room.

Meticulous external examination of the body revealed features of medical treatment, but no evidence of a bee sting - or other abnormality - could be found macroscopically. Internal examination showed no edema or erythema of the laryngeal structures, but the heart was notably enlarged, with concentric left ventricular hypertrophy and a heart mass of 596g. No overt atherosclerotic coronary artery changes or features of ischemic heart disease were otherwise seen. No macroscopic cause of death could thus be ascertained at autopsy. Histological examination of tissue slides showed only non-specific findings of edema and congestion of the lungs and most other parenchymal organs.

In this case, a post mortem blood sample was collected only approximately 96 hours after death. The post mortem serum tryptase level was found to be >200µg/L, whilst the bee venom IgE antibody level was 0.04 kUA/L (deemed to be negative).

Case 3:

A 58 year old male died at the scene of injury after allegedly having been stung by bees. External examination revealed the residual presence of 5 bee stingers in the skin, 3 on the upper eyelids and 2 on the cheeks. Mild peri-orbital swelling involving predominantly the upper eyelids was present. Internal examination of the body again showed no distinct edema or erythema of the glottis or laryngeal structures. No other significant macroscopic findings were made, whilst histological examination similarly revealed only non-specific systemic / organ changes, with no evidence of an inflammatory infiltrate at the sting sites or elsewhere. Stereomicroscopic examination of stinger removed from the eyelid of the victim at autopsy confirmed the anatomical features of a stinger in keeping with that of the *A. mellifera* species. A femoral blood sample was collected approximately 6 hours after death and the post mortem tryptase level was reported to be 49 µg/L. The bee venom IgE antibodies were positive (measuring 23.5 kAU/L).

Discussion:

Deaths from bee stings constitute a very small number of registered deaths, as reported in South Africa and Sweden.[3,6] Nonetheless, as stated by Riches *et al* from Australia; it is likely that official figures are substantially under-representative of the real incidence of such deaths.[5] The venom of the honey bee is a complex mixture of molecules, with several active peptides / proteins including: mellitin (a peptide which causes hydrolysis of cell membranes and histamine release), Peptide 401 (causes degranulation of mast cells), Phospholipase A₂ (regarded as being primarily responsible for the allergic reaction in conjunction with mellitin) and vasoactive amines, including histamine.[5,8-10,]

The pathophysiology regarding bee stings can broadly be divided into localized and systemic reactions.[11] The localized reactions can be allergic or non-allergic. The non-allergic reactions are regarded to be as a direct result of the toxic components of the venom and include the local reactions seen at the site of the sting. Larger local reactions are regarded as an allergic reaction to the venom proteins.[12] Systemic reactions include the clinical features of anaphylaxis.[13] Allergic reactions are due to molecules mentioned above, with most patients reacting to phospholipase A, followed by hyaluronidase and few allergic reactions to mellitin.[11]

In general, 3 clinical reactions can be seen following a bee sting. Local pain and swelling, a larger local reaction due to allergic mechanisms and systemic anaphylaxis and very rarely a delayed hypersensitivity reaction.[4,14,15,] Deaths related to bee stings can either be caused by anaphylaxis (as appears to have been the case in all 3 cases presented in this paper) or as a result of severe local reaction.[4,5,11-15] The phenomenon of diffuse intravascular coagulopathy following a bee sting has been documented by Gawlik *et al*. [16] The pathogenetic mechanism may be attributed to mesothelial damage, activation of macrophages and thrombocytes and the release of leucotriene.[16] We believe that the first of our reported cases may have suffered some degree of such vasculopathy, resulting in the internal haemorrhages.

Riches *et al* proposed a classification in order to more accurately compare these deaths. [5] Type 1 cases include bee sting “related” deaths in which a bee sting is involved in the mechanism of death, but not directly causing the death. The example cited by them is that of a person who is stung by a bee but subsequently falls from a ladder. Type 2 cases represent a systemic reaction or anaphylactic death, due to an IgE-mediated acute hypersensitivity reaction (most common mechanism). Type 3 fatalities involve mass envenomation and are rare, generally resulting from more than 500 stings leading to direct toxic death rather than death by a systemic reaction to the stings.[5]

The medico-legal investigation and assessment of these cases can be problematic, as in many cases no substantial or supporting history is obtained and meticulous external and internal examination, as well as histological evaluation, may yield no pathognomonic or even suggestive results.[6,7] Each of the cases we present may serve to illustrate a diagnostic perspective regarding these deaths. In Case no. 1, where many sting sites were seen, the presence of underlying pathology in the form of a pheochromocytoma raises interesting questions: could it be that a secreting pheochromocytoma (with altered levels of catecholamines in the blood) could have played a role in the demise of the victim? In Case no. 2, meticulous post mortem examination showed no bee sting, but the victim had a known allergy to bees and had personally communicated to his wife that he had been stung by a bee. The tryptase level (which was very high) was derived from a post mortem blood sample taken some 96 hours after death, but correlated very well with the corroborated clinical history of an anaphylactic death. However, the comorbid condition of a markedly enlarged heart with concentric left ventricular hypertrophy (strongly suggestive of hypertensive heart disease) should certainly be considered in the formulation of the cause and/or mechanism of death. With Case no. 3 we present an apparently healthy individual with no history of allergies and no other comorbidities, but the presence of multiple stingers on the skin and elevated tryptase and IgE levels allowed for what we believe to be a valid diagnosis.

Clinical health care workers (including nursing staff and paramedics) as well as death investigation personnel must be vigilant at the scene or time of first medical treatment, taking care to identify possible stingers on the body or within the clothes. Stereomicroscopic examination of possible stingers may be helpful, as is described in our case no. 3. Special attention should be paid to examination of the laryngeal structures and the presence of non-specific signs such as even moderate hyperaemia, edema and hemorrhage should be noted.[5,17] Ancillary investigations should include histological examination of possible sting sites.[5] Histologically, the tract of the sting and

(depending on time elapsed), an inflammatory response (often with substantial numbers of eosinophils) are some of the features which may be present.[5,6]

The diagnosis of anaphylaxis at post mortem can be challenging.[5,7,17] Blood should be taken for tryptase levels and immunological screening (IgE) as these results may aid in the diagnosis.[5,6,18] The stability of post mortem tryptase levels has been questioned with reports indicating an elevation with a prolonged post mortem interval and other authors not reporting a correlation.[18,19] It is advised that these tests be conducted within 48 hours following death.[20] The exact level of tryptase which should support the diagnosis of anaphylaxis also differs in the literature and is said to be influenced by post mortem interval, site of collection and cause of death.[7,18,21,22]. Edston *et al* reported in 2007 that tryptase levels should be taken from femoral blood and that the normal upper level in 95% of cases was recorded as 44.3µg/l.[21] In 2015 McLean-Took *et al* stated that aortic samples should be taken and that values of >110µg/l can support the diagnosis of anaphylaxis, but the authors emphasise that the diagnosis should not be made solely on the value of the tryptase levels.[22]

The interpretation of IgE levels should also be done with caution in the post mortem setting. A positive IgE value does not confirm that an anaphylactic reaction had taken place, but probably show that the person was sensitive to the venom. [17] It has been reported in the United States of America that approximately 1% of blood donors have bee venom IgE antibodies, whilst in some deaths following bee stings, the IgE antibody status was reported to be negative.[17] We also report this in case number 2 where the patient had a known allergy to bee venom but had low levels of circulating bee venom IgE. Elevated levels of IgE in clinically allergic patients can be detected in about 10% of patients.[23]

In South Africa, the Inquests Act mandates the investigation of unnatural deaths. The latter are statutorily defined in the Regulations Regarding the Rendering of Forensic Pathology Services (R636 in terms of Chapter 11 of the National Health Act) and include, amongst others, “any death due to physical or chemical influence” as well as “where the death is sudden and unexpected, or unexplained, or where the cause of death is not apparent”. Interestingly, some pathologists here propose that most bee sting related deaths must be regarded as “natural” and need not be referred for medico-legal investigation. This is based on the premise that an anaphylactic reaction is a natural disease process and therefore death following a bee sting in a person known to be allergic, should be deemed natural, whereas multiple bee stings resulting in envenomation should be regarded as a “chemical influence” - and thus unnatural. Most authors however appear to subscribe to the view that these deaths (irrespective of the underlying pathophysiological mechanism) should undergo proper medico-legal investigation, presumably to include autopsy.[5,6,17]. We concur with the latter view. As stated above, establishing the cause of death in such cases may be difficult and a multiplicity of factors should be considered. Shen *et al* reviewed anaphylactic deaths in Maryland and Shanghai and concluded that “the postmortem diagnosis of anaphylactic deaths is usually based on exclusion and circumstantial evidence.”[24] A reasoned conclusion as to the probable cause of death can only be arrived at if there is due regard for all relevant perspectives, including clinical / medical history, information pertaining to the terminal event(s), anatomical (autopsy / histology) findings, as well as biochemical / humoral findings.[5-7, 21-24] We support the proposals by Riches *et al* in the classification of these deaths, in an attempt to achieve greater clarity and insight into these often tragic deaths.[5]

Key points:

- Deaths associated with bee stings present a diagnostic challenge to forensic pathologists, as there may be no specific history or definitive post mortem findings.
- A multiplicity of factors impact on the eventual diagnosis, including co-morbidities and instability / unpredictability of humoral factors in the post mortem period.
- Pathologists should maintain a high index of suspicion for such deaths and ensure that a thorough investigation is undertaken, to include full autopsy, histology and appropriate laboratory analyses.
- More research and review of data regarding the use and validity of post mortem markers such as IgE antibodies and serum tryptase values should be undertaken.

References

1. Bradbear N. Bees and their role in forest livelihoods: a guide to the services provided by bees and the sustainable harvesting, processing and marketing of their products. Rome: Food and Agriculture Organization of the United Nations; 2009. Ch2. p19. Available from: <ftp://ftp.fao.org/docrep/fao/012/i0842e/i0842e00.pdf> Accessed 27/10/2015
2. Ordman D. Bee stings in South Africa. *S Afr Med J.* 1968;42(44):1194-8.
3. Africa SS. P0309.3 - Mortality and causes of death in South Africa: Findings from death notification 2013. Available from: <http://www.statssa.gov.za/publications/statsabout.asp?PPN=P0309.3&SCH=5490>. Accessed 25 August 2014.
4. Harvey P, Sperber S, Kette F, Heddle RJ, Roberts-Thomson PJ. Bee-sting mortality in Australia. *Med J Aust.* 1984;140(4):209-11.
5. Riches KJ, Gillis D, James RA. An autopsy approach to bee sting-related deaths. *Pathology.* 2002;34(3):257-62.
6. Johansson B, Eriksson A, Ornehult L. Human fatalities caused by wasp and bee stings in Sweden. *Int J Leg Med* 1991;104:99-103.
7. Da Broi U, Moreschi C. Post-mortem diagnosis of anaphylaxis: A difficult task in forensic medicine. *Forensic Sci Int.* 2011;204:1-5.
8. Vetter RS, Visscher PK. Bites and stings of medically important venomous arthropods. *Int J Dermatol.* 1998;37(7):481-96.
9. Hoffman DR. Hymenoptera Venom Proteins. *Natural Toxins 2*, 1996. Springer. Chapter 10. p169-186
10. Banks BEC, Shipolini RA. Venoms of the Hymenoptera. *Biochemical, Pharmacological and Behavioural Aspects* 1986; 329-416
11. Rayamane AP, Kumar MP, Kishor DG et al. Honey bee stings and anaphylaxis: Review. *Journal of Forensic Medicine, Science and Law.* 2014;23(1):53-60
12. Wright DN, Lockey RF. Local reactions to stinging insects (Hymenoptera). *Allergy Proc.* 1990;11(1):23-8.
13. Ewan PW. Allergy to insect stings: a review. *J R Soc Med* 1985;78(3):234-9.
14. Golden DBK, Valentine MD. Insect sting allergy. In: Franklin EC, ed. *Clinical immunology update*. Edinburgh: Churchill Livingstone. 1981:169-196.
15. Light WC, Reisman RE, Shimisu M, Arberman CE. Unusual reactions following insect stings: clinical features and immunological analysis. *J Allergy Clin Immunol* 1977;59:391-399.
16. Gawlik R, Rymarczyk B, Rogala B. A rare case of intravascular coagulation after honey bee sting. *J Investig Allergol Clin Immunol.* 2004;14(3):250-2.
17. DiMaio VJ, DiMaio DD. *Forensic Pathology 2nd Ed (Practical Aspects of Criminal and Forensic Investigations)*: CRC Press; 2001 Ch 20, p469.
18. Edston E, van Hage-Hamsten M. beta-Tryptase measurements post-mortem in anaphylactic deaths and in controls. *Forensic Sci Int.* 1998;93(2-3):135-42.
19. Becker AB, Mactavish G, Frith E et al. Post-mortem stability of serum tryptase and immunoglobulin E. *J Allergy Clin Immunol* 1995;95:369
20. ImmunoCAP Tryptase - Phadia - Setting the Standard - Phadia.com 2014. Available from: <http://www.phadia.com/en/Products/Allergy-testing-products/ImmunoCAP-Lab-Tests/ImmunoCAP-Tryptase/>. Accessed 25 August 2014.
21. Edston E, Eriksson O, Van Hage M. Mast cell tryptase in postmortem serum – reference values and confounders. *Int J Legal Med* 2007;121:275-280.
22. McLean-Took A, Goulding M, Bundell C, White J, Hollingsworth P. Postmortem serum tryptase levels in anaphylactic and non-anaphylactic deaths. *J Clin Pathol* 2014;67:134-138.
23. Golden DBK. New directions in diagnostic evaluation of insect allergy. *Curr Opin Allergy Clin Immunol* 2014;14:34-339.
24. Shen Y, Li, Grant J et al. Anaphylactic deaths in Maryland (United States) and Shanghai (China): A review of forensic autopsy cases from 2004 to 2006. *Forensic Sci Inter* 2009;186:1-5.