

OVINE HEPATOGENOUS PHOTSENSITIVITY CAUSED BY THE PLANT *NIDORELLA FOETIDA* (THUNB.) DC. (ASTERACEAE)

D. J. SCHNEIDER⁽¹⁾, JENNIFER R. GREEN⁽¹⁾ and M. G. COLLETT⁽²⁾

ABSTRACT

SCHNEIDER, D. J., GREEN, JENNIFER R. & COLLETT, M. G., 1987. Ovine hepatogenous photosensitivity caused by the plant *Nidorella foetida* (Thunb.) DC (Asteraceae). *Onderstepoort Journal of Veterinary Research*, 54, 53-57 (1987)

Following a field outbreak of hepatogenous photosensitivity in sheep, an identical condition was reproduced experimentally by dosing 2 sheep with green, homogenized, *Nidorella foetida* material, collected from the camp where the outbreak occurred. This is a rare, unpalatable, aromatic shrub found in swampy places in the south-western Cape Province. The main lesion was a hepatitis, characterized by peripheral coagulative necrosis and midzonal degeneration in the 2 acute cases and mild bile duct proliferation and hepatic regeneration in the more chronic field case.

Botanical, toxicological, clinical and pathological data are given.

INTRODUCTION

Many hepatotoxic plants, among them a fungus and an alga, are known to cause liver damage when ingested by sheep and cattle in South Africa. Poisonings by some of these hepatotoxic agents are frequently associated with photosensitivity, usually in less acute cases (Steyn 1949; Marasas, Adelaar, Kellerman, Minné, Van Rensburg & Burroughs, 1972; Kellerman, Basson, Naudé, Van Rensburg & Welman, 1973; Coetzer & Bergh, 1983; Kellerman, Coetzer, Schneider & Welman, 1983).

Although the aetiologies of most forms of hepatogenous intoxications are known, a few remain unresolved, and without identification the causative agents of the latter no rational control measures can be implemented in these cases.

This is the first report of ovine hepatogenous photosensitivity caused by *Nidorella foetida*.

HISTORY OF THE FIELD OUTBREAK

Ovine hepatogenous photosensitivity of unknown aetiology occurred during 1983 in a 30 ha camp on a farm in the Durbanville District near Cape Town.

On 20 March 1985, 15 out of 300 South African Muton Merino sheep from 9 months to 4 years of age were found to be photosensitive 5 days after having been placed in the camp. The grazing consisted of dry wheat stubble with *Cynodon dactylon* (L.) Pers. along the borders. Apart from a few dry, well-known, unpalatable shrubs growing along one fence, a patch of green *N. foetida* shrubs was present in a localized moist area in a dry waterway. Most of the accessible *Nidorella* plants had been freshly grazed by the sheep.

All the sheep were taken out of the camp on 20 March 1985 and the 15 affected sheep were stabled. One large sack of fresh *N. foetida* plants was collected from the camp and taken to the Regional Veterinary Laboratory, Stellenbosch, for botanical identification and toxicity trials.

The plant was identified by the Government Herbarium, Stellenbosch, as *Nidorella foetida* (Thunb.) DC.

DESCRIPTION, DISTRIBUTION AND ECOLOGY OF THE PLANT

Family

Asteraceae (Compositae).

Name

Nidorella foetida (Thunb.) DC.

Description (Fig. 1-3)

A branched, erect, hairy perennial, slightly woody at the base. Height up to about 1 m. 'Leaves' bright-green, often tufted, linear-spathulate, obtuse, covered with short glands mingled with coarse hairs. 'Capitula' yellowish, rather small, densely corymbose. 'Involucral bracts' imbricate, oblong mucronate, raised and hairy in the middle and with a scariosus, gland-fringed margin. The transition from marginal to central flowers gradual, the sterile central flowers having a more conspicuous corolla than the remainder. 'Flowering time' from January to October (Adamson & Salter, 1950; Welman, Wilhelmina G., 1986. Botanical Research Institute, Private Bag X101, Pretoria 0001 pers. com.)

Distribution

The plant is rather rare and is found only in the south-western Cape Province. There it has been found in Coastal Renosterveld and West Coast Strandveld and has been recorded in the following districts: Llandudno, Wynberg, Simon's Town, Camps Bay, Bredasdorp, Somerset Strand, Velddrif, Uilskraalmond and Hangklip (Welman, Wilhelmina G., 1986. Botanical Research Institute, Pretoria pers. com.)

Eleven *Nidorella* spp. are described in South Africa (Gibbs Russell, G. E. and the staff of the National Herbarium, 1984) with 3 occurring in the winter rainfall area (Moffett, R. O., Government Herbarium, P.O. Box 471, Stellenbosch 7600 pers. com.)

Habitat

N. foetida is usually found in full sun, near water, in marshy or seasonally marshy ground, often growing with reeds. It is found in a winter rainfall area, measuring 250-500 mm rain per annum, at an altitude between 3 and 170 m.

MATERIALS AND METHODS

Field outbreak

Blood samples for chemical pathological determinations (Table 2) were collected on 20 March 1985 from 4 of the 15 affected sheep. Eight days later another of the affected sheep (No. 8), 9 months old, was taken to the Regional Veterinary Laboratory, Stellenbosch. A blood sample was collected and the animal killed and autopsied. Tissue specimens of liver, gall bladder, kidney, spleen, heart and affected skin were placed for fixation in 10 % buffered formalin and processed for light microscopy.

A representative pasture sample from this camp, mainly wheat stubble and *C. dactylon*, was collected and examined for *Pithomyces chartarum* (Berk. & Curt.) M. B. Ellis, spores, as described by Di Menna & Bailey, 1973.

⁽¹⁾ Regional Veterinary Laboratory, Private Bag X5020, Stellenbosch 7600

⁽²⁾ Department of Pathology, Faculty of Veterinary Science, P.O. Box 12580, Onderstepoort 0110

Received 21 October 1986—Editor



1



2

FIG. 1-3 *Nidorella foetida*



3



4

FIG. 4 Very early stage of photosensitivity in Sheep 2

Toxicity tests in sheep

The green parts of the *N. foetida* plant material collected during the outbreak were stripped off the woody stems, homogenized with water in a blender and dosed by stomach tube to 2 sheep (Nos. 1 and 2), as summarized in Table 1.

The following routine chemical pathological determinations were done daily for the duration of the experiment on the sera of the 2 sheep that had received the plant material, as well as on 1 control sheep (No. 3): gamma-glutamyl transferase (GGT), aspartate transaminase (AST) and total bilirubin (T Br). The 3 animals were young South African Mutton Merino sheep, kept in a camp containing green kikuyu grass (*Pennisetum clandestinum* Hochst. ex chiov) pasture and were examined 3 times a day. No shade was present or provided in the camp, and during the day they were exposed to the maximum sunlight.

Autopsies on Sheep 1 and 2 were performed following death or euthanasia by exsanguination (Table 1). Selected tissue specimens of liver, kidney, heart and spleen

from both, as well as skin and gall bladder from Sheep 2, were collected, fixed in 10 % buffered formalin and processed for microscopy.

RESULTS

Clinical signs

Field outbreak

The 15 affected sheep examined on 20 March 1985 all had swollen ears, eyelids and lips, with serious exudation on the skin of some of the most severely affected areas. Icteric mucous membranes and coronites, as manifested by hyperaemia of the skin of the coronet, was seen in most of these animals.

The sheep were placed in a stable, fed oat and lucerne hay and examined again 8 days later. Although they all survived, there was a marked drop in body mass. The swellings had subsided, but dark-brown scabs and crusts covered the affected skin areas (Fig. 5) and icterus was no longer visible in the mucous membranes of the live animals.

TABLE 1 Toxicity of green homogenized *Nidorella foetida* to sheep

Sheep No.	Sex	Age (months)	Mass (kg)	Dose (g/kg × n)	Period dosed days	Total dose g	Duration of experiment (days)	Signs of photosensitivity	Fate
1	M	10	28	5 × 2	1	280	1	-	Died
2	M	12	35	2,5 × 1	5	437,5	5	+	Killed

M = Male

g/kg × n = Dose × number of daily administrations

- = No signs of photosensitivity

+ = Photosensitivity present



FIG. 5 Sheep from field outbreak (Sheep 8) 9 days after initial signs of photosensitivity were seen

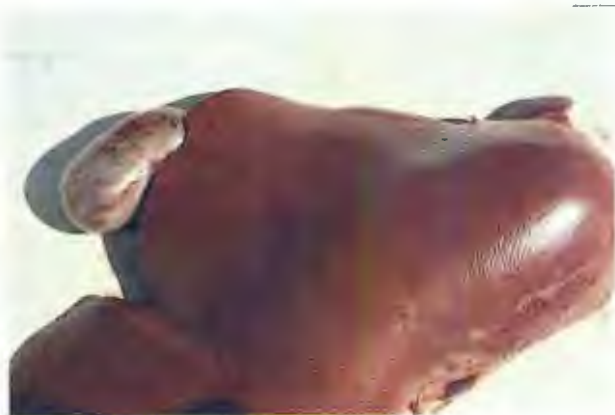

FIG. 6 Pale-brown, swollen liver with disseminated haemorrhages of Sheep 1

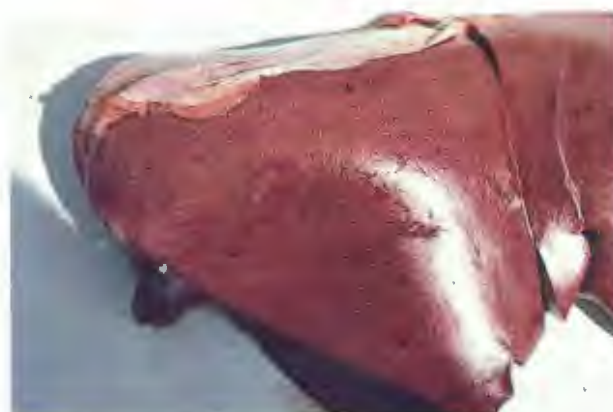

FIG. 7 Yellowish-brown liver with accentuated lobulation and a few small haemorrhages of Sheep 2

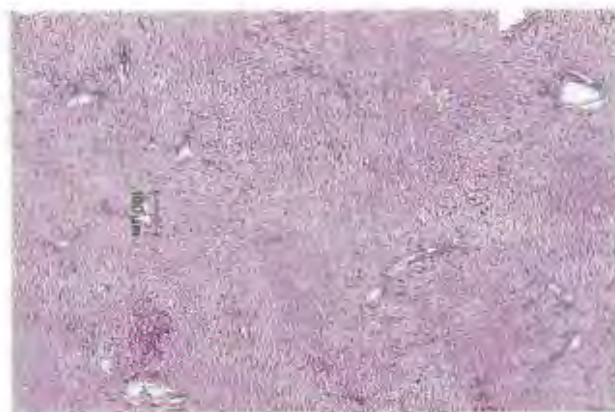


FIG. 8 Peripheral coagulative necrosis with severe midzonal degeneration in the liver of Sheep 1

TABLE 2 Chemical pathological findings in the blood of 5 sheep from the field outbreak

Sheep No.	Date	GGT	AST	Total bilirubin
4	85/03/20	112	Not available	137.6
5	85/03/20	103	Not available	84.0
6	85/03/20	150	Not available	59.6
7	85/03/20	86	Not available	132.8
8*	85/03/28	128	137	29.3

* This blood specimen was collected from 1 sheep from a field outbreak and brought to the laboratory for autopsy 8 days after the sheep had been taken out of the toxic camp

TABLE 3 Chemical pathological changes in the blood of sheep dosed with green *Nidorella foetida* plant material

Sheep No.	Date	Days after beginning of dosing regime	GGT $\mu\text{l/l}$ at 25 °C	AST $\mu\text{l/l}$ at 25 °C	Total bilirubin $\mu\text{mol/l}$
1	85/03/21	—	28	43	4.6
	85/03/22	1	73	178	111.0
2	85/03/25	—	25	20	1.9
	85/03/26	1	92	178	28.4
	85/03/27	2	97	178	75.4
	85/03/28	3	92	178	84.6
	85/03/29	4	77	178	90.0
3*	85/03/26	—	31	38	4.2
	85/03/27	—	30	10	6.5
	85/03/28	—	28	46	1.7
	85/03/29	—	27	27	2.0

* Control sheep

No *P. chartarum* spores were found during spore counting of pasture samples from the toxic camp.

Toxicity tests

Sheep 1 became listless, refused food and suffered from ruminal stasis and paresis 20 h after having received 2 doses of 5 g/kg plant material on Day 1. The sheep's condition deteriorated rapidly and it died 26 h after having received the first dose.

Sheep 2 received 5 daily doses of 2.5 g/kg of the plant. On the 4th day, at midday, the sheep became restless, sought the shade of a corner post and developed a marked swelling of the ears, eyelids and face (Fig. 4). On the 5th day, the swelling had increased, the eyes were almost closed and visible mucous membranes had a yellowish tinge. The sheep was autopsied on Day 5.

Sheep 3 was kept on the pasture for 4 weeks without developing any abnormal clinical signs.

During the course of the experiment the weather was fine, hot and sunny.

Chemical pathology

Field outbreak

In the field outbreak, the T Br and GGT levels of the serum of the 4 sheep tested on 20 March 1985 were found to be markedly elevated (Table 2). AST was not tested. The serum levels of T Br, AST and GGT of the sheep (No. 8) bled 8 days later were elevated, although that of the T Br was markedly lower than those tested at the earlier stage of the disease.

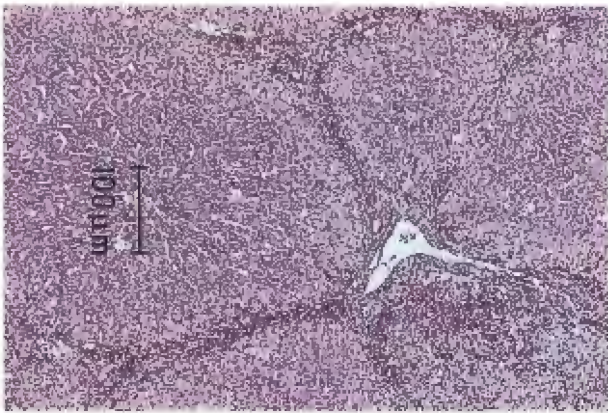

FIG. 9 Accentuated lobulation caused by peripheral haemorrhage and prominent bile duct proliferation in the liver of Sheep 2

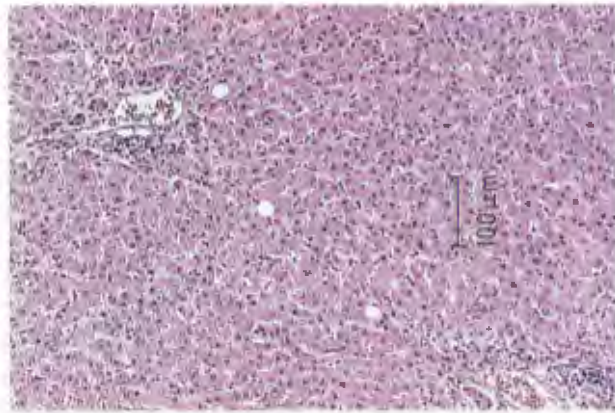


FIG. 10 Hepatocellular unrest with mild bile duct proliferation seen in the regenerating liver of Sheep 8

Toxicity tests

In the case of Sheep 1 and 2, T Br, AST and GGT serum levels were found to be markedly elevated 24 h after having received the initial dose (Table 3). These serum values of Sheep 3 (control) remained within normal limits.

Pathology

Field outbreak

The subcutaneous swelling of the affected areas of the head and face had disappeared by the time the animal was autopsied, but these areas were covered by dark-brown crusts on the point of becoming detached from the underlying skin. Slight icterus was apparent in the subcutis. The liver was yellowish-brown, i.e. slightly more yellow than normal.

Histopathologically, there was a mild hepatitis with hepatocellular unrest. This was more prominent in the peripheral zones of the lobules and was characterized by hepatocytic anisonucleosis and by occasional binucleate hepatocytes. There was mild degeneration and necrosis of the hepatocytes in the midzonal and peripheral zones. There was a mild portal bile duct proliferation and a mild periportal mononuclear cell infiltration. A mild peripheral fatty degeneration and mild bile stasis were also present (Fig. 10).

The gall-bladder wall was oedematous, and there was mild nephrosis characterized by cloudy swelling and hydropic degeneration in the proximal tubules.

A fibrinopurulent exudate had formed a crust on the skin of the macroscopically affected areas. A severe hyperaemia, oedema, lymphatic dilatation, focal mineralization and a mild neutrophil infiltration of the dermis was also present. No other lesions considered to be of significance were encountered in the other organs examined microscopically.

Toxicity tests

Sheep 1

The liver was slightly swollen, friable and pale-brown, having many disseminated haemorrhages varying in size from pin-point to 4 mm in diameter (Fig. 6). The gall-bladder wall was slightly oedematous. The carcass was distinctly icteric, and there was a mild hydrothorax, hydropericardium and ascites, the fluid being more yellow than normal. Other changes observed were severe endocardial haemorrhages of the right ventricle and gastro-intestinal stasis.

A severe hepatitis, found on histopathological examination, was characterized by peripheral coagulative necrosis of hepatocytes and severe midzonal degeneration. In addition, in several lobules there was early coagulative necrosis in the midzonal areas (Fig. 8). In these areas, there were also small haemorrhages. Small foci of hepatocytic lysis, frequently situated around the central vein, were also encountered. There was hydropic degeneration and early coagulative necrosis of the proximal tubules in the kidney. No lesions of significance were noticed in the other organs examined.

Sheep 2

The liver was yellowish-brown with distinct lobulation. A few pin-point- to pin-head-sized disseminated haemorrhages were present (Fig. 7). The wall of the gall-bladder was slightly oedematous. Moderate icterus could be seen macroscopically.

On histopathological examination, the liver lesions were found to be less severe than those in Sheep 1. The lobulation in the liver was accentuated by the peripheral haemorrhage present in most lobules, and intralobular bile duct proliferation was prominent (Fig. 9). Relatively numerous necrotic or dividing and regenerating hepatocytes were encountered, particularly in the peripheral zones of lobules. The hepatocytes in paracentral and central zones showed mild hydropic degeneration with occasional binucleate and regenerating cells.

Small foci of degeneration were evident in the epithelial layer of the gall-bladder, with aggregation of neutrophils in these areas.

Mild nephrosis, as manifested by the mild hydropic degeneration of the proximal tubules, occurred. The skin was moderately oedematous. The other organs examined did not reveal any significant changes from the normal.

DISCUSSION

This is the first report of a *Nidorella* sp. causing toxicity in animals. Although this study has shown *N. foetida* to be highly toxic to sheep, it is not of major economic importance in South Africa because of its localized distribution.

A knowledge of its hepatotoxicity and resultant photosensitivity, however, is important in elucidating the aetiology of other outbreaks of hepatogenous photosensitivity of unknown cause; for instance, "Stellenbosch photosensitivity", which occurs in the same area. This knowledge might also be valuable in the investigation of the possible toxicity of other more common *Nidorella* spp. occurring in other parts of South Africa.

It is evident that *N. foetida*, like *Athanasia trifurcata* L. (Kellerman *et al.*, 1983) and numerous other toxic plants, is unpalatable and consequently not normally grazed by stock. In certain circumstances, however, (e.g. acute food shortage, a craving for green plants when the animals are on dry grazing or requiring roughage when on lush, young, green pasture) stock may ingest sufficient quantities of these unpalatable plants to cause intoxication. The first 2 factors undoubtedly played a role in this outbreak.

In Sheep 1, which manifested an acute severe hepatitis involving the entire lobule to some degree, a zonal necrosis involving the periphery of the lobule was a particularly prominent feature. Although the hepatitis in Sheep 2 and the field case was less severe, the haemorrhages found in the peripheral zone followed the same pattern.

It is evident from this investigation that in *N. foetida* toxicity the insult is directed at the hepatocytes, as is also the case in poisoning caused by *A. trifurcata* (Kellerman *et al.*, 1983), *Asaemia axillaris* (Thunb.) Harv. ex Jackson (Coetzer & Bergh, 1983) and *Lasiospermum bipinnatum* (Thunb.) Druce (Kellerman *et al.*, 1973). Some evidence of a zonal necrosis is usually also found with these 3 hepatotoxic plants.

In comparing the histopathological changes in the liver caused by different hepatotoxic components, the duration of toxin ingestion, the dosage, the period between the last dose of toxic material and death or euthanasia must be taken into account. In this particular investigation, there was a marked difference in the pattern of *Nidorella* ingestion in the 3 sheep that were autopsied. Sheep 1 died 26 h after having received 2 doses of 5 g/kg of plant material on 1 day; Sheep 2 was killed 4 days after 5 daily doses of 2.5 g/kg, and the "field sheep" was killed 8 days after being taken out of the "toxic" land where it has been for 5 days. Sheep 2 would probably have survived if more plant material had not been administered.

ACKNOWLEDGEMENTS

The authors wish to thank Mr R. O. Moffett and Mrs A. Fellingham of the State Herbarium, Stellenbosch, and Miss W. Welman of the Botanical Research Institute, Pretoria, for identification of the *Nidorella* sp. and for supplying botanical information. Thanks are also due to Mr E. W. P. Heine and Miss A. M. D. Kriel of the Regional Veterinary Laboratory, Stellenbosch, for their excellent technical assistance, to Mr P. van der Merwe of the Fruit and Fruit Technology Research Institute, Stellenbosch, for the photographs of the sections, and to Mr D. G. du Toit for co-operation on the farm.

We are grateful to the Directorate of Veterinary Services, Pretoria, for permission to publish this article.

REFERENCES

- ADAMSON, R. S. & SALTER, T. M., 1950. Flora of the Cape Peninsula. Cape Town: Juta.
- COETZER, J. A. W. & BERGH, T., 1983. Photosensitivity in South Africa. IV. Pathological changes in the liver in ovine sensitivity caused by the plant *Asaemia axillaris* (Thunb.) Harv. ex Jackson. *Onderstepoort Journal of Veterinary Research*, 50, 55-58.
- DI MENNA, MARGARET E. & BAILEY, J. R., 1973. *Pithomyces chartarum* spore counts in pasture. *New Zealand Journal of Agricultural Research*, 16, 343-351.
- GIBBS RUSSELL, G. E. and the staff of the National Herbarium, 1984. *Memoirs of the Botanical Survey of South Africa*, No. 48.
- KELLERMAN, T. S., BASSON, P. A., NAUDÉ, T. W., VAN RENSBURG, I. B. R. & WELMAN, WILHELMINA G., 1973. Photosensitivity in South Africa. I. A comparative study of *Asaemia axillaris* (Thunb.) ex Jackson and *Lasiospermum bipinnatum* (Thunb.) Druce poisoning in sheep. *Onderstepoort Journal of Veterinary Research*, 40, 115-126.
- KELLERMAN, T. S., COETZER, J. A. W., SCHNEIDER, D. J. & WELMAN, WILHELMINA G., 1983. Photosensitivity in South Africa. III. Ovine hepatogenous photosensitivity caused by the plant *Athanasia trifurcata* L. (Asteraceae). *Onderstepoort Journal of Veterinary Research*, 50, 45-53.
- MARASAS, W. F. O., ADELAAR, T. F., KELLERMAN, T. S., MINNE, J. A., VAN RENSBURG, I. B. J. & BURROUGHS, G. W., 1972. First report of facial eczema in sheep in South Africa. *Onderstepoort Journal of Veterinary Research*, 39, 107-112.
- STEYN, D. G., 1949. *Vergiftiging van mens en dier*. Pretoria: Van Schaik.