

Original article

Revisiting the anatomy of the ilio-inguinal / iliohypogastric nerve block

Albert-Neels van Schoor¹, Marius C Bosman¹, Adrian T Bosenberg²,

¹ Department of Anatomy, School of Medicine, Faculty of Health Sciences, University of Pretoria, Pretoria, South Africa.

² Department of Anesthesiology and Pain Management, University Washington and Seattle Children's Hospital, Seattle, USA.

*Correspondence to:

Dr. A. van Schoor,

Department of Anatomy, Section of Clinical Anatomy, School of Medicine, Faculty of Health Sciences, University of Pretoria, Pretoria 0001, South Africa

Tel: +27 12 3192315

Telefax: +27 12 3192240

E-mail: albert.vanschoor@up.ac.za

Abstract

Background: The ilio-inguinal / iliohypogastric nerve block (INB) is one of the most common peripheral nerve block techniques in pediatric anesthesia, which is largely due to the introduction of ultrasound (US) guidance. Despite the benefits of US guidance, the absence of an US machine should not deter the provider from performing INB, considering that many institutions, especially in developing countries, cannot afford to provide ultrasound machines in their anesthesiology departments. The aim of this study was to revisit the anatomical position of the ilio-inguinal and iliohypogastric nerves in relation to the ASIS, in a large sample of neonatal cadavers, and compare the results with a similar group in a previously published US guided study. *Methods:* With Ethics Committee approval the ilio-inguinal and iliohypogastric nerves were carefully dissected in 54 neonatal cadavers. *Results:* In the total sample the ilio-inguinal nerve was found to be $2.2\text{mm} \pm 1.2\text{mm}$ from the ASIS, on a line connecting

the ASIS to the umbilicus. The iliohypogastric nerve was on average $3.8\text{mm}\pm 1.3\text{mm}$ from the ASIS. For the entire sample, the optimal needle insertion site was 3.00mm from the ASIS. Although there is a strong correlation between the needle insertion point and the weight of the neonate, this will only “fit” for 60% of the population. *Conclusion:* The linear regression formula; needle insertion distance (mm) = $0.6 \times \text{weight} + 1.8$ can be used as a guideline for the position of the ilio-inguinal and iliohypogastric nerves.

Key words: Pediatric, ilio-inguinal blocks, trunk, linear regression, inguinal surgery, ultrasound

Introduction

The ilio-inguinal / iliohypogastric nerve block (INB) provides effective analgesia for inguinal surgery (L1 dermatome). It has been well described for common surgical procedures such as inguinal hernia repair, orchidopexy, hydrocele or varicocele repair (1-3). Performing these procedures successfully and without complications is an integral part of modern pediatric surgical practice. General anesthesia is still widely utilized in children undergoing these procedures. An exception would be premature infants who may have the procedure performed under spinal anesthesia, caudal epidural anesthesia with or without mild sedation.

The INB has become one of the most common peripheral nerve block techniques in pediatric anesthesia largely due to the introduction of ultrasound (US) guidance. US allows the anesthesiologist to visualize the nerves within the correct tissue plane (i.e. between the internal oblique and transverse abdominis muscles) and to introduce an appropriate sized needle within that tissue plane by using real-time tracking and hydro-dissection (1-4).

Despite the benefits of US guidance, the absence of an US machine should not be a contraindication to performing INB, considering that many institutions, especially in developing countries, cannot afford to provide ultrasound machines for their anesthesiology departments. With this in mind, a thorough knowledge of the anatomy of the ilio-inguinal and iliohypogastric nerves technique is essential, as well as knowledge of the technique.

In 2005, the authors conducted a study on 25 embalmed neonatal cadavers in order to determine the precise anatomical positions of both the ilio-inguinal and the iliohypogastric nerves. The results showed that the ilio-inguinal and iliohypogastric nerves lie much closer to the ASIS than was previously thought (5).

The aim of this study was to revisit the anatomical position of the ilio-inguinal and iliohypogastric nerves in relation to the ASIS in a larger sample, as well as to compare the results of the cadaveric study with a similar US guided study (1).

Materials & methods

The ilio-inguinal and iliohypogastric nerves were carefully exposed in a further 29 embalmed cadavers giving a total of 54 neonatal and infant cadavers (51 left and 52 right sides; mean length: 43cm; mean weight: 1.9kg) that was studied. A specimen was excluded when both nerves were not found for any given side. The nerves were exposed by first making a midline incision from the umbilicus to the pubic symphysis. From there, two horizontal incisions were made on both sides of each cadaver that extended laterally from the umbilicus and pubic symphysis. The skin was then reflected laterally, leaving the superficial fascia of the anterior abdominal wall intact. The superficial fat layer was carefully removed to expose the superficial muscles and the rectus sheath of the anterior abdominal wall (see Fig 1).

A midline incision through the aponeurosis of the external oblique muscle was made and carefully reflected laterally to expose the underlying internal oblique and rectus abdominis muscles. The ilio-inguinal nerve was then identified as it courses through the deeper layers and travels within the inguinal canal (see Figure 2). The nerve was then followed superolaterally to the point where it penetrates the internal oblique muscle. The latter was then carefully removed in sections to expose the course of the ilio-inguinal nerve back to a point superolateral to the ASIS. The iliohypogastric nerve, which courses superior to the ilio-inguinal nerve, was exposed in a similar manner (see Figure 3).

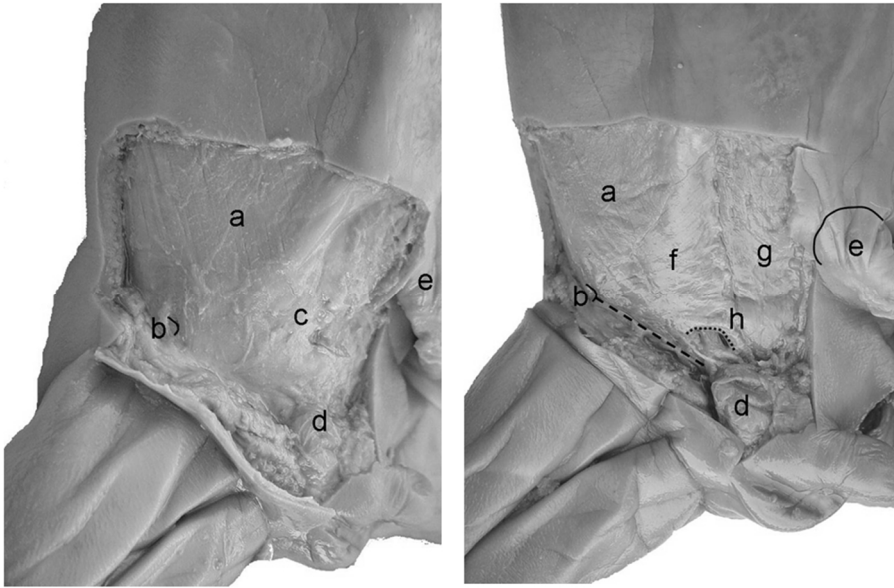


Figure 1: Superficial and deeper dissections of the anterior abdominal wall of a neonatal cadaver with (a) the external oblique muscle, (b) the ASIS, (c) the rectus sheath, (d) testis, (e) the umbilicus, (f) internal oblique muscle, (g) rectus abdominis muscle, and (h) the conjoint tendon (also indicated with the smaller, curved dotted line). The inguinal ligament is indicated with a dashed line.

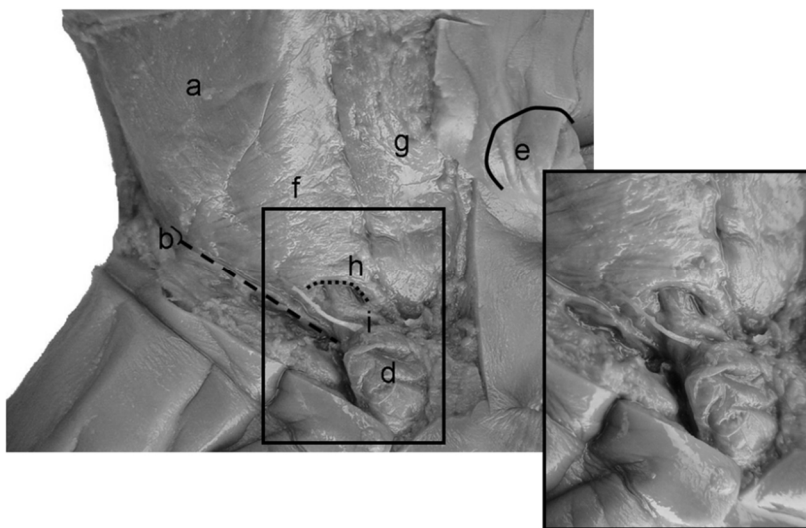


Figure 2: Dissection of (i) the ilio-inguinal nerve. The nerve can be seen piercing (f) the internal oblique muscle running with the spermatic cord towards (d) the testis.

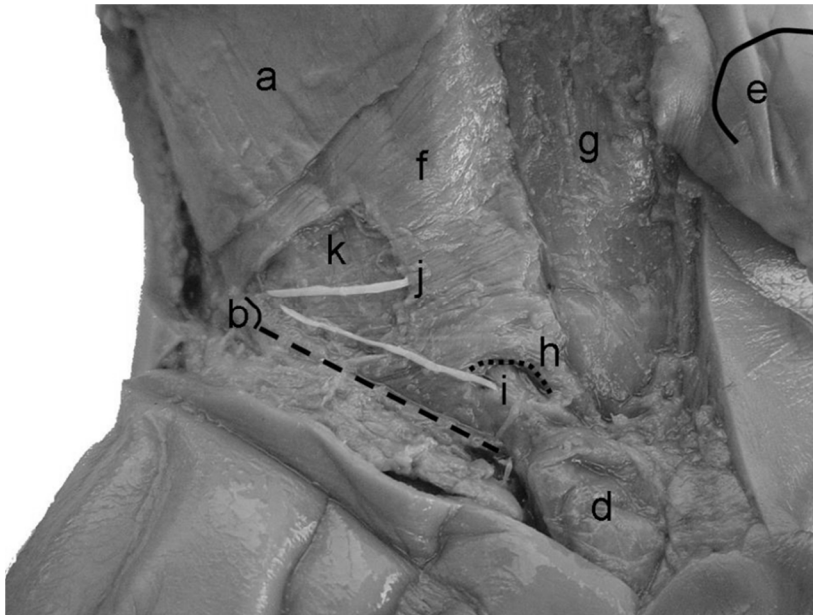


Figure 3: Dissection of the (i) ilio-inguinal and (j) iliohypogastric nerves. As the nerves pass inferomedial past the (b) ASIS, they are still running in the plane between the (k) transverse abdominis muscle and (f) internal oblique muscle.

The ASIS was identified on both sides and the distance of both nerves from the ASIS - on a line connecting the ASIS to the umbilicus - was measured with a mechanical dial sliding caliper (accuracy of 0.01mm).

Statistical analysis included a comparison between the left and right sides by using a paired *t*-test. A Pearson's correlation coefficient test (correlation coefficient or *R*) was conducted to determine the correlation coefficient or the strength of the correlation between the *dependent variables*, i.e., the distance of the ilio-inguinal and iliohypogastric nerves from the ASIS and the distance of the point of needle insertion from the ASIS, and the *independent variables*, i.e., the length and weight of the sample population.

In the case where a strong or high, moderate correlation ($R > 0.6$) between the dependent and independent variables was found, the coefficient of determination (or R^2) was determined. This is a statistical measure of how well the regression line, that was also determined, approximates the real data points.

Results

The distances from the ASIS to the ilio-inguinal and iliohypogastric nerves, on both the left and right sides of the cadavers, are shown in Table 1. The upper and lower ranges stated in Table 1 were determined with a 95% confidence level.

Table 1: Distances (in mm) of the right and left ilio-inguinal and iliohypogastric nerves (II-IH) from the ASIS (SD = Standard Deviation, CI95% = 95% confidence interval)

	Right			Left		
	Ilio-inguinal nerve	Iliohypogastric nerve	II-IH	Ilio-inguinal nerve	Iliohypogastric nerve	II-IH
n	52			51		
Mean	2.3	3.9	1.6	2.2	3.8	1.6
SD	1.2	1.3	0.5	1.2	1.4	0.6
CI 95%	0.3	0.3	0.1	0.3	0.4	0.2
Lower range*	2.0	3.6	1.5	1.8	3.4	1.4
Upper range*	2.6	4.2	1.7	2.5	4.1	1.8
Insertion site	3.1			3.0		

The correct distance for needle insertion was then defined as a point midway between the ilio-inguinal and iliohypogastric nerves (needle insertion from ASIS = distance to ilio-inguinal nerve + $\frac{1}{2}$ (distance between the iliohypogastric and ilio-inguinal nerves)). The needle insertion site on the right and left sides were found to be 3.1mm and 3.0mm from the ASIS, on a line connecting the ASIS with the umbilicus, respectively.

A paired *t*-test revealed that there was no significant difference between the distance from the ASIS to the left and right ilio-inguinal or iliohypogastric nerves or needle insertion site. There was also no significant difference between the distance between the ilio-inguinal and iliohypogastric nerves on both sides ($p > 0.05$ for all comparisons). All the data was therefore compiled for a total sample of 103 (see Table 2).

Table 2: Distances (in mm) of the ilio-inguinal and iliohypogastric nerves from the ASIS for the total neonatal sample.

	Total		
	Ilio-inguinal nerve	Iliohypogastric nerve	II-IH
n	103		
Mean	2.2	3.8	1.6
SD	1.2	1.3	0.6
CI 95%	0.2	0.3	0.1
Lower range*	2.0	3.6	1.5
Upper range*	2.4	4.1	1.7
Insertion site	3.00		

Looking at the total of 103 inguinal regions, the ilio-inguinal was found to be 2.2mm±1.2mm from the ASIS, on a line connecting the ASIS to the umbilicus. The iliohypogastric nerve was 3.8mm±1.3mm from the ASIS. For the entire sample, the optimal needle insertion site was 3.00mm from the ASIS.

The Pearson's correlation coefficient test revealed that a moderate correlation exists between either the distance of the ilio-inguinal nerve (R=0.4032), iliohypogastric nerve (R=0.5161) and point of needle insertion (R=0.4776), to the ASIS (*dependent variables*) or the **length** of the cadaver specimen (*independent variables*). There was however a strong correlation between the distance of the ilio-inguinal nerve (R=0.7340), iliohypogastric nerve (R=0.7647) and point of needle insertion (R=0.7707), to the ASIS and the **weight** of the cadaver specimen. Because of this strong correlation, a linear regression formula was then calculated for determining the correct distance, from the ipsilateral ASIS, to the ideal point of needle insertion when the weight of the cadaver is known (see Figure 4).

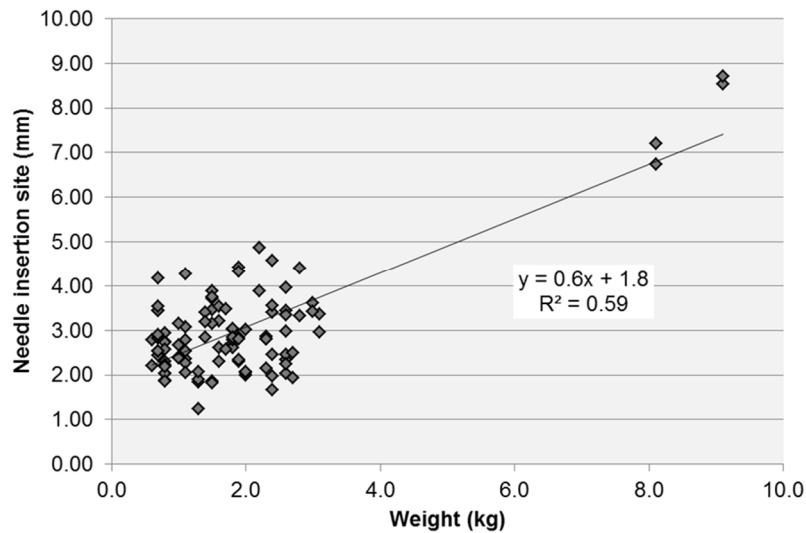


Figure 4: Linear regression formula for the distance of the point of needle insertion from the ASIS as the dependent variable, and the weight of the sample as the independent.

The coefficient of determination for these linear regression formulae revealed that there is a moderate “fit” ($R^2=0.59$) when determining the distance to the ideal point of needle insertion.

Discussion

Sound knowledge and understanding of the anatomy is vitally important for successful nerve blocks, even when using US guidance. Extrapolation of anatomical findings from adult studies and simply “downscaling” these findings in order to apply them to infants and children is inappropriate. The ideal situation would be to study the anatomy of neonatal or infant cadavers that are similar in age of the living patient. This unfortunately wasn’t (and very often isn’t) possible. A clear limitation of this study was therefore the fact that only nine cadavers were above 2.5kg (normal birth weight) and there was also lack of specific information regarding the neonatal sample (i.e. gestational age). It was impossible to determine whether the sample of neonatal cadavers, which ranged from very low birth weight (<1.5kg), low birth weight (1.5kg-2.5kg) and normal birth weight (>2.5kg), were growth restricted term or preterm infants. However, the intent of this study was to provide accurate, anatomical measurements for a neonatal sample that could be extrapolated and used to identify the ilio-inguinal and iliohypogastric nerve on older infants. This study further emphasized that the ilio-inguinal and iliohypogastric nerves in neonates and infants lie very close to the ASIS. A recent review

still suggests that the needle insertion point should be at the junction of the lateral one third and medial two thirds on a line connecting the ASIS with the umbilicus (2). In neonates, this point is far more cranial than the actual position of the nerves and requires that the local anesthetic spread inferiorly in order to reach both nerves and provide effective analgesia.

In this study, the ilio-inguinal nerve was found to be between 2.0mm and 2.4 mm (95% confidence level), while the iliohypogastric nerve was between 3.6mm and 4.1mm from the ASIS. Both nerves ran in the plane between the transverse abdominis and internal oblique muscles to a point inferomedial to the ASIS, where the ilio-inguinal nerve then pierced the internal oblique muscle and entered the inguinal canal. The iliohypogastric nerve pierced the internal oblique muscle approximately at the semi-lunar line or the lateral border of the rectus sheath.

The ideal point of needle insertion, according to our data, should be halfway between the ilio-inguinal and iliohypogastric nerves, which was between 2.8mm and 3.2mm (95% confidence level) from the ASIS. The average distance is 3.0mm. Willschke and co-workers performed US guided INB on one hundred pediatric patients. They determined that the mean distance of the ilio-inguinal nerve from the ASIS was $6.7\text{mm} \pm 2.9\text{mm}$. The mean weight of the population was 13kg (1). This corresponds well with the data obtained from this study, where the mean distance of the ilio-inguinal nerve was found to be 2.2mm in a much smaller population with a mean weight of only 1.9kg. The distance of the ilio-inguinal nerve from the ASIS of two larger infants in the sample, weighing 8.1kg and 9.1kg, were 5.1mm and 8.0mm, respectively, which falls within the range described by Willschke and co-workers. They also looked at the skin to ilio-inguinal nerve and ilio-inguinal nerve to peritoneum distance and found them to be $8.0\text{mm} \pm 2.2\text{mm}$ and $3.3\text{mm} \pm 1.3\text{mm}$ (shortest distance, 1 mm), respectively. This emphasizes the risk of undetected peritoneal puncture when using the “fascial click” method (1). This may contribute to failed blocks and is a strong argument for the use of ultrasound guidance in young children.

There are several reasons why INB should preferably be done under US guidance. The literature describes several complications occurring when using the “blind” technique. The first is a high incidence of complete or partial failure to block the ilio-inguinal and iliohypogastric nerves. It is

estimated that, even in experienced hands, complete failure of this block could occur in about 10% of cases. Partial failure to block these nerves occurs even more frequently - between 10 and 15% (6-9). More recently, Eichenberger and co-workers reported a failure rate as high as 20%–30% in children when using the classic technique for blocking the ilio-inguinal and iliohypogastric nerves (9). An inadvertent femoral nerve block is another recognized complication, (8, 10, 11) which was found to occur in 11% of cases in a prospective study in children between 2 and 12 years (11). An adult cadaver study has shown that the fascial plane between the transverse abdominis muscle and the transversalis fascia was in continuity with the space around the femoral nerve posteriorly. Injection of methylene blue into this plane resulted in pooling of dye around the femoral nerve (10). This may partly explain the relatively high incidence of femoral nerve palsy, particularly if a relatively large volume of local anesthetic is used. Incorrect placement of the needle below or close to the inguinal ligament using incorrect landmarks is more likely to involve the femoral nerve, even if small volumes of local anesthetic are used. If the needle is inserted too deeply, unintentional intraperitoneal injection may occur. Jöhr and Sossai reported a case of accidental colonic puncture after INB was performed on a child (12).

US guidance is therefore strongly recommended when performing the INB whenever available. Precise administration of small volumes of local anesthetic is possible under US guidance to provide effective blockade with a low failure rate and little or no complications (1).

Conclusion

The findings of this study suggest that the needle should be placed much closer to the ASIS than previously described. In neonates, the local anesthetic needle should be inserted approximately 3mm from the ASIS on a line drawn between the ASIS and the umbilicus. Although there is a strong correlation between the needle insertion point and the weight of the sample, this will only “fit” for 60% of the population. The linear regression formula; **needle insertion distance (mm) = 0.6 x weight + 1.8** can therefore be used as a guideline for the position of the ilio-inguinal and iliohypogastric nerves, with or without US guidance.

Ethical approval

Ethical approval to conduct dissections on a sample of neonatal cadavers within the Department of Anatomy, University of Pretoria, was obtained from the Faculty of Health Sciences, University of Pretoria Main Ethics Committee. All dissections were also conducted in the Department of Anatomy under the rules and regulations stipulated in the South African National Health Act, number 61 of 2003.

Conflict of interests

None of the authors has any conflicts of interest to declare.

References

1. Willschke H, Marhofer P, Bosenberg A, Johnston S, Wanzel O, Cox SG, Sitzwohl C, Kapral S. Ultrasonography for ilioinguinal / iliohypogastric nerve blocks in children. *Br J Anaesth* 2005; **95**:226-230.
2. Aziz A, Farid N, Abdelaal A. Ultrasound-guided regional anaesthesia and paediatric surgery. *Curr Anaesth Crit Care* 2009; **20**:74-79.
3. Weintraud M, Lundblad M, Kettner SC, Willschke H, Kapral S, Lönnqvist P, *et al.* Ultrasound Versus Landmark-Based Technique for Ilioinguinal-Iliohypogastric Nerve Blockade in Children: The Implications on Plasma Levels of Ropivacaine. *Anesth Analg* 2009; **108**:1488-1492.
4. McCormack JG, Malherbe S. Applications of ultrasound in paediatric anaesthesia. *Curr Anaesth Crit Care* 2008; **19**:302-308.
5. Van Schoor A, Boon JM, Bosenberg A, Meiring JH. Anatomical considerations of the paediatric ilioinguinal/iliohypogastric nerve block. *Paediatr Anaesth* 2005; **15**: 371-377.
6. Dalens BJ. Nerve blocks of the trunk. In: Dalens BJ (ed.). *Regional Anesthesia in Infants, Children, and Adolescents*. London: Williams & Wilkens, 1995:476-479.
7. Markakis DA. Regional anaesthesia in paediatrics. *Anesth Clin North Am* 2000; **18**:355-381.
8. Lim SL, Ng Sb A, Tan GM. Ilioinguinal and iliohypogastric nerve block revisited: single shot versus double shot technique for hernia repair in children. *Paediatr Anaesth* 2002; **12**:255-260.
9. Eichenberger U, Greher M, Kirchmair L, Curatolo M, Moriggl B. Ultrasound-guided blocks of the ilioinguinal and iliohypogastric nerve: accuracy of a selective new technique confirmed by anatomical dissection. *Br J Anaesth* 2006; **97**:238-243.
10. Rosario DJ, Jacob S, Luntley J, Skinner PP, Raftery AT. Mechanism of femoral nerve palsy complicating percutaneous ilioinguinal field block. *Br J Anaesth* 1997; **78**:314-316.
11. Lipp A, Woodcock J, Hensman B, Wilkinson K. What is the incidence of leg weakness after ilio-inguinal block in children? *Paediatr Anaesth* 2000; **10**: 687-688.
12. Jöhr M, Sossai R. Colonic puncture during ilioinguinal nerve block in a child. *Anesth Anal* 1999; **88**:1051-1052.