

CASE REPORT

Horses and other equids

Metastatic renal carcinoma in a horse presented for lameness examination and suspected pneumonia

Elza Hollenbach¹  | Emily P. Mitchell¹ | Corne Randlehoff¹ | Juan Alberto Munoz^{2,3,4}

¹Companion Animal Clinical Studies, University of Pretoria, Pretoria, South Africa

²Hospital Veterinario Sierra de Madrid, San Agustín de Guadalix, Madrid, Spain

³Hospital Veterinario Sierra de las Nieves, Fuente el Saz, Madrid, Spain

⁴San Agustín de Guadalix and Fuente el Saz del Jarama, Madrid, Spain

Correspondence

Elza Hollenbach, University of Pretoria, Pretoria, South Africa.
Email: Elza.hollenbach@up.ac.za

Abstract

Equine renal cell carcinoma (RCC) is a rare and poorly understood condition, making the diagnosis challenging. We present a case of a 16-year-old Warmblood gelding referred for lameness and suspected pneumonia. The horse exhibited diverse non-specific symptoms, including pyrexia, coughing, weight loss and lameness. Diagnostic imaging revealed an osseous neoplastic lesion and lung metastasis. Postmortem confirmed metastatic renal carcinoma. This case underscores the difficulty of RCC diagnosis due to non-specific clinical signs, necessitating a comprehensive approach involving clinical, imaging and histopathological findings. RCC offers limited treatment options as it is typically diagnosed at advanced stages, leading to a poor prognosis and euthanasia. Increased awareness and research are crucial for early detection and better understanding of this rare equine disease.

BACKGROUND

Prevalence

Renal cell carcinoma (RCC) is a rare condition in horses^{1–6} and other domestic animals. In a retrospective analysis in 1981, only two cases of primary RCC were found in 32,389 equine necropsies (0.006%).⁵ A more recent 2017 retrospective analysis found nine RCCs in 1069 renal biopsies (0.8%).⁶ Other reported renal tumours include transitional cell carcinoma, squamous cell carcinoma, renal adenoma, nephroblastoma and renal neuroendocrine tumours.^{2,6,7} In humans, dogs, cats and horses, RCC is the most common primary renal tumour.⁴ RCCs are usually malignant, well-demarcated and originate from the renal tubular epithelium or collecting ducts in the renal cortex at one of the poles.^{5,8}

The limited number of cases documented makes it difficult to draw conclusions regarding the breed, age and sex predilection in horses. RCC can occur at any age (4–25 years old, mean 13 years) and in either sex.^{4,9,10}

Diagnosis

Horses with RCC can show a diverse number of non-specific clinical signs. These can include pyrexia, colic, tenesmus, chronic weight loss, anorexia, cachexia, haematuria, polyuria, polydipsia, anaemia, haemoperitoneum, ascites, ventral oedema, intra-abdominal mass, uveitis, hypovolaemic

shock or haemorrhage of the affected vessels followed by acute deterioration and death.^{1,2,4,5,8,10–16} Lameness has also been recorded in a few cases.^{17–20}

Non-specific changes have been reported in haematology, serum biochemistry and urinalysis and could include hypoglycaemia, anaemia, hypoproteinaemia and haematuria.^{1,4,21} This makes RCCs challenging to diagnose.⁹

Diagnosis can often be suspected by combining the results found on clinical examination, rectal palpation and abdominal ultrasound but can only be confirmed with histopathology.^{4,16}

Histopathology and pathology

Valuable information regarding aetiology, prognosis and treatment can be gained through ultrasound-guided biopsy and histological diagnosis in a horse with suspected kidney disease. RCCs are derived from tubular epithelium or the collecting duct and often have mixed histological features.

A wide range of organs can be affected through seeding, exfoliation and implantation or metastasis of the tumour.^{10,11,22,23} Through lymphatic and haematogenous routes, the lungs, liver and regional lymph nodes are most often affected.²² Other organs that can be affected by metastasis include the spleen, adrenal glands, thyroid gland, myocardium, peritoneum, oral cavity, soft tissue of the forelimb and bone.^{2,5,10,11,13,15,17,18,20,24,25} The abdominal

This is an open access article under the terms of the [Creative Commons Attribution-NonCommercial-NoDerivs](https://creativecommons.org/licenses/by-nc-nd/4.0/) License, which permits use and distribution in any medium, provided the original work is properly cited, the use is non-commercial and no modifications or adaptations are made.

© 2024 The Author(s). *Veterinary Record Case Reports* published by John Wiley & Sons Ltd on behalf of British Veterinary Association.

carcinomatosis observed in RCC cases is likely due to implantation of exfoliated cells from the original neoplasm to the peritoneal surface rather than invasion of lymphatics or blood vessels.^{11,23} In human medicine, RCC has been labelled one of the 'great mimics' as a result of its unpredictable metastatic pattern.¹³ In humans, bone is the most common site of metastasis, with metastasis to the axial skeleton accounting for approximately 26% of all metastases.^{13,24}

Treatment

Treatment has only been attempted in a few cases because the diagnosis is usually made late during the disease process.^{1,19,23}

CASE PRESENTATION

A 16-year-old Warmblood gelding was referred to the Onderstepoort Veterinary Academic Hospital (OVAH) for a lameness evaluation as well as respiratory workup on 1 March 2021. The patient was first seen by the referring veterinarian on 3 February after the gelding showed mild epistaxis and coughing after a riding lesson. The horse was pyrexia (38.9°C) and had mild tachypnoea (24 breaths per minute [brpm]) and tachycardia (45 beats per minute [bpm]). The gelding was treated with anti-inflammatories and antibiotics and rested for 7 days. When the horse was ridden after 7 days, the cough recurred, and a complete blood count revealed a mild mature neutrophilia, after which antibiotic and anti-inflammatory therapy and paddock rest were extended for an additional 7 days.

The cough improved with paddock rest, but the gelding developed a right hind (RH) limb lameness, which became progressively worse over 3 days. Hoof tester application elicited pain in the medial quarter of the RH hoof, but no solar abscess could be located after shoe removal. The horse was poulticed daily for 4 days, but no abscess could be identified or was visible on radiographs. A full lameness exam was attempted, but the gelding was painful upon flexion and palpation of most of the structures of the RH limb. The lameness improved only slightly after a low six-point metatarsal nerve block.

INVESTIGATIONS

Clinical findings

On presentation to OVAH, the patient was bright, alert and responsive with a body condition of 6 of 9 but non-weight bearing on the RH limb (grade 5/5 American Association of Equine Practitioners (AAEP) RH lameness). The gelding was tachycardic (60 bpm) and tachypnoeic (30 brpm). All other clinical parameters were within normal limits. Blood was drawn to evaluate the complete blood count and serum biochemistry. A complete blood count revealed moderate neutrophilia (13.06×10^9 cells/L, ref. $3.54\text{--}7.08 \times 10^9$ cells/L) and mild lymphopenia (1.57×10^9 cells/L, ref. $1.8\text{--}3.6 \times 10^9$ cells/L). Serum biochemistry showed mild azotaemia (8.5 mmol/L, ref. 3.8–7.7 mmol/L) and moderate

LEARNING POINTS/TAKE-HOME MESSAGES

- Renal cell carcinoma (RCC) in horses is a rare but serious condition that can manifest with non-specific clinical signs, including chronic weight loss, intermittent colic, lameness and respiratory symptoms.
- Diagnostic challenges exist for RCC in horses as clinical signs may not always align with typical presentations, and standard diagnostic tests such as haematology, blood biochemistry, urinalysis and abdominocentesis have limited utility in confirming the disease.
- Ultrasonography is a valuable tool for evaluating kidney architecture and detecting suspected masses. Biopsy guided by ultrasonography can help diagnose and stage the disease.
- Metastasis to various areas can complicate diagnosis by causing additional clinical signs.
- The prognosis for horses with RCC is generally poor, often leading to euthanasia, as diagnosis often occurs in the terminal stage.

bilirubinaemia (50.7 mmol/L, ref. 8.3–30.2 µmol/L). Serum creatinine was normal (129 µmol/L, ref. 105–170 µmol/L). The packed cell volume was 42% (ref. 24%–44%) and the total serum protein was normal (78.1 g/L, ref. 66–78 g/L).

Static musculoskeletal examination revealed marked swelling and heat on the plantarolateral aspect of the RH pastern. The horse was severely reactive to the palpation and flexion of the pastern as well as global flexion of the RH. The digital pulse of the RH was increased. Hoof tester application elicited pain on the RH toe. Due to the severe grade of lameness, no dynamic lameness examination was performed.

Diagnostic imaging

Radiography

Radiography of the RH (fetlock, pastern and foot) was performed (Figure 1a,b), and a lytic bone lesion was observed on the lateral plantar aspect of the first phalanx (P1), starting mid-P1 and extending distally. There was also a marked sunburst-like periosteal reaction or amorphous bone associated with the lesion. Moderate soft tissue swelling and signs of bone remodelling were also observed.

Thoracic radiographs revealed consolidation in the caudodorsal lung field (Figure 2).

Ultrasonography

Ultrasonography of pastern, digital flexor tendons and sesamoid ligaments was performed (Figure 3a,b). The lateral oblique sesamoid ligament was thickened and hypoechoic. Its insertion on P1 could not be accurately determined as the region was irregular. The plantar surface of P1 presented a

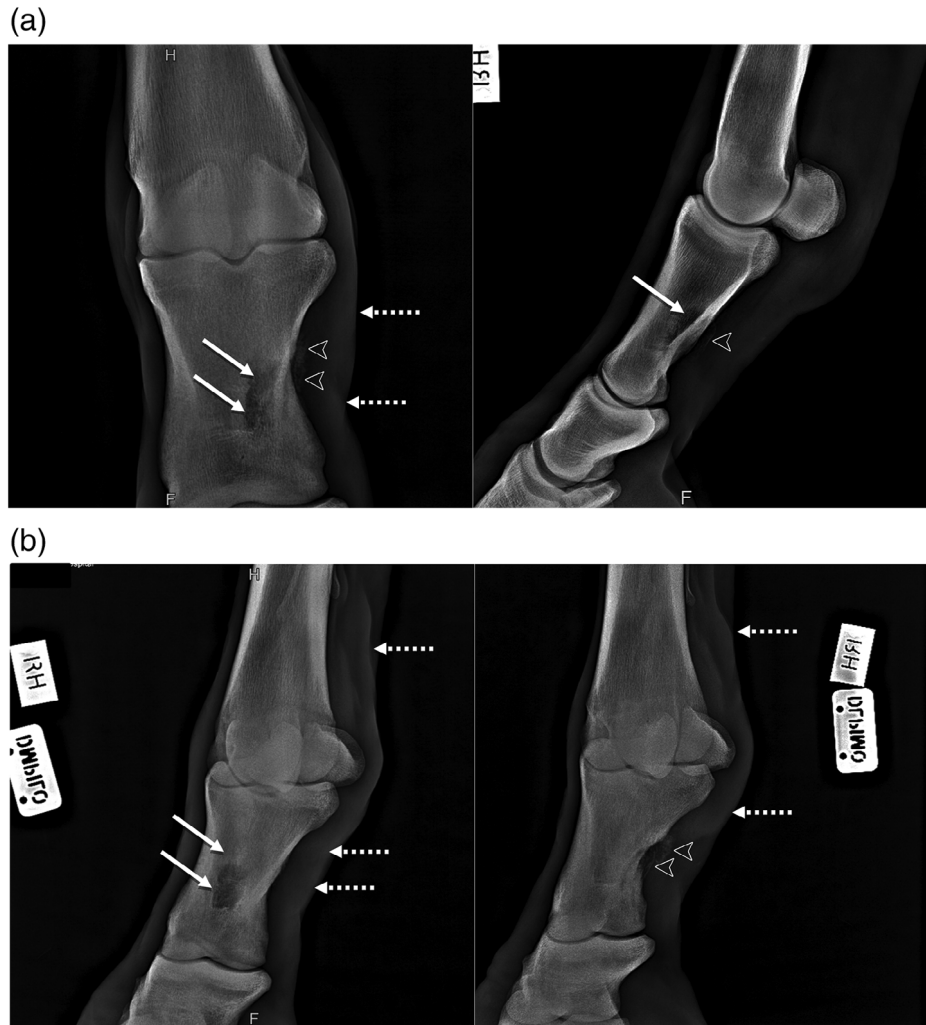


FIGURE 1 Lateromedial and dorsopalmar (a) as well as oblique (b) radiographs of the right metatarsophalangeal joint showing a lytic bone lesion (white arrows) on the lateral plantar aspect of the first phalanx (P1) starting mid P1 and extending distally. This was associated with a marked sunburst-like periosteal reaction or amorphous bone (white arrow heads). Moderate soft tissue swelling (dashed arrows) can be seen on the pastern.

bone defect with hyperechoic regions and a hyperechoic line proximal slightly plantar to the adjacent normal bone surface. The dorsal surface of the affected bone was irregular. The plantar aspect of the affected P1 was irregular.

Ultrasonography of the thorax revealed numerous pleural irregularities in the dorsal lung field extending caudally from intercostal space (ICS) 13 on the left and ICS12 on the right. The right lung seemed more affected than the left lung. A hyperechoic mass was seen in the right kidney on transcutaneous abdominal ultrasound; unfortunately, no images of the kidneys were recorded. The right kidney was not palpable transrectally.

Computed tomography

The horse was sedated and contiguous 0.5 mm transverse images (helical 128-slice Toshiba Aquilion prototype hydrolically mounted CT scanner from Canon Medical Systems, Japan—720 mm gantry bore diameter, with 64 detector rows; 0.35–1.5 rotations per second) of the distal extremities of the hindlimbs, including the metatarsophalangeal joints, were obtained (Figure 4) with the horse standing. These revealed an aggressive, primarily destructive, osseous lesion of the plantarolateral proximal phalanx with a soft tissue

component. Primary osseous neoplasia was prioritised, with osteomyelitis less likely. Although this lesion did involve the insertion of the lateral oblique sesamoidean ligament and there was mild desmitis of the ligament, traumatic avulsion was unlikely to cause the extent of these changes. Ultrasound guided biopsy of the lesion was advised for further characterisation as clinically indicated.

DIFFERENTIAL DIAGNOSIS

Differential diagnosis included primary osseous neoplasia.

TREATMENT

Initially, the horse was maintained on intravenous fluid therapy and flunixin meglumine (1.1 mg/kg IV q12h), but due to persistent severe lameness (5/5 AAEP RH lameness) additional analgesia was initiated. Oral gabapentin (10 mg/kg PO q12h), intramuscular morphine (0.1 mg/kg IM q4h) and ketamine (0.4 mg/kg/h IV CRI) were added to control pain. With the additional analgesia, comfort improved, heart rate decreased slightly (52–56 bpm) and lameness improved to the point where the horse could bear weight but was still

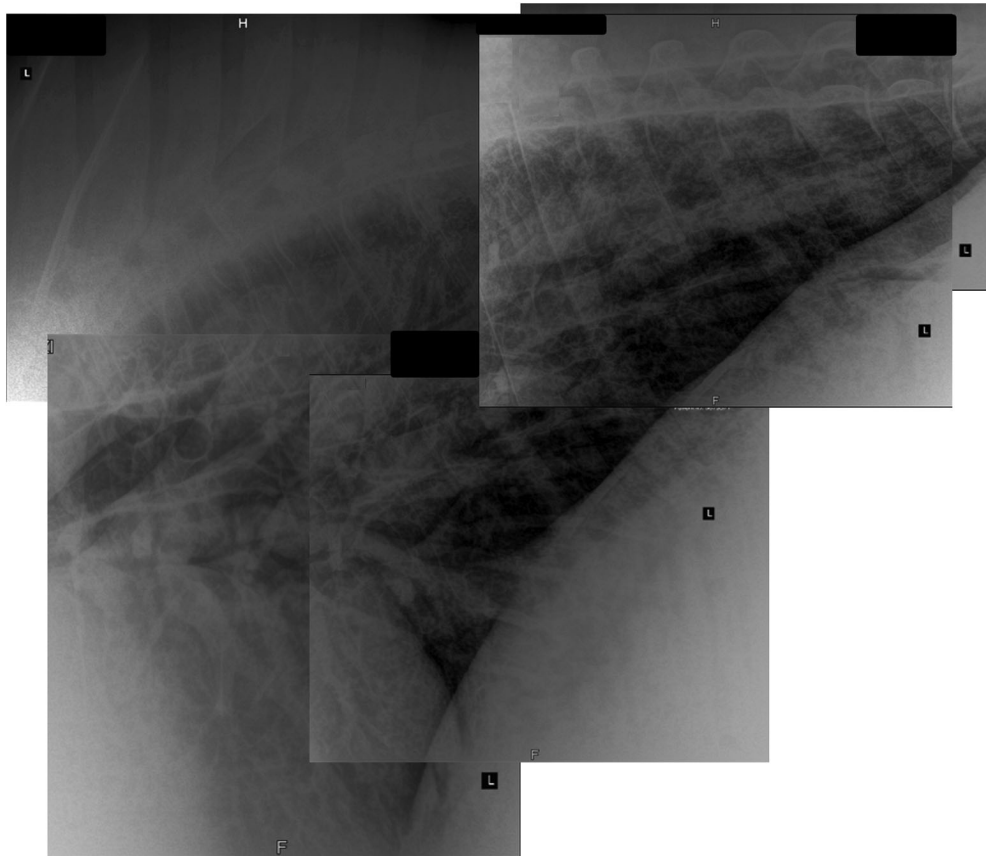


FIGURE 2 Lung radiographs revealing extensive dorsal lung field consolidation indicative of neoplastic infiltration.

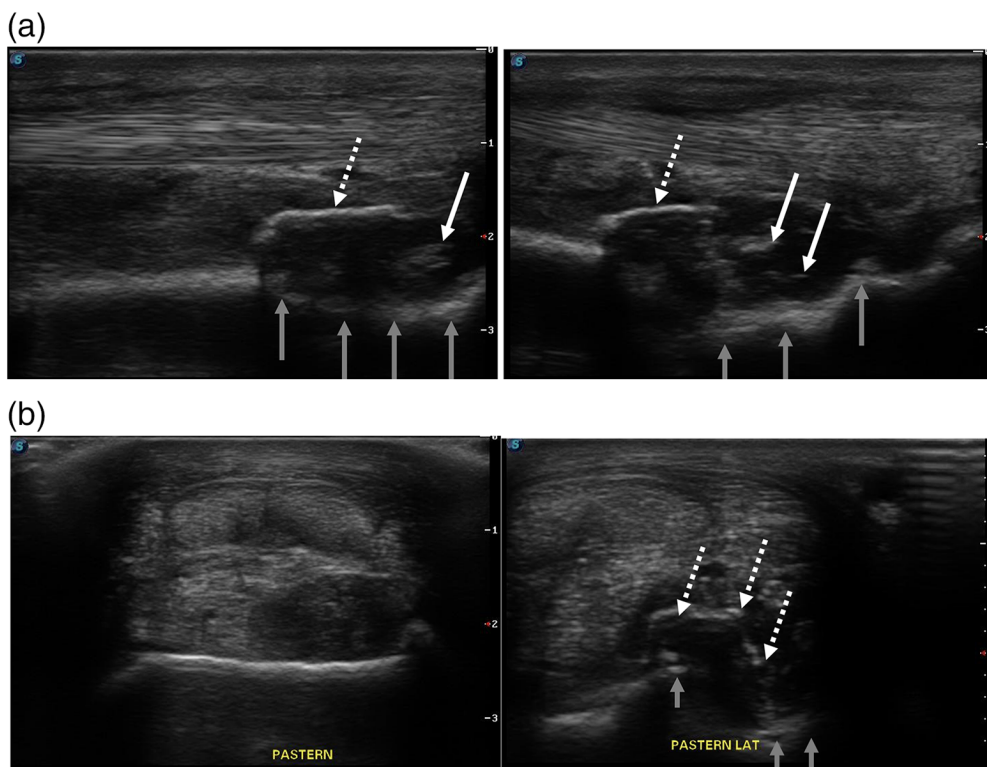


FIGURE 3 Longitudinal (a) and transverse (b) ultrasound images of the right hind pastern revealing a hypoechoic enlarged lateral oblique sesamoid ligament (white arrows), a bone defect in the plantar surface of P1 (grey arrows) with hyperechoic regions and a hyperechoic line proximal slightly plantar to the adjacent normal bone surface (dashed white arrows).

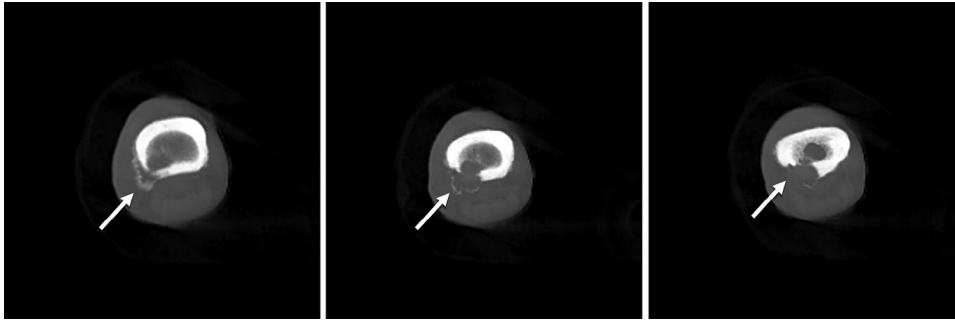


FIGURE 4 Computed tomography images of the distal right hindlimb showing an aggressive, primarily destructive, osseous lesion of the plantarolateral proximal phalanx with amorphous new bone (white arrows).

obviously lame at a walk (4/5 AAEP RH lameness). The affected and supporting limbs were bandaged.

OUTCOME AND FOLLOW-UP

Outcome

A neoplastic space-occupying lesion of P1 with possible metastasis to the lung was suspected. Humane euthanasia was advised and performed due to the severe clinical signs, suspicion of neoplastic lesion, high risk of treatment and poor prognosis.

Pathology findings

On postmortem examination, a large, firm, mottled red to tan encapsulated mass distorted the shape of the left kidney and extended from the capsular surface to the medulla (13 × 6 × 3 cm). Histologically, renal tissue was largely effaced by islands, nests, ribbons, tubules and irregular trabeculae separated and surrounded by immature fibrous connective tissue (consistent with a scirrhous response), infiltrated by small to moderate numbers of lymphocytes and plasma cells. The neoplastic cells were polygonal with indistinct cell margins, scant eosinophilic cytoplasm and large round to oval nuclei with finely stippled to vesicular chromatin and one to multiple prominent magenta nucleoli. Mitoses were frequent and extensive foci of haemorrhage and necrosis were infiltrated by large numbers of neutrophils. A thick layer of mature fibrous connective tissue on the margins of the tumour and adjacent renal cortex was infiltrated by moderate numbers of lymphocytes, plasma cells and haemosiderin-laden macrophages. Moderate lymphovascular invasion was seen as well as metastasis to the renal pelvis.

In addition, a light brown, irregularly lobulated, soft firm mass on the plantar aspect of the RH P1 replaced the bone cortex and extended into the marrow cavity (Figure 5). Large numbers of metastases (1–2 cm diameter) were also seen attached to the pleura overlying the left 4th, 8th, 10th and 15th ribs (greatly expanding both adrenal glands and the surrounding adipose tissue) and throughout the lungs and, to a lesser extent, the liver. Pathological examination confirmed the presence of a metastatic RCC, including the plantarolateral aspect of the RH P1. All of the metastases had similar histological appearance to the original renal mass. Mild serous

hydropericardium was also present. The remaining tissues were unremarkable.

DISCUSSION

Equine RCC is a rare condition in horses^{1–5} and other domestic animals. Metastasis to the liver and lungs was reported in 70% of the renal carcinoma metastasis seen.⁷ Interestingly, even though metastasis and infiltration are common, extension into the urinary tract is uncommon.

Diagnosis

Clinical signs and examination

Horses suffering from RCC are generally systematically healthy at presentation. Presenting clinical signs can include pyrexia, colic, chronic weight loss, anorexia, cachexia, haematuria, polyuria, polydipsia, anaemia, haemoperitoneum, ascites, abdominal distension, ventral oedema, intra-abdominal mass, hypovolaemic shock or haemorrhage of the affected vessels followed by acute deterioration.^{1,2,4,5,8,10,13–16}

Endogenous pyrogens can cause pyrexia. This occurs either directly or because of sensitised lymphocytes interacting with tumour-related antigens. Anaemia can be due to blood loss or secondary to the neoplastic and inflammatory processes.¹¹ It is thought that vascular invasion of the renal microvasculature by the tumour may lead to haematuria.^{2,4,25}

The clinical signs mentioned above were documented in most horses with RCCs. These clinical signs are non-specific and do not point to a particular disease process. This is what makes early detection of the disease challenging.

Diagnostic imaging

Transabdominal and transrectal ultrasound can be used to evaluate the architecture of the kidneys, which can also indicate acute nephrosis or chronic renal disease. With transrectal examination, the entire kidney and the adjacent lymph nodes can be evaluated. However, the limitation of renal ultrasound is that the equine kidney cannot be evaluated in two planes. Various ultrasonographic appearances can be found with RCCs, ranging from loss of normal renal architecture to complete obliteration of normal renal anatomy. The image

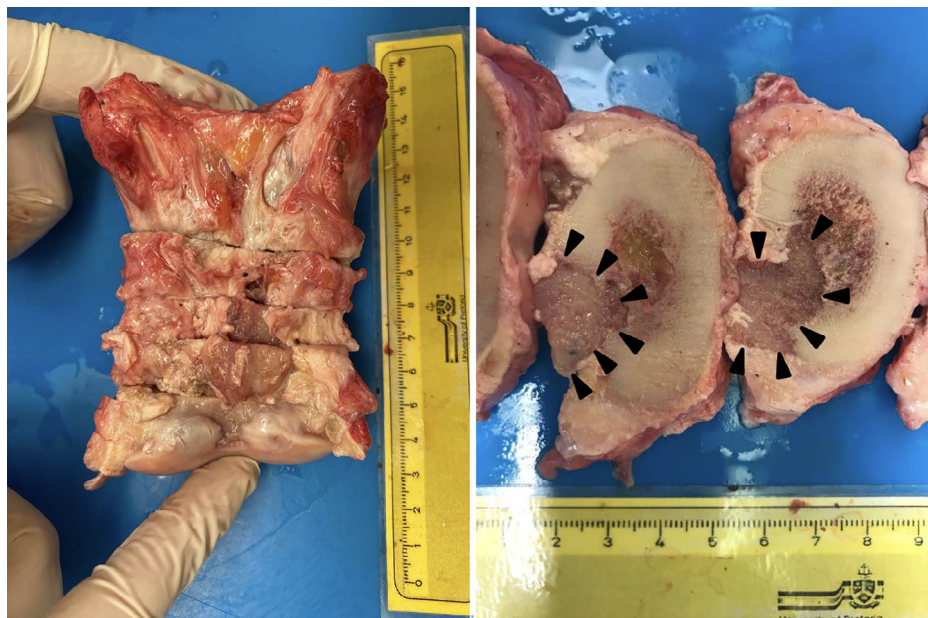


FIGURE 5 Postmortem photos of the right hind pastern (P1) with a space-occupying soft tissue mass (black arrow heads) seen obliterating the plantar cortex.

can range from a hyperechoic to hypoechoic mass or complex patterns of echogenicity with significant tumour liquefaction and necrosis causing acoustic shadowing and calcification. An abscess, haematoma, cyst and tumour can be differentiated with ultrasonographic evaluation.

Screening for metastasis can be done with thoracic radiographs and rectal palpation of the regional lymph nodes.¹⁶

Laboratory results

Non-specific changes have been reported in haematology, serum biochemistry and urinalysis.^{1,4} It is of little aid in providing a diagnosis for RCC.⁴ An increase in serum creatinine concentrations and blood urea levels can be detected in clinical pathology, including abnormalities such as neutrophilia, hypoglycaemia, hypoalbuminaemia, anaemia and thrombocytopenia.²³ None of these are specific for RCC. Osseous and hepatic metastasis can possibly be detected with the evaluation of serial serum alkaline phosphatase and serum liver enzyme levels. Serum biochemistry can also be useful in evaluating renal function following the confirmation of disease.⁴

During urinalysis, evaluation of the urine gamma-glutamyl transpeptidase (GGT)/creatinine ratio might be an indicator of renal tubular damage. A range of less than 25 for the urine GGT/creatinine ratio is considered normal. A value higher than 25 can be an indication of proximal tubular damage.¹⁶ However, it is important to note that blood urea nitrogen levels and creatinine levels may remain normal in a horse suffering from a unilateral disease.^{1,9,20} Very few cases of bilateral RCC have been reported.^{1,13,15} Abnormal cells may be detected with cytological evaluation of urine sediment.^{4,9}

Abdominocentesis can also be used as a diagnostic tool. Abdominal neoplasia can be suspected with neoplastic cells in the peritoneal fluid. Neoplastic cells have only been detected in the peritoneal fluid of 11% out of 25 cases with intra-abdominal neoplasia.^{1,4} Abdominocentesis results can include

an increase in the total protein concentration in horses with RCC.⁴

Histopathology

Ultrasound-guided biopsy and histological diagnosis can be used to differentiate between renal tumours.² Renal carcinomas are classified as tubular, papillary, acinar or solid.¹⁰ Cytologically, they can be subdivided into granular, basophilic, eosinophilic or clear cells.^{2,8}

The gross pathology usually consists of a well-demarcated, lobulated, ovoid or round white mass. Excision is often difficult due to the tumour developing adhesions and being locally invasive.⁵ During postmortem examination, abnormal fluid has been reported in the abdominal cavity. This can include blood-stained fluid or haemorrhage due to a ruptured kidney.^{1,8} Abnormalities in the shape of the kidney and tumour have also been observed, leading to displacement of organs and tissues, which includes but is not limited to the kidney itself, the ureter, the adrenal gland and the spleen.⁸ Metastasis is common in equine RCC, including to the liver, aorta, regional lymph nodes, heart, lungs, cranial mediastinum and bone.¹

Outcome

RCC is mainly staged using the tumour, nodes and metastasis (TNM) system.²³ The TNM system should be combined with mitotic count and nuclear grading to improve the accuracy of the prognosis.²² Thoracic radiographs and abdominal ultrasound are important to perform following the diagnosis of RCC to aid in determining the prognosis.⁴ However, it is impossible to estimate the survival time and prognosis of most horses.⁴

Non-specific and misleading presenting signs make early diagnosis, and thus treatment, challenging.^{1,20} Initial

treatment is usually symptomatic until a diagnosis is made.²³ If the condition is detected at an early stage a unilateral nephrectomy might be possible, depending on the presence of metastasis and adhesions by the mass.^{16,19,23,26} Theoretically, surgical excision, chemotherapy with cisplatin and radiation therapy are treatment options for appendicular neoplasms. The detection of metastasis is extremely important prior to commencing treatment because the presence of metastasis limits the success of treatment.¹⁹ Euthanasia is most often advised following diagnosis.²³

CONCLUSION

Very few cases of primary equine RCC have been documented in the literature.¹³ RCCs need to be considered for horses that show non-specific clinical signs such as chronic weight loss and intermittent colic.¹⁴ Clinical signs vary, are non-specific and could be related to a number of different diseases. Therefore, it is also important to evaluate the kidney per rectum with each rectal examination. This can aid in detecting any abnormalities that might be present in the left kidney should the clinical signs include colic, weight loss, ascites, etc.¹⁶ Haematology, blood biochemistry, urinalysis and abdominocentesis are of limited use in the diagnosis of this disease. Their results could lead to the suspicion of disease and possible indications of secondary damage due to the disease, but it is not confirmatory.^{1,4}

Along with the clinical signs, ultrasonography is a valuable tool for evaluating the architecture of the kidney, detecting a suspected mass and guiding biopsy. The results of the biopsy can be used to diagnose and stage the disease. A combination of all these diagnostic results will aid in diagnosing RCC.

The treatment of horses with RCC is limited by the non-specific initial clinical signs and the very limited treatment options once the diagnosis is confirmed. This is often due to the diagnosis occurring in the terminal stage of the disease.^{19,23} The poor prognosis usually leads to euthanasia.²³

It is important to note the wide variety of areas where metastasis has been found. Because these areas are affected, it usually leads to other clinical signs, which can hinder accurate diagnosis. The limited information documented regarding equine RCC indicate that more research is necessary to better understand the disease process and allow earlier diagnosis.

RCCs are usually found unilaterally but have been reported bilaterally, with one report mentioning that the left kidney is more commonly affected.^{2,4,13,15,17}

The diagnosis of RCC in this patient was challenging. The clinical signs were suggestive of respiratory disease and lameness, and haematology results were non-specific. The patient was bright, alert and responsive but non-weight bearing on the RH limb (grade 5/5 AAEP RH lameness) at presentation. The patient also had a history of epistaxis and coughing. These clinical signs were later revealed to be the result of metastasis of a primary RCC. None of the commonly reported clinical signs of RCC were present in this case.

Radiography of the RH was performed, and a lytic bone lesion was observed on the lateral plantar aspect of the first phalanx (P1), starting mid-P1 and extending distally. Thoracic radiographs revealed consolidation in the caudodorsal lung field. With the use of ultrasonography, computed tomography

and radiography, secondary metastasis to the lung fields and RH P1 was seen.

Due to the severity of clinical signs, the suspicion of neoplasia and the poor prognosis, euthanasia was advised and performed. During the postmortem examination, a mass extending from the capsular surface to the medulla (13 × 6 × 3 cm) of the left kidney was found. This tumour was confirmed to be the primary tumour with the use of histopathology.

The information in this case report indicates that more research is needed to improve the diagnosis of this condition.

AUTHOR CONTRIBUTIONS

Elza Hollenbach and Juan Alberto Munoz were the attending clinicians. Elza Hollenbach and Corme Randlehoff prepared the manuscript. Emily P. Mitchell performed the postmortem examination and histopathology. Emily P. Mitchell and Juan Alberto Munoz reviewed the manuscript.

ACKNOWLEDGEMENTS

Thanks to Sheelagh Higgerty, who performed CT scans, and Amy Norvall, who evaluated the CT images.

CONFLICT OF INTEREST STATEMENT

The authors declare they have no conflicts of interest.

FUNDING INFORMATION

The authors received no specific funding for this work.

ETHICS STATEMENT

This case report was approved by the Onderstepoort Veterinary Academic Hospital. Informed owner consent was obtained in writing.

ORCID

Elza Hollenbach  <https://orcid.org/0000-0001-7771-8027>

REFERENCES

- Knowles E, Withers J, Day M, Mair T. Renal carcinoma as a cause of sudden death in an aged horse. *Equine Vet Educ.* 2008;20(9):452–55. <https://doi.org/10.2746/095777308x334275>
- Brown PJ, Holt PE. Primary renal cell carcinoma in four horses. *Equine Vet J.* 1985;17(6):473–77. <https://doi.org/10.1111/j.2042-3306.1985.tb02561.x>
- Cotchin E. A general survey of tumours in the horse. *Equine Vet J.* 1977;9(1):16–21. <https://doi.org/10.1111/j.2042-3306.1977.tb03964.x>
- Wise LN, Bryan JN, Sellon DC, Hines MT, Ramsay J, Seino KK. A retrospective analysis of renal carcinoma in the horse. *J Vet Intern Med.* 2009;23(4):913–18. <https://doi.org/10.1111/j.1939-1676.2009.0326.x>
- Haschek WM, King JM, Tennant BC. Primary renal cell carcinoma in two horses. *J Am Vet Med Assoc.* 1981;179(10):992–94.
- Vienenkötter J, Siudak K, Stallenberger L, Herden C. Renal neoplasia in horses—a retrospective study. *Tierarztl Prax Ausgabe G Grosstiere—Nutztiere.* 2017;45(5):290–95. <https://doi.org/10.15653/TPG-161091>
- Schott HC, Waldrige B, Bayly WM. Disorders of the urinary system. *Equine internal medicine: Fourth edition.* 2018;888–990. doi: [10.1016/B978-0-323-44329-6.00014-0](https://doi.org/10.1016/B978-0-323-44329-6.00014-0)
- Pomroy W. Renal adenocarcinoma in a horse. *Equine Vet J.* 1981;13(3):198–200. <https://doi.org/10.1111/j.2042-3306.1981.tb03487.x>
- Lichtenberg D, Holst I, Winter J, Kleinschmidt S, Venner M. Renal adenocarcinoma: clinic and immunohistochemical differentiation via cytokeratines. *Pferdeheilkunde.* 2014;30:291–96.
- Meuten DJ, Meuten TLK. Tumors of the urinary system. In: *Tumors in domestic animals.* John Wiley & Sons; 2016. p. 632–88. <https://doi.org/10.1002/9781119181200.ch15>

11. Mesquita LP, de Mesquita Neto FD, Varaschin MS, Wouters ATB, Wouters F. Carcinoma renal associado à carcinomatose peritoneal em uma égua. *Cienc Rural*. 2017;47(1):1–4. <https://doi.org/10.1590/0103-8478cr20160485>
12. Romero BF, Iglesias-García M, Gil-Molino M, Gómez L, Galapero J, Parejo C, et al. Bilateral uveitis in a horse with a renal carcinoma. *J Equine Vet Sci*. 2022;118:104111. <https://doi.org/10.1016/j.jevs.2022.104111>
13. Rhind SM, Hawe C, Dixon PM, Scudamore CL. Oral metastasis of renal cell carcinoma in a horse. *J Comp Pathol*. 1999;120(1):97–103. <https://doi.org/10.1053/jcpa.1998.0255>
14. Birkmann K, Trump M, Dettwiler M, Rütten M, Wehrli Eser M. Severe polyuria and polydipsia as major clinical signs in a horse with unilateral renal adenocarcinoma. *Equine Vet Educ*. 2016;28(12):675–80. <https://doi.org/10.1111/eve.12123>
15. West H, Kelly D, Ritchie H. Renal carcinomatosis in a horse. *Equine Vet J*. 1987;19(6):548–51. <https://doi.org/10.1111/j.2042-3306.1987.tb02671.x>
16. Ramirez S, Seahorn TL. Ultrasonography as an aid in the diagnosis of renal cell carcinoma in a horse. *Vet Radiol Ultrasound*. 1996;37(5):383–86. <https://doi.org/10.1111/j.1740-8261.1996.tb01247.x>
17. Ocarino NM, Silva AE, França SA, Rachid MA, Nascimento EF, Palhares MS, et al. Renal cell carcinoma with bone metaplasia in a horse. *J Equine Vet Sci*. 2006;26(4):168–70. <https://doi.org/10.1016/j.jevs.2006.02.007>
18. Young AC, Hoffmann KL, Begg AP, Major DA. Acute lameness associated with osseous metastasis of a peri-renal carcinoma in a horse. *Aust Vet J*. 2010;88(9):346–50. <https://doi.org/10.1111/j.1751-0813.2010.00609.x>
19. Oosterlinck M, Raes E, Verbraecken S, van Loon G, Maes S, Gielen I, et al. Severe lameness caused by metastatic renal adenocarcinoma of the third phalanx in a Warmblood mare. *Equine Vet Educ*. 2011;23(10):512–16. <https://doi.org/10.1111/j.2042-3292.2011.00282.x>
20. Rumbaugh M, Latimer F, Porthouse K, Cho D, Leblanc C. Renal carcinoma with osseous and pulmonary metastases in an Arabian gelding. *Equine Vet J*. 2003;35(1):107–9. <https://doi.org/10.2746/042516403775467522>
21. Swain JM, Pirie RS, Hudson NPH, Else RW, Evans H, McGorum BC. Insulin-like growth factors and recurrent hypoglycemia associated with renal cell carcinoma in a horse. *Africa's Potential Ecol Intensif Agric*. 2013;53(9):1689–99.
22. Shuch BM, Lam JS, Belldgrun AS, Figlin RA. Prognostic factors in renal cell carcinoma. *Semin Oncol*. 2006;33(5):563–75. <https://doi.org/10.1053/J.SEMINONCOL.2006.06.006>
23. Hilton HG, Aleman M, Maher O, Peterson TS, Whitcomb MB, Galuppo LD. Hand-assisted laparoscopic nephrectomy in a standing horse for the management of renal cell carcinoma. *Equine Vet Educ*. 2008;20(5):239–44. <https://doi.org/10.2746/095777308x295783>
24. Rhind S, Sturgeon B. Papillary renal carcinoma with an unusual clinical presentation in a horse. *Equine Vet Educ*. 1999;11(4):171–73. <https://doi.org/10.1111/j.2042-3292.1999.tb00941.x>
25. Servantie J, Magnol J, Regnier A, Lescure F, Merritt A. Carcinoma of the renal pelvis with bony metaplasia in a horse. *Equine Vet J*. 1986;18(3):236–38. <https://doi.org/10.1111/j.2042-3306.1986.tb03610.x>
26. Mullard J, Ireland J, Dyson SJ. Radiographic assessment of the ratio of the hoof wall distal phalanx distance to palmar length of the distal phalanx in 415 front feet of 279 horses. *Equine Vet Educ*. 2020;32(S10):2–10. <https://doi.org/10.1111/eve.13004>

How to cite this article: Hollenbach E, Mitchell EP, Randlehoff C, Munoz JA. Metastatic renal carcinoma in a horse presented for lameness examination and suspected pneumonia. *Vet Rec Case Rep*. 2024;12:e935. <https://doi.org/10.1002/vrc2.935>

MULTIPLE CHOICE QUESTION

Increased serum creatinine levels in this case alerted the attending veterinarian to possible kidney involvement.

POSSIBLE ANSWERS TO MULTIPLE CHOICE QUESTION

- a. True, Creatinine was significantly increased
- b. False, Creatinine was normal

CORRECT ANSWER

- b. False, creatinine was normal

EXPLANATION

Serum Creatinine in this case was normal. This is most likely due to the large functional reserve capacity of the kidneys. This highlights that kidney disease cannot be ruled out with normal creatinine levels.