







# Clinicoradiologic features of ameloblastomas: A single-centre study of 155 cases

Chané Smit<sup>1</sup>  | Liam Robinson<sup>1</sup>  | Jason Ker-Fox<sup>2</sup>  |  
Felipe Paiva Fonseca<sup>1,3</sup>  | Willie F. P. van Heerden<sup>1</sup>  | André Uys<sup>4</sup> 

<sup>1</sup>Department of Oral and Maxillofacial Pathology, School of Dentistry, Faculty of Health Sciences, University of Pretoria, Pretoria, South Africa

<sup>2</sup>Private Statistician, Cape Town, South Africa

<sup>3</sup>Department of Oral Surgery and Pathology, School of Dentistry, Federal University of Minas Gerais (UFMG), Belo Horizonte, Brazil

<sup>4</sup>Department of Anatomy, School of Medicine, Faculty of Health Sciences, University of Pretoria, Pretoria, South Africa

## Correspondence

Chané Smit, Pretoria Oral Health Care Centre, Corner of Steve Biko and Dr Savage Road, Pretoria 0084, South Africa.  
Email: [chane.smit@up.ac.za](mailto:chane.smit@up.ac.za)

## Abstract

**Background:** The purpose of the current study was to report on the clinical presentation and radiologic features of 155 cases of ameloblastoma (AB), representing a detailed, large, single-centre radiologic study.

**Methods:** Histologically confirmed cases were reviewed over 11 years. Demographic and clinical data were retrieved from the patient's records. Radiologic information was analysed from available radiographs. The radiologic features of ABs were assessed according to the mean age of presentation and the mean duration of the lesion. The distinguishing radiologic features between adults/children and sex were also evaluated.

**Results:** A statistically significant correlation existed between loss of border demarcation and advanced mean age. Multilocular lesions were markedly more common in adults compared to children. Multilocular ABs were associated with increased lesion duration and advanced mean age. Radiologic signs of reactive bony changes associated with the tumour presented at the highest mean duration of all bony effects. Bony expansion and cortical destruction were statistically correlated with lesion duration. Tooth impaction was more common in children. Some mandibular lesions reached a significant size, resulting in impingement of the maxillary sinus, zygoma, orbit and pterygoid plates.

**Conclusion:** Due to unfortunate healthcare access constraints, ABs grow to significant sizes and exhibit features not often reported in the literature. The findings of this analysis highlighted the radiologic features of ABs expressed through the mean age and duration of the lesion. This emphasises the significance of timely management of these lesions.

## KEYWORDS

ameloblastoma, benign odontogenic neoplasm, maxillofacial pathology, maxillofacial radiology

## 1 | INTRODUCTION

Ameloblastoma (AB) is an aggressive benign odontogenic neoplasm arising from epithelial remnants of the dental lamina.<sup>1</sup> Current theories regarding the aetiopathogenesis of AB revolve around an initial mutation initiating the events that lead to neoplastic transformation. However, the sequence of events and exact pathogenesis remains poorly understood.<sup>2</sup> ABs often present with mutations in genes involving the mitogen-activated protein kinase (MAP-K) pathway, frequently involving the *BRAF* gene.<sup>1</sup> Other less commonly implicated genes also affecting the MAP-K pathway include *KRAS*, *NRAS*, *HRAS* and *FGFR2*. Mutations in the *SMO* gene activating the hedgehog signalling pathway may also be seen.<sup>1</sup> Multiple mutations within different populations have been identified and can be explained by the genetic diversity among population groups.<sup>3</sup>

Globally, AB is the second most common odontogenic tumour after an odontoma<sup>1</sup>; however, it is the most common on the African continent.<sup>4,5</sup> They represent 34% of all odontogenic tumours, with their prevalence differing significantly between different population groups.<sup>6,7</sup> ABs are especially prevalent in Africa and East Asia, representing over 75% of all odontogenic tumours in these regions.<sup>5,7</sup> The global incidence of ABs is 0.92 per million persons (PMP) per year,<sup>8</sup> with a higher incidence in South African patients (1.65 PMP).<sup>9</sup> The number of diagnosed cases of ABs per hospital per year has increased globally from 3.97% before 1990 to 5.3% after this period.<sup>7</sup> Given that the South African incidence was last calculated before 1990,<sup>9</sup> the current incidence may be much higher if aligned with global trends.

AB presents at a mean age of 38 years (range 4–92 years) with a peak incidence during the fourth and fifth decades of life.<sup>1,3,6,10,11</sup> They often present as painless swellings with an ‘eggshell cracking’ effect on palpation. Most cases manifest with associated pain, with paraesthesia reported in the minority of cases.<sup>12</sup> As a result of the substantial growth and aggressive behaviour of this neoplasm, facial disfigurement and impaired functionality frequently arise.<sup>1,13</sup> Radiologically, ABs present as expansile, well-demarcated uni- or multilocular radiolucencies, often showing bony expansion and root resorption.<sup>12</sup> Multilocular lesions can present with large locules resembling ‘soap bubbles’ or small locules giving a ‘honeycomb’ appearance.<sup>1,14</sup>

ABs can be treated conservatively or via resection, depending on the clinical features and histopathologic classification.<sup>15–17</sup> Reichart et al. reported that patients with ABs in developing countries typically present for treatment at a later stage (33 months) compared to developed countries (25 months).<sup>11</sup> Due to their longer duration in developing countries, ABs may present as extensive lesions with unique presentations. This study aimed to report detailed clinical and radiologic features of ABs in a South African cohort.

## 2 | MATERIALS AND METHODS

The study was conducted following approval by the University of Pretoria, Faculty of Health Sciences Research Ethics Committee

(reference number: 723/2022). All procedures followed the ethical standards of the Helsinki Declaration of 1975, as revised in 2008.

Histologically confirmed cases of conventional and unicystic ABs were retrospectively reviewed over 11 years (2012–2022). Cases were collected from the histopathologic archives of the Department of Oral and Maxillofacial Pathology, University of Pretoria. The primary author (CS) and two experienced Oral and Maxillofacial Pathologists (LR and WvH) confirmed the diagnosis of all included cases from the available histopathologic slides. Cases with inconclusive diagnoses, insufficient tissue, recurrent ABs, adenoid ABs and cases of AB that transformed into ameloblastic carcinomas were excluded from this study.

Demographic and clinical data were retrieved from the patient's clinical records. Only cases with available radiographic examinations of sufficient quality for subsequent analysis were included in the final sample. Conventional radiographs, including panoramic (PR) and skull radiographs, and specialised imaging, consisting of computerised tomography (CT) and cone-beam CT (CBCT), were utilised for radiologic evaluation. Lesions located from the incisor to the canine region were classified as anterior, whereas lesions located posterior to the canine region were classified as posterior. The radiologic features were analysed by two authors (CS and AU), who have experience in the field of Maxillofacial Radiology, with any disagreements resolved by consensus and/or consultation with the other authors.

The results of the radiologic examinations were recorded using Microsoft Excel (Version 2019), with subsequent statistical analysis of the categorical data performed using SPSS software 29.0 (IBM Corporation, New York, NY, USA). The data consisted of both categorical data (borders, radiodensity, bone effects, etc.) and continuous data (age, duration, etc.). Data deemed to be categorical in nature was given an ‘either-or’ fashion of classification; for example, the borders of the lesion were classified as being either ‘well-demarcated’, ‘poorly-demarcated’, or with ‘focal loss of demarcation’. A univariate frequency table was constructed for each categorical variable, showing the percentage breakdown and distribution of the cases according to the variable parameters. Multivariate  $2 \times 3$  tables, which highlighted the interaction between the radiologic features and other variables, were constructed before determining the statistical significance thereof. Categorical data ( $2 \times 2$ ) correlations, such as child/adult and anterior/mandible (observed and unobserved), were assessed using chi-squared tests. Continuous and categorical data (with 2+ categories) correlations, such as borders and age, were assessed using a one-way ANOVA table. Continuous and categorical data (with two categories only), such as bone effects and age, were assessed using a *t* test (looking at variance in means). Throughout the statistical analysis, correlations with a two-sided asymptotic significance (*p* value) of less than 0.05 were considered statistically significant.

## 3 | RESULTS

During the 11-year study period, a total of 12 080 lesions involving the oral and maxillofacial region were diagnosed at the institution,

from which 390 ABs were diagnosed. The prevalence of ABs at this institution was therefore determined as 3.23% of all head and neck lesions. One hundred and ninety-six (196) cases were excluded from the current study due to a lack of radiographic examinations available on the relevant database. A further 14 cases were excluded for only having postoperative radiographs. Finally, 25 cases were excluded due to insufficient tissue available for further histopathologic analysis, which resulted in a total of 155 cases included in the final sample. The majority of cases were diagnosed as conventional ABs, with 12 classified as unicystic. Most cases were analysed using PR radiographs and skull views, with 23 cases having CBCT/CT imaging available for evaluation.

### 3.1 | Clinical features

Table 1 summarises the main demographic and clinical features of included cases. ABs had a peak prevalence in the second and third decades of life. Females presented at an older mean age (34.06 years) compared to males (31.76 years). The population group was reported in 141 cases, with black individuals being the most common (94.3%), followed by white individuals (4.3%) and Indian individuals (1.4%). The duration of the tumour, as reported by the patient, was slightly lengthier in males (23.96 months) compared to females (21.23 months). Most patients presented with painless, slow-growing swellings. Associated pain was reported in less than a third of cases. Bleeding, fistula formation and trismus were rarely seen (two cases each). Patients presenting with associated pain did not present earlier than those without pain (28.8 vs. 23.4 months).

In the current sample, ABs reached a considerable size, often involving multiple regions simultaneously. The mandible was affected in the majority of cases, with the posterior mandible affected in nearly all instances. Almost half of all mandibular cases extended from the posterior region to involve the anterior jaw. The ramus, coronoid and condyle were involved in 46.6%, 26.7% and 11.6% of mandibular cases, respectively. The maxilla was only affected in nine cases, with all lesions involving the posterior region. Seven cases extended to involve the anterior maxilla (Figure 1). Unlike the mandible, none of the maxillary cases crossed the midline. All subsites (maxilla and mandible) were affected in greater frequencies on the left side. The location of ABs did not differ significantly between children and adults (Table S1) or sex.

### 3.2 | Radiologic features

Table 2 summarises the main radiologic features, including the difference in radiologic presentations over the mean age and lesion duration, to assess whether certain factors were influenced by time. There were no statistically significant differences in radiologic features between males and females. Table S2 distinguished the radiologic features between children and adults (over 18 years of age).

**TABLE 1** Summarised demographic and clinical features of ABs.

Clinical features	n = 155	%
Age, years (mean, range) <sup>a</sup>	32.33	(4–95)
Sex (M:F)	81:74	1.1:1
Duration (months, range) <sup>b</sup>	25.31	(2 weeks to 240 months)
Clinical signs <sup>c</sup>		
Swelling	132	97.1%
Pain	38	27.9%
Slow growing	37	27.2%
Fast growing	4	2.9%
Mobile teeth	15	11%
Paraesthesia	4	2.9%
Ulcer	9	6.6%
Pus	5	3.7%
Location		
Maxilla	9	5.8%
Anterior	7	77.8%
Posterior	9	100%
Both	7	77.8%
Crosses midline	0	0%
Mandible	146	94.2%
Anterior	71	48.6%
Posterior	144	98.6%
Both	69	47.3%
Ramus	68	46.6%
Coronoid	39	26.7%
Condyle	17	11.6%
Crosses midline	50	34.2%

Abbreviation: AB, ameloblastoma.

<sup>a</sup>Age was not reported in two cases.

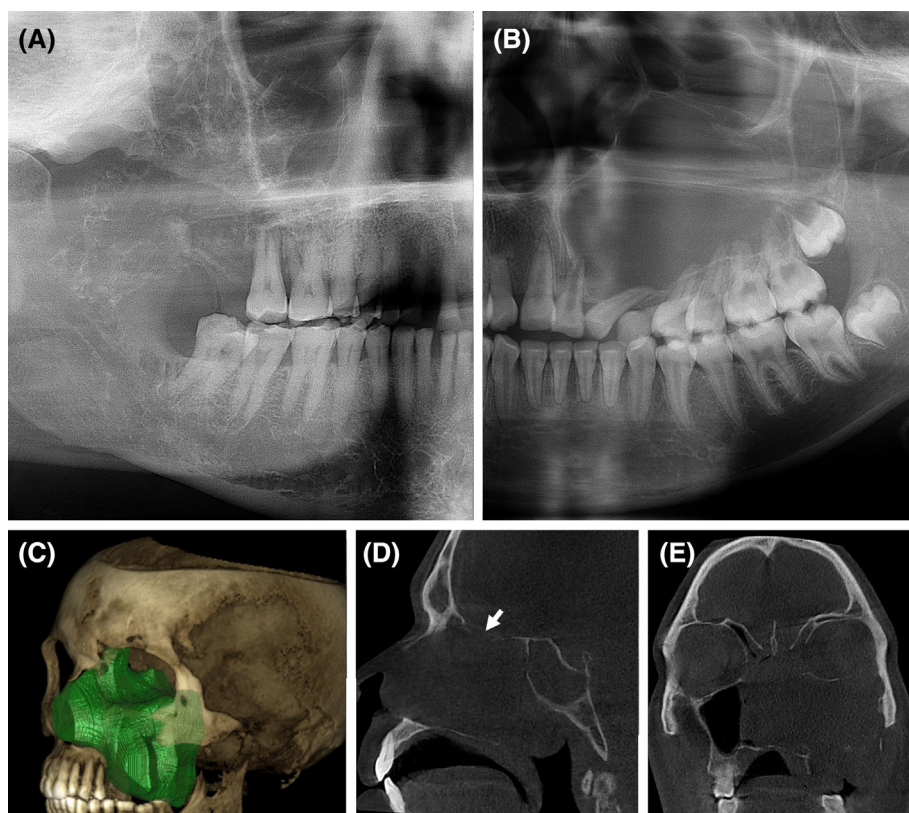
<sup>b</sup>The clinical duration was only reported in 108 cases.

<sup>c</sup>Clinical signs and or symptoms were reported in 136 patients, with patients often presenting with more than one symptom.

Most ABs appeared well-demarcated, with nearly half of the cases exhibiting a focal loss in demarcation due to high frequencies of cortical destruction. Borders with a loss of demarcation or those considered poorly demarcated were associated with advanced mean age and lesion duration. The advancement of mean age showed a statistically significant correlation with loss of border demarcation. Focal loss of demarcation was significantly more common in adults than children (49.2% vs. 29%).

Interestingly, 14.8% of cases presented with faint and focal internal calcifications, and one case presented with a mixed, fibro-osseous presentation (Figure 2). ABs with internal calcifications presented at an advanced mean age or lesion duration. Additionally, adult patients showed an increased percentage of lesions presenting with internal calcifications. However, these findings were not statistically significant.

Multilocular lesions were most commonly seen, with unilocular lesions with scalloped borders being the least common. Multilocular



**FIGURE 1** (A) Cropped panoramic radiograph of an AB affecting the posterior maxilla with extension to involve the pterygomaxillary complex. (B) Maxillary AB affecting both the anterior and posterior regions of the left maxilla resulting in the displacement of teeth, the orbit and the nasal cavity. (C) Three-dimensional reconstructed CBCT image showing the extent of a maxillary AB. (D) Sagittal CBCT image showing infiltration of the cranial base (arrow) and sphenoid sinus. (E) Coronal CBCT image showing involvement of the maxillary sinus, nasal cavity and impingement of the medial and inferior borders of the orbit. AB, ameloblastoma; CBCT, cone-beam computerised tomography.

lesions were significantly more common in adults (78%). In contrast, unilocular lesions predominated in children (50%). Seven of the unicystic cases occurred in children and five in adults. Furthermore, 35 cases of conventional ABs had a unilocular/scalloped appearance. Unilocular to scalloped and eventually multilocular lesions were associated with advanced mean age and lesion duration. In both instances, these findings were statistically significant.

Bony expansion and cortical thinning were seen in most cases, with more than half exhibiting cortical destruction. Another interesting finding in the current sample was the presence of radiologic signs of reactive bony changes associated with the lesion (Figure 3), a finding also more common in adults. Regarding the effects on the involved bone, cortical thinning followed by bony expansion and cortical destruction were associated with advanced mean age and lesion duration. Reactive bony changes showed the highest mean duration of all the bony effects. The average duration of cases with and without bony expansion was 24 months versus 11 months. Bony expansion and cortical destruction showed a statistical correlation with tumour duration. Additionally, cortical destruction was significantly more common in adults.

The most common effects on the surrounding dentition were root resorption, followed by tooth displacement and loss of associated teeth. The mean age and duration increased from tooth impaction to tooth displacement, root resorption and eventual loss of teeth. Loss of associated teeth was statistically correlated with a longer tumour duration, whereas tooth impaction and root resorption were statistically correlated with younger and more advanced

age at presentation, respectively. Tooth displacement was significantly more common in children, whereas teeth loss associated with the lesion was more common in adults. Tooth impaction was generally not common, but when present, it occurred significantly more commonly in children than adults. The most commonly impacted teeth in children were the second molars and canines (six cases each). In adults, the most frequently impacted tooth associated with the lesion was third molars (15 cases), followed by second molars and canines (2 cases each).

Another interesting finding of the current study was centred around the impingement of surrounding structures by the tumour. Displacement of the inferior alveolar nerve was seen in 59% of mandibular cases and was significantly influenced by the mean age of presentation. Maxillary lesions were analysed using both PR and CT/CBCT imaging in most cases and showed impingement of the maxillary sinus (100%), nasal cavity (78%), orbit (70%) and pterygoid plates (50%). One large maxillary lesion extended to impinge on the sphenoid sinus and the cranial base. In some cases, mandibular lesions reached a significant size, resulting in impingement of the maxillary sinus (10 cases), zygoma (6 cases), pterygoid plates (2 cases) and orbit (1 case) (Figure 4).

## 4 | DISCUSSION

ABs, although considered benign odontogenic neoplasms, often behave aggressively and grow to considerable sizes with marked patient morbidity, especially in developing countries. Demographic

**TABLE 2** Difference between radiologic findings of ABs and mean age of presentation and lesion duration.

Radiologic features	Mean age (years)	p Value	Lesion duration (months)	p Value	Total n = 155	%
<b>Borders</b>						
Well-demarcated	28.58	<b>0.009*</b>	18.49	0.117	82	52.9
Loss of demarcation	36.44		32.27		70	45.2
Poorly-demarcated	41.82		43.5		3	1.9
<b>Radiodensity</b>						
Osteolytic	31.53	0.159	22.58	0.104	131	84.5
Internal calcifications	37.84		44.57		23	14.8
Mixed	15.77		10		1	0.7
<b>Locularity<sup>a</sup></b>						
Multilocular	35.73	<b>0.0001*</b>	31.41	<b>0.025*</b>	107/154	69.5
Scalloped	30.98		13.3		15/154	9.7
Unilocular	21.9		9.68		32/154	20.8
<b>Bone effects</b>						
Bony expansion	31.73	0.599	27.83	<b>0.048*</b>	129	83.2
Cortical thinning	31.22	0.196	26.46	0.526	123	79.4
Cortical destruction	35.53	0.121	30.8	<b>0.008*</b>	86	55.5
Reactive bone	32.8	0.126	32.15	0.351	37	23.9
<b>Tooth effects</b>						
Loss of teeth	38.02	0.249	34.44	<b>0.001*</b>	72	46.5
Tooth displacement	28.58	0.186	26.85	0.370	90	58.1
Tooth impaction	20.83	<b>0.0000*</b>	18.53	0.134	32	20.6
Root resorption	30.99	<b>0.043*</b>	24.52	0.699	114	73.5
<b>Impingement of anatomical structures</b>						
Inferior alveolar nerve <sup>b</sup>	29.98	<b>0.000*</b>	22.87	0.053	86	58.9
Maxillary sinus <sup>c</sup>	35.87	0.171	50.83	<b>0.000*</b>	19/19	100
Nasal cavity <sup>c</sup>	29.45	0.930	12.00	0.432	7	77.8
Zygoma	33.35	0.149	45.00	0.453	6/15	40.0
Orbit <sup>c</sup>	35.76	<b>0.015*</b>	55.25	0.076	7/10	70.0
Pterygoid plates <sup>c</sup>	52.44	0.132	58.80	0.143	5/11	45.5

Abbreviation: AB, ameloblastoma.

\*Highlight statistically significant findings are in bold.

<sup>a</sup>In one-mixed density case, the locularity could not be described.

<sup>b</sup>Only mandibular cases analysed.

<sup>c</sup>Only maxillary cases analysed.

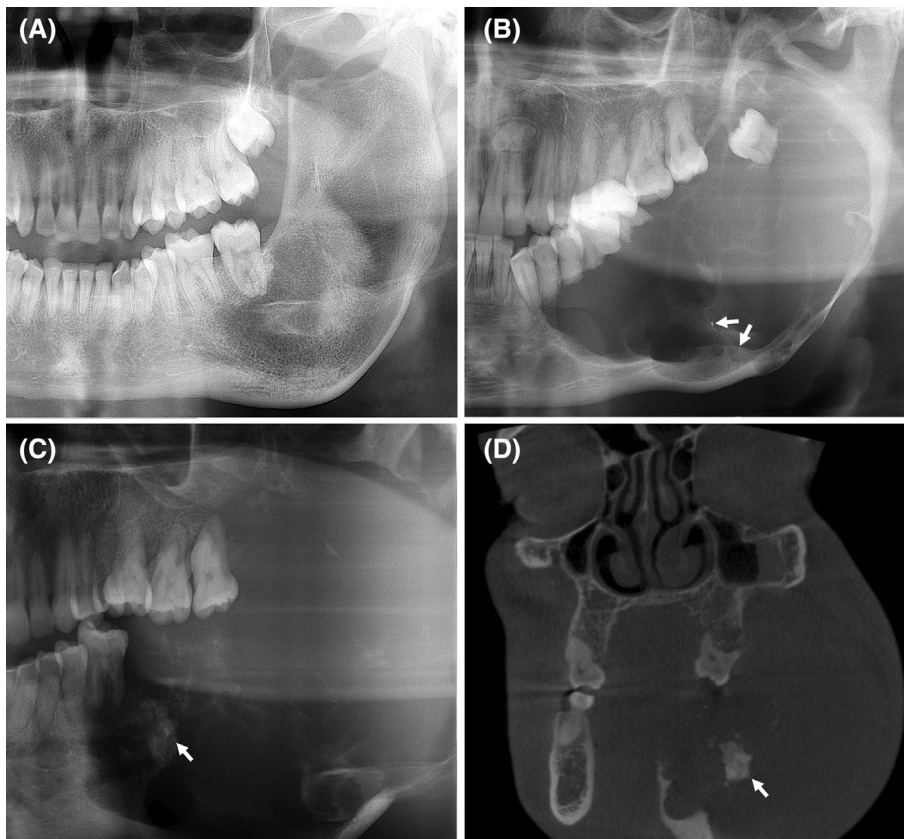
differences in age of presentation have been reported in ABs, with developing countries presenting at a younger mean age compared to developed countries.<sup>11,18</sup> A peak incidence in the third decade was noted for African and South American patients, compared to a peak in the fifth and sixth decades for a North American and European population.<sup>8,17</sup> The cause of these varying demographic figures has been speculated to be related to different aetiological agents or poor nutrition.<sup>8</sup>

ABs have varying sex predilections in different population groups, with no outright strong sex predominance.<sup>1,7,10</sup> However, a slight male predominance was noted in an African population.<sup>8,19</sup> There is no statistically significant difference between sex and mean age of

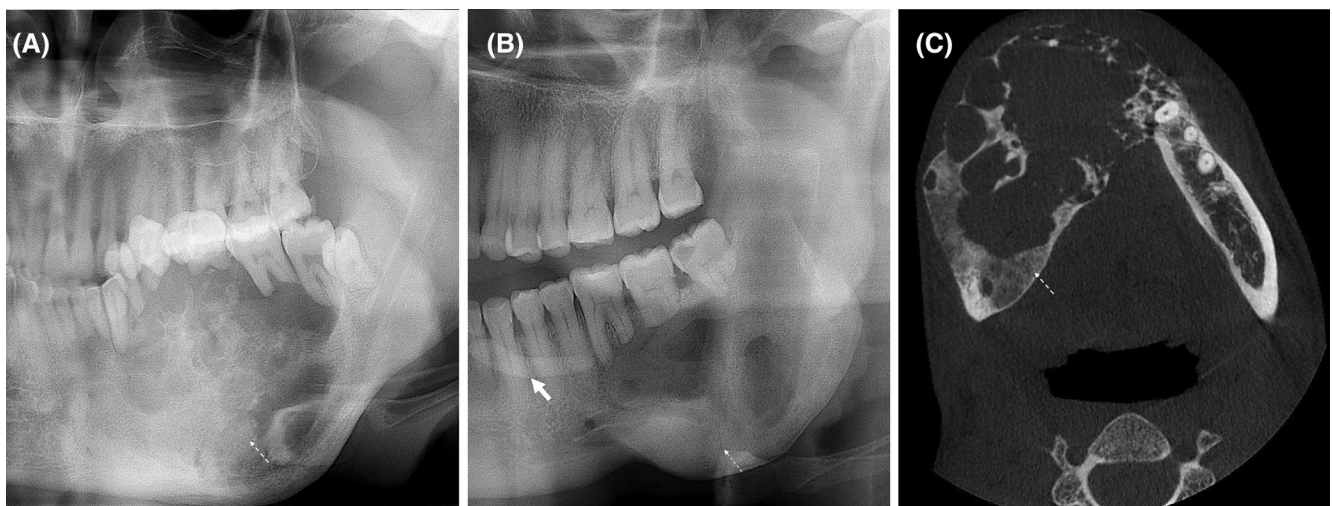
presentation.<sup>20</sup> An earlier mean age of presentation has been reported in both males and females.<sup>11,13</sup> In the current study, females presented at a slightly older mean age, but with a shorter mean duration, implying they sought healthcare earlier.

ABs were most common among the black population, a finding also noted globally, with a ratio of 9:1 compared to their white counterparts.<sup>9,11,21</sup> Reasons might include environmental factors or skewed results due to harvesting bias.<sup>5,9</sup> In the current study, this might be due to the population group distribution in South Africa. Additionally, global reports indicate that black patients presented with ABs at a much younger age compared to other population groups.<sup>7,11,13,22</sup>





**FIGURE 2** (A) Ameloblastoma with a fibro-osseous-like or mixed-density appearance involving the left mandibular corpus and ramus-complex. (B) AB with fine specks of internal calcifications (arrows) and a coincidental finding of a compound odontoma apical of the left maxillary incisors. (C) Cropped PR and (D) coronal CBCT image showing an AB with a larger conglomerate of internal calcifications (arrows). AB, ameloblastoma; CBCT, cone-beam computerised tomography; PR, panoramic.

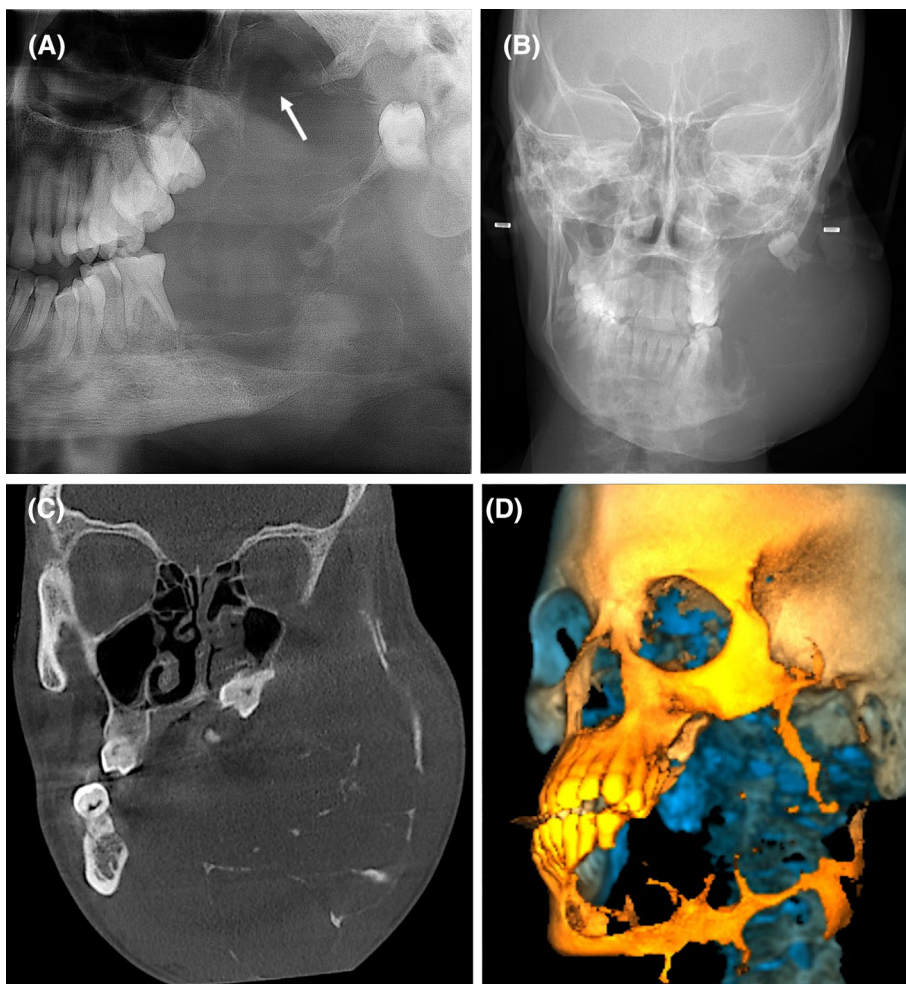


**FIGURE 3** (A, B) Cropped PRs and (C) axial CBCT image of ABs with radiologic signs of associated reactive bony changes (stippled arrows), presenting as surrounding bony sclerosis. Figure (B) has a coincidental finding of a sialolith (solid arrow). AB, ameloblastoma; CBCT, cone-beam computerised tomography; PR, panoramic.

The mean clinical duration of ABs before initial patient presentation has been reported at 27 months (range 9–38 months).<sup>11</sup> Younger patients and patients with associated pain typically present earlier,<sup>5,7</sup> but these findings were not replicated in the current study. In an African setting, only 23% of patients presented within the first year of noting the lesion due to difficulty accessing specialised healthcare

services in developing countries.<sup>22,23</sup> In the current study, 57% of patients presented within 12 months of noticing the lesion. Swelling is the most common presenting symptom, followed by pain, fistula formation and tooth mobility.<sup>7,15</sup> In another African study, the frequency of swelling, tooth mobility, purulent discharge and paraesthesia was higher than in other global studies.<sup>13</sup>

**FIGURE 4** Mandibular cases of AB that extent to involve the maxilla. (A, B) PR and skull radiograph of a large AB affecting the left posterior mandible, ramus, condylar and coronoid processes, with impingement of the zygomatic arch and maxilla (arrow). (C, D) Coronal CBCT image and reconstructed CBCT image of a mandibular AB causing displacement of maxillary teeth as well as the orbit and maxillary sinus. AB, ameloblastoma; CBCT, cone-beam computerised tomography; PR, panoramic.



ABs have a strong predilection for the mandible, particularly in an African demographic (94%)<sup>8,13,19</sup> and specifically the posterior region.<sup>1,10,12,20</sup> Several case reports have also described the involvement of the condylar and coronoid processes and ABs frequently crossing the midline.<sup>6,21</sup> When the maxilla is affected, the anterior region is the most commonly affected subsite,<sup>10,13</sup> in contrast to the current study. Due to the aggressive growth of these neoplasms, many cases often involve multiple regions.<sup>14,21</sup> A Hong Kong Chinese study including 61 cases of AB found that mandibular cases in individuals younger than 25 years generally had a predilection for the posterior regions of the jaws, whereas patients older than 25 years had an anterior predilection. These findings have not been reported in other published literature and were not seen in the current study.<sup>7</sup> Maxillary ABs are commonly reported in men,<sup>24</sup> contrasting the current study, where no statistical differences between the site and sex distribution of ABs were seen.

Literature tends to be limited in reporting the radiologic features of ABs, apart from basic descriptive features such as tumour density or shape, emphasising the importance of the current study. MacDonald-Jankowski et al.<sup>14</sup> performed a descriptive analysis of the AB cases within their population group. Generally, well-demarcated margins are seen in 96% of cases, with only a minority having poorly

demarcated margins.<sup>14,20</sup> In the current study, loss of border demarcation correlated with more advanced age. The longer the lesion is left untreated, the more cortical destruction will occur, leading to a loss of demarcation on conventional radiographs. Li et al.<sup>25</sup> found that ABs with poorly demarcated margins were usually associated with poorer prognostic outcomes as a cortical margin could act as a barrier to tumour invasion, favouring the overall prognosis.<sup>25</sup>

Most ABs (97%) appear completely radiolucent, with others presenting with central opacities or calcifications.<sup>14</sup> A rare mixed-density appearance has been reported in approximately 4% of ABs,<sup>6</sup> possibly due to desmoplastic stroma<sup>26</sup> or dystrophic calcifications.<sup>27</sup> Higher rates of mixed-density radiologic appearances have been previously reported in this population group.<sup>21</sup> In the current study, the histopathologic slides of cases exhibiting calcifications or mixed lesions were reanalysed, with several cases showing stromal fibrosis, dystrophic calcifications, or reactive bone, likely a result of secondary infection. This could be further explained by long-standing lesions, as noted by the advanced mean age and lesion duration seen in these cases.

The frequency of uni- and multilocular lesions differs between different population groups and depends on the relative frequency of unicystic or conventional histopathologic subtypes in that

population.<sup>20</sup> Many reports indicate that the distribution between uni- and multilocular lesions are roughly equal,<sup>6,11</sup> whilst others report a higher prevalence of multilocular lesions.<sup>13,14,17</sup> Unilocular lesions have been reported in higher frequencies than multilocular lesions in children.<sup>21,28</sup> This is likely due to unicystic ABs being more common in children, which was also a factor in the current study. The higher frequency of multilocular lesions in adults could be a factor of time, supported by the increased mean age and duration seen in multilocular cases. The progression of cases from unilocular to multilocular lesions has been reported in the literature.<sup>29,30</sup> This might be explained by the cystic degradation of tumour islands being initially too small to detect on imaging.

Bony expansion occurs more commonly in a buccolingual (91%) dimension than in a superior–inferior (42%) dimension.<sup>14</sup> This phenomenon can be explained by the general resistance to expansion by the thick inferior mandibular cortex. Cortical destruction and soft tissue involvement are also common findings,<sup>14,15,31</sup> pointing to the aggressive behaviour of the tumour. Cortical perforation was noted in 77% of ABs, including smaller lesions, reaffirming the overall local aggressiveness of the tumour rather than a result of the size of the lesion.<sup>31</sup> Cortical destruction was significantly more common in adults, likely due to a higher prevalence of conventional ABs in this age group or a longer clinical duration. In the current study, reactive bony changes were seen radiologically as peripheral sclerosis, possibly due to secondary infection or a bony reaction to infiltration of neoplastic cells. This effect was also more common in adults, again a factor of longer duration or possibly higher rates of secondary infection. Further studies on this reactive bony pattern should be conducted to better understand this process.

Root resorption and tooth displacement are common radiologic signs in ABs,<sup>20</sup> with tooth impaction noted in roughly 10% of cases,<sup>6</sup> often involving third molars.<sup>11,14</sup> In the current study, tooth displacement was more common in children, whereas loss of teeth associated with the lesion was more common in adults. These findings also correlated with the mean ages of presentation and duration of these entities. Tooth impactions are statistically more common in children under the age of 18 years.<sup>14,28</sup> This is an expected finding related to the timing of dental development and tooth eruption, supported by the lowest mean age of this effect on the surrounding teeth in the current study. The teeth commonly impacted in adults versus children also correlate with the age of tooth development and eruption.

Impingement of the maxillary sinus has been documented in approximately 75% of all maxillary AB cases,<sup>31</sup> with cases often extending to the nasal cavity.<sup>11</sup> The extent of the lesions in the current sample surpassed the effects of surrounding tissues reported in the literature. This finding was also noted in a previous African study in 1975,<sup>23</sup> showing that no significant improvements have been made concerning the speed of treatment. Maxillary ABs tend to be more aggressive than mandibular cases due to the easier invasion of the porous trabeculae in the maxilla.<sup>24</sup> Extension to the cranial vault is rare, with one case in the current sample. This results from limited access to healthcare services in developing countries, with many lesions reaching a considerable size before treatment is sought or initiated.<sup>30</sup>

Limitations of the current study were that most baseline radiographic evaluations are performed using PR as this imaging modality is widely available and cost-effective.<sup>14,20</sup> Although it produces an image with a good overview of the jaws and the surrounding structures, PR has disadvantages associated with two-dimensional (2D) imaging, including the superimposition of structures. CBCT imaging overcomes these limitations. As CBCT imaging becomes more widely available in developing countries, a detailed three-dimensional analysis will better assist treatment planning. Another limitation is that due to the study's retrospective nature, the clinical information depends on clinicians' record-keeping.

## 5 | CONCLUSION

This study aimed to assess the detailed radiologic features of ABs in a South African population. Due to the constraints around access to healthcare services, ABs in this sample tend to grow to significant sizes, often exhibiting features rarely reported in the literature. The findings of the current analysis eluded to changes in border demarcation and locularity, as well as effects on the surrounding bony structures and teeth, which were a factor of time expressed through the mean age and duration of the lesion. This highlights the importance of timeously managing these lesions to reduce overall patient morbidity following surgical intervention.

### AUTHOR CONTRIBUTIONS

**Chané Smit:** Conceptualisation; data curation; formal analysis; investigation; methodology; writing—original draft; writing—review and editing. **Liam Robinson:** Data curation; formal analysis; investigation; methodology; writing—original draft; writing—review and editing. **Jason Ker-Fox:** Formal analysis; investigation; methodology; writing—original draft; writing—review and editing. **Felipe Paiva Fonseca:** Formal analysis; investigation; project administration; supervision; writing—original draft; writing—review and editing. **Willie F. P. van Heerden:** Formal analysis; investigation; project administration; supervision; writing—original draft; writing—review and editing. **André Uys:** Formal analysis; investigation; project administration; supervision; writing—original draft; writing—review and editing.

### CONFLICT OF INTEREST STATEMENT

The authors declare no conflicts of interest.

### PEER REVIEW

The peer review history for this article is available at <https://www.webofscience.com/api/gateway/wos/peer-review/10.1111/jop.13510>.

### DATA AVAILABILITY STATEMENT

The data of the current study are summarised in the tables and supplementary tables. Access to raw data is subject to approval by the University of Pretoria, Faculty of Health Sciences Research Ethics Committee.



## ETHICS STATEMENT

This study was approved by the University of Pretoria, Faculty of Health Sciences Research Ethics Committee (Reference no. 723/2022). All procedures followed the ethical standards of the Helsinki Declaration of 1975, as revised in 2008. This article does not contain any studies with human or animal subjects performed by any of the authors.

## ORCID

Chané Smit  <https://orcid.org/0000-0003-4047-6356>

Liam Robinson  <https://orcid.org/0000-0002-0549-7824>

Jason Ker-Fox  <https://orcid.org/0000-0002-4660-7612>

Felipe Paiva Fonseca  <https://orcid.org/0000-0002-6657-4547>

Willie F. P. van Heerden  <https://orcid.org/0000-0003-2494-667X>

André Uys  <https://orcid.org/0000-0001-8250-7662>

## REFERENCES

- Vered M, Muller S, Heikinheimo K. Ameloblastoma. In: El-Naggar AK, Chan JKC, Grandis JR, Takata T, Slootweg PJ, eds. *WHO Classification of Head and Neck Tumours*. 4th ed. International Agency for Research on Cancer (IARC); 2017:215-218.
- Gomes CC, Duarte AP, Diniz MG, Gomez RS. Current concepts of ameloblastoma pathogenesis. *J Oral Pathol Med*. 2010;39(8):585-591.
- Gültekin SE, Aziz R, Heydt C, et al. The landscape of genetic alterations in ameloblastomas relates to clinical features. *Virchows Arch*. 2018;472(5):807-814.
- Effiom OA, Ogundana OM, Akinshipo AO, Akintoye SO. Ameloblastoma: current etiopathological concepts and management. *Oral Dis*. 2018;24(3):307-316.
- Oginni FO, Stoelinga PJW, Ajike SA, et al. A prospective epidemiological study on odontogenic tumours in a black African population, with emphasis on the relative frequency of ameloblastoma. *Int J Oral Maxillofac Surg*. 2015;44(9):1099-1105.
- Dhanuthai K, Chantarangsu S, Rojanawatsirivej S, et al. Ameloblastoma: a multicentric study. *Oral Surg Oral Med Oral Pathol Oral Radiol*. 2012;113(6):782-788.
- MacDonald-Jankowski D, Yeung R, Lee K, Li T. Ameloblastoma in the Hong Kong Chinese. Part 1: systematic review and clinical presentation. *Dentomaxillofac Radiol*. 2004;33(2):71-82.
- Hendra FN, Van Cann EM, Helder MN, et al. Global incidence and profile of ameloblastoma: a systematic review and meta-analysis. *Oral Dis*. 2020;26(1):12-21.
- Shear M, Singh S. Age-standardized incidence rates of ameloblastoma and dentigerous cyst on the Witwatersrand, South Africa. *Community Dent Oral Epidemiol*. 1978;6(4):195-199.
- Waldron CA, El-Mofty SK. A histopathologic study of 116 ameloblastomas with special reference to the desmoplastic variant. *Oral Surg Oral Med Oral Pathol*. 1987;63(4):441-451.
- Reichart PA, Philipsen HP, Sonner S. Ameloblastoma: biological profile of 3677 cases. *Eur J Cancer Part B Oral Oncol*. 1995;31(2):86-99.
- Kim S-G, Jang H-S. Ameloblastoma: a clinical, radiographic, and histopathologic analysis of 71 cases. *Oral Surg Oral Med Oral Pathol Oral Radiol Endod*. 2001;91(6):649-653.
- Adeline VL, Dimba EAO, Wakoli KA, et al. Clinicopathologic features of Ameloblastoma in Kenya. *J Craniofac Surg*. 2008;19(6):1589-1593.
- MacDonald-Jankowski D, Yeung R, Lee K, Li T. Ameloblastoma in the Hong Kong Chinese. Part 2: systematic review and radiological presentation. *Dentomaxillofac Radiol*. 2004;33(3):141-151.
- Laborde A, Nicot R, Wojcik T, Ferri J, Raoul G. Ameloblastoma of the jaws: management and recurrence rate. *Eur Ann Otorhinolaryngol Head Neck Dis*. 2017;134(1):7-11.
- Ueno S, Mushimoto K, Shirasu R. Prognostic evaluation of ameloblastoma based on histologic and radiographic typing. *J Oral Maxillofac Surg*. 1989;47(1):11-15.
- Boffano P, Cavarra F, Tricarico G, et al. The epidemiology and management of ameloblastomas: a European multicenter study. *J Cranio-Maxillofac Surg*. 2021;49(12):1107-1112.
- Ong'uti MN, Cruchley AT, Howells GL, Williams DM. Ki-67 antigen in ameloblastomas: correlation with clinical and histological parameters in 54 cases from Kenya. *Int J Oral Maxillofac Surg*. 1997;26(5):376-379.
- Chidzonga MM, Lopez Perez VM, Portilla Alvarez AL. Ameloblastoma. *Oral Surg Oral Med Oral Pathol Oral Radiol Endod*. 1996;82(1):38-41.
- Filizola A, Bartholomeu-dos-Santos T, Pires F. Ameloblastomas: Clinicopathological features from 70 cases diagnosed in a single Oral Pathology service in an 8-year period. *Med Oral Patol Oral Cir Bucal*. 2014;19(6):e556-e561.
- Ranchod S, Titinchi F, Behardien N, Morkel J. Ameloblastoma of the mandible: analysis of radiographic and histopathological features. *J Oral Med Oral Surg*. 2021;27(1):6.
- Soyele OO, Akinshipo AO, Effiom OA, et al. A multi-centre evaluation of 566 cases of ameloblastoma in Nigeria by the African Oral Pathology Research Consortium. *Oral Cancer*. 2019;3(1-2):9-15.
- Lagundoye SB, Akinosi JO, Obisesan AA, Oluwasanmi JO. Radiologic features of ameloblastoma in Nigerians. *Oral Surg Oral Med Oral Pathol*. 1975;39(6):967-975.
- Pitak-Arnop P, Subbalekha K, Sirintawat N, et al. A retrospective cohort study on predictors associated with skull base invasion of maxillary ameloblastomas. *J Stomatol Oral Maxillofac Surg*. 2022;123(5):e439-e447.
- Li Y, Han B, Li L-J. Prognostic and proliferative evaluation of ameloblastoma based on radiographic boundary. *Int J Oral Sci*. 2012;4(1):30-33.
- Wakoh M, Harada T, Inoue T. Follicular/desmoplastic hybrid ameloblastoma with radiographic features of concomitant fibro-osseous and solitary cystic lesions. *Oral Surg Oral Med Oral Pathol Oral Radiol Endod*. 2002;94(6):774-780.
- Kang BC, Lee JS, Yoon SJ, Kim Y. Ameloblastoma with dystrophic calcification: a case report with 3-dimensional cone-beam computed tomographic images of calcification. *Imaging Sci Dent*. 2020;50(4):373-376.
- Krishnapillai R, Angadi PV. A clinical, radiographic, and histologic review of 73 cases of ameloblastoma in an Indian population. *Quintessence Int*. 2010;41(5):e90-e100.
- Mariz B, Andrade B, Agostini M, et al. Radiographic estimation of the growth rate of initially underdiagnosed ameloblastomas. *Med Oral Patol Oral Cir Bucal*. 2019;24(4):e468-e472.
- Merbold L, Smit C, Ker-Fox J, Uys A. The radiologic progression of ameloblastomas. South African. *J Radiol*. 2023;27(1):2668.
- Apajalahti S, Kelppe J, Kontio R, Hagström J. Imaging characteristics of ameloblastomas and diagnostic value of computed tomography and magnetic resonance imaging in a series of 26 patients. *Oral Surg Oral Med Oral Pathol Oral Radiol*. 2015;120(2):118-130.

## SUPPORTING INFORMATION

Additional supporting information can be found online in the Supporting Information section at the end of this article.

**How to cite this article:** Smit C, Robinson L, Ker-Fox J, Fonseca FP, van Heerden WFP, Uys A. Clinicoradiologic features of ameloblastomas: A single-centre study of 155 cases. *J Oral Pathol Med*. 2024;53(2):133-141. doi:10.1111/jop.13510