

## CASE REPORT

# Apexification of dens evaginatus in a mandibular premolar: A case report

Peet J. van der Vyver  | Martin Vorster  | Glynn Dale Buchanan 

Department of Odontology, School of Dentistry, Faculty of Health Sciences, University of Pretoria, Pretoria, South Africa

**Correspondence**

Glynn Dale Buchanan, Department of Odontology, Room 4-12, University of Pretoria Oral Health Centre, 31 Bophelo Road, Prinslof Campus, Riviera, Pretoria 0002, South Africa.  
Email: [glynn.buchanan@up.ac.za](mailto:glynn.buchanan@up.ac.za)

**Key Clinical Message**

Dens evaginatus is an uncommon dental anomaly presenting on mandibular premolar teeth. Affected teeth are difficult to diagnose and manage, and often demonstrate immature apices requiring complex endodontic treatment approaches.

**Abstract**

Dens evaginatus (DE) is an uncommon anomaly affecting mandibular premolars, frequently requiring endodontic intervention. This report documents the treatment of an immature mandibular premolar presenting with DE. Early diagnosis and preventive strategies remain the preferred management for these anomalies, however endodontic approaches may be successfully applied to retain these teeth.

**KEYWORDS**

dens evaginatus, dentistry, endodontics, mandibular premolar

## 1 | INTRODUCTION

Dens evaginatus (DE) is an uncommon dental anomaly that is characterized by the formation of an accessory cusp which may present on either the anterior and posterior teeth.<sup>1</sup> The condition was first described by Mitchell in 1892<sup>2</sup> and has been well documented from 1925.<sup>3</sup> In posterior teeth, this anomaly is typically found on the occlusal surface, with mandibular premolar teeth commonly involved.<sup>4,5</sup> In DE, additional tooth material is found, presenting as a tubercle, cusp, extrusion, or bulge extending beyond the adjacent tooth structure, consisting of a dentinal core covered by a thin layer of enamel. The tubercle often contains pulp tissue which may project at various lengths along the dentinal core.<sup>6</sup>

These cusp-like projections found in teeth affected by DE carry important clinical significance, especially in endodontics. Fracture or wear of the tubercles due to malocclusion or trauma may lead to pulpal exposure, infection, and necrosis shortly following tooth eruption,

often requiring endodontic intervention.<sup>1</sup> Caries is usually not a predisposing factor for pulpal involvement in these cases.<sup>7</sup> Additionally, teeth with DE often present with immature roots and open apices, necessitating the need for the provision of an apical barrier, increasing the complexity of the endodontic management.<sup>1</sup> Treatment for this condition may vary from early recognition and preventive measures to conventional endodontic approaches such as root canal treatment, with or without apexification, and/or regenerative endodontics,<sup>8</sup> depending on the severity of pulpal involvement and level of root development.<sup>1</sup>

The following report details the diagnosis and management of a mandibular second premolar in a female patient that presented with DE, pulpal necrosis and an immature apex. The case was successfully managed by endodontic treatment including MTA apexification. Ethical approval for this case report was obtained from the Research Ethics Committee of the Faculty of Health Sciences, University of Pretoria (protocol number:

This is an open access article under the terms of the [Creative Commons Attribution-NonCommercial](https://creativecommons.org/licenses/by-nc/4.0/) License, which permits use, distribution and reproduction in any medium, provided the original work is properly cited and is not used for commercial purposes.

© 2023 The Authors. *Clinical Case Reports* published by John Wiley & Sons Ltd.

368/2021). Written informed consent was obtained from the patient to publish this report in accordance with the journal's patient consent policy.

## 2 | CASE PRESENTATION

The patient, a 22-year-old female of Asian descent, presented to a private endodontic practice with symptoms of discomfort on her right mandibular second premolar of several weeks duration. Clinical examination revealed a small tubercle on the occlusal surface of the tooth and a draining sinus in the vestibule associated with the buccal root surface (Figure 1). Radiographic examination using periapical radiography revealed an open apex of the right mandibular second premolar with a large periapical lesion and associated buccal bone destruction. As no caries or restorations were present, a high-resolution CBCT scan (Carestream 8200, Carestream Dental) was furthermore acquired, which confirmed the periapical pathoses and revealed destruction of the buccal cortical bone plate (Figure 2). Given the history, clinical and radiographic features, the condition was diagnosed as DE with pulpal necrosis and immature apex. Several treatment options, including endodontic therapy with the creation of a root-end barrier (apexification), were discussed with the patient. Following discussion and the provision of informed consent, the patient elected to proceed with this approach.

Following the administration of local anesthesia and rubber dam isolation, a conservative access cavity was prepared extending from the tubercle into the pulp chamber. Length determination was completed using an electronic apex locator and size 40 K-File, which was also verified radiographically. The canal was instrumented beyond the determined working length until resistance was experienced apically, using a ProTaper Ultimate FXL manual instrument (Dentsply Sirona). Heated 3.5% sodium hypochlorite was activated during and after canal instrumentation using an Eddy Irrigating Tip (VDW) attached to

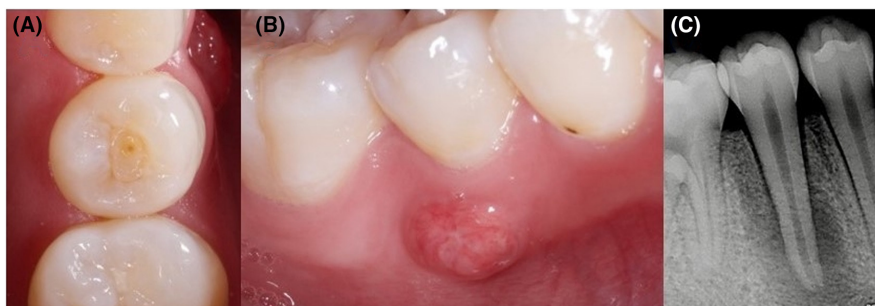an NSK Air scaler (NSK Dental). Calcium hydroxide was placed as an inter-appointment medicament for a period of 1 week and the access cavity sealed using Teflon tape and composite resin.

At the second visit, the acute symptoms has resided and the temporary restoration was removed. The canal was irrigated with sodium hypochlorite to remove the calcium hydroxide paste. A stainless steel endodontic plugger, attached to an electronic apex locator (and confirmed radiographically), was used to determine the position of the apex and the final position of the ProRoot MTA pack (Dentsply Sirona) (Figure 3). Incremental packing of the MTA was performed using a microapical placement system (MAP system, Dentsply Sirona) until a 5-mm apical barrier was achieved (Figure 4). The remainder of the canal was obturated using warm gutta percha (Gutta Smart system, Dentsply Sirona) in conjunction with bioceramic sealer (AH Plus Bioceramic sealer, Dentsply Sirona). The access cavity was air-polished using bicarbonate of soda (Aquacut, Velopex International) to remove remnants of root canal cement and/or gutta percha on the walls of the access cavity. The access cavity was finally restored using Prime and Bond Universal, SDR and Spectra ST (Dentsply Sirona) composite resin (Figure 5).

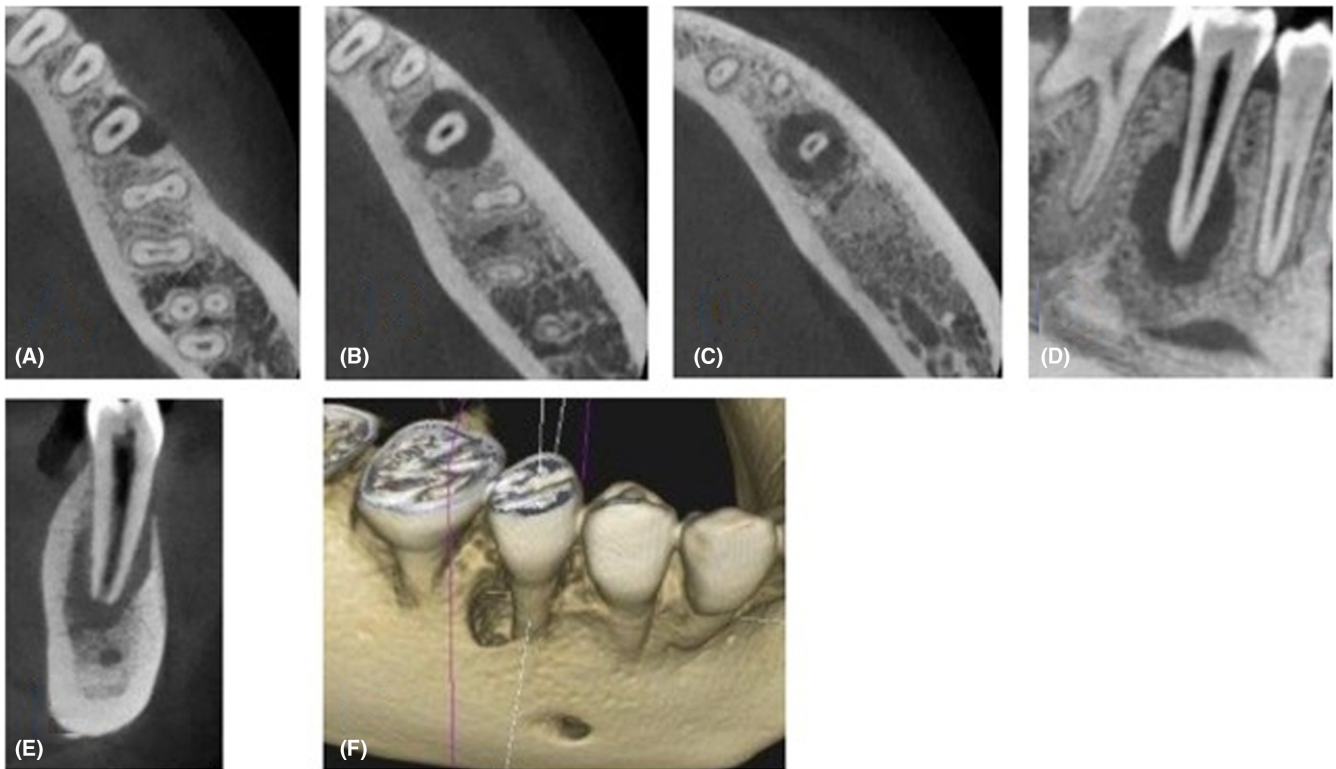
The 3- and 8-month follow-up periapical radiographs showed excellent resolution of the periapical lesion (Figure 6). Healing was further confirmed with high-resolution CBCT, acquired at the 1-year follow-up visit (Figure 6).

## 3 | DISCUSSION

Considered a relatively uncommon developmental anomaly, DE may pose a significant clinical challenge if not detected and managed early.<sup>1</sup> This is mainly due to the fact that associated teeth may become necrotic when root closure is still incomplete. Loss of vitality is mainly caused by direct injury to the extended portion of the pulp present in the center of the superficial tubercle. For this

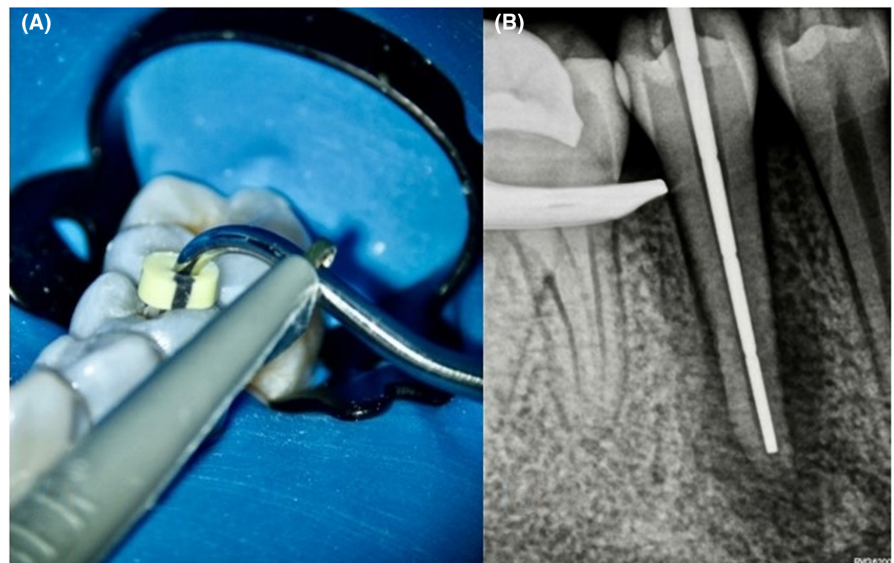


**FIGURE 1** (A) Pre-op intraoral photograph of mandibular right second premolar showing a small tubercle on the occlusal surface; (B) draining sinus in vestibule next to the affected premolar tooth; (C) periapical radiograph showing large periapical radiolucent lesion around the apex of the mandibular second premolar.



**FIGURE 2** (A) Axial view, coronal third of root; (B) axial view, middle third of root; (C) axial view, apical third of root; (D) sagittal view; (E) coronal view; (F) 3D reconstructed view of the CBCT scan showing the extent of the destruction of the buccal bone plate.

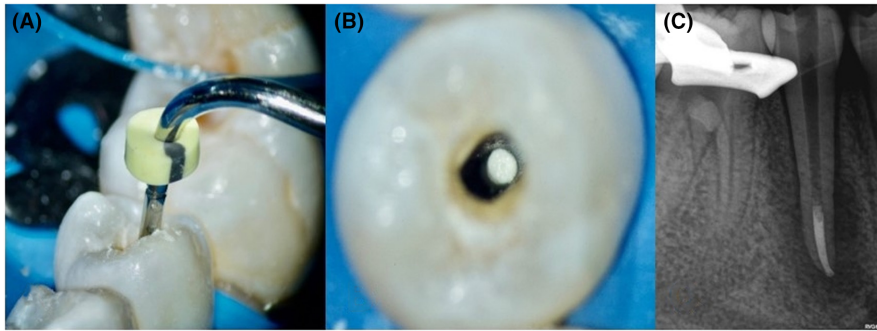
**FIGURE 3** (A) A stainless steel endodontic plugger attached to an electronic apex locator was used to confirm the position of the open apex and the final position of the MTA material; (B) the position was confirmed radiographically.



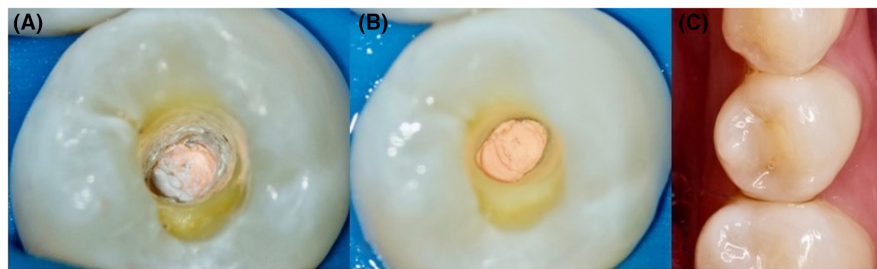
reason, prophylactic treatment by means of a preventative restoration is recommended directly following eruption of these teeth into the oral cavity, to eliminate the chance of pulpal exposure and subsequent necrosis.<sup>9</sup>

DE has been described in several population groups, but predominantly affects individuals of Asian descent as opposed to Europeans.<sup>8,10</sup> In Asian populations, the overall prevalence of the anomaly has been estimated to range between 0.5%–4.3%.<sup>10</sup> The highest prevalences of DE (of up to

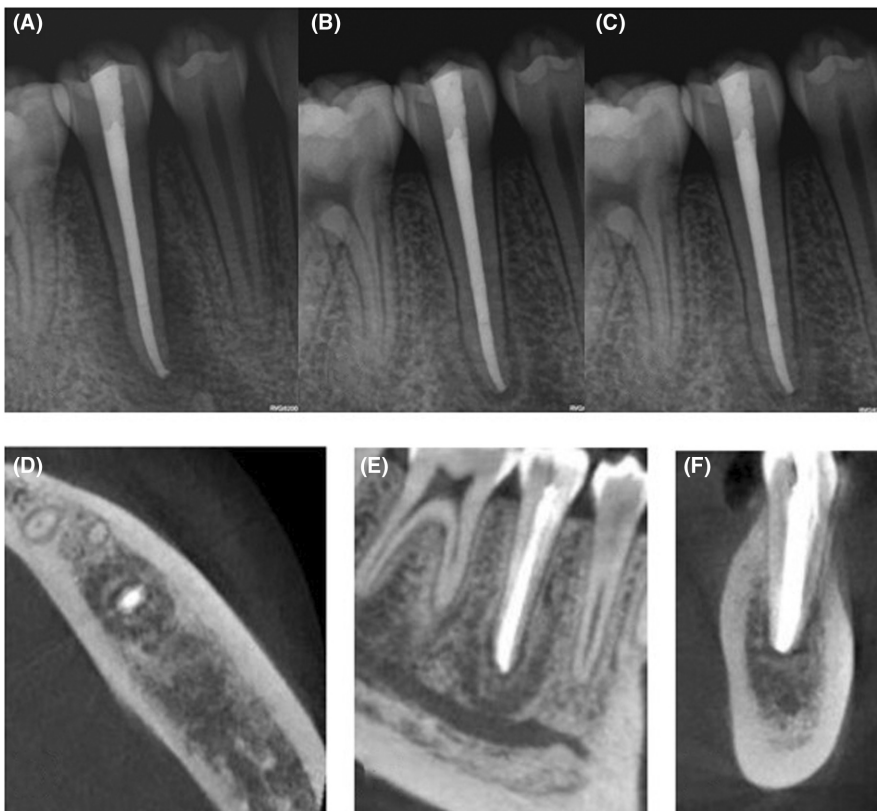
15%) were reported in Eskimo and North American Indian populations respectively.<sup>11,12</sup> The condition has been less commonly described in White individuals and rarely in Black individuals,<sup>13–15</sup> although the anomaly is becoming more frequently observed in Western countries due to migration.<sup>8</sup> Both genetic inheritance<sup>12,14</sup> as well as localized causes, such as trauma to the developing tooth bud,<sup>16</sup> have been suggested to cause DE; however, the exact etiology remains undetermined and may be multifactorial.<sup>10,16</sup>



**FIGURE 4** (A) ProRoot MTA condensed with a stainless steel plugger to the predetermined length; (B) magnified view from occlusal showing a cylindrical plug of ProRoot MTA; (C) final 5-mm apical plug of ProRoot MTA was confirmed radiographically.



**FIGURE 5** (A) Magnified view of the access cavity after obturation showing excess cement and gutta-percha; (B) magnified view of the access cavity after air-polishing using bicarbonate of soda leaving clean walls for restoration of the access cavity; (C) final composite restoration.



**FIGURE 6** (A) Final obturation result; (B) three-month follow-up radiograph showing a reduction in the periapical pathology; (C) eight-month follow-up radiograph showing excellent healing of the peri-apical lesion. The one-year follow up CBCT scan with (D) axial view; (E) sagittal view; (F) coronal view, showing healing of the periapical lesion and buccal bone plate.

The distribution of DE is frequently bilateral and symmetrical, with a slight female predilection.<sup>11</sup> In the anterior dentition, DE may be found on the palatal or lingual tooth surfaces and in these instances are referred to as talon cusps.<sup>16</sup> While both primary and permanent teeth

may present with DE, the permanent dentition is reportedly more commonly affected.<sup>6,7</sup>

Treatment options for DE vary depending on the extent of root maturity and pulpal involvement at the time of diagnosis, and are mainly based on previous case reports.<sup>8</sup>

Treatment options may include: tubercle preservation, gradual tubercle reduction, vital pulp therapy, apexification, root canal filling and regenerative endodontics.<sup>8</sup> In 2006, Levitan and Himel proposed a comprehensive regimen for the management of DE cases, which varied from preventive measures only for simpler cases, to more advanced endodontic approaches given classification of the anomaly's extent using their system.<sup>1</sup> The classification is as follows:

- Type I: normal pulp, mature apex;
- Type II: normal pulp, immature apex;
- Type III: inflamed pulp, mature apex;
- Type IV: inflamed pulp, immature apex;
- Type V: necrotic pulp, mature apex;
- Type VI: necrotic pulp, immature apex.

In the present study, the involved mandibular second premolar was classified as type VI (necrotic pulp with immature apex), and required apexification in order to form a root-end barrier and good apical seal.<sup>1</sup> The contralateral (left) mandibular second premolar of the same patient was previously treated in a similar way, and had also demonstrated clinical success with an MTA apexification approach.<sup>17</sup> In modern times, treatment options for DE with immature apices and thin roots have been further expanded to include regenerative endodontics.<sup>8</sup> Apexification of the mandibular second premolar in the present case was the treatment option of choice over regenerative endodontics, as the existing root thickness was considered adequate for success despite the open apex.

While preservation of natural teeth remains the preferred treatment modality, especially in light of modern endodontic techniques, it has been suggested that extraction of type VI DE teeth may be considered an alternative treatment option, due to the uncertain outcome of many these cases.<sup>1</sup> While treatment should always be tailored to the individual, and considered in light of the overall treatment plan for any given patient, the present case demonstrates that even challenging DE cases, including those with necrotic pulps and open apices, can be successfully managed by endodontic approaches instead of extraction.

In conclusion, this report documents the successful endodontic management of a mandibular second premolar affected by DE, presenting with a necrotic pulp and immature apex, via apexification. Whilst early detection and conservative management of this condition remains the ideal treatment approach, when necessary, endodontic treatment such as MTA apexification may be successfully applied to retain teeth affected by this relatively uncommon developmental anomaly.

All authors have equally contributed to the conception, writing, and editing of this manuscript (PJV, MV, and GDB 33.3% each). All authors are in agreement with the final version of the manuscript.

## AUTHOR CONTRIBUTIONS

**Peet J. van der Vyver:** Conceptualization; data curation; writing – review and editing. **Martin Vorster:** Conceptualization; writing – original draft; writing – review and editing. **Glynn Dale Buchanan:** Project administration; writing – original draft; writing – review and editing.

## FUNDING INFORMATION

This research did not receive any specific grant from funding agencies in the public, commercial, or not-for-profit sectors.

## CONFLICT OF INTEREST STATEMENT

The authors have no conflict of interest to disclose.

## DATA AVAILABILITY STATEMENT

Data available on request from the authors.

## ETHICS STATEMENT

Ethical approval and patient consent was obtained for this manuscript.

## CONSENT

Written informed consent was obtained from the patient to publish this report in accordance with the journal's patient consent policy.

## ORCID

Peet J. van der Vyver  <https://orcid.org/0000-0003-1951-6042>

[org/0000-0003-1951-6042](https://orcid.org/0000-0003-1951-6042)

Martin Vorster  <https://orcid.org/0000-0003-4470-1530>

Glynn Dale Buchanan  <https://orcid.org/0000-0003-2957-166X>

[org/0000-0003-2957-166X](https://orcid.org/0000-0003-2957-166X)

## REFERENCES

1. Levitan M, Himel V. Dens evaginatus: literature review, pathophysiology, and comprehensive treatment regimen. *J Endod.* 2006;32(1):1-9.
2. Mitchell W. Death. *Case Rep Dent Cosm.* 1892;34:1036-14000.
3. Leigh R. Dental pathology of the Eskimo. *Dent Cosm.* 1925;67:884-898.
4. Oehlers F. Dens evaginatus (evaginated odontome). Its structure and responses to external stimuli. *Dent Pr Dent Rec.* 1967;17:239-244.
5. Hill F, Bellis W. Dens evaginatus and its management. *Br Dent J.* 1984;156(11):400-402.
6. Neville B, Damm D, Allen C, Chi A. *Oral and Maxillofacial Pathology.* Elsevier; 2016.

7. Stecker S, Diangelus A. Dens evaginatus: a diagnostic and treatment challenge. *J Am Dent Assoc.* 2002;133(2):190-193.
8. Chen J, Huang G, Bakland L. Dens evaginatus current treatment options. *J Am Dent Assoc.* 2020;151(5):358-367.
9. Chen R. Conservative management of dens evaginatus. *J Endod.* 1984;10(6):253-257.
10. Kocsis G, Marcsik A, Kókai E, Kocsis K. Supernumerary occlusal cusps on permanent human teeth. *Acta Biol Szeged.* 2002;46:71-82.
11. Merrill R. Occlusal anomalous tubercles on premolars of Alaskan Eskimos and Indians. *Oral Surg Oral Med Oral Pathol.* 1964;17(4):484-496.
12. Curzon M, Curzon J, Poyton H. Evaginated odontomes in the Keewatin Eskimo. *Br Dent J.* 1970;129(7):324-328.
13. Palmer M. Case reports of evaginated odontomes in Caucasians. *Oral Surg Oral Med Oral Pathol.* 1973;35(6):772-779.
14. Stewart R, Dixon G, Graber R. Dens evaginatus (tuberculated cusps): genetic and treatment considerations. *Oral Surg Oral Med Oral Pathol.* 1978;46(6):831-836.
15. Pearlman J, Curzon M. An evaginated odontoma in an American Negro: report of case. *J Am Dent Assoc.* 1977;95(3):570-572.
16. Davies P, Brook A. The presentation of talon cusp: diagnosis, clinical features, associations and possible aetiology. *Br Dent J.* 1985;160(3):84-88.
17. Van der Vyver PJ, Vorster M, Buchanan GD. Clinical application of a new rotary file system—part 2. *Int Dent—African Ed.* 2022;12(1):6-15.

**How to cite this article:** van der Vyver PJ, Vorster M, Buchanan GD. Apexification of dens evaginatus in a mandibular premolar: A case report. *Clin Case Rep.* 2023;11:e07316. doi:[10.1002/ccr3.7316](https://doi.org/10.1002/ccr3.7316)