

# **A case report of *Nocardia asiatica* constrictive pericarditis in a patient with Human Immunodeficiency Virus**

Rosemary Griessel<sup>1,2,#</sup>, Barend Mitton<sup>1,2</sup>, Roxanne Rule<sup>1,2</sup>, Mohamed Said<sup>1,2</sup>

<sup>1</sup> Department of Medical Microbiology, University of Pretoria, Pretoria, South Africa

<sup>2</sup> Department of Medical Microbiology, Tshwane Academic Division, National Health Laboratory Service, Pretoria, South Africa

# Corresponding author: Rosemary.Griessel@nhls.ac.za

## **Keywords**

Nocardiosis; Pericarditis; *Nocardia asiatica*; *Actinomycetes*

## **Abstract**

Nocardiosis commonly affects the respiratory system and is a rare cause of purulent pericarditis. Invasive nocardial infections occur more frequently in patients with immunosuppression. A misdiagnosis as tuberculosis infection is not uncommon, especially in the context of immunosuppression in high burden tuberculosis settings. The risk factors and clinical features of the two disease entities overlap substantially. Misdiagnosis may lead to a delay in appropriate treatment and may result in poor outcomes. It is important to note that these conditions may also co-exist in the same patient.

We describe, to the best of our knowledge, the first case of *Nocardia asiatica* pericarditis in a 32-year-old man with Human Immunodeficiency Virus infection. The patient was initially diagnosed in September 2020 with a lower respiratory tract infection and pulmonary tuberculosis was suspected. A chest radiograph, performed at admission, revealed a pericardial effusion and *N. asiatica* was cultured from a pericardial fluid specimen that was collected 5 days following admission. Despite a good initial clinical response to a combination of trimethoprim/sulfamethoxazole and imipenem/cilastatin, the patient demised after 16 weeks of treatment. Previous reports of laboratory confirmed nocardial pericarditis are also reviewed and summarized.

## **1. Introduction**

*Nocardia* species (spp.) are aerobic filamentous bacteria found in soil and water [1]. Human nocardial disease is usually an opportunistic infection in immunocompromised individuals [1]. The clinical suspicion of nocardiosis is often overshadowed by tuberculosis due to the similar clinical presentation and the high tuberculosis burden in certain settings [2]. The most common clinical presentation of nocardiosis is pulmonary nocardiosis. [2] Purulent pericarditis is a rare form of nocardiosis [2]. This report highlights the importance of having a high index of suspicion of nocardiosis when managing immunocompromised patients.

## **2. Case report**

In September 2020, a 32-year-old male patient was referred by a general practitioner to a tertiary academic hospital in Pretoria, South Africa, for a lower respiratory tract infection and suspected pulmonary tuberculosis (TB). The patient had no significant medical history and no history of substance use. He presented with a one-month history of dyspnoea, left sided chest pain, a productive cough, unintentional weight loss, drenching night sweats, poor appetite and fatigue. The cardiovascular examination revealed a raised jugular venous pressure (JVP), distended neck veins and a pericardial rub.

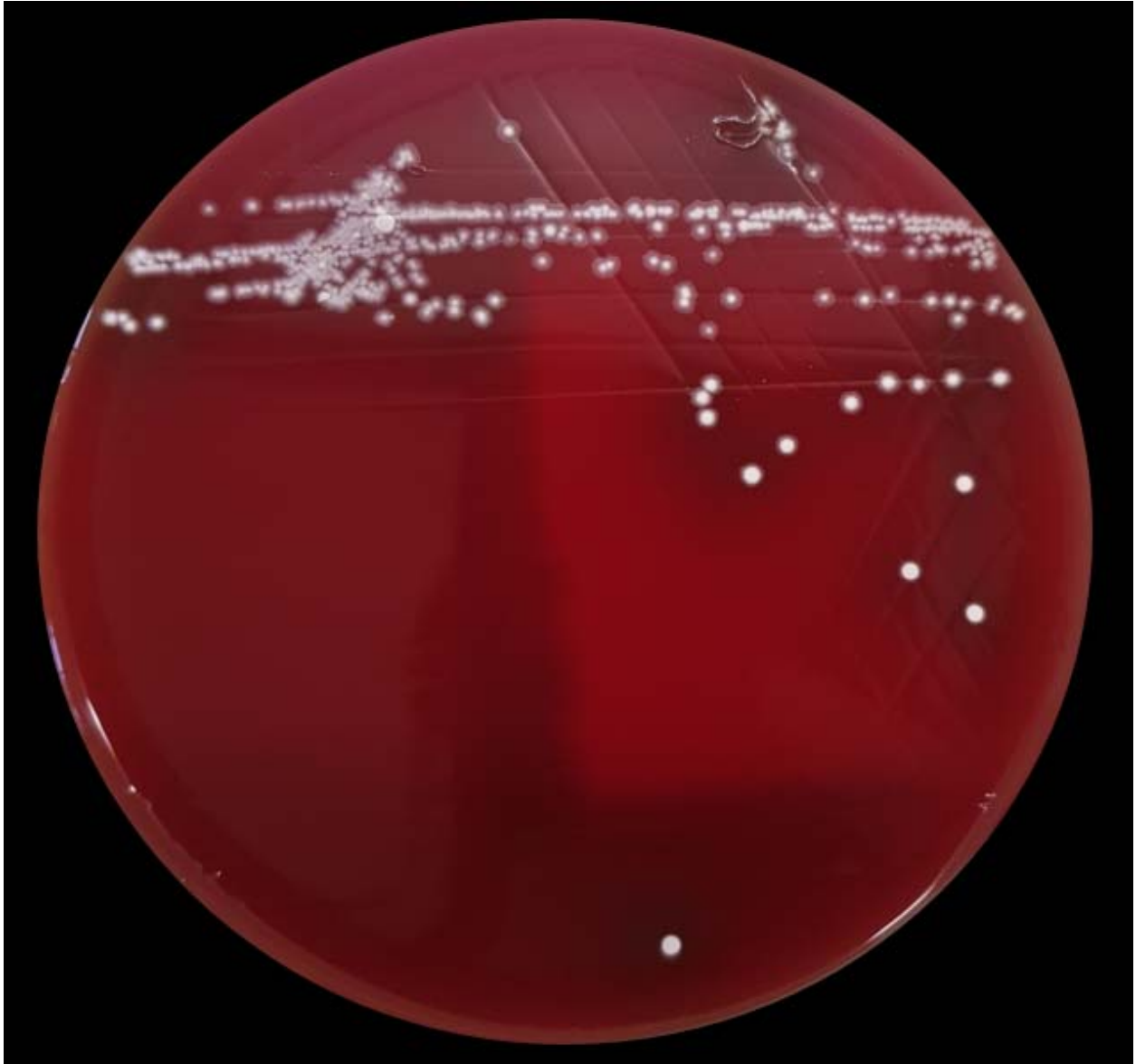
## **3. Results**

A chest radiograph revealed a left sided pleural effusion with an irregular outline and clear lung fields. An increased cardiothoracic index with a globular cardiac shadow suggested a pericardial effusion. Echocardiography confirmed a 10 mm pericardial effusion and a presumptive diagnosis of tuberculous pericarditis was made. An electrocardiogram (ECG) displayed a sinus tachycardia (143 bpm) with diffuse ST-segment elevation. Human immunodeficiency virus (HIV) serology was positive, the absolute CD4 count was 4 cells/ $\mu$ L and the CD4 percentage of lymphocytes were 0.54%, the CRP was 97 mg/L and the ESR was 109 mm/hr. Severe Acute Respiratory Syndrome Coronavirus 2 (SARS-CoV-2) Polymerase Chain Reaction (PCR) (Allplex™ 2019-nCoV Assay, Seegene Inc., Seoul, Republic of South Korea) done on a nasopharyngeal aspirate was negative. Normal respiratory flora was isolated from sputum samples. Subsequently, a sonar guided


pericardial drain was inserted. Pericardial fluid was sent for routine microscopy, culture and sensitivity (MC&S), TB MC&S, real time PCR for *M. tuberculosis* (Xpert MTB/Rif Ultra, Cepheid, Sunnyvale, CA, USA), cytology and adenosine deaminase (ADA). TB microscopy and 42-day TB culture was negative. The Xpert MTB/Rif Ultra did not detect *M. tuberculosis*. The ADA was >120IU/L. The cytology displayed acute inflammation and no malignant cells were observed. A urine lipoarabinomannan lateral flow assay (U-LAM, Determine™ TB-LAM Ag test, Alere, Waltham, MA, USA) was performed and was positive.

### **3.1. Diagnosis**

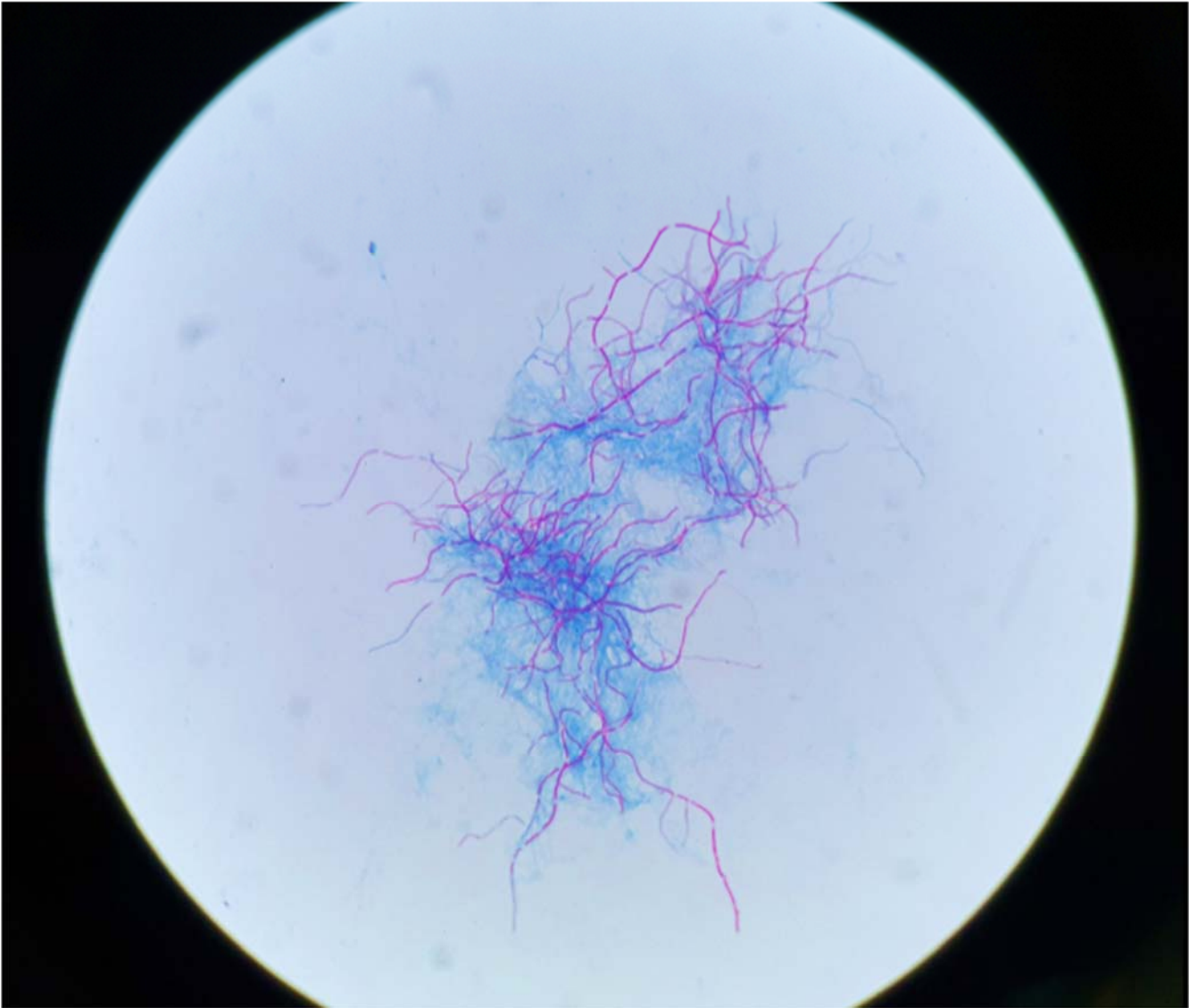
After a 2-day incubation period white chalky colonies with a characteristic “earthy” smell grew on blood agar and chocolate agar (Figure 1. and Figure 2). The Gram stain showed filamentous Gram-positive bacilli that were partially acid fast on a modified acid-fast stain (Figure 3.). This led to a presumptive diagnosis of *Nocardia* species. The organisms identity was confirmed by a referral laboratory employing 16S rRNA gene sequencing and *secA1* gene sequencing which identified the isolate as *Nocardia asiatica*. Susceptibility testing by broth microdilution was also performed by a second referral laboratory. The minimum inhibitory concentrations (MICs) values for trimethoprim-sulfamethoxazole was 0.5ug.mL and 2 µg/mL for imipenem. The MICs were interpreted as susceptible according the 2018 Clinical & Laboratory Standards Institute (CLSI) M62 document. Additional susceptible agents included amikacin, ceftriaxone and linezolid while amoxicillin/clavulanic acid and ciprofloxacin were resistant.



**Fig. 1.** Culture of pericardial fluid specimen on 5% sheep blood agar demonstrating white, chalky colonies of *Nocardia asiatica*.



**Fig. 2.** Culture of pericardial fluid specimen on chocolate agar after 48 hours of incubation at 35°C in ambient air showing characteristic white, chalky colonies of *Nocardia asiatica*.



**Fig. 3.** Kinyoun acid-fast stain of pericardial fluid specimen at 1000x magnification displaying acid-fast filamentous bacilli of *Nocardia asiatica*.

### **3.2. Treatment**

The patient was initiated on a combination of trimethoprim/sulfamethoxazole and imipenem/cilastatin. Anti-tuberculosis therapy, consisting of rifampicin, isoniazid, pyrazinamide and ethambutol, was continued.

### **3.3. Patient outcome**

The patient improved on therapy initially, but unfortunately the pericardial effusion and tamponade recurred. Despite reinsertion of a pericardial drain the patient demised after 16 weeks of treatment.

## **4. Discussion**

Nocardiosis is a rare cause of purulent pericarditis. Since nocardiosis is not a notifiable condition in most countries, the incidence of invasive nocardiosis is poorly described in literature. We searched the literature for the terms “nocardiosis” and “pericarditis” through PubMed for publications up to July 2021. We found 25 published cases of laboratory confirmed nocardial pericarditis (Table 1). The most common species identified in these cases was *Nocardia asteroides* (14, 56%). The mean age at presentation was 46 years and 18 (72%) patients were male. The mortality rate was 38% (9/24). This study reports, to the best of our knowledge, the first case of pericarditis caused by *Nocardia asiatica*. Presently, only a few cases of human infections caused by *N. asiatica* have been described. This could be due to more discriminatory identification methods used by the modern Microbiology laboratory. Invasive nocardial infections occur more frequently in patients with immunosuppression, including those with advanced human immunodeficiency virus (HIV) infection where the incidence of nocardiosis is reported to be between 0.2 and 1.8%.

**Table 1:** Previous reports of laboratory confirmed nocardial pericarditis.

No	Reference	Age (years)	Sex	Comorbid conditions	Clinical features	Specimen	Nocardia species	Treatment	Outcome
1	Maaz & Pollak, 1959, in Poland et al., 1990	38	F	Pregnancy	Chest pain	Pericardial fluid	<i>N. brasiliensis</i>	Penicillin, Streptomycin, Sulfisoxazole	Died
2	Smith et al., 1963, in Poland et al., 1990	57	M			Pericardium	<i>N. asteroides</i>	Tetracycline, Chloramphenicol, Penicillin, Erythromycin	Died
3	Susens et al., 1967, in Poland et al., 1990	56	M		Malaise, Anorexia, Fever, Pulsus paradoxus, Tachycardia	Pericardial fluid	<i>N. asteroides</i>		Died
4	Chavez et al., 1972, in Poland et al., 1990	47	M	Smoker	Dyspnoea, Chest pain, Cough, Fever, Tamponade	Pericardial fluid, Pericardium	<i>N. asteroides</i>	Sulfisoxazole, INH, PAS, Streptomycin	Survived
5	Geiseler et al., 1979, in Poland et al., 1990	43	M	Smoker, Alcohol abuse	Weight loss, Fever, Malaise	Pericardial fluid	<i>N. asteroides</i>	Sulfadiazine, TMP/SMX, Sulfisoxazole, Amoxicillin	Survived
6	Holtz et al., 1985, in Laksananun et al., 2017	32	M	HIV, Intravenous drug abuse	Fever, Night sweats, Malaise, Weight loss	Pericardium	<i>N. asteroides</i>	TMP/SMX	Survived
7	Holtz et al., 1985, in Laksananun et al., 2017	34	M	HIV, Intravenous drug abuse, Disseminated TB	Dyspnoea, Fever	Pericardial fluid	<i>N. asteroides</i>	TMP/SMX	Died
8	Poland et al., 1990	34	F		Fever, Chills, Myalgia, Arthralgia, Chest pain, Dyspnoea, Pulsus paradoxus, Weight loss, Productive cough	Pericardial fluid, Sputum	<i>N. asteroides</i>	Sulfadiazine, Sulfisoxazole	Survived



9	Kessler et al., 1991	55	M		Dyspnoea, Fever, Peripheral oedema	Pericarial fluid, pericardium	<i>Nocardia</i> species	TMP/SMX	Survived
10	Clenney et al., 1993	45	M	Epilepsy, Alcohol abuse	Dyspnoea, Fever, Chest pain, Weight loss, Tachycardia, Tachypnoea, Tamponade	Pericardium	<i>N. asteroides</i>	TMP/SMX, Imipenem/cilastatin, Amikacin, Sulfadiazine	Survived
11	Santamaria Saber et al., 1993	32	M	Azathioprine, Prednisone	Fever, Cough, Diarrhoea, Chest pain, Vomiting	Pecicardium	<i>Nocardia</i> species	Amikacin, Cefoxitin	Died
12	Tabrizi et al., 1994 & Hornick et al., 1995	71	F	Polyarteritis, Glomerulonephritis, Pulmonary fibrosis, Prednisone	Chest pain, Dyspnoea, Cyanosis, Tamponade	Pericardium, Blood culture	<i>N. asteroides</i>	TMP/SMX, Ciprofloxacin	Died
13	Abdelkafi et al., 1997	41	M	Smoker, Alcohol abuse	Cough, Night sweats, Weight loss	Pericardial fluid	<i>N. farcinica</i>	TMP/SMX	Survived
14	Ramanathan & Rahimi, 2000, in Laksananun et al., 2017	42	M	HIV	Fever, Dyspnoea, Chills, Cough, Chest pain, Weight loss, Night sweats	Pericardial fluid	<i>N. asteroides</i>	TMP/SMX, Ceftriaxone, Minocycline	Survived
15	Rivero et al., 2000, in Laksananun et al., 2017	34	M	HIV, Intravenous drug abuse	Fever, Dyspnoea, Chest pain, Tamponade	Pericardial fluid	<i>N. asteroides</i>	TMP/SMX, Sulfadiazine	Survived
16	Leang et al., 2004, in Laksananun et al., 2017	24	F	HIV	Fever, cough, Dyspnoea, Pleural effusion, Tamponade	Pericardial fluid, Sputum	<i>N. asteroides</i>	TMP/SMX	Survived
17	Jinno et al., 2007, in Laksananun et al., 2017	44	M	HIV	Fever, Malaise, Tachycardia	Pericardial fluid	<i>N. asteroides</i>	TMP/SMX	Survived
18	McPhee et al., 2009	57	F	Kidney transplant, Renal impairment, Prednisone, Tacrolimus, Diabetes mellitus	Malaise, Anorexia, Chest pain, Dyspnoea, Tachycardia, Tachypnoea, Tamponade	Pericardial fluid	<i>N. farcinica</i>	Amikacin, Ceftriaxone, TMP/SMX, Minocycline	Survived

19	Roubille et al., 2010	50	M	BMI 41	Chest pain, Dyspnoea, Tamponade	Pericardial fluid	<i>Nocardia</i> species	TMP/SMX, Tigecycline	Died
20	Sirijatuphat et al., 2013	53	M	Nephrotic syndrome, Diabetes mellitus, Prednisone, Smoker	Chest pain, Dyspnoea, Tachypnoea, Tachycardia	Pericardial fluid	<i>N. farcinica</i>	TMP/SMX, Imipenem/cilastatin, Amikacin, Sulfadiazine	Survived
21	Aisenberger & Martin, 2014, in Laksananun et al., 2017	37	M	HIV, Chronic Hepatitis B, Cocaine use	Chest pain, Dyspnoea, Tamponade	Pericardial fluid	<i>N. asteroides</i>	TMP/SMX, Imipenem/cilastatin	Survived
22	Severo et al., 2016	50	F	Emphysema, Prednisone, Tacrolimus	Dyspnoea	Pericardial fluid	<i>N. nova</i>	TMP/SMX	Survived
23	Takashima et al., 2016	91	F	Myasthenia gravis, Tacrolimus	Fever, Tachycardia	Pericardial fluid	<i>Nocardia</i> species	Ceftriaxone	Died
24	Laksananun et al., 2017	32	M	HIV, Pulmonary TB	Chest pain, Dyspnoea, Tachycardia, Tachypnoea, Cyanosis, Tamponade	Pericardial fluid	<i>N. beijingensis</i>	TMP/SMX, Imipenem/cilastatin	Died
25	Faircloth & Troy, 2019	60	M	Alcohol abuse	Dyspnoea, Tamponade	Pericardial fluid, BAL	<i>N. farcinica</i>	TMP/SMX, Imipenem/cilastatin, Linezolid	
26	Griessel et al., 2021 (current study)	32	M	HIV	Dyspnoea, Chest pain, Cough, Weight loss, Malaise	Pericardial fluid	<i>N. asiatica</i>	TMP/SMX, Imipenem/cilastatin	Died

F = Female; M = Male; INH = Isoniazid; PAS = Para-aminosalicylic acid; TMP = Trimethoprim; SMX = Sulfamethoxazole; HIV = Human Immunodeficiency Virus; BMI = Body Mass Index, TB = Tuberculosis

Nocardiosis is usually sub-acute to chronic in nature and commonly affects the respiratory system, however involvement of other organ sites including the central nervous system, musculoskeletal system, eyes and heart may also occur[2].Nocardial pericarditis is a significant invasive cardiac manifestation of nocardiosis associated with high morbidity and mortality. This form of infection may arise as a consequence of direct contiguous spread from a pulmonary focus or may be secondary to haematogenous dissemination [2].Apart from non-specific constitutional symptoms, reported cases reveal that patients commonly present with fever, cough, tachycardia, pulsus paradoxus, dyspnoea and chest pain [2-13].Cardiac tamponade is a life-threatening complication observed in as many as 40% of patients with nocardial pericarditis [2-3, 5, 7-9, 13].

Establishing a diagnosis of nocardial pericarditis is challenging and is thus often delayed, likely contributing to the increased morbidity and mortality associated with the disease [2].Contributors to delays in diagnosis are multifactorial. Firstly, misdiagnosis as tuberculosis is not uncommon, especially in the context of immunosuppression in high burden tuberculosis settings, as the risk factors and clinical features of the two disease entities overlap substantially [2]. Secondly, empiric antimicrobial usage prior to specimen collection may contribute to a reduced diagnostic yield from culture [1].Finally, the inherent slow growing nature of the organism may contribute to delayed diagnosis or missed diagnosis if culture plates are not incubated for a sufficient duration of time [6].A high index of suspicion is critical to optimally diagnose and manage these patients.

Laboratory diagnosis of nocardial pericarditis is established by submitting pericardial fluid or tissue for microscopy, culture and sensitivity however, direct nucleic acid detection methods such as polymerase chain reaction (PCR) and/or sequencing may also be used [14]. *Nocardia* species can be visualised with conventional stains such as the Gram stain, where they appear as thin, filamentous, branching, beaded rods [14].Additional staining methods such as the modified acid-fast stain is used to demonstrate the partially acid-fast nature of the organism, allowing for a presumptive diagnosis of nocardiosis [14].*Nocardia* species are capable of growing on primary microbiological media such as blood and chocolate agar but due to their characteristically slow growing nature, agar plates may require prolonged incubation of up to 3 weeks before detectable growth is observed [14].Positive cultures typically appear as chalky white, dry colonies with aerial hyphae and a distinct mildew odour [14].Definitive species identification of characteristic bacterial

colonies is critical as unique antimicrobial susceptibilities exist between the various *Nocardia* species [14]. Species identification requires the use of highly discriminatory in-house molecular methods such as PCR and sequencing of the *secA1* or 16S rRNA genes as phenotypic methods are typically unreliable [14]. Antimicrobial susceptibility testing is indicated for all clinically significant isolates, with broth microdilution being the recommended antimicrobial susceptibility testing method [14].

Optimal management of nocardial pericarditis includes a combination of pericardial drainage and prolonged antimicrobial therapy (a minimum of 6 – 12 months' duration) [1]. Trimethoprim-sulfamethoxazole is considered the antimicrobial agent of choice for nocardiosis. (Mehta and Shamoo, 2020) Although no official guidelines exist on the optimal antimicrobial regimen for nocardial pericarditis, combination therapy for this form of disease may be of benefit to patients. Agents that may be considered as part of a combination regimen include imipenem, third generation cephalosporins and amikacin [1]. This decision should be guided by antimicrobial susceptibility test results.

## **5. Conclusion**

The clinical presentation of nocardiosis is very similar to tuberculosis. This case report draws attention to the consideration of human nocardial disease as an opportunistic infection in severely immunosuppressed patients, both as a differential diagnosis to tuberculosis as well as a possible coinfection.

## **Ethical approval**

Ethical approval was obtained from the Faculty of Health Sciences Research Ethics Committee of the University of Pretoria (Ethics reference no.: 8/2021). Written informed consent was obtained from the patient.

## **Funding**

No funding was received for this study.

## Authors contributions

Case conception: Rosemary Griessel, Barney Mitton, Roxanne Rule

Collection of data: Rosemary Griessel, Barend Mitton, Roxanne Rule

Data analysis: Rosemary Griessel, Barend Mitton, Roxanne Rule

Construction of case write up: Rosemary Griessel, Barend Mitton, Roxanne Rule, Mohamed Said

## Conflict of interest statement

The authors have no conflict of interest to declare.

## References

1. Mehta HH, Shamooy Y. Pathogenic Nocardia: A diverse genus of emerging pathogens or just poorly recognised? PLoS Pathogens. 2020
2. Laksananun N, Salee P, Kaewpoowat Q. Nocardia beijingensis pericarditis presenting with cardiac tamponade: A case report. Int J STD AIDS. 2018;29(5):515-519. doi:<http://dx.doi.org/10.1177/0956462417736986>.
3. Poland GA, Jorgensen CR, Sarosi GA. Nocardia asteroides pericarditis: report of a case and review of the literature. Mayo Clin Proc. 1990;65(6):819-24. doi:[http://dx.doi.org/10.1016/s0025-6196\(12\)62573-7](http://dx.doi.org/10.1016/s0025-6196(12)62573-7).
4. Kessler R, Follis F, Daube D, Wernly J. Constrictive pericarditis from Nocardia asteroides infection. Ann Thorac Surg. 1991;52(4):861-2. doi:[http://dx.doi.org/10.1016/0003-4975\(91\)91228-n](http://dx.doi.org/10.1016/0003-4975(91)91228-n).
5. Clenney TL, Hammond MD, McKeown PP, Holt DA, Wallach PM. Cardiac tamponade due to Nocardia asteroides. Chest. 1993;103(2):641-2. doi:<http://dx.doi.org/10.1378/chest.103.2.641>.
6. Santamaria Saber LT, Figueiredo JF, Santos SB, Levy CE, Reis MA, Ferraz AS. Nocardia infection in renal transplant recipient: diagnostic and therapeutic considerations. Revista do Instituto de Medicina Tropical de São Paulo. 1993;35:417-21.
7. Tabrizi SJ. Nocardia pericarditis. BMJ. 1994;309(6967):1495-7. doi:<http://dx.doi.org/10.1136/bmj.309.6967.1495>.

8. McPhee L, Stogsdill P, Vella JP. Nocardia farcinica pericarditis after kidney transplantation despite prophylaxis. *Transpl Infect Dis.* 2009;11(5):448-53. doi:<http://dx.doi.org/10.1111/j.1399-3062.2009.00413.x>.
9. Roubille F, Maxant G, Serre I, Colson P, Battistella P, Calvet B, Albat B, Pasquié JL. Fatal systemic nocardia infection revealed by cardiac tamponade. *Intern Med.* 2010;49(2):135-7. doi:<http://dx.doi.org/10.2169/internalmedicine.49.2478>.
10. Sirijatuphat R, Niltwat S, Tiangtam O, Tungsubutra W. Purulent pericarditis and cardiac tamponade caused by Nocardia farcinica in a nephrotic syndrome patient. *Intern Med.* 2013;52(19):2231-5. doi:<http://dx.doi.org/10.2169/internalmedicine.52.0453>.
11. Severo CB, Matter LB, Oliveira Fde M, Vargas AP, Schio SM, Camargo Jde J, Hochhegger B, Severo LC. Nocardia nova causing empyema necessitatis after lung re-transplantation: a case report. *Rev Soc Bras Med Trop.* 2016;49(4):523-6. doi:<http://dx.doi.org/10.1590/0037-8682-0331-2015>.
12. Takashima A, Yagi S, Yamaguchi K, Watanabe S, Yamamoto N, Ito H, Kadota M, Hara T, Yamazaki H, Ise T, Kusunose K, Tobiume T, Yamada H, Soeki T, Wakatsuki T, Sata M. Purulent Pericarditis Accompanying Pericardial Abscess Induced by Nocardia in an Immunocompromised Patient. *Circ J.* 2016;80(11):2409-2411. doi:<http://dx.doi.org/10.1253/circj.CJ-16-0531>.
13. Faircloth EL, Troy P. A Rare Presentation of Nocardia pericarditis Leading to Cardiac Tamponade in an Immunocompetent Patient. *Cureus.* 2019;11(2):e4140. doi:<http://dx.doi.org/10.7759/cureus.4140>.
14. Jorgensen JH, Pfaller MA. *Manual of Clinical Microbiology.* ASM Press. 2015
15. Abdelkafi S, Dubail D, Bosschaerts T, Brunet A, Van Camp G, de Marneffe M, De Vaster JM, Ninane V. Superior vena cava syndrome associated with *Nocardia farcinica* infection. *Thorax.* 1997;52(5):492-3. doi:<http://dx.doi.org/10.1136/thx.52.5.492>.