

# Successful treatment of babesiosis in a south-western black rhinoceros (*Diceros bicornis bicornis*)

DE Zimmermann,<sup>1</sup> I Vorster,<sup>2</sup> C Dreyer,<sup>1</sup> W Fowlds,<sup>3</sup> BL Penzhorn<sup>2,4,5</sup>

<sup>1</sup>South African National Parks, Veterinary Wildlife Services, South Africa

<sup>2</sup>Ticks & Tick-borne Diseases Research Programme, Department of Veterinary Tropical Diseases, Faculty of Veterinary Science, University of Pretoria, South Africa

<sup>3</sup>Ikhala Veterinary Wildlife Services, Amakhala Game Reserve, South Africa

<sup>4</sup>National Zoological Garden, South African National Biodiversity Institute, South Africa

<sup>5</sup>Centre for Veterinary Wildlife Studies, Faculty of Veterinary Science, University of Pretoria, South Africa

**Corresponding author, email:** david.zimmerman@sanparks.org

Under stressful conditions, black rhinoceroses that are sub-clinical carriers of *Babesia bicornis* can succumb to babesiosis. After 16 days in captivity, a five-year-old female black rhino captured for relocation presented with inappetence, abdominal discomfort and constipation. After chemical immobilisation, dry faecal balls were removed from the rectum, peripheral blood smears were made and blood collected into EDTA tubes. She was treated prophylactically for colic with flunixin meglumine, penicillin and doramectin. Piroplasmids were seen on fixed and stained peripheral blood smears. Overnight she developed severe haemoglobinuria, a sign consistent with babesiosis. Subsequently, DNA extracted from a blood specimen reacted with the *B. bicornis* probe on Reverse Line Blot (RLB) assay, confirming the diagnosis of babesiosis. Specific treatment consisted of 14 ml imidocarb dipropionate (dosage 2.4 mg/kg) administered intramuscularly by pole syringe. Fifteen days later the patient was still moderately anaemic, with the red blood cell (RBC) count, haematocrit and haemoglobin concentration within normal ranges but on microscopic examination there was a marked RBC macrocytosis and polychromasia indicative of a regenerative anaemia. DNA extracted from blood collected at that time did not react with the *B. bicornis* probe on RLB assay, indicating that treatment with imidocarb had been effective. Once the patient's appetite improved, she started gaining weight. After 82 days in captivity and 65 days after babesiosis had been diagnosed, she was released at the site where she had been captured.

**Keywords:** black rhinoceros, *Babesia bicornis*, babesiosis, South Africa, metapopulation management, imidocarb

## Introduction

Wildlife has long been known to act as carriers of *Babesia* species, which under stressful conditions, such as translocations or drought, can become pathogenic to the host (Penzhorn 2006) and may result in mortalities. The first records of mortalities of black rhinoceroses (henceforth rhinos), *Diceros bicornis*, due to babesiosis associated with capture and translocation were from the Grumeti and Lamai Game Control Areas in Tanzania (McCullough & Achard 1969). Subsequently, deaths of two black rhinos in Ngorongoro Conservation Area, Tanzania, and one in Hluhluwe-iMfolozi Park and Addo Elephant National Park (AENP), South Africa, respectively, were positively linked to babesiosis (Nijhof et al. 2003). A number of black rhino deaths at AENP during a very dry period during the 1990s were also thought to be primarily due to babesiosis. In all these cases, the animals died soon after capture or during periods of environmental stress.

In South Africa, *Babesia bicornis* and *Theileria bicornis* are relatively widespread in black rhino populations and thus pose a potential risk to the success of metapopulation management programmes (Zimmermann et al. 2021). Of the two black rhino subspecies that occur in South Africa, *D. b. bicornis* (south-western ecotype) is at greater risk due to its apparently *Babesia/Theileria*-naïve status in arid areas (Penzhorn et al. 2008), when compared to the subspecies *D. b. minor* (south-central ecotype). Conservation managers need to carefully evaluate methods and procedures during the translocation of black rhinos, especially when relocating from geographically and climatically diverse

ecosystems and more so when dealing with the *D. b. bicornis* ecotype.

After the death of the two black rhinos in the Ngorongoro Conservation Area, the remaining rhinos in the population received prophylactic treatment with diminazene by means of darting, to apparent good effect (Fyumagwa et al. 2004).

The case reported here was the first successful treatment of babesiosis in a black rhino.

## Case presentation

### History

In preparation for translocation to establish a founder population at a new site, eight black rhinos were captured on 11 and 12 March 2020 in two ecologically distinct habitats in AENP: four in the Thicket biome on the first day and four in the Nama-Karoo biome the following day. They were relocated to the AENP holding facility (boma) for boma-training to reduce stress during the translocation and to facilitate their adaptation after release at the recipient site. The long-acting tranquilliser zuclopenthixol acetate (Clopixol-Acuphase, Lundbeck) was administered intramuscularly, at a dosage of 100 mg/individual, to assist with the initial adaptation to the boma. While in the bomas, the rhinos were provided with an adequate quantity and variety of local browse. As it is difficult to maintain a rhino in good condition in a boma on browse alone, good quality lucerne (alfalfa) was also provided. After five to seven days, the rhinos had started to

adapt to the routine of boma management. By late March they had all started eating lucerne.

The rhinos were in relatively good condition at capture, except for Akhona, a five-year-old female which had been captured in the Thicket biome. At time of capture her weight was estimated as 750 kg and her condition score at 2.5 to 3 (on a scale of 1–5: 1 being very poor; 5 excellent). On 27 March 2020, 16 days into the boma-holding and training period, Akhona presented with inappetence and abdominal discomfort. She frequently attempted to defaecate and appeared to be constipated. For closer examination, she was immobilised, using a combination of 2.5 mg etorphine hydrochloride (M99, Novartis) and 40 mg azaperone (Stresnil, Janssen-Cilag) administered intramuscularly. After examination, immobilisation was reversed by intravenous administration of 75 mg naltrexone (Naltrexone, Kyron Laboratories).

### Clinical examination

Akhona was very listless and did not respond with the usual excitation when darted with the immobilising agent, although she did break into a sweat without any prior exertion. Her heart rate was 65–75 beats per minute and respiration six to eight breaths per minute. The rectal temperature was 40.5 °C. Her rectum was impacted with dry faecal balls, which were manually removed by means of an enema with medical liquid paraffin and three to four litres of water. To combat dehydration, in addition to the water administered per rectum, one litre of Ringers lactate solution (Fresenius Kabi) and one litre of 5% glucose in saline solution were administered intravenously. As prophylactic treatment for colic, 15 ml flunixin meglumine (15 mg/ml) (Finadyne, Schering-Plough AH), 60 ml procaine benzylpenicillin (150 mg/ml); benzathine benzylpenicillin (115 mg/ml) (Duplocillin, Intervet SA) and 15 ml doramectin (10 mg/ml) (Dectamax, Zoetis) were administered intramuscularly. Blood specimens were collected from the *vena brachialis* into K3EDTA, SST serum and Sodium Heparin vacutainers

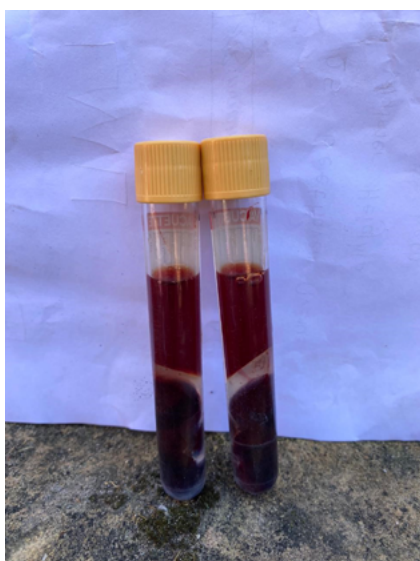

Figure 1: Serum blood samples collected from the black rhino Akhona, on 27 April 2020, while in the holding facilities at Addo Elephant National Park, South Africa; note the haemolysed appearance of the serum

(Vacurette, 9 ml). The blood specimens appeared to be haemolysed (Figure 1) with a haematocrit of 41.

Peripheral blood smears were made from a drop of blood obtained from the tip of the ear using a 21' gauge hypodermic needle. The blood smears were air dried, fixed and stained in Diff-Quik (Kyro-Quick Stain, Kyron), and examined microscopically; large piroplasms were seen in the red blood cells (RBCs) (Figures 2 and 3). Further clinical haematology and serum chemistry could not be performed as the countrywide lockdown due to the COVID-19 pandemic, precluded access to laboratories for analysis.

### Management and outcome

Overnight Akhona had developed severe haemoglobinuria. The following morning, 28 March 2020, she was treated for babesiosis by intramuscular administration of 14 ml imidocarb dipropionate (120 mg/ml) (Forray 65, Schering-Plough Animal Health) at a dosage of 2.4 mg/kg. This dose was extrapolated from the indicated dosage for equine babesiosis. The following day, 10 ml dexamethasone (2 mg/ml) (Kortico, Bayer Animal Health) was administered. Both were given by means of a pole-syringe as her condition had deteriorated, increasing the risk of immobilisation complications. Over the course of the following two weeks, she was carefully monitored. Her inappetence persisted over this period and she lost body condition (Condition Score 1 to 1.5). Browse was cut up into smaller pieces and mixed with lucerne. Akhona showed a preference for *Azima tetracantha* and *Plumbago auriculata*, therefore these were fed in greater quantity.

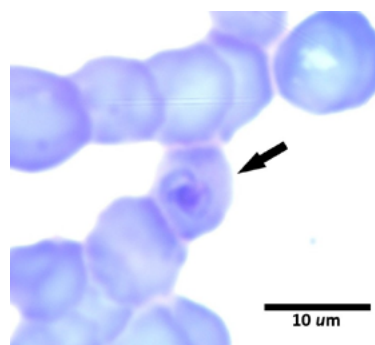


Figure 2: Large piroplasm in a red blood cell (arrowhead) of the peripheral blood smear (stained in Diff-Quik) made from the black rhino Akhona on 27 April 2020

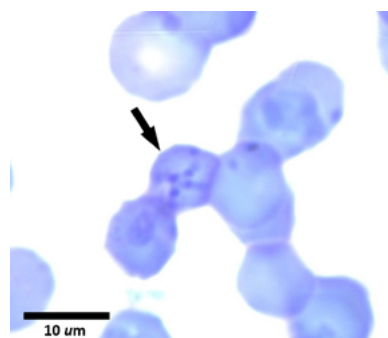


Figure 3: Piroplasm merozoite tetrad (Maltese Cross) in red blood cell (arrowhead) of the peripheral blood smear (stained in Diff-Quik) made from the black rhino Akhona on 27 April 2020

**Table I:** Haematological parameters of female black rhinoceros 'Akhona' two weeks (13 April) after being treated against babesiosis

Parameter <sup>a</sup>	Akhona	Reference range <sup>b</sup>	Mean $\pm$ 1 SD <sup>c,d</sup>
RBC ( $10^{12}/L$ )	2.6	3.6–7.2	4.6–5.0
HGB (g/dL)	8.8	10.8–20.6	14.3–17.9
Hct (%)	23.0	29–54	37.9–48.1
MCV (fL)	89.0	59.3–103	74.3–89.7
MCH (pg)	34.0	23.7–36.4	28.9–33.3
MCHC (g/dL)	38.3	30.8–61	33.7–41.8

<sup>a</sup>RBC – red blood cell, HGB – haemoglobin, Hct – hematocrit, MCV – mean corpuscular volume, MCH – mean corpuscular haemoglobin, MCHC – mean corpuscular haemoglobin concentration

<sup>b</sup>Kock et al. 1990

<sup>c</sup>SD – standard deviation

<sup>d</sup>Calculated from data presented by Kock et al. 1990

Although Akhona was still in poor condition 15 days later (13 April 2020), her demeanour had recovered sufficiently, reducing the risk of a follow-up immobilisation and examination. The protocol for immobilisation and collection of blood specimens, as described above, was followed; 40 ml of sodium glycerophosphate (200 mg/ml) (Phosamine Stimulans, Bayer Animal Health) was administered intramuscularly for liver support due to the ongoing inappetence. Blood specimens were collected for routine haematological assessment (Abaxis HM5 machine). Results (Table I) were compared to baseline data for free-ranging black rhinos (Kock et al. 1990).

Akhona was moderately anaemic, with a red RBC of 2.6 ( $10^{12}/L$ ) and a haematocrit of 23%. The haemoglobin concentration was still moderately low at 8.8 g/dl. The mean cell volume (MCV), mean corpuscular haemoglobin (MCH) and mean corpuscular haemoglobin concentration (MCHC) readings were all within the normal reference ranges. On microscopic examination there was a marked RBC macrocytosis and polychromasia indicative of a regenerative anaemia.

After approximately four weeks, Akhona started eating lucerne again and was able to gain weight. By 1 June 2020, after 82 days in captivity and 65 days since being diagnosed with babesiosis, she had gained sufficient weight, with a condition score of 2.5–3,

and was released back into AENP at the site where she had been captured.

The rest of the cohort showed no signs of babesiosis while in the holding facilities. Prior to relocation, the other three individuals originating from the Thicket biome were treated prophylactically with imidocarb at a dosage of 2.4 mg/kg. The four rhinos originating from the Nama-Karoo biome were not treated, as they were deemed low risk of being carriers of *B. bicornis*. All seven rhinos were successfully relocated and released at destination.

#### Retrospective RLB-PCR analysis of collected blood specimens

Blood specimens in EDTA, collected during capture on 10 March ( $n = 4$ ) and 11 March 2020 ( $n = 4$ ), and repeat sampling of Akhona on 27 March, 13 April and 1 June 2020, were stored at the SANParks Biobank in Kimberley. Aliquots of blood were transferred to Whatman filter paper and sent to the molecular biology laboratory at the Department of Veterinary Tropical Diseases, Faculty of Veterinary Science, University of Pretoria. Standard techniques were used to extract DNA, which was subjected to the Reverse Line Blot (RLB) hybridisation assay (Nijhof et al. 2003) to screen for the presence of piroplasms

**Table II:** Piroplasms (*Babesia* spp. and *Theileria* spp.) and blood-associated rickettsias (*Ehrlichia* spp. and *Anaplasma* spp.) detected by Reverse Line Blot assay in blood samples from eight black rhinoceroses captured (11 and 12 March 2020) in the Thicket or Nama-Karoo biomes in Addo Elephant National Park (AENP) and subsequent sampling while in holding facilities at AENP

Sample no	Rhino ID	Sample date	Piroplasms and/or rickettsias detected by Reverse Line Blot assay	Biome from which sample originated
1	#34 (Akhona)	2020/03/11	<i>E/A</i> catch-all <sup>a</sup> (f) <sup>b</sup> , <i>T.</i> catch-all <sup>c</sup> (f)	Thicket
2	#4	2020/03/11	No nucleic acid detected	Thicket
3	#10	2020/03/11	<i>E/A</i> catch-all, <i>T.</i> catch-all (f)	Thicket
4	#24	2020/03/11	<i>T/B</i> catch-all, <i>B.</i> catch-all 1 <sup>e</sup>	Thicket
5	#54	2020/03/12	<i>E/A</i> catch-all	Nama-Karoo
6	#56	2020/03/12	<i>E/A</i> catch-all	Nama-Karoo
7	#206	2020/03/12	<i>E/A</i> catch-all	Nama-Karoo
8	Unnotched	2020/03/12	<i>E/A</i> catch-all (f), <i>T/B</i> catch-all, <i>T.</i> catch-all (f), <i>B.</i> catch-all 1	Nama-Karoo
9	#34 Akhona	2020/03/27	<i>E/A</i> catch-all (f), <i>T/B</i> catch-all <sup>d</sup> , <i>Babesia bicornis</i>	Thicket
10	#34 Akhona	2020/04/13	<i>E/A</i> catch-all (f)	Thicket
11	#34 Akhona	2020/06/01	<i>E/A</i> catch-all (f)	Thicket

<sup>a</sup>*Ehrlichia/Anaplasma* catch-all

<sup>b</sup>Faint

<sup>c</sup>*Theileria* catch-all

<sup>d</sup>*Theileria/Babesia* catch-all

<sup>e</sup>*Babesia* catch-all 1

(*Babesia* spp. and *Theileria* spp.) and blood-associated rickettsias (*Ehrlichia* spp. and *Anaplasma* spp.) (Table II).

Samples numbers 1 to 8 were collected during the capture of the rhino on 11 and 12 March. Piroplasms and/or rickettsias were detected in all of the samples except number 2, originating from the Thicket biome, where no nucleic acid could be detected. One sample (sample number 4) hybridised only with the *Theileria/Babesia* and *Babesia*-specific probes. The remaining six specimens all hybridised with the *Ehrlichia/Anaplasma* genera-specific probe. Three of these (Sample numbers 1, 3 and 8) also hybridised with the *Theileria* genus-specific probe. Sample number 8 also hybridised with *Babesia*-specific probe.

The specimen collected from Akhona on day of capture (Sample number 1), hybridised with the *Theileria* genus-specific and *Ehrlichia/Anaplasma* genera-specific probes. The specimen collected from her on 27 March (Sample number 9) hybridised with the *Babesia bicornis*-specific probe, confirming the diagnosis of babesiosis made on microscopic examination of the blood smear. Specimens collected on 13 April and 1 June did not hybridise with the *B. bicornis*-specific probe, indicating that treatment with imidocarb had been successful in resolving the babesiosis infection.

## Discussion

*Babesia* infections may be peracute, acute, chronic, or inapparent. In a typical acute case, the first sign is fever, up to 42 °C; this is followed by signs of malaise and inappetence (Fraser et al. 1991). Akhona's initial clinical findings of pyrexia and inappetence presented as a typical babesiosis case, but this can easily be confused with a number of other conditions, such as colic.

When a *Babesia*-infected tick engorges on a host, sporozoites in its saliva pass into the host's bloodstream where they enter erythrocytes, undergo binary fission, and break out into the plasma to invade new cells. This rupturing of the RBCs causes the characteristic haemoglobinuria, as seen in Akhona, which is commonly referred to as "redwater" in cattle. In the case of Akhona, piroplasms visible on blood smears were retrospectively confirmed to be *Babesia bicornis* on RLB-PCR analysis. Interestingly, the blood specimen taken at capture (Table II: Sample No. 1) did not react with the *B. bicornis* probe, nor with *Theileria/Babesia* or *Babesia* genus-specific probes, yet, barely two weeks later, Akhona showed clinical signs typical of babesiosis.

There are two possible explanations: 1) Akhona was a subclinical carrier, but the parasitaemia at capture was so low that it was not detected by RLB; or 2) she contracted the infection while in the boma. The latter would have been possible if an infected rhino had been kept in the bomas, prior to Akhona, and dropped infected ticks. In this instance, no rhinos had been held in the bomas prior to the capture of the cohort. The first explanation is more feasible as it has been demonstrated that rhinos can be subclinical carriers of *Babesia* spp, which can become pathogenic under stressful conditions, in this case, the combined capture and confinement in the holding facility. In addition, prior to capture, Akhona had been kept in a separate camp due to an injury she had sustained in 2018. On capture her condition score

(2.5 to 3) was not as good as that of the other seven rhinos (3+); it is speculated that this was due to nutritional stress as a result of poor browse availability within the camp where she was held.

The translocation of wildlife is an essential conservation tool in the in situ management of small isolated populations and the establishment of new founder populations into areas from which they have become extirpated (Parker et al. 2012). In the case of black rhinos, which inhabit a diversity of habitats, the practical issues of individual selection, capture, handling, welfare and general translocation management can be very complex. Due to the stressors associated with confinement, individuals or groups should preferably not be held in confinement for extended periods. Paradoxically, however, when moving black rhinos to a different habitat, it is best practice to hold the rhinos at source and introduce them to supplementary food and the local vegetation at destination, to assist with the adaptation to the new area and reduce the environmental stressors of the translocation. The south-western black rhino ecotype, originating from the more arid areas of South Africa, has been found to be at risk due to their apparently *Babesia/Theileria*-naïve status (Penzhorn et al. 2008).

Addo Elephant National Park extends over a number of biomes, ranging from the arid Nama-Karoo to moist coastal forests. The Thicket biome is situated in between these two extremes. The potential tick vectors also differ in the different biomes. The tick vectors of *B. bicornis* have not been confirmed, but one or more of the following ticks that occur in AENP, could possibly be competent vectors of *B. bicornis*: *Amblyomma hebraeum*, *Hyalomma rufipes*, *Hyalomma truncatum*, *Rhipicephalus follis*, *Rhipicephalus simus* and *R. zumpti* (Zimmermann et al. 2021). In general, the rhino captured in the Nama-Karoo are less infested with potential tick vectors when compared to rhino originating from the Thicket habitat and *A. hebraeum* has not been detected in the arid Nama-Karoo habitat. The four rhinos captured in the arid Nama-Karoo biome of AENP were regarded as a low risk of being potential carriers, and because they were being relocated to an arid area, where it is unlikely there are potential vectors, they posed less of a risk of 'contaminating' the destination property. However, on RLB assay, DNA extracted from blood from one of the rhinos from the Nama-Karoo biome (Table II: Lab # RE20/217) reacted with the *Theileria/Babesia* catch-all and *Babesia* catch-all probes. This suggests that, in the case of AENP, even rhinos originating from more arid areas may be subclinical carriers of *Babesia bicornis*. Furthermore, the fact that specimens from all four rhinos from the Nama-Karoo biome reacted with the *Ehrlichia/Anaplasma* probe on RLB strongly suggests that, even in this arid environment, tick numbers may be high enough to ensure transmission of tick-associated microorganisms in the rhino population.

The remaining three rhinos originating from the Thicket biome in AENP did pose a potential higher risk of being *Babesia* spp carriers and were subsequently treated prophylactically for babesiosis prior to release at destination. There appeared to be no adverse side-effects to the prophylactic treatment with imidocarb at a dosage rate of 2.4 mg/kg.



It is thus recommended that rhino translocated from biomes associated with babesiosis, such as AENP, are treated prophylactically with an anti-*Babesia* formulation such as imidocarb.

#### Acknowledgements

The Veterinary Wildlife Services team of SANParks, especially Rudi Williams, Angela Bruens and Lourens de Lange, for their assistance during the capture of the study animals.

#### Ethical approval

The capture and holding of all rhinos was conducted according to the "SANParks's standard operating procedure for capture, transport and holding of wild animals" – (SANParks Ref number 17/PR-CSD/SOP/capture, transport, holding facilities (04/07) vs 2) which is approved by SANParks ethics committee.

#### ORCID

DE Zimmermann  <https://orcid.org/0000-0002-1742-5510>

I Vorster  <https://orcid.org/0000-0001-8576-6213>

C Dreyer  <https://orcid.org/0000-0002-2476-3147>

W Fowlds  <https://orcid.org/0000-0002-9447-0294>

BL Penzhorn  <https://orcid.org/0000-0001-6935-5545>

#### References

- Fraser, C.M., Bergeron J.A., Mays A., et al., (eds), 1991, *The Merck Veterinary Manual*, 7th edn, Merck & Co., Inc. New York.
- Fyumagwa, R.D., Mkumbo, S.S., Morkel, P., 2004, Remote treatment of black rhinos against babesiosis in Ngorongoro Crater, Tanzania, *Pachyderm* 37, 80–83.
- Kock, M., Du Toit, R., Morton, D., et al., 1990, Baseline biological data collected from chemically immobilized, free ranging black rhinoceroses (*Diceros bicornis*) in Zimbabwe, *J Zoo Wildl Med* 21(3), 283–291.
- McCulloch, B., Achard, P.L., 1969, Mortalities associated with capture, translocation, trade and exhibition of black rhinoceros, *Int Zoo Yearb* 9(1), 184–195. <https://doi.org/10.1111/j.1748-1090.1969.tb02681.x>.
- Nijhof, A.M., Penzhorn, B.L., Lynen, G., et al., 2003, *Babesia bicornis* sp. nov. and *Theileria bicornis* sp. nov.: Tick-borne parasites associated with mortality in the black rhinoceros (*Diceros bicornis*), *J Clin Microbiol* 41(5), 2249–2254. <https://doi.org/10.1128/JCM.41.5.2249-2254.2003>.
- Parker, K.A., Dickens, M.J., Clarke, R.H., et al., 2012, The theory and practice of catching, holding, moving and releasing animals, In: Ewen, G.E., Armstrong, D.P., Parker, K.A., Seddon, P.J. (eds) *Reintroduction Biology*. Chp 4, 105–137. <https://doi.org/10.1002/9781444355833.ch4>.
- Penzhorn, B.L., 2006, Babesiosis of wild carnivores and ungulates, *Vet Parasitol* 138(1-2), 11–21. <https://doi.org/10.1016/j.vetpar.2006.01.036>.
- Penzhorn, B.L., Oosthuizen, M.C., Bosman, A.M., et al., 2008, Black rhinoceros *Diceros bicornis* populations in northwestern Namibia are apparently not infected with piroplasms, *J Wildl Dis* 44(4), 1032–1035. <https://doi.org/10.7589/0090-3558-44.4.1032>.
- Zimmermann, D.E., Penzhorn, B.L., Vorster, I., et al., 2021, *Babesia bicornis*, *Theileria bicornis* and *Theileria equi* in metapopulations of two black rhinoceros (*Diceros bicornis*) subspecies in South Africa and their potential impact on conservation, *Ticks Tick Borne Dis* 12(2), 101635. <https://doi.org/10.1016/j.ttbdis.2020.101635>.