

## ORIGINAL RESEARCH

# Root and canal morphology of maxillary second molars in a Black South African subpopulation using cone-beam computed tomography and two classifications

Glynn Dale Buchanan BChD, MSc<sup>1,2</sup>  | Mohamed Yasin Gamiieldien BChD, MSc<sup>3</sup> | Inger Fabris-Rotelli PhD<sup>4</sup> | Albert Van Schoor PhD<sup>2</sup> | Andre Uys BChD, PhD<sup>2</sup>

<sup>1</sup>Department of Odontology, School of Dentistry, Faculty of Health Sciences, University of Pretoria, Pretoria, South Africa

<sup>2</sup>Department of Anatomy, School of Medicine, Faculty of Health Sciences, University of Pretoria, Pretoria, South Africa

<sup>3</sup>Department of Maxillofacial and Oral Surgery, School of Dentistry, Faculty of Health Sciences, University of Pretoria, Pretoria, South Africa

<sup>4</sup>Department of Statistics, Faculty of Natural and Agricultural Sciences, University of Pretoria, Pretoria, South Africa

## Correspondence

Glynn Dale Buchanan, Department of Odontology, University of Pretoria Oral Health Centre, 31 Bophelo Road, Prinshof Campus, Riviera, Pretoria 0002, South Africa.

Email: [glynn.buchanan@up.ac.za](mailto:glynn.buchanan@up.ac.za)

## Abstract

This study investigated the root and canal morphology of maxillary second molars in a Black South African population using high-resolution cone-beam computed tomography. In total, 386 maxillary second molar teeth were evaluated and described according to the classifications of Vertucci (with the additions of Sert and Bayirli), as well as Ahmed et al. Root number, fusions and canal morphology were recorded. Relationships between morphology, sex and age were assessed using Fisher's exact test ( $p < 0.05$ ). Maxillary second molars were predominantly three-rooted (96.1%), with root fusion observed in 14%. No relationships between sex, age and canal morphology were found. Additional canals were observed in 67.4% of mesiobuccal roots. The Ahmed et al. classification provided a better overall description of the morphology. In this population, maxillary second molar teeth exhibited a diversity of root and canal morphology. Complex variations may render endodontic management more difficult and increase the possibility of missed anatomy.

## KEYWORDS

classification, cone-beam computed tomography, dental anatomy, endodontics, maxillary second molar

## INTRODUCTION

Sound knowledge of dental root and canal morphology is a prerequisite to successful endodontic treatment [1]. Many studies have demonstrated variations in the external root structure, along with complex internal canal systems in several tooth types [2–5]. These differences have been related to variations in ethnicity, race, sex and geographic distribution of subjects [2, 6].

Maxillary second molars have frequently been studied due to a high incidence of anatomical variation and

complexities in both the external and internal structure of this tooth type [6]. These teeth commonly display three roots: a mesiobuccal, distobuccal and palatal root [7]. With a reported prevalence ranging from 5.9% to 42.2% [8–14], root fusion is an important variation in this tooth type.

The role of cone-beam computed tomography (CBCT), in both clinical endodontics and the study of endodontic anatomy, is well established [15]. Historically, several techniques have been employed to study dental anatomy. Examples of these include conventional radiography [7] and clearing and staining [5]. The use of CBCT has

This is an open access article under the terms of the [Creative Commons Attribution-NonCommercial](https://creativecommons.org/licenses/by-nc/4.0/) License, which permits use, distribution and reproduction in any medium, provided the original work is properly cited and is not used for commercial purposes.

© 2022 The Authors. *Australian Endodontic Journal* published by John Wiley & Sons Australia, Ltd on behalf of Australian Society of Endodontology Inc.

increased in recent times due to its superiority over conventional radiography and a similar reliability to the clearing and staining technique [16].

Since its inception in 1984, the Vertucci classification [5], has been extensively used to describe root canal morphology. Due to a limited number of categories in the original Vertucci system, additions describing more complex canal configurations were proposed by Sert and Bayirli in 2004 [2]. More recently, Ahmed et al. [17] introduced an alternative classification system where a single descriptive code represents both canal morphology and root number. To date, the newer system has been implemented in a limited number of studies [18], and to the authors' knowledge has not been used to describe the morphology of maxillary second molar teeth.

According to the last available South African census, Black African individuals constitute the vast majority (79%) of the country's population [19]. Limited reports of dental anatomy in Black African populations, as well as Southern Africans in general, exist in the current literature [3, 4, 20]. The root and canal morphology of maxillary second molars is currently undocumented in this population group. The present study, therefore, aimed to describe the root and canal morphology of maxillary second molars in a Black South African population using two classification systems and CBCT imaging.

## MATERIALS AND METHODS

The Research Ethics Committee of the Faculty of Health Sciences, University of Pretoria (Protocol number:

331/2021) granted ethical approval for this study. The study design was descriptive and cross-sectional and reported following the Strengthening the Reporting of Observational studies in Epidemiology (STROBE) guidelines. The STROBE flow diagram can be seen in Figure 1. Retrospective analysis of existing CBCT scans from the Section of Diagnostic Imaging, University of Pretoria Oral and Dental Hospital was performed. Convenience sampling was used over a date range extending from May 2016 until September 2021.

Scan evaluation was performed in line with the methodology described by Buchanan et al. [3] and Ahmed et al. [21] with modification. A detailed description of the specific methodology follows:

### Origin of scans

A single CBCT unit (Planmeca Promax 3D Max, Planmeca OY) based in the Section of Diagnostic Imaging, University of Pretoria Oral and Dental Hospital had previously acquired all scans included for the study. No new patients were scanned for the purpose of the study. The parameters of the CBCT machine were variable and adjusted as necessary at the time of acquisition as clinically indicated. The CBCT machine's possible parameter ranges were as follows: resolution—100 to 600  $\mu\text{m}$ , number of basic frames—300 to 750, tube current—1 to 14 mA, tube voltage—54 to 90 kV, focal spot diameter—0.6 mm. Possible voxel sizes ranged from 0.150 to 0.600 mm. All included scans had previously been acquired for a variety of clinical reasons.

STROBE Flow Diagram

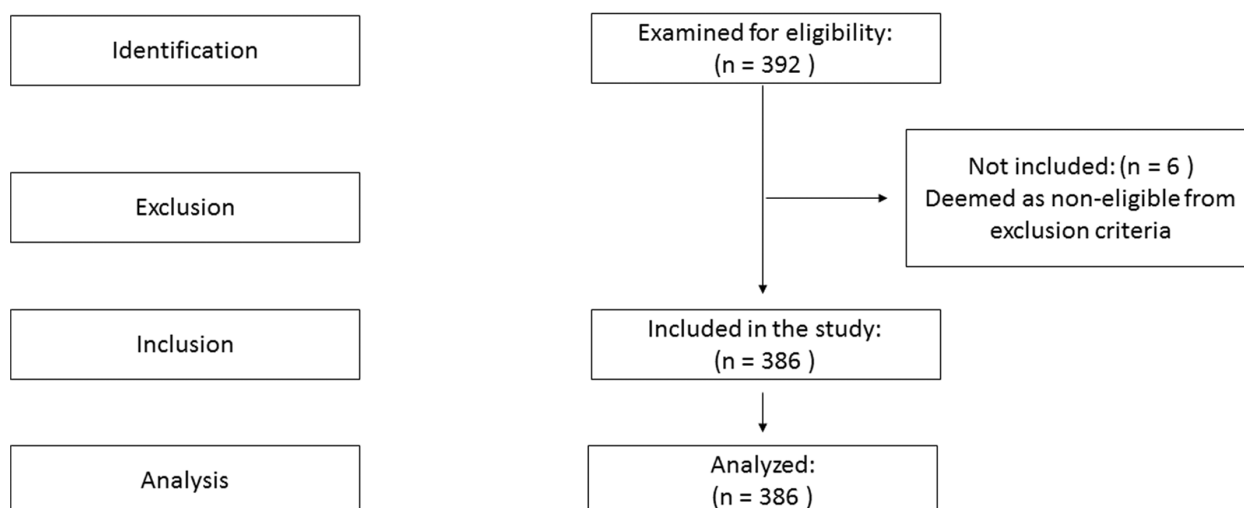


FIGURE 1 A STROBE flow diagram demonstrating subject eligibility and inclusion for the present study.

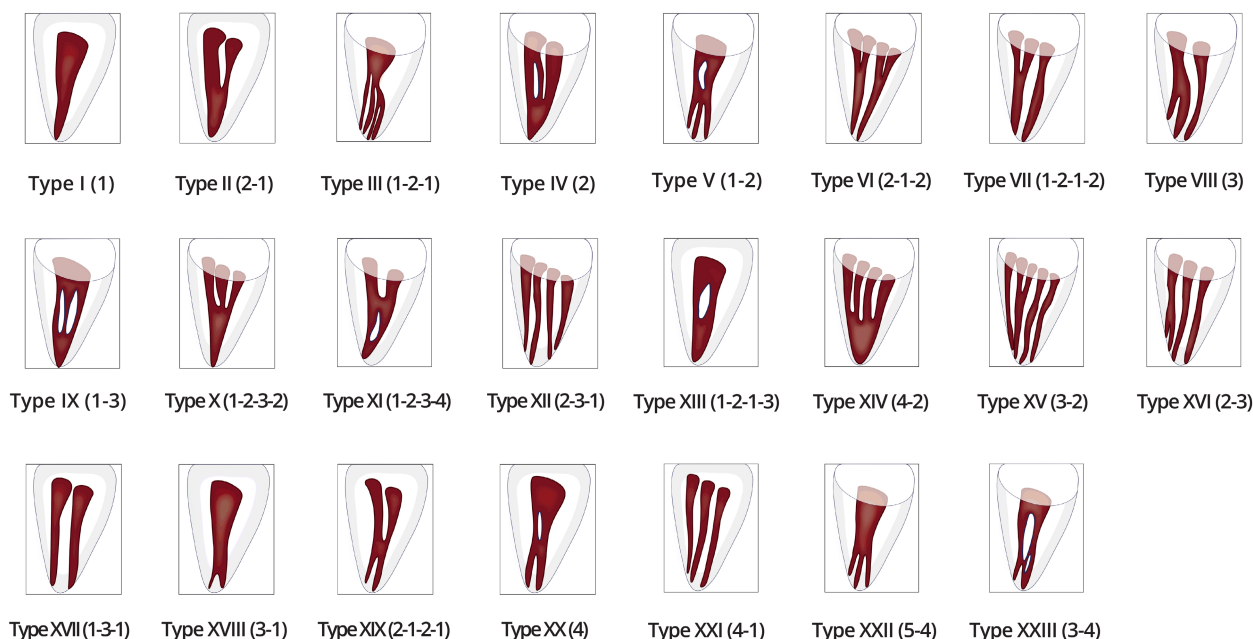
## Analysis of scans

All CBCT scans were evaluated in three planes (coronal, sagittal, and axial) to determine the root number and internal configurations of each tooth. The software used was Romexis version 6.0 (Planmeca, Planmeca OY). Two examiners were involved in the evaluation of the scans. The examiners were calibrated prior to data collection by assessing 50 individual teeth. In line with the previous methodology [22], the first examiner evaluated all the scans and the second examiner a 10% subset.

Brightness, contrast and sharpness filters were adjusted as necessary to allow improved visualisation of each scan. The two examiners' findings were initially recorded in Microsoft Excel 2016 (Microsoft Corporation). In cases of agreement, the classification was accepted and remained unchanged, however, in cases of disagreement a third examiner was approached where no consensus could be reached.

## Root and canal morphology

The Vertucci classification [5] with the additions of Sert and Bayirli [2] was used to classify the canal morphology of all maxillary second molars. The number of roots was recorded. Classification of canal type using the Vertucci system was performed per individual root [6]. Sert and Bayirli's 23 possible canal configurations are presented in Figure 2.



**FIGURE 2** The 1984 Vertucci classification system with the additions proposed by Sert and Bayirli in 2004 was used in the present study [2]. A total of 23 possible canal configurations can be described using this classification system.

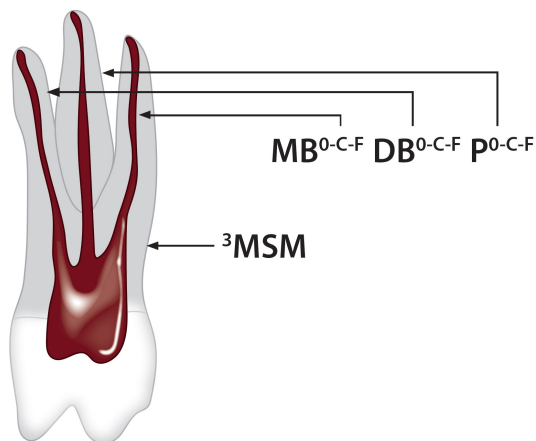
Each tooth was additionally classified using the Ahmed et al. [17, 21] classification. The Ahmed et al. classification, with a brief description of coding nomenclature, is presented in Figure 3. Maxillary second molars were assigned the code MSM during description using the Ahmed et al. system. In cases where root fusion was identified, the morphology of the fused root configuration was described according to the classification of Zhang et al. [9], as suggested by Ahmed et al. [21]. The six types of root fusion described in this classification are demonstrated in Figure 4. All scans included in the present study were anonymised. Sex and age were recorded to test for clinically relevant differences regarding root number or canal morphology. Age cohorts were defined as: <25 years, 25–40 years, and >40 years in line with the previous methodology [4].

## Inclusion criteria

The inclusion criteria were: fully-formed maxillary second molar teeth from subjects 15 years of age or older, scans of adequate quality for the visualisation of individual root and canal morphology, voxel sizes equal to or lower than 0.2 mm, and subjects defined as Black African according to the hospital file.

## Exclusion criteria

Exclusion criteria included the following: teeth where individual roots and/or canals could not be adequately



**FIGURE 3** The Ahmed et al. classification system. The number of roots, root fusion and canal morphology could be described with a single code. The tooth itself was assigned a code, in the present study indicated as MSM (maxillary second molar). Root number was reported using a superscript number to the left of the tooth code (e.g., <sup>3</sup>MSM for three roots or <sup>1</sup>MSM for a single root). To the right of the tooth code, letters O, C and F indicated number of orifice/s (O), canal/s (C), and foramina (F) per root (e.g., MB for the mesiobuccal root). Numbers replaced the letters when the root and canal morphology was reported (e.g., code <sup>3</sup>MSM MB<sup>1</sup> DB<sup>1</sup> P<sup>1</sup> indicated a three-rooted tooth, with one canal per root). Root fusions, as described by Zhang et al. [9] were indicated using the prefix RF in brackets prior to the root number, with a number directly adjacent to the RF code, indicating the type of root fusion [e.g., (RF<sup>2</sup>)<sup>3</sup>MSM MB<sup>1</sup> DB<sup>1</sup> P<sup>1</sup> indicated a three-rooted maxillary second molar, with the fusion of the MB and P root, i.e., type 2 fusion, with one canal per root]. C-shaped canals were indicated using the prefix CSC in brackets, followed by a Roman numeral indicating the type of C-shape according to Fan et al. [23]. Double slashes (//) were used to indicate root fusions which shared canal anatomy (e.g. (RF<sup>1</sup>)<sup>3</sup>MSM MB//DB<sup>2-1</sup> P<sup>1</sup> indicated a three-rooted maxillary second molar with the fusion of the MB and DB roots, the fused roots shared a canal system which began as two independent canals but fused to form a single canal before exiting as one foramen. The palatal root however displayed no root fusion with a single orifice, canal and apical foramen).

visualised, evidence of dental treatment or surgery altering the original anatomy (e.g., posts, metal restorations, apicectomy, root resection, etc.). Teeth other than maxillary second molars were excluded.

## Sample size

A minimum of 385 maxillary second molars were required. The sample size was calculated using Epi-Info version 7 statistical software (Atlanta, GA, USA). A 50% prevalence was used to maximise the sample size, assuming a 5% margin of error and 95% confidence interval, yielding a minimum sample size of  $n = 384$ . This included left- and right-sided samples.

## Statistical analysis

R Statistical Software version 4.1.1 (R Core Team 2021. R. A language and environment for statistical computing. R Foundation for statistical computing) was used to test for associations between categorical variables. The Fisher Exact test was used with a significance set at  $p < 0.05$ . Inter- and intra-rater reliability was assessed using percentage agreement.

## RESULTS

### Description of the sample and examiner agreement

A total of 392 maxillary second molar teeth were evaluated for inclusion. Six samples ( $n = 6/392$ ) were excluded as they did not meet the inclusion criteria. The final analysis was, therefore, performed on the remaining 386 teeth, from 204 subjects. The age of the subjects ranged from 15 to 72 years (mean age: 32.4 years). The distribution of left- ( $n = 197/386$ , 51%) and right-sided ( $n = 189/386$ , 49%) samples was similar. The sex distribution included fewer teeth from male ( $n = 163/386$ , 42.2%) than female subjects ( $n = 223/386$ , 57.8%). All samples evaluated met the inclusion criteria. Inter- and intra-examiner agreement was 82% and 89%, respectively.

### Root number and root fusion

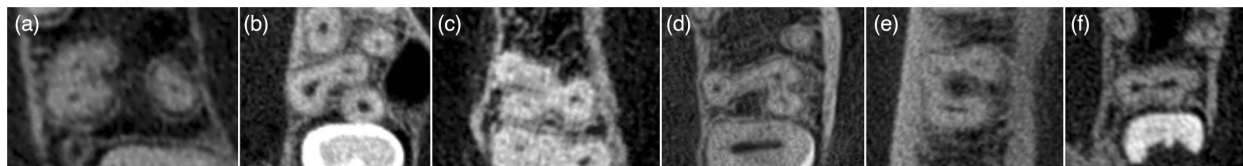
The vast majority of maxillary second molars were three-rooted ( $n = 371/386$ , 96.1%). A minority were two-rooted ( $n = 11/386$ , 2.8%) and a very small number of teeth displayed either one ( $n = 3/386$ , 0.7%) or four roots ( $n = 1/386$ , 0.25%).

Root fusion was present in more than one-tenth ( $n = 54/386$ , 14.0%) of maxillary second molars. The most common type of root fusion was type 1 (MBR and DBR, 37.0%,  $n = 20/54$ ), followed by type 2 (MBR and PR, 33.3%,  $n = 18/54$ ). Type 4 ( $n = 7/54$ , 12.9%), type 5 ( $n = 4/54$ , 7.4%), type 6 ( $n = 3/54$ , 5.6%) and type 3 ( $n = 2/54$ , 3.7%) root fusions were less commonly observed.

### Canal configurations according to the Vertucci classification

In molar teeth, the Vertucci classification was applied per individual root [5]. The distribution of canal configurations of maxillary second molars according to Vertucci is summarised in Table 1.





**FIGURE 4** All six types of root fusions according to Zhang et al. [9] were observed in the present study. Axial views revealed the following fusions: Type 1 (a)—the mesiobuccal root (MBR) is fused with the distobuccal root (DBR); in type 2 (b)—the MBR is fused with the palatal root (PR); in type 3 (c)—DBR fused with PR; type 4 (d)—MBR fused with DBR, and PR fused with MBR or DBR; in type 5 (e)—PR fused with MBR and DBR, and finally type 6 (f)—PR, MBR and DBR fused to form a cone-shaped root.

Three maxillary second molars were single-rooted. Due to the presence of only one canal, two single-rooted maxillary second molars ( $n = 2/386$ ) were classified as Vertucci Type I. The remaining single-rooted tooth demonstrated C-shaped anatomy and was considered unclassifiable according to the Vertucci system.

Of the two-rooted maxillary second molars, the majority of buccal roots displayed Type I configuration ( $n = 8/11$ , 72.7%), followed by Type III ( $n = 2/11$ , 18.2%) and II ( $n = 1/11$ , 9.1%) respectively. All two-rooted teeth's palatal roots displayed Type I configuration.

In three-rooted maxillary second molars, only teeth that maintained separate internal canal anatomy (i.e. no communication between the pulps of adjacent roots) were classified. Fused three-rooted teeth which shared canal anatomy between roots were considered unclassifiable using the Vertucci system due to difficulty in classification, a position adopted in previous studies [8].

The most common configuration in mesiobuccal roots was Type I ( $n = 121/371$ , 32.6%), followed by Type IV ( $n = 73/371$ , 19.7%), III ( $n = 64/371$ , 17.4%), II ( $n = 42/371$ , 11.3%) and V ( $n = 29/371$ , 7.8%). A number of mesiobuccal roots ( $n = 13/371$ , 3.5%) were considered unclassified. Additional canals were seen in 67.4% of mesiobuccal roots of three-rooted maxillary second molars. The majority of distobuccal ( $n = 352/371$ , 94.9%), as well as palatal ( $n = 365/371$ , 98.4%) roots, were single canal/Type I.

One four-rooted maxillary second molar was observed. This tooth displayed one mesiobuccal root, one palatal root, and two distobuccal roots. The two distobuccal roots arose from one single root, splitting approximately halfway down the length of the root. Whilst each root displayed individual canals in the apical third, the distobuccal root was classified as Vertucci Type V due to the overall canal morphology, and both the mesiobuccal and palatal roots were classified as Type I.

## Canal configurations according to the Ahmed et al. classification

The distribution of configurations of maxillary second molar teeth according to the Ahmed et al. classification can be found in Tables 2 and 3. Maxillary second molars were divided into

two groups, namely teeth without root fusion ( $n = 332/386$ , 86.0%) and teeth with root fusion ( $n = 54/386$ , 14.0%).

In the group without root fusion, three single-rooted teeth were observed. Two teeth displayed single canals and were assigned the code  $^1\text{MSM}^1$ . The remaining tooth displayed C-shaped morphology and was classified as  $(\text{CSC}^{\text{II}})^1\text{MSM}^{2-4-2}$ . This tooth had a complex internal canal structure reflecting a type 2 C-shaped morphology, as described by Fan et al. [23].

The most common configuration seen amongst the two-rooted maxillary second molars was  $^2\text{MSM B}^1 \text{P}^1$  ( $n = 8/332$ , 2.4%), followed by  $^2\text{MSM B}^{1-2-1} \text{P}^1$  ( $n = 2/332$ , 0.6%) and  $^2\text{MSM B}^{2-1} \text{P}^1$  ( $n = 1/332$ , 0.3%).

In three-rooted teeth, the most common configuration was  $^3\text{MSM MB}^1 \text{DB}^1 \text{P}^1$  ( $n = 96/332$ , 28.9%), followed by  $^3\text{MSM MB}^2 \text{DB}^1 \text{P}^1$  ( $n = 66/332$ , 20.0%),  $^3\text{MSM MB}^{1-2-1} \text{DB}^1 \text{P}^1$  ( $n = 55/332$ , 16.6%),  $^3\text{MSM MB}^{2-1} \text{DB}^1 \text{P}^1$  ( $n = 38/332$ , 11.4%) and  $^3\text{MSM MB}^{1-2} \text{DB}^1 \text{P}^1$  ( $n = 18/332$ , 5.4%). A large number of codes with a small number of representatives were seen in the remaining maxillary second molars (Table 2).

One four-rooted maxillary second molar was found and described as  $^4\text{MSM MB}^1 \text{MDB}^1 \text{DDB}^1 \text{P}^1$ .

In the group with root fusion (Table 3), only three-rooted teeth were observed. The most common configuration was  $(\text{RF}^2)^3\text{MSM MB}^1 \text{DB}^1 \text{P}^1$  ( $n = 11/54$ , 20.1%), followed by  $(\text{RF}^1)^3\text{MSM MB}^1 \text{DB}^1 \text{P}^1$  ( $n = 6/54$ , 11.0%) and thereafter  $(\text{RF}^1)^3\text{MSM MB}^{1-2-1} \text{DB}^1 \text{P}^1$  ( $n = 6/54$ , 11.0%). The remainder of the root fusion group also demonstrated a large number of codes with a small number of representatives.

When evaluated across both the fusion and non-fusion groups combined (i.e., the entire Ahmed et al. dataset), all codes indicating a single canal in the mesiobuccal root of three-rooted maxillary second molars (namely,  $^3\text{MSM}^1 \text{MB}^1 \text{DB}^1 \text{P}^1$ ,  $^3\text{MSM MB}^1 \text{DB}^1 \text{P}^1$ ,  $^3\text{MSM MB}^1 \text{DB}^{1-2-1} \text{P}^1$ ,  $(\text{RF}^1)^3\text{MSM MB}^1 \text{DB}^1 \text{P}^1$ ,  $(\text{RF}^2)^3\text{MSM MB}^1 \text{DB}^1 \text{P}^1$ ,  $(\text{RF}^3)^3\text{MSM MB}^1 \text{DB}^1 \text{P}^1$ ,  $(\text{RF}^4)^3\text{MSM MB}^1 \text{DB}^1 \text{P}^1$ ,  $(\text{RF}^5)^3\text{MSM MB}^1 \text{DB}^1 \text{P}^1$  and  $(\text{RF}^6)^3\text{MSM MB}^1 \text{DB}^1 \text{P}^1$ ) totalled 32.6% ( $n = 121/371$ ).

## Effect of age and sex on canal configuration

No relationships were found between age and Vertucci classification ( $p = 0.48$ ), as well as age and Ahmed et al.

**TABLE 1** Canal configurations per root of maxillary second molars according to the Vertucci classification.

Root number	Canal location	I (%)	II (%)	III (%)	IV (%)	V (%)	VI (%)	VII (%)	X (%)	XII (%)	XV (%)	XVII (%)	XVIII (%)	XIX (%)	Unclassified (%)	Total n of teeth
One	Central	2 (66.7)													1 (33.3)	3
Two	B	8 (72.7)	1 (9.1)	2 (18.2)												11
	P	11 (100)														
Three	MB	121 (32.6)	42 (11.3)	64 (17.4)	73 (19.7)	29 (7.8)	9 (2.4)	7 (1.9)	5 (1.3)	2 (0.5)	1 (0.3)	2 (0.5)	1 (0.3)	2 (0.5)	13 (3.5)	371
	DB	352 (94.9)	1 (0.3)	4 (1.1)		2 (0.5)									12 (3.2)	
	P	365 (98.4)		3 (0.8)											2 (0.5)	
Four	MB	1 (100)				1 (100)										1
	DB/DB2 P	1 (100)														
Total																386

classification ( $p = 0.88$ ). Furthermore, no relationship was observed between sex and Vertucci classification ( $p = 0.37$ ) or Ahmed et al. ( $p = 0.72$ ) classification. No relationship was found between sex and the presence of root fusion ( $p = 0.74$ ).

## DISCUSSION

Neglecting to identify and treat all canals in a given tooth may lower the success of endodontic treatment [1], resulting in persistent periapical inflammation [10]. Practitioners may ameliorate this problem by developing an intimate knowledge of the root canal system and its variations [4]. Maxillary second molars display complex root and canal configurations and have greater variation than maxillary first molars [10, 12].

A small number of studies considering the endodontic anatomy of South African populations have been conducted [3, 4, 20, 24]. None of these studies presents information on an exclusively Black South African population. Fernandes et al. reported the prevalence of second mesiobuccal canals in maxillary molars of a mixed South African population. Their investigation did not consider other roots and did not consider the population group [20]. The present study, therefore, reports novel and detailed information from a previously unreported population group.

The vast majority of maxillary second molars in the present study were three-rooted. This finding is in agreement with those of numerous studies from other population groups [6–8, 10–13]. Variation in root number is commonly seen [7, 8]. Single- and double-rooted variations have commonly been reported, albeit with a lower prevalence than their three-rooted counterparts [7, 8, 11]. Four-rooted second molars are an uncommon finding [8, 11]. This assertion was supported by the findings of the present study.

Root fusion is commonly seen in maxillary second molars [9]. Fusion of roots is thought to occur due to increased cementum deposition over time or a failure of Hertwig's epithelial root sheath to develop or fuse in the furcal area [25]. The presentation of fusion in maxillary molars may vary with partial or complete fusion of two or more roots [9]. Endodontic treatment of teeth with fused roots may be more challenging as complex internal anatomy may lead to higher failure rates [11]. The present study found a 14.0% prevalence of root fusion in maxillary second molars, equal to that reported in a Ugandan population [26]. This similarity may be due to both populations including predominantly subjects of African origin. The prevalence of root fusion in the present study was higher than that reported in Korean

**TABLE 2** Root canal configurations of maxillary second molar teeth without root fusion according to the Ahmed et al. classification.

Configuration according to Ahmed (2017) classification			
Configuration	Number (n =)	Total percentage (%)	Cumulative total
<b>Teeth with/without root fusion</b>			
<sup>1</sup> MSM <sup>1</sup>	2	0.6	2
(CSC <sup>II</sup> ) <sup>1</sup> MSM <sup>2-4-2</sup>	1	0.3	3
<sup>2</sup> MSM B <sup>1</sup> P <sup>1</sup>	8	2.4	11
<sup>2</sup> MSM B <sup>1-2-1</sup> P <sup>1</sup>	2	0.6	13
<sup>2</sup> MSM B <sup>2-1</sup> P <sup>1</sup>	1	0.3	14
<sup>3</sup> MSM <sup>1</sup> MB <sup>1</sup> DB <sup>1</sup> P <sup>1</sup>	3	0.9	17
<sup>3</sup> MSM <sup>BR</sup> MB <sup>1-2</sup> DB <sup>1</sup> P <sup>1</sup>	2	0.6	19
<sup>3</sup> MSM <sup>BR</sup> MB <sup>2</sup> DB <sup>1</sup> P <sup>1</sup>	1	0.3	20
<sup>3</sup> MSM MB <sup>1</sup> DB <sup>1</sup> P <sup>1</sup>	96	28.9	116
<sup>3</sup> MSM MB <sup>1</sup> DB <sup>1-2-1</sup> P <sup>1</sup>	1	0.3	117
<sup>3</sup> MSM MB <sup>1-2</sup> DB <sup>1</sup> P <sup>1</sup>	18	5.4	135
<sup>3</sup> MSM MB <sup>1-2-1</sup> DB <sup>1</sup> P <sup>1</sup>	55	16.6	190
<sup>3</sup> MSM MB <sup>1-2-1</sup> DB <sup>1</sup> P <sup>1-2-1</sup>	2	0.6	192
<sup>3</sup> MSM MB <sup>1-2-1</sup> DB <sup>1</sup> P <sup>2-1-2-1</sup>	1	0.3	193
<sup>3</sup> MSM MB <sup>1-2-1</sup> DB <sup>1-2-1</sup> P <sup>1</sup>	1	0.3	194
<sup>3</sup> MSM MB <sup>1-2-1-2</sup> DB <sup>1</sup> P <sup>1</sup>	7	2.1	201
<sup>3</sup> MSM MB <sup>1-2-3-2</sup> DB <sup>1</sup> P <sup>1</sup>	3	0.9	204
<sup>3</sup> MSM MB <sup>1-2-3-2</sup> DB <sup>1-2</sup> P <sup>1</sup>	1	0.3	205
<sup>3</sup> MSM MB <sup>1-3-1</sup> DB <sup>1</sup> P <sup>1</sup>	1	0.3	206
<sup>3</sup> MSM MB <sup>1-3-1</sup> DB <sup>1-2</sup> P <sup>1</sup>	1	0.3	207
<sup>3</sup> MSM MB <sup>2</sup> DB <sup>1</sup> P <sup>1</sup>	66	20.0	273
<sup>3</sup> MSM MB <sup>2</sup> DB <sup>2-1</sup> P <sup>1</sup>	1	0.3	274
<sup>3</sup> MSM MB <sup>2-1</sup> DB <sup>1</sup> P <sup>1</sup>	38	11.4	312
<sup>3</sup> MSM MB <sup>2-1</sup> DB <sup>1</sup> P <sup>1-2-1</sup>	1	0.3	313
<sup>3</sup> MSM MB <sup>2-1</sup> DB <sup>1-2-1</sup> P <sup>1</sup>	2	0.6	315
<sup>3</sup> MSM MB <sup>2-1-2</sup> DB <sup>1</sup> P <sup>1</sup>	8	2.4	323
<sup>3</sup> MSM MB <sup>2-1-2-1</sup> DB <sup>1</sup> P <sup>1</sup>	3	0.9	326
<sup>3</sup> MSM MB <sup>2-3-1</sup> DB <sup>1</sup> P <sup>1</sup>	2	0.6	328
<sup>3</sup> MSM MB <sup>2-3-2</sup> DB <sup>1</sup> P <sup>1</sup>	1	0.3	329
<sup>3</sup> MSM MB <sup>3-1</sup> DB <sup>1</sup> P <sup>1</sup>	1	0.3	330
<sup>3</sup> MSM MB <sup>3-2</sup> DB <sup>1</sup> P <sup>1</sup>	1	0.3	331
<sup>4</sup> MSM MB <sup>1</sup> MDB <sup>1</sup> DDB <sup>1</sup> P <sup>1</sup>	1	0.3	332
Total	332	100	332

[8], Indian [27], Thai [28], Brazilian [12] and Burmese [29] populations, but lower than that of Chinese populations [9–11, 14]. These reported variations may be explained by racial differences between population groups. Differing study designs and methodologies [9], including the definition of the presence of root fusion [8, 9] may influence this number.

Both race and ethnicity have been suggested to influence differences in the root canal morphology of maxillary

second molar teeth [9, 10]. It has further been suggested that geographic distribution contributes to the variation of canal anatomy between different population groups [3]. Studies of other Southern African populations may be beneficial in the description of the prevailing dental anatomy of the region.

In line with the findings of other studies, single-rooted teeth commonly displayed only one canal and two-rooted teeth two canals [8]. When considering the mesiobuccal root of three-rooted teeth, second (MB2), or additional

**TABLE 3** Root canal configurations of maxillary second molar teeth with root fusion according to the Ahmed et al classification.

Configuration according to Ahmed (2017) classification			
Configuration	Number (n =)	Total percentage (%)	Cumulative total
<b>Teeth with root fusion</b>			
(RF <sup>1</sup> ) <sup>3</sup> MSM <sup>1</sup> MB <sup>2</sup> DB <sup>1</sup> P <sup>1</sup>	1	1.9	1
(RF <sup>1</sup> ) <sup>3</sup> MSM MB//DB <sup>2-1</sup> P <sup>1</sup>	2	3.7	3
(RF <sup>1</sup> ) <sup>3</sup> MSM MB <sup>1</sup> DB <sup>1</sup> P <sup>1</sup>	6	11.0	9
(RF <sup>1</sup> ) <sup>3</sup> MSM MB <sup>1-2</sup> DB <sup>1</sup> P <sup>1</sup>	4	7.2	13
(RF <sup>1</sup> ) <sup>3</sup> MSM MB <sup>1-2-1</sup> DB <sup>1</sup> P <sup>1</sup>	5	9.1	18
(RF <sup>1</sup> ) <sup>3</sup> MSM MB <sup>2</sup> DB <sup>1</sup> P <sup>1</sup>	1	1.9	19
(RF <sup>1</sup> ) <sup>3</sup> MSM MB <sup>2-1</sup> DB <sup>1</sup> P <sup>1</sup>	1	1.9	20
(RF <sup>2</sup> ) <sup>3</sup> MSM <sup>1</sup> MB <sup>1-2</sup> DB <sup>1</sup> P <sup>1</sup>	1	1.9	21
(RF <sup>2</sup> ) <sup>3</sup> MSM MB <sup>1</sup> DB <sup>1</sup> P <sup>1</sup>	11	20.1	32
(RF <sup>2</sup> ) <sup>3</sup> MSM MB <sup>1-2</sup> DB <sup>1</sup> P <sup>1</sup>	3	5.5	35
(RF <sup>2</sup> ) <sup>3</sup> MSM MB <sup>1-2-3-2</sup> DB <sup>1</sup> P <sup>1</sup>	1	1.9	36
(RF <sup>2</sup> ) <sup>3</sup> MSM MB <sup>2</sup> DB <sup>1</sup> P <sup>1</sup>	2	3.7	38
(RF <sup>3</sup> ) <sup>3</sup> MSM MB <sup>1</sup> DB <sup>1</sup> P <sup>1</sup>	1	1.9	39
(RF <sup>3</sup> ) <sup>3</sup> MSM MB <sup>2</sup> DB <sup>1</sup> P <sup>1</sup>	1	1.9	40
(RF <sup>4</sup> ) <sup>3</sup> MSM MB//DB <sup>1-2</sup> P <sup>1</sup>	1	1.9	41
(RF <sup>4</sup> ) <sup>3</sup> MSM MB//DB <sup>1-2-1</sup> P <sup>1</sup>	2	3.7	43
(RF <sup>4</sup> ) <sup>3</sup> MSM MB//DB <sup>1-2-1</sup> P <sup>1-2-1</sup>	1	1.9	44
(RF <sup>4</sup> ) <sup>3</sup> MSM MB//DB <sup>2-1</sup> P <sup>1</sup>	1	1.9	45
(RF <sup>4</sup> ) <sup>3</sup> MSM MB <sup>1</sup> DB <sup>1</sup> P <sup>1</sup>	1	1.9	46
(RF <sup>4</sup> ) <sup>3</sup> MSM MB <sup>1-2</sup> DB <sup>1</sup> P <sup>1</sup>	1	1.9	47
(RF <sup>5</sup> ) <sup>3</sup> MSM MB//DB <sup>1-2-1</sup> P <sup>1</sup>	2	3.7	49
(RF <sup>5</sup> ) <sup>3</sup> MSM MB//DB <sup>2-1-2</sup> P <sup>1</sup>	1	1.9	50
(RF <sup>5</sup> ) <sup>3</sup> MSM MB <sup>1</sup> DB <sup>1</sup> P <sup>1</sup>	1	1.9	51
(RF <sup>6</sup> ) <sup>3</sup> MSM MB//DB//P <sup>1-2</sup>	1	1.9	52
(RF <sup>6</sup> ) <sup>3</sup> MSM MB//DB//P <sup>3-2</sup>	1	1.9	53
(RF <sup>6</sup> ) <sup>3</sup> MSM MB <sup>1</sup> DB <sup>1</sup> P <sup>1</sup>	1	1.9	54
Total	54	100	54

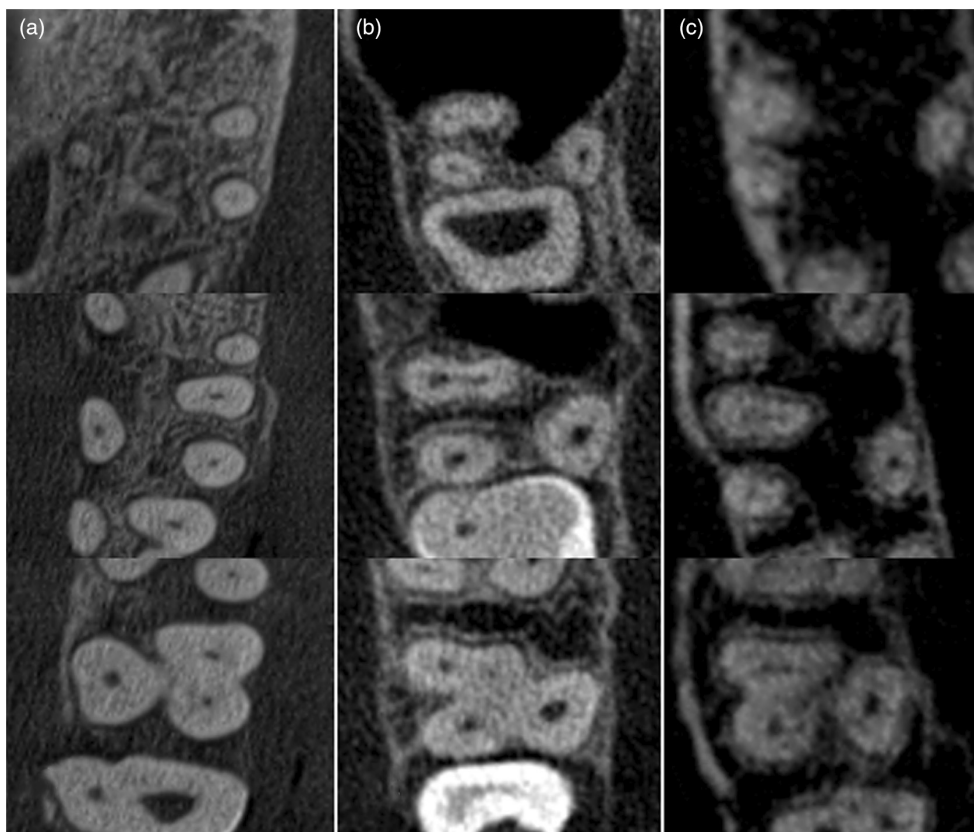
canals, were present 67.4% of the time (Figure 5). This finding is similar to those reported by Fernandes et al. [20] in a South African population. The prevalence of MB2 canals of maxillary second molars in the present study was higher than those of Ugandan, Chinese [9–11], Korean [8], Brazilian [12] and Thai [28] populations, but lower than that of another Brazilian population [30]. Plotino et al. [13] reported a 15.1% prevalence of MB2 in the maxillary second molars of a white population but did not state the nationality of the sample. The single most common canal configuration in the mesiobuccal root of three-rooted teeth was a single canal (32.6%), in line with the findings of others [11–13]. A selection of anatomical configurations according to the Vertucci and Ahmed et al. classifications can be observed in Figures 6 and 7, respectively.

In the present study, two separate foramina constituted the most common type of MB2. This configuration has been suggested to be a trait more frequently seen in Asian populations [28].

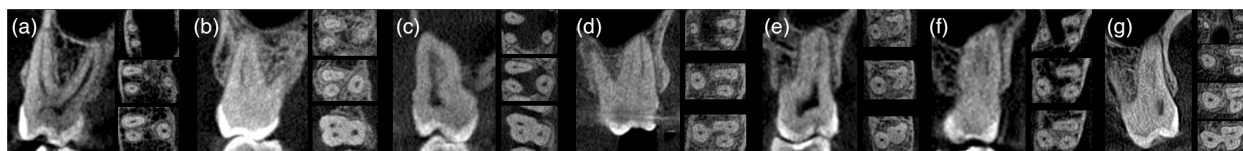Additional canals in the distobuccal and palatal roots were uncommon in the present study, in line with the findings in numerous other population groups [8, 10–12]. In line with the findings of others, only one C-shape maxillary second molar was found in the present study, indicating a low prevalence of this variation in this tooth type [14].

No relationships were observed between root and canal morphology versus the variables of age and sex. This is in agreement with Fernandes et al. [20]. Other authors have observed a reduced MB2 prevalence with increasing age [2, 8, 10, 30]. Increasing age may, therefore, in some

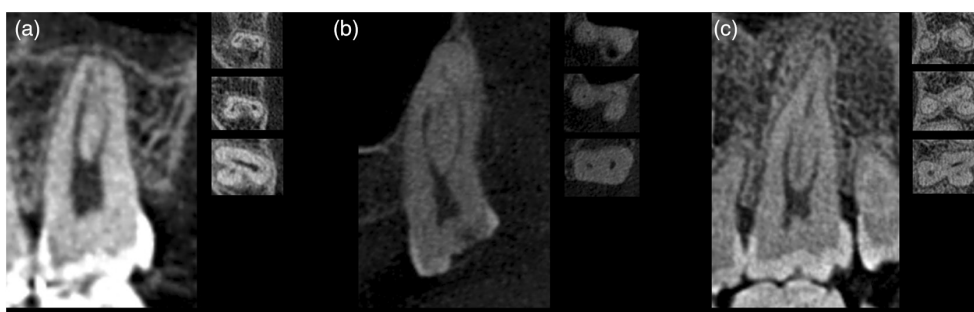




**FIGURE 5** Axial views (representative coronal, middle and apical CBCT slices from bottom to top) demonstrating a selection of internal variations of the mesiobuccal roots of three-rooted maxillary second molars. Single canal configurations ((a) Vertucci type I) in the mesiobuccal root were seen in approximately one-third of the teeth studied. Additional canal anatomy, such as MB2 canals ((b) Vertucci type IV) or at times even three canals ((c) Vertucci type XVIII) were observed in more than two-thirds (67.4%) of the sample.



**FIGURE 6** Coronal and axial views (including representative coronal, middle and apical CBCT slices from bottom to top) demonstrating the Vertucci configurations found in the mesiobuccal roots of three-rooted maxillary second molars in the present study. Vertucci type I (a), type II (b), type III (c), type IV (d), type V (e), type VI (f) and type VII (g) were observed. No type VIII configurations were found.



**FIGURE 7** Coronal and axial views (including representative coronal, middle and apical CBCT slices from bottom to top) demonstrating a selection of maxillary second molars in the present study described using the Ahmed et al. system. A C-shaped maxillary molar is demonstrated in (a), reported as  $(CSC^{II})^1MXM^{2-4-2}$ . In (b) an example of type 4 root fusion is shown, coded as  $(RF^4)^3MXM\ MB//DB^{1-2-1}P^1$ . (c) Displays a type 1 root fusion described as  $(RF^1)^3MXM\ MB//DB^{2-1}P^1$ . These figures represent examples of teeth which could not be classified using the Vertucci classification, due to the high level of anatomical complexity and shared internal anatomy between fused roots.

populations, lead to simpler internal anatomy due to calcification and reduction in pulp volume, however, MB2 canals may present at any age [20]. Although not observed in the present study, sex has previously been reported as a factor which may impact the configuration of root canal systems [22, 31].

Two classification systems were used in the present study. The Vertucci classification is well-known with extensive use in anatomical research [5]. Additions such as those by Sert and Bayirli, incorporating more complex variations, extended the application of the Vertucci classification [2]. The Vertucci classification cannot, however, be used to describe root numbers, complex configurations or the presence of dental anomalies or variations [17]. The present study, as in other investigations, did not describe teeth displaying fused roots sharing internal canal anatomy using Vertucci's classification [8, 11]. This was done as an adequate description of such canal morphologies is often not possible. Additionally, in molar teeth, the Vertucci classification is applied per individual root [5], an impossibility in fusion with shared canal anatomy.

Ahmed et al. [17] proposed a system describing both root and canal morphology. This newer classification provides an accurate description of both simple and complex anatomy, as well as the ability to report anatomical variations and dental anomalies [17, 21]. The Ahmed et al. classification could report all configurations in the present study. This should be seen as an advantage over the Vertucci system. One previous study reported that only small numbers of teeth could not be classified using the Vertucci classification alone [3]. This study however described maxillary premolars, which display relatively simple anatomy when compared to maxillary second molars. Whilst an increasing number of studies have reported root and canal morphology according to the Ahmed et al. [32, 33] system, a limited number have, to date, compared the Ahmed et al. [18] and Vertucci classification systems. The present study, therefore, improves the knowledge regarding the usage and comparability of the Ahmed et al. system in complex tooth types. It was notable that major findings, such as the overall prevalence of MB2 canals in three-rooted maxillary second molars were similar despite the classification system used.

Cone-beam computed tomography is a clinically effective, non-invasive tool that can be used for the evaluation of root and canal anatomy in living subjects [8]. The technology has proved effective in the study of roots and canals in a number of different tooth types [3, 4, 8]. When compared to other methods used for the determination of root and canal morphology, CBCT has been found equal to, or better than, the modified clearing and staining technique, peripheral quantitative computed tomography, spiral computed tomography and digital radiography [16].

Limitations of the present study included the 200  $\mu$ m resolution of the CBCT scans used, as well as the self-reported race of the subjects when creating a hospital file.

In summary, the maxillary second molars of this Black South African population demonstrated a wide range of root and canal morphologies. Three-rooted maxillary second molars were the most prevalent root configuration, with root fusion observed in 14% of teeth studied. The mesiobuccal roots of maxillary second molars in this population displayed the greatest variation in canal morphology, with 67.4% containing MB2 canals/additional anatomy. No relationships between canal morphology and the variables of age and sex were found. Anatomical variations of maxillary second molars were frequently encountered in this population group, with implications for clinicians performing endodontic treatment. The Ahmed et al. system, in contrast to the Vertucci classification, was able to classify all teeth, regardless of complexity. The use of CBCT for the evaluation of root and canal morphology relevant to endodontics was confirmed.

#### AUTHOR CONTRIBUTIONS

All authors have contributed significantly and are in agreement with the manuscript.

#### ACKNOWLEDGEMENT

None.

#### CONFLICT OF INTEREST

The authors deny any conflicts of interest related to this study. Root and canal morphology of maxillary second molars in a Black South African subpopulation using CBCT and two classifications.

#### FUNDING INFORMATION

This research did not receive any specific funding from agencies in the public, commercial or not-for-profit sectors.

#### ORCID

Glynn Dale Buchanan  <https://orcid.org/0000-0003-2957-166X>

#### REFERENCES

1. Vertucci FJ. Root canal morphology and its relationship to endodontic procedures. *Endod Top*. 2005;10:3–29.
2. Sert S, Bayirli GS. Evaluation of the root canal configurations of the mandibular and maxillary permanent teeth by gender in the Turkish population. *J Endod*. 2004;30:391–8.
3. Buchanan GD, Gamielien MY, Tredoux S, Vally ZI. Root and canal configurations of maxillary premolars in a south African subpopulation using cone beam computed tomography and two classification systems. *J Oral Sci*. 2020;62:93–7.

4. Tredoux S, Warren N, Buchanan GD. Root and canal configurations of mandibular first molars in a south African subpopulation. *J Oral Sci.* 2021;63:252–6.
5. Vertucci FJ. Root canal anatomy of the human permanent teeth. *Oral Surg Oral Med Oral Pathol.* 1984;58:589–99.
6. Wu D, Zhang G, Liang R, Zhou G, Wu Y, Sun C, et al. Root and canal morphology of maxillary second molars by cone-beam computed tomography in a native Chinese population. *J Int Med Res.* 2017;45:830–42.
7. Peikoff MD, Christie WH, Fogel HM. The maxillary second molar: variations in the number of roots and canals. *Int Endod J.* 1996;29:365–70.
8. Kim Y, Lee S, Woo J. Morphology of maxillary first and second molars analyzed by cone-beam computed tomography in a Korean population: variations in the number of roots and canals and the incidence of fusion. *J Endod.* 2012;38:1063–8.
9. Zhang Q, Chen H, Fan B, Fan W, Gutmann JL. Root and root canal morphology in maxillary second molar with fused root from a native Chinese population. *J Endod.* 2014;40:871–5.
10. Zhang R, Yang H, Yu X, Wang H, Hu T, Dummer PMH. Use of CBCT to identify the morphology of maxillary permanent molar teeth in a Chinese subpopulation. *Int Endod J.* 2011;44:162–9.
11. Tian X, Yang X, Qian L, Wei B. Analysis of the root and canal morphologies in maxillary first and second molars in a Chinese population using cone-beam computed tomography. *J Endod.* 2016;42:696–701.
12. Silva EJNL, Nejaim Y, Silva Amaro AIV, Haiter-Neto F, Zaia AA, Cohenca N. Evaluation of root canal configuration of maxillary molars in a Brazilian population using cone-beam computed tomographic imaging: an in vivo study. *J Endod.* 2014;40:173–6.
13. Plotino G, Tocci L, Grande NM, Testarelli L, Messineo D, Ciotti M, et al. Symmetry of root and root canal morphology of maxillary and mandibular molars in a white population: a cone-beam computed tomography study in vivo. *J Endod.* 2013;39:1545–8.
14. Yang ZP, Yang SF, Lee G. The root and root canal anatomy of maxillary molars in a Chinese population. *Endod Dent Traumatol.* 1988;4:215–8.
15. Patel S, Durack C, Abella F, Shemesh H, Roig M, Lemberg K. Cone beam computed tomography in endodontics – a review. *Int Endod J.* 2015;48:3–15.
16. Neelakantan P, Subbarao C, Subbarao CV. Comparative evaluation of modified canal staining and clearing technique, cone-beam computed tomography, peripheral quantitative computed tomography, spiral computed tomography, and plain and contrast medium-enhanced digital radiography in studying root canal morphology. *J Endod.* 2010;36:1547–51.
17. Ahmed HMA, Versiani MA, De-Deus G, Dummer PMH. A new system for classifying root and root canal morphology. *Int Endod J.* 2017;50:761–70.
18. Ahmed HMA. A critical analysis of laboratory and clinical research methods to study root and canal anatomy. *Int Endod J.* 2022;55(S2):229–80.
19. Statistics South Africa. Formal Census 2011. [PDF of Internet]. South Africa. <https://www.statssa.gov.za/publications/P03014/P030142011.pdf>. Accessed 1 June 2022.
20. Fernandes NA, Herbst D, Postma TC, Bunn BK. The prevalence of second canals in the mesiobuccal root of maxillary molars: a cone beam computed tomography study. *Aust Endod J.* 2019;45:46–50.
21. Ahmed HMA, Ibrahim N, Mohamad NS, Nambiar P, Muhammad RF, Yusoff M, et al. Application of a new system for classifying root and canal anatomy in studies involving micro-computed tomography and cone beam computed tomography: explanation and elaboration. *Int Endod J.* 2021;54:1056–82.
22. Buchanan GD, Gamielidien MY, Fabris-rotelli I, Schoor A, Uys A. Root and canal morphology of the permanent anterior dentition in a black south African population using cone-beam computed tomography and two classification systems. *J Oral Sci.* 2022;64:218–23.
23. Fan B, Cheung GSP, Fan M, Gutmann JL, Bian Z. C-shaped canal system in mandibular second molars: part I—anatomical features. *J Endod.* 2004;30:899–903.
24. Martins JNR, Alkhawas MBAM, Altaki Z, Bellardini G, Berti L, Boveda C, et al. Worldwide analyses of maxillary first molar second mesiobuccal prevalence: a multicenter cone-beam computed tomographic study. *J Endod.* 2018;44:1641–9.
25. Al-Fouzan KS. C-shaped root canals in mandibular second molars in a Saudi Arabian population. *Int Endod J.* 2002;35:499–504.
26. Rwenyonyi CM, Kutesa AM, Muwazi LM, Buwembo W. Root and canal morphology of maxillary first and second permanent molar teeth in a Ugandan population. *Int Endod J.* 2007;40:679–83.
27. Neelakantan P, Subbarao C, Ahuja R, Subbarao CV, Gutmann JL. Cone-beam computed tomography study of root and canal morphology of maxillary first and second molars in an Indian population. *J Endod.* 2010;36:1622–7.
28. Alavi AM, Opananon A, Ng YL, Gulabivala K. Root and canal morphology of Thai maxillary molars. *Int Endod J.* 2002;35:478–85.
29. Ng YL, Aung TH, Alavi A, Gulabivala K. Root and canal morphology of Burmese maxillary molars. *Int Endod J.* 2001;34:620–30.
30. Reis AG, Grazziotin-Soares R, Barletta FB, Fontanella VR, Mahl CR. Second canal in mesiobuccal root of maxillary molars is correlated with root third and patient age: a cone-beam computed tomographic study. *J Endod.* 2013;39:588–92.
31. Buchanan GD, Gamielidien MY, Fabris-Rotelli I, van Schoor A, Uys A. A study of mandibular premolar root and canal morphology in a black south African population using cone-beam computed tomography and two classification systems. *J Oral Sci.* 2022;64:300–6.
32. Olczak K, Pawlicka H, Szymański W. Root form and canal anatomy of maxillary first premolars: a cone-beam computed tomography study. *Odontology.* 2022;110:365–75.
33. Olczak K, Pawlicka H, Szymański W. Root and canal morphology of the maxillary second premolars as indicated by cone beam computed tomography. *Aust Endod J.* 2022;1–12. <https://doi.org/10.1111/aej.12624>

**How to cite this article:** Buchanan GD, Gamielidien MY, Fabris-Rotelli I, Van Schoor A, Uys A. Root and canal morphology of maxillary second molars in a Black South African subpopulation using cone-beam computed tomography and two classifications. *Aust Endod J.* 2023;49(Suppl. 1):217–227. <https://doi.org/10.1111/aej.12720>